1
Leave Feedba

BASICS OF EAR

BASICS OF EAR

00:00:50

External ear.
Middle ear.
Internal ear.

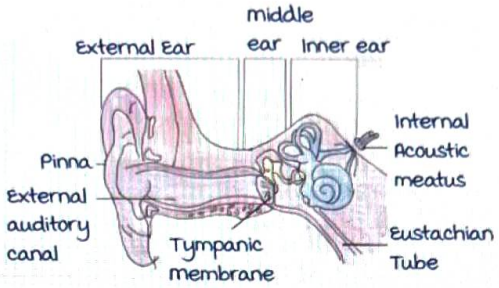

External ear :

- Pinna.
- External Auditory Canal (EAC).
- Tympanic Membrane (TM).

Middle ear : Medial to tympanic membrane.
3 ossicles.
Eustachian tube (ET tube) : Connection between middle ear and pharynx.

- Ventilates middle ear.
- Ventilation is required for proper vibration.
- Maintains middle ear pressure.
- Drainage of secretion of middle ear (defect leads to collection of fluid : Serous otitis media).

Even infection of pharynx,throat or URT can lead to acute infection of ME.

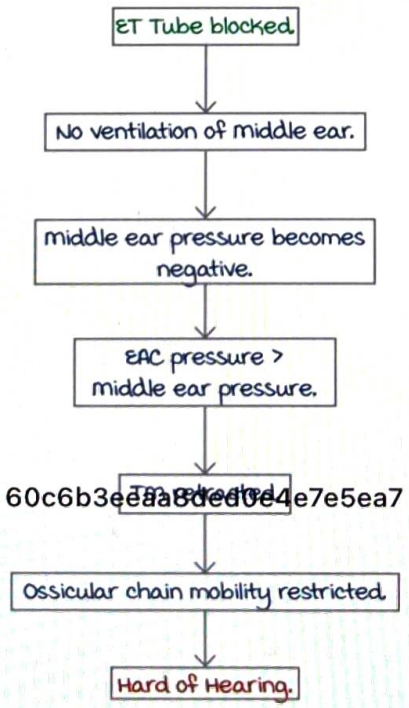

60c6b3ee4a8ded0e4e7e5ea7

Active space

Leave Feedbac

Inner ear : medial to middle ear
AKA labyrinth.
2 parts : membranous and Bony.

Medial to inner ear : Cranium (base of skull).
Connection from Inner ear to brain (posterior cranial fossa).

↓

Internal Acoustic meatus.
(Base of skull).

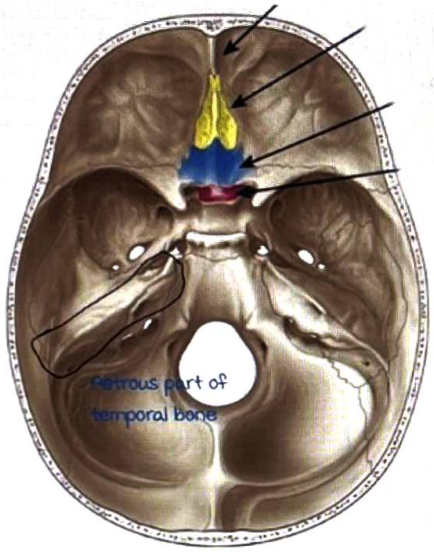

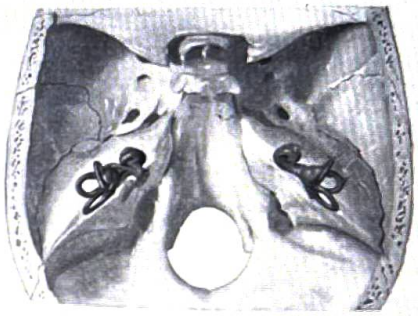

60c6b3eeaa8ded0e4e7e5ea7

Parts of temporal bone

00:10:05

- Petrous part of temporal bone : AKa petrous pyramid.
  Contains ME and IE.
  Formation of inner part of mastoid .
- Squamous part : Forms outer part of mastoid.
- Tympanic bone.
- Mastoid.
- Styloid Process.

Active space

Leave Feedba

Whole of ear is present inside temporal bone in the form of tunnel.
Any infection ascending superiorly reaches cranium(temporal lobe).

Roof of middle ear : Tegmen tympani (anterior slant of petrous part of temporal bone).

Superior SCC bulges at arcuate eminence : Can be dehiscent.
If dehiscent, called as 3rd window syndrome.
Increase ICP, transmitted to inner ear, inner ear stimulated resulting in inner ear symptoms.

Meckel's Cave : Depression medial to arcuate eminence.
Gasserian ganglion (Trigeminal Ganglion) :
Ophthalmic branch - goes through superior orbital fissure in eye,
Maxillary branch - goes through foramen rotrandum &
Mandibular branch - goes out through foramen ovale).

kumarankitindia1@gmail.com

In case of infections :
Symptoms such as parasthesia of face, absent corneal reflexes.

Cranial nerves in base of skull 00:21:04

- Petrous apex : CN VI (junction of Pons and medulla).
  Any pathology (petrositis) in petrous apex involves CN V VI : Diplopia.
- Internal acoustic meatus (posterior slant) : CN VII and CN VIII.

Active space

Leave Feedbac

- Jugular foramen : CN IX, CN X and CN XI.
- Posterior boundary of mastoid : Sigmoid sinus (Jugular bulb : A continuation of sigmoid sinus). Can lead to jugular vein thrombosis (extension) Lies in floor of middle ear.

Base of Skull

00:31:57

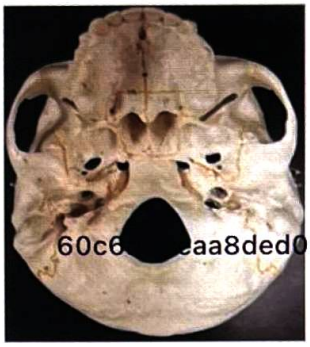

Floor of middle ear : Infection of ME descend downs here.
Jugular foramen : Junction of petrous and occipital bone.

Carotid canal : Anterior to ear and jugular formen.

- Cervical part of carotid enters petrous part : Vertical segment of carotid (runs vertically).
- Genu.
- Horizontal Segment.
- Foramen Lacerum.
- Cavernous Sinus.

In aneurysms of carotid : Ear complaints are common.

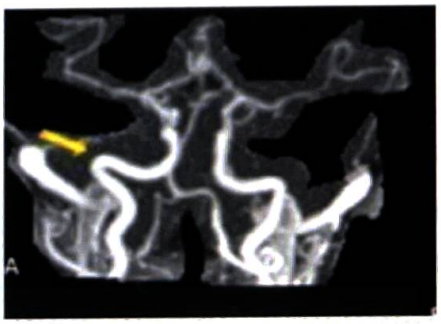

In otitis externa : Can lead to skull base osteomyelitis.

Active space

Leave Feedba

Stylomastoid foramen : CN VII (Infection of EAC – CN VII involved).

Infection from ear going :

- Superior : Intra cranially CN IX, X and XI at jugular foramen.
- Base of Skull : CN IX, X and XI.
- Can involve CN VI also (petrositis).

Investigations 00:39:38

Best for ear : HRCT of temporal bone.

8ded0e4e7e5ea7

Active space

Leave Feedback

CLINICAL EMBRYOLOGY OF INNER EAR

Basic structure 00:01:20

- membranous labyrinth is surrounded by bony labyrinth.
- membranous labyrinth has endolymph ; bony labyrinth has perilymph.

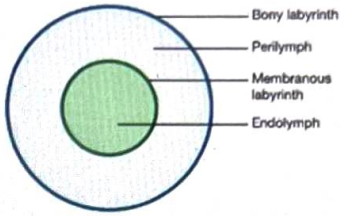

- Inner ear is laterally connected (by openings in bony labyrinth) to middle ear and, medially connected to cranium (brain).

Embryology of membranous labyrinth 00:03:23

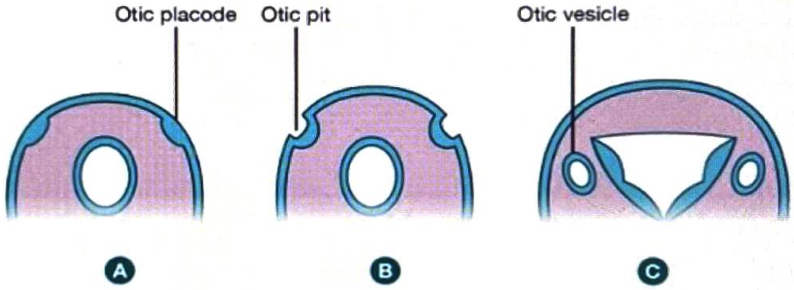

membranous labyrinth develops from the surface ectoderm.
(otic placode ⟶ otic pit ⟶ otic vesicle)

Outpouchings develop from otic vesicle, from which rest of the membranous labyrinth develops.

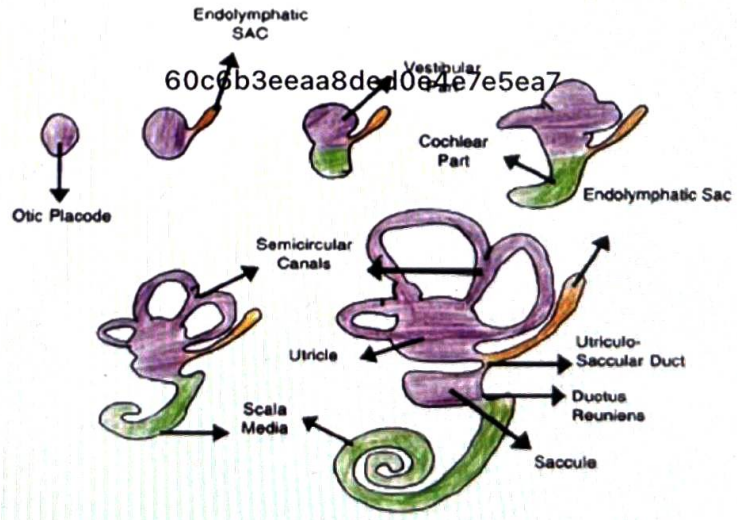

60c6b3eeaa8de10e4e7e5ea7

Active space

Leave Feedba

Parts of membranous labyrinth :

- 3 semi-circular canals (SCC) : Superior (anterior), posterior and lateral SCC.
- Crus commune : Common opening for superior & posterior SCC.
- Posterior SCC : Opens into the utricle & saccule through 5 openings.
- Utricle & saccule gives 2 ducts that joins to form endolymphatic sac (responsible for absorption of endolymph).
- Utricle & saccule opens into scala media / membranous cochlea (takes 2.5 to 2.75 turns around modiolus / bony pyramid).

60c6b3eeaa8ded0e4e7e5ea7

Functions of membranous labyrinth 00:12:11

Major functions : hearing and balance.
Sensory end organ of hearing : organ of corti (present in scala media).
Sensory end organ of balance : cristae (present in 3 SCC - for rotational acceleration), and maculae (present in utricle and saccule for linear acceleration, head tilt & gravitational movements).

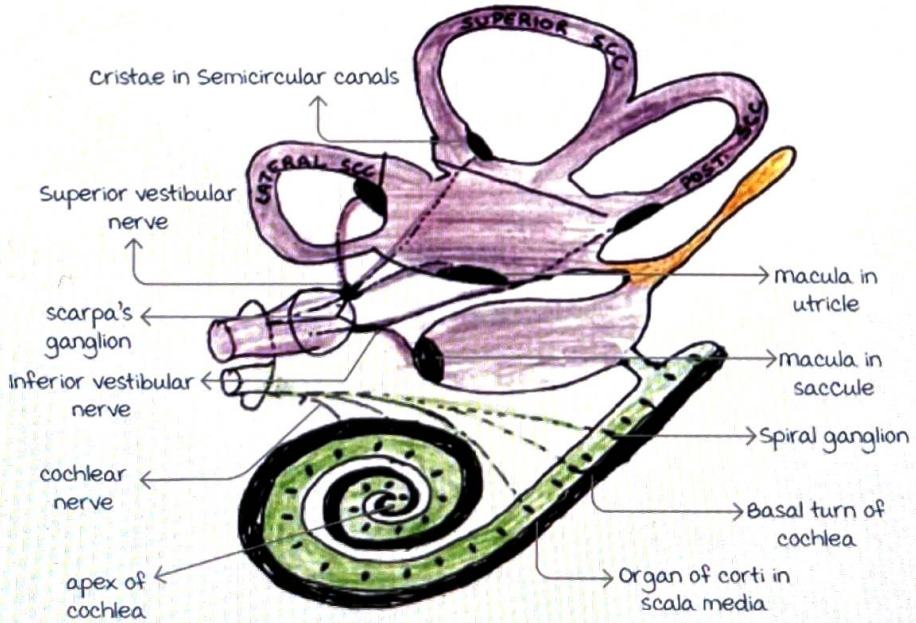

Active space

Leave Feedbac

Apex of organ of corti : senses sound vibrations of low frequency (affected early in meniere's disease).
Base of organ of corti : senses sound vibrations of high frequency.

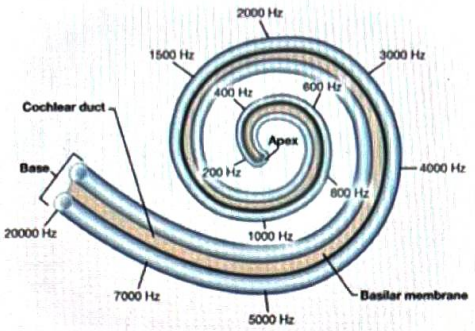

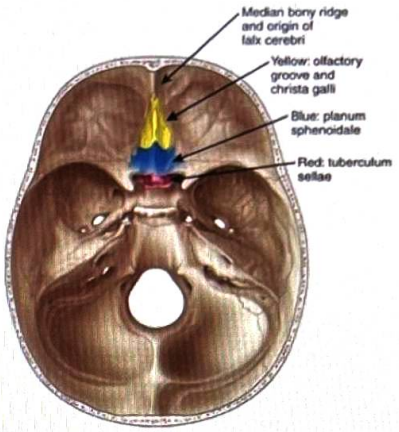

Bony labyrinth

00:20:11

kumarankitindia1@gmail.com

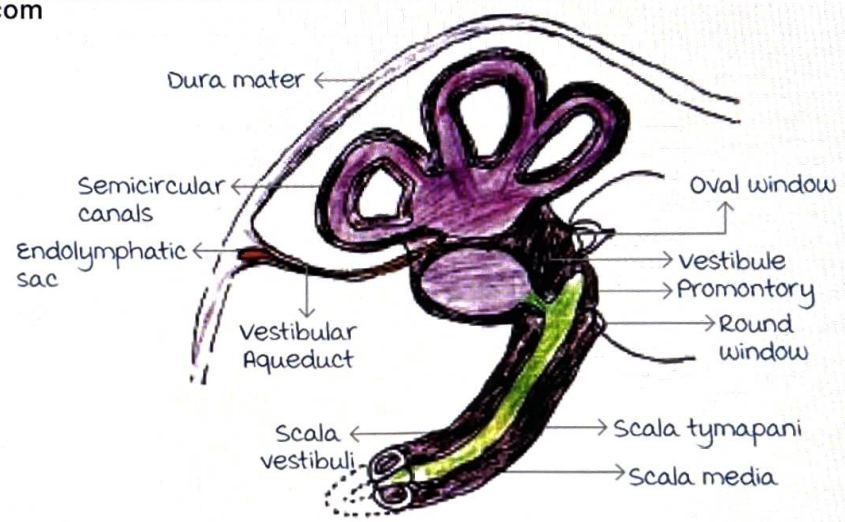

Bony labyrinth develops from mesoderm by enchondral ossification, and then differentiates into cartilage and bone.

Parts of bony labyrinth :

1. Three SCC :
   Superior SCC : bulges on the anterior slant of petrous part of temporal bone, into the base of skull ;
   clinical significance – superior SCC dehiscence syndrome or, 3rd window syndrome.
   Posterior SCC : bulges towards the mastoid.
   Lateral SCC : bulges towards the middle ear.
2. Vestibule : part of bony labyrinth around utricle & saccule.

Active space

3. Scala media : divides bony labyrinth into 2 parts :
   Scala vestibule : present above scala media ; opens into vestibule.
   Scala tympani : present below scala media.

Scala vestibule & scala tympani are connected through helicotrema.

Oval window

00:29:32

Oval window is a connection between middle ear and inner ear vestibule.

Function : conduction of sound.

Abnormalities :

1. Otosclerosis : Due to fixation of foot plate of stapes.
2. Vertigo : Due to dilation (as in meniere's), or hypermo bility (as in congenital syphilis) of utricle and saccule.

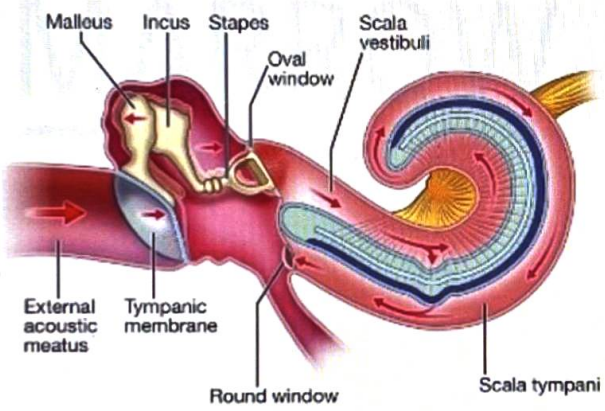

Round window

00:37:29

Connects middle ear to scala tympani (inner ear).

Covered by secondary tympanic membrane (very thin, 3 layered, tympanic membrane like structure).

Function : sound transmission.

60c6b3eeaa8ded0e4e7e5ea7

Clinical significance :

1. Cochlear implant :
   Electrodes passed through : Round window.
   Placed in : Scala tympani.
   Replaces : Organ of Corti.
   Stimulates : Cochlear nerve.
2. Drugs (like Gentamycin, steroids) are injected through round window.

Active space

Leave Feedba

Cochlear aqueduct 00:51:01

Connection between inner ear and brain.

Function : Responsible for transfer of CSF into inner ear, to form perilymph.

Inner ear is connected to brain via :

1. Cochlear aqueduct.
2. Internal acoustic meatus (passage for 7th & 8th cranial nerve).

Infections may spread from brain to inner ear or vice versa (meningitis ↔ labyrinthitis).

60c6b3eeaa8ded0e4e7e5ea7

Note : cochlear implant to be placed as early as 1 year of age. Therefore in a child with meningtis , hearing test is done to ensure the infection has not impaired the inner ear

Endolymphatic sac 01:06:37

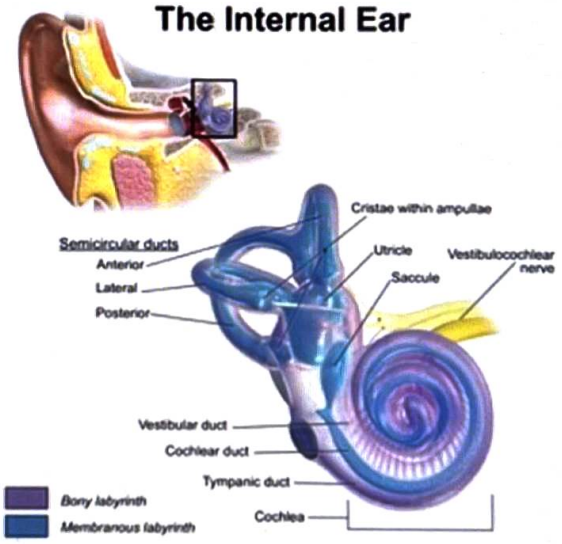

It lies intradural / in between 2 layers of dura (meningeal & endosteal layer of dura).

Congenital anomalies of inner ear 01:08:21

Inner ear develops in two parts :

Pars superior : development of 3 SCC and utricle.

Pars inferior : development of saccule and cochlea.

1. Michel aplasia : Total non-development of inner ear ;

Active space

Leave Feedba

contraindication for cochlear implant.

2. Alexander aplasia : Deformity of basal turn ; high frequency sound affected.
3. Mondini aplasia : cochlea has 1.5 turns only.
4. Scheibe aplasia : deformity of saccule & cochlea (most common).

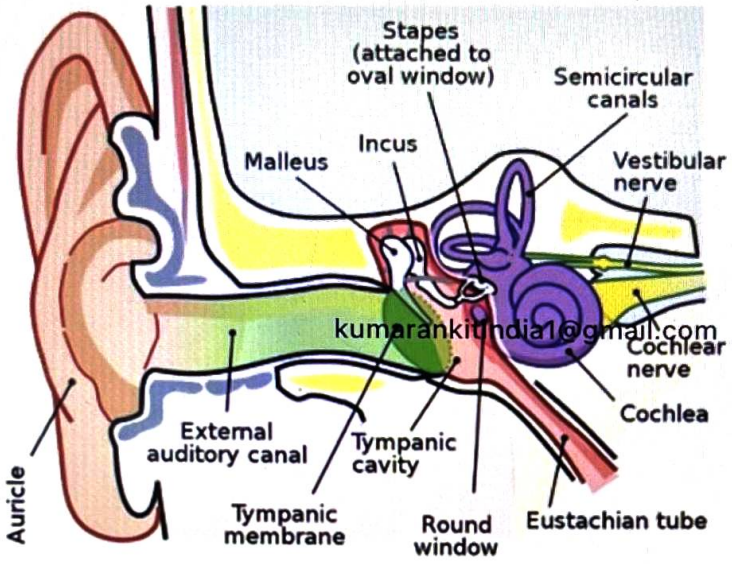

kumarankitindia1@gmail.com

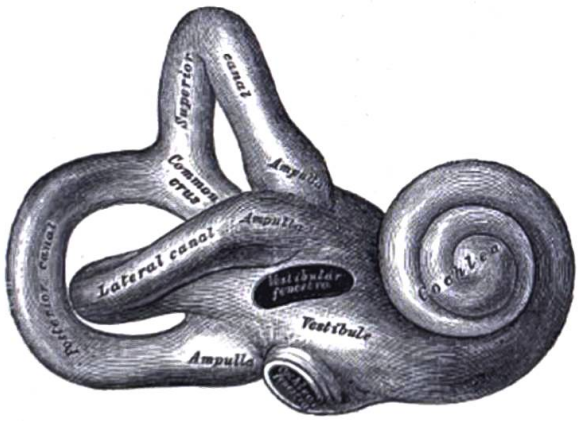

Active space

Leave Feedba

CLINICAL EMBRYOLOGY OF EXTERNAL AND MIDDLE EAR

Embryology

00:02:38

In the neck of the developing fetus develop 6 branchial arches are found out of which 5th disappears, leaving 5 branchial arches.

Each arch has an ectodermal lining on the outside and an endodermal lining on the inside.

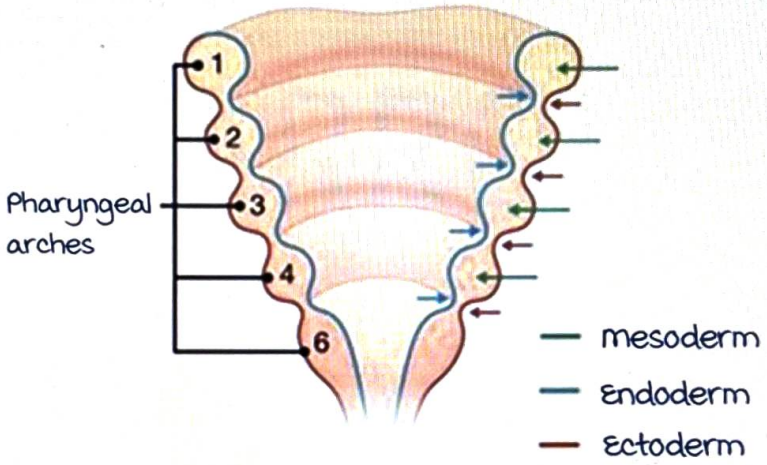

Ectodermal cleft :
The ectodermal lining on the outside dips to form the ectodermal cleft.
Endodermal pouch : The endodermal layer, dips inside forms a pouch.

Any structure developing from :

- Pouch – Endodermal.
- Cleft – Ectodermal.
- Arch – Mesodermal.

Hillocks of His 1st arch (1,2,3) & 2nd arch (4,5,6)

Around the first cleft, from the 1st and 2nd arches, the 6 mesodermal thickenings called as Hillocks of His develop.

Active space

The six hillocks from the 1st and 2nd arches fuse to form a single framework of cartilage called as the pinna.

Tragus and ascending crus of the helix develops from 1st arch.
Rest of pinna develops from the 2nd arch.

Developmental abnormalities

00:05:11

- Pre auricular Sinus :

  Any fusion defect of the auricular tubercules or Hillocks of His, can cause formation of sinus most commonly found just above the tragus anteriorly.
  Most Common site - At the root of helix.

- Pre auricular tags :

  Accessory appendages caused by fusion defects of Hillocks.

Pre auricular tags Pre auricular Sinus Microtia

- Anotia :

  Totally absent pinna.

- Microtia :

  Development of a small pinna.

To provide hearing rehabilitation to a patient with microtia or anotia (external deformities of the ear), Bone Anchored Hearing Aid (BAHA) is used.

Active space

Leave Feedba

Otoplasty/Pinnaplasty :
Cosmetic surgery also otoplasty/pinnaplasty, for the deformed ear is done in stages and not until the child reaches 6 – 7 years of age (till the rib cartilages can develop enough for Otoplasty).

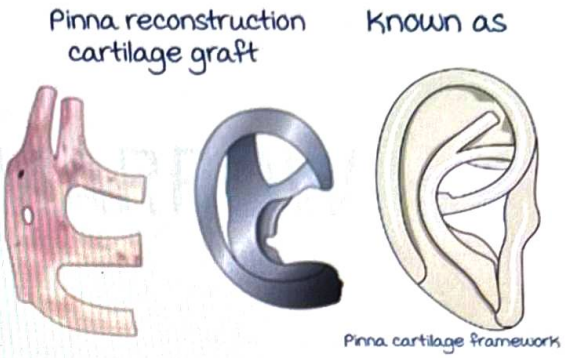

Cartilage used for implantation : Autologous rib cartilage.

External Auditory Canal/EAC

00:12:42

The medial growth of the 1st cleft results in the development of EAC.

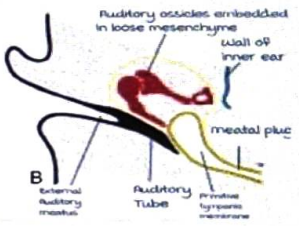

EAC is divided into –

- Cartilaginous part : Present at birth.
- Bony part : Not completely developed at birth.

External Auditory meatus develops from the 1st arch and not the 1st cleft.

Callaural fistula

Callaural fistula :
Abnormality of the 1st cleft.
Naturally the cleft regresses but if the cleft persists, it creates a communication between the neck and the EAC.

- External opening at : Angle of mandible, adjacent to sternocleidomastoid muscle.
- Internal opening at : Floor of the EAC.

Active space

Leave Feedbac

If the fistula causes pain, discomfort or discharge is found, excision surgery is indicated.

The cleft passes through parotid gland, therefore during surgery, the facial nerve passing through parotid gland is at risk. Hence, the fistula is in close proximity with facial nerve.

Middle ear

00:18:19

Develops from the 1st endodermal pouch. The pouch extends laterally towards the direction of the 1st cleft and creates a recess known as tubo tympanic recess.

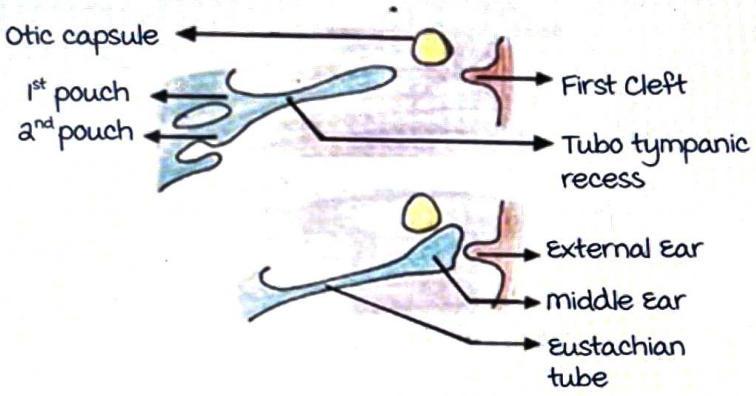

The tubo tympanic recess then develops to form the middle ear cleft (eustachian tube, middle ear cavity along with the mastoid antrum).

60c6b2eeaa8ded0e4e7e5ea7

middle ear cleft refers to middle ear cavity with ET (proximally) and mastoid antrum (distally).

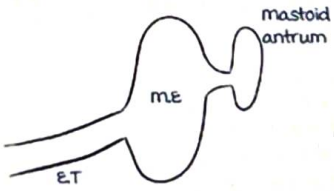

The middle ear cleft develops from the 1st pouch and not the 1st cleft.

When the 1st pouch develops to form the middle ear cleft, it also encompasses part of the mesoderm at 1st and 2nd arch and results in the formation of the ossicles.

- 1st arch : malleus and Incus.
- 2nd arch : Stapes suprastructure only, (i.e., the head, neck, 2 crura and not the footplate).

The footplate develops from the bony labyrinth/ottic capsule.

Tympanic membrane :

Active space

Leave Feedba

The cleft develops medially and pouch laterally, and the junction formed by them results in tympanic membrane.

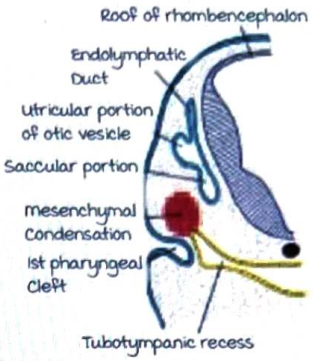

Tympanic membrane has 3 embryonic layers :

- Outer : Ectoderm
- Middle : Mesoderm
- Inner : Endoderm

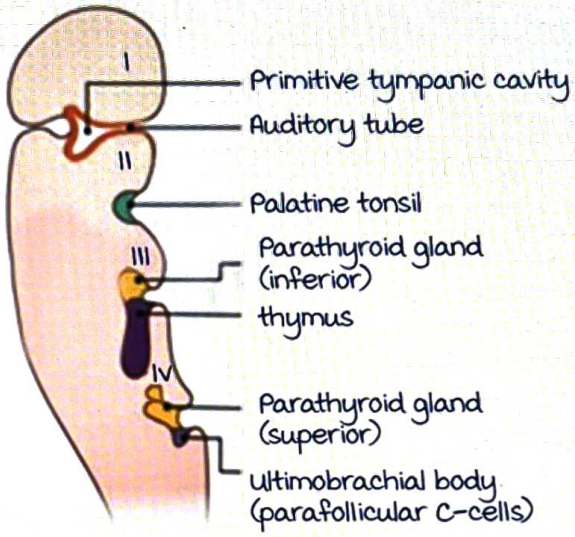

Mastoid

00:25:56

Superficially formed by squamous part of the temporal bone. Petrous part of temporal bone forms the deep part of mastoid.

The junction between the two forms the petro squamosal suture/ Korner's septum.

The largest air cells are found in the petrous part and are called as mastoid antrum.

Squamous part > Korner's septum > mastoid antrum > medial wall of mastoid antrum leading to posterior cranial fossa.

60c6b3eeaa8ded0e4e7e5ea7

Korner's septum is significant as

Active space

Leave Feedbac

it can be confused as the medial wall of the mastoid antrum and it holds back the surgeon from entering the mastoid antrum, resulting in incomplete clearance of disease.

kumarankitindia1@gmail.com

The mastoid tip develops at 2 years of age.

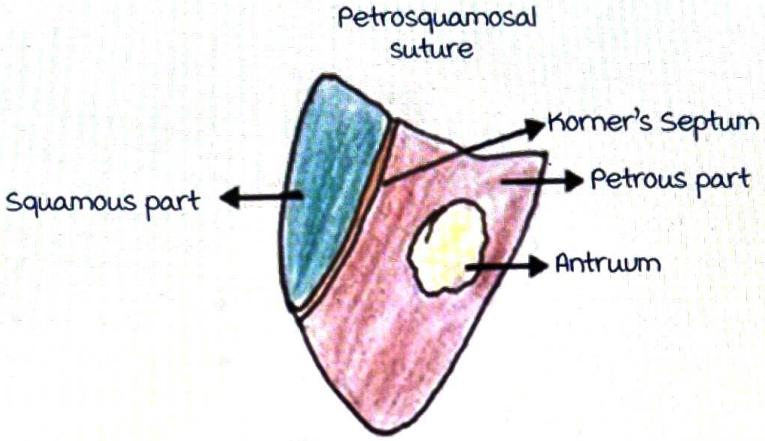

The inner ear and middle ear are well developed at birth. The organ of corti completely develops at 20 weeks of gestation and can hear during IUL.

The bony EAC is not developed at birth, only the cartilaginous EAC (therefore short EAC), resulting in a much easier access to tympanic membrane, therefore high risk of injury.

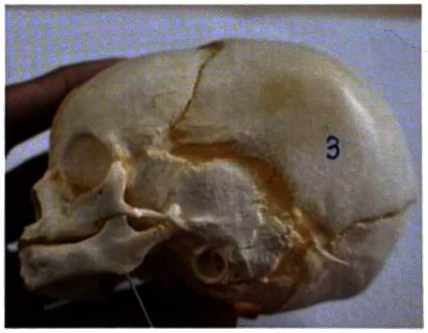

Mastoid tip develops at 2 years of age because of the pull of

Mastoid tip

Active space

Leave Feedba

posterior belly of digastric and sternocleidomastoid muscles attached to the mastoid.

The stylomastoid foramen present below the mastoid tip is where the facial nerve exits.
Therefore, the mastoid tip protects the foramen and hence the facial nerve after 2 years of age.
For a post auricular abscess in a child < 2 years of age, a horizontal superior incision is done than a vertical inferior incision.

Active space

60c6b3eeaa8ded0e4e7e5ea7

Leave Feedba

CLINICAL ANATOMY OF EXTERNAL EAR

Anatomy of pinna

00:01:48

Develops from 1st & 2nd pharyngeal arch. 60c6b3eeaa8ded0e4e7e5ea7

- Tragus → 1st arch.
- Rest → 2nd arch.

Parts of pinna :

- Lobule → Only fat present, no cartilage.
- Cymba concha → Cartilaginous landmark for mastoid antrum.
- macewen's triangle Bony landmark for mastoid antrum.
  Superior → Dural plate (separates mastoid from middle cranial fossa).
  Posterior → Sinus plate.
  Inferior → Mastoid tip and facial nerve.
  Therefore, landmarks are important to prevent damage to these structures.

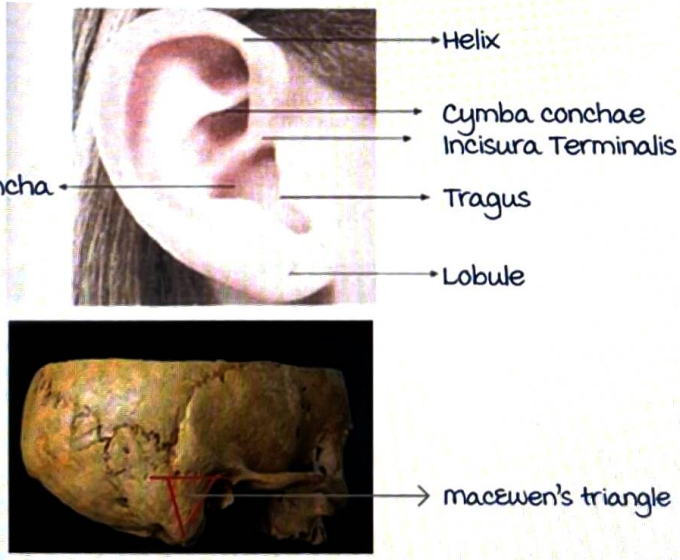

1. Post aural incision (Wilde's incision) → Pinna retracted forward → No hindrance.

2. Endaural incision : Area between tragus and helix → No cartilage → Incision site (Incisura terminalis) → Widens external auditory meatus → Easy for smaller surgeries.

Active space

Leave Feedba

Skin on lateral surface of pinna is tightly attached to underlying perichondrium.

Any scratch → Infection → Perichondritis.

Any trauma → Perichondreal leakage of blood → Hematoma of the pinna.

- Hematoma/perichondritis more common : Lateral surface of pinna.
- This region is very sensitive to temperature changes/ pressure changes.

Therefore, piercing are never recommended in the cartilaginous part.

60c6b3eeaa8ded0e4e7e5ea7

Macewen's (suprameatal) triangle

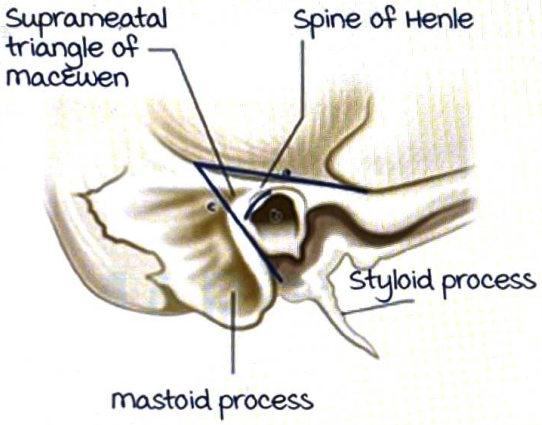

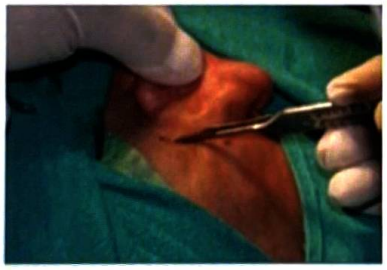

Peri-aural incision

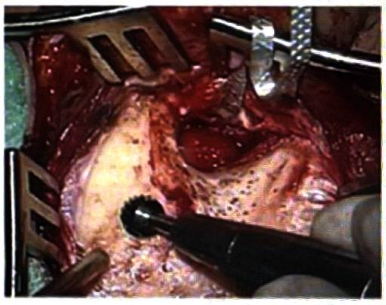

Endaural incision

Darwin's tubercle

00:15:36

Variation in anatomy.

Projection at junction of upper 1/3rd and lower 2/3rd of helix.

Personal identification mark.

Active space

Darwin's tubercle

Anatomy of external auditory canal 00:18:14

Develops from 1st cleft.

Cartilaginous part of EAC → Present at birth.

Lateral (outer) 1/3rd part → Cartilaginous.

Inner 2/3rd part → Bony.

Length → 8 mm (outer) + 16 mm (inner) = 24 mm.

Function → Transmission of sound from outside to inside.

Cartilaginous part :

- Lining epithelium same as outside.
- Skin is thick.
- Contains all appendages (hair follicles, sweat and sebaceous glands, ceruminous glands).
- Lined by stratified squamous epithelium (thick in cartilage, thin in bony part).
- Ceruminous glands → Produce wax (only produced from cartilaginous part).

Fissures of Santorini :

- Present at anterior wall, towards floor.
- Infection from EAC through floor can reach base of skull (otitis externs → Skull base osteomyelitis).
- Infection from EAC → Involves soft tissue structures → Parotid involved → Parotitis.

kumarankitindia1@gmail.com

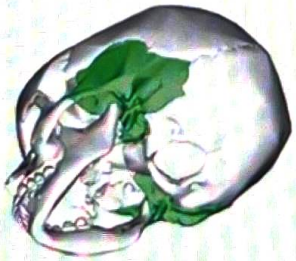

Skull base

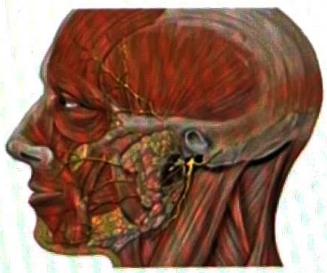

Parotid

Active space

Leave Feedba

Narrowest part of EAC : Isthmus (deep inside).

- 5 to 6 mm lateral to tympanic membrane.
- Any foreign body goes medial to isthmus → Impaction → Difficult to remove.

Beyond isthmus, in bony part, a dilatation in the floor is present called as Meatal recess (any pus from middle here can collect here).

Foramen of Huschke : During development,
Openings are present in the floor of bony part.

- Any infection → Base of skull or parotid.

Fissures of Santorini in cartilaginous part = Foramen of Huschke in bony part.

EAC directions :
S-shaped (not a straight line).
Cartilaginous part : Upwards, backwards and medially.
Bony part : Downwards, forwards and medially.

- Pull the pinna postero-superiorly to see the tympanic membrane.

Anatomy of tympanic membrane 00:35:05

Develops from all 3 germ layers.
Can be affected in any conditions in both external and middle ear.
Central part of tympanic membrane, where it is dented inside → Umbo.
Tympanic membrane is at an angle of 55 degrees from the horizontal surface.
It comprises of 2 parts :

1. Lower 2/3rd : Fibrous layer is very well developed → Has a fibrous annulus (thick rim) → Tightly fits into tympanic depression (tympanic sulcus) → Thus called pars tensa.

60c6b3eeaa8ded0e4e7e5ea7

Centre → Tympanic membrane attached to umbo.
Periphery → Tightly fixed to sulcus (Mobility : Peripheral > central).

Active space

Leave Feedba

Paramedian part : most mobile.

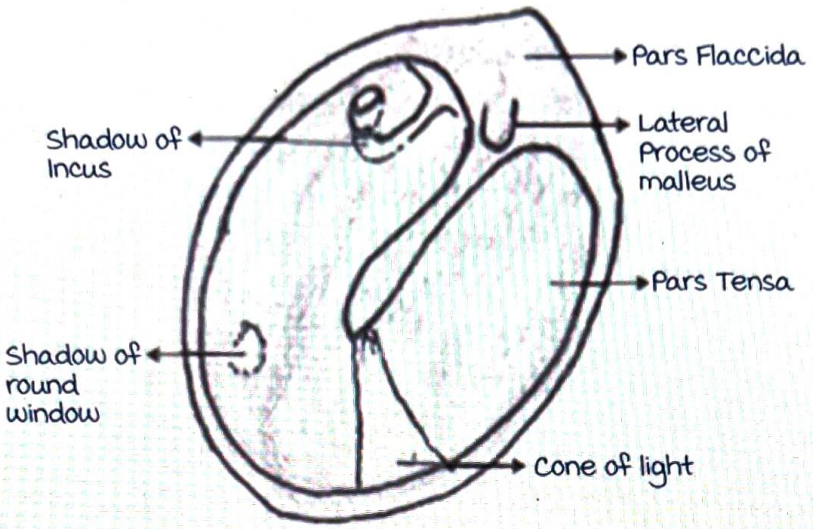

2. Upper 1/3rd → No tympanic annulus → Notch of Rivinus → Very mobile and flaccid → Pars flaccida (Shrapnell's membrane).
   Retraction pocket more commonly seen in upper 1/3rd (Pars flaccida).

Anatomical surface area of tympanic membrane : 10 mm width, 9 mm length and 0.1 mm in thickness.
Total surface area : 90 mm^2.
Effective, vibratory surface area : 55 m^2.

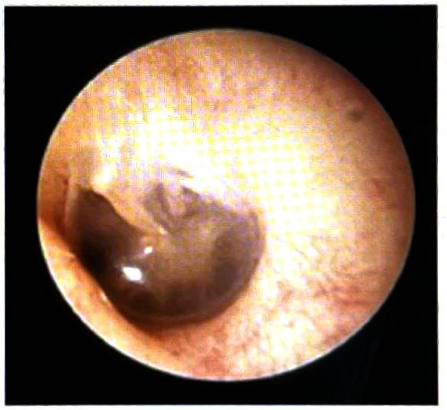

Handle of malleus directed towards left → Left TM.

Lateral process of malleus :
Projection of malleus on tympanic membrane.
From umbo, in antero-inferior quadrant, cone of light is seen (obliquity of tympanic membrane → Reflection of malleus).

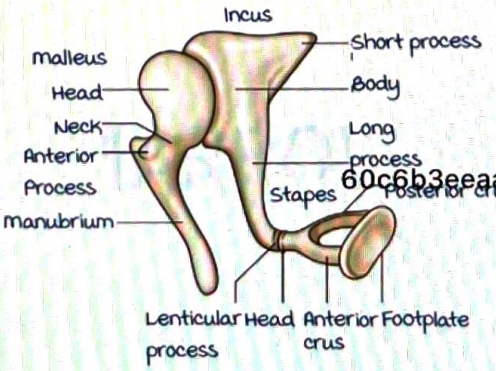

60c6b3eeaa8ded0e4e7e5ea7

Leave Feedba

Pearly white/pearly grey in color. Translucent.

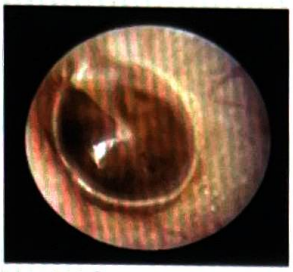

Handle of malleus directed towards left → Left TM.

Handle of malleus directed towards right → Right TM.

Normal color of tympanic membrane : Pearly white/grey and is translucent.

Direction of handle of malleus : Determines whether it is right or left tympanic membrane.

Direction of handle of malleus : Anterior part of tympanic membrane.

kumarankitindia1@gmail.com

Active space

Leave Feedba

CLINICAL ANATOMY OF MIDDLE EAR : PART 1

Introduction

00:01:18

Middle ear → 6 box cavity (floor, roof, anterior wall, posterior wall, lateral wall and medial wall).

Medial wall → Common wall between middle & inner ear.

Anterior wall → Common wall between middle ear & pharynx.

Eustachian tube :

- Connects middle ear with pharynx.
- Present on the anterior wall.

Facial nerve → Passes through the anterior wall of middle ear and supplies the tongue.

Posterior wall →

- Common wall between the middle & mastoid.
- After disease eradication in mastoid, route of entry into middle ear is through posterior wall (mastoid surgeries).

Tympanic membrane :

- Common wall b/w middle ear & external auditory canal.
- Lateral wall of middle ear.
- Develops from all the 3 germ layers.
- Colour : Pearly white/grey, translucent.
- Angle with horizontal is 55°.
- Surface area : 90 mm^2.
- Effective vibratory surface area : 55 mm^2.
- Thickness : 0.1 mm.
- Umbo : Tip of handle of malleus.
- Cone of light : Anteroinferior quadrant.
- Most mobile : Pars flaccida.
- Most mobile part of pars tensa : Paramedian/periphery.
- Side :

Upper end of malleus facing right → Right TM.

Upper end of malleus facing left → Left TM.

60c6b3eeaa8ded0e4e7e5ea7

Active space

Leave Feedbac

Medial wall of the middle ear

00:06:20

Common wall between the middle and inner ear.
Structures on the medial wall :

- Promontory : It is the bulge on medial wall by basal turn of cochlea (senses high frequency sounds).

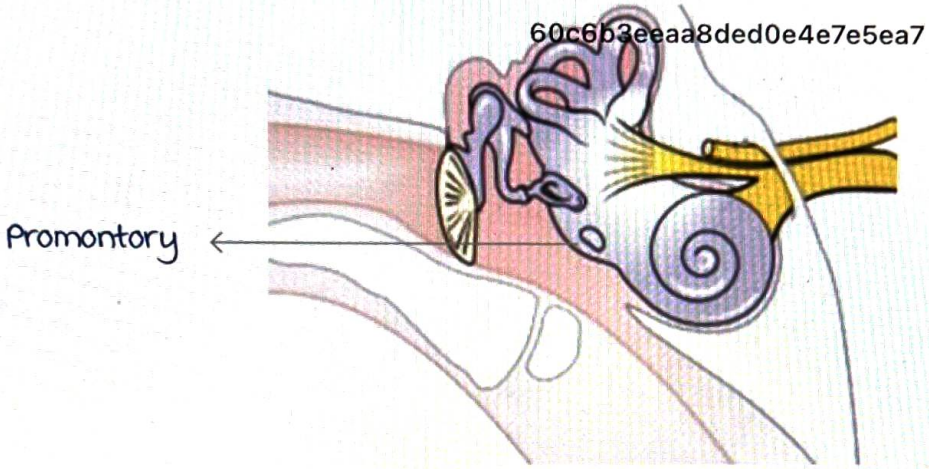

- Oval window : Foot plate of stapes gets attached.
- Round window :
  Secondary tympanic membrane (scala tympani).
  Electrodes of cochlear implants are passed through it.
- Lateral semicircular canal :
  Eroded m/c due to diseases of middle ear.
  Calorie test stimulates it.
- Processus cochleariformis :
  Tensor tympani tendon winds around it, turns laterally and attaches to the upper end of handle of malleus.
- Tensor tympani :
  Supplied by mandibular nerve.
  Tenses the tympanic membrane, stiffens the ossicular chain and hinders the sound from mastication.
- Facial nerve :
  Takes a turn (genu) and runs horizontally on the medial wall (horizontal segment /tympanic segment).

Landmarks of tympanic segment of facial nerve :

- Ist genu of facial nerve (geniculate ganglion) is just superior to the processes cochleariformis.

Active space

Leave Feedba

- Superior to the oval window.
- Inferior to the bulge of the lateral semicircular canal.

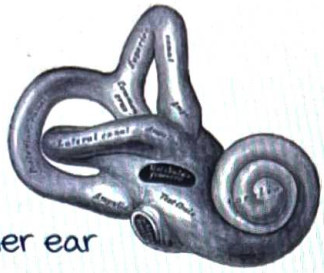

Inner ear

Endoscopic image of medial wall of right middle ear :

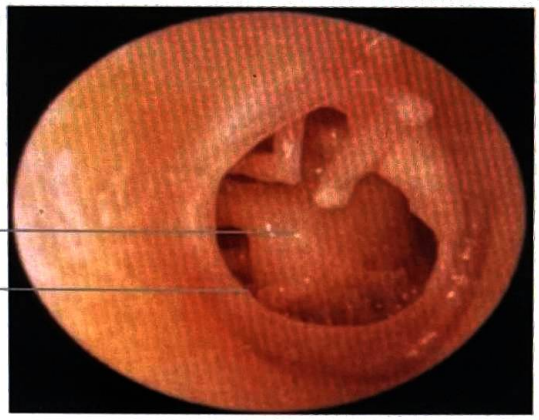

Posterior wall of middle ear

00:23:04

- Common wall between the middle and mastoid.
- Aditus : Connects attic or epitympanum (uppermost part of middle ear cavity) to the mastoid antrum.
- Facial nerve runs vertically down along the posterior wall (vertical /mastoid segment).
  m/c injured during mastoid surgeries.
- Chorda tympani passes from posterior to the anterior wall just above the attachment of tensor tympani and innervates anterior $(2/3)^{rd}$ of tongue.
- Opening for entry of chorda tympani is present in the po terior wall of tympanic membrane.
- Fossa incudis :
  Produced by the short process of incus.
  Forms one of the boundaries of facial recess area.

kumarankitindia1@gmail.com

Active space

Leave Feedba

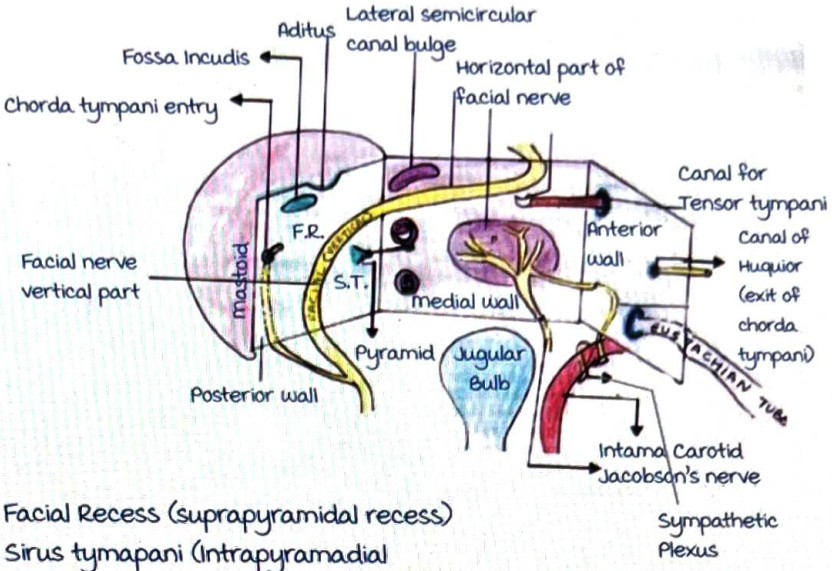

F.R. : Facial Recess (suprapyramidal recess)
S.T. : Sirus tymapani (Intrapyramadial recess)
P : Promontory
O.W. : Oval Window
R.W. : Round Window

Facial recess area/suprapyramidal recess :

Boundaries :

Medial : Vertical segment of facial nerve.

Lateral : Chorda tympani

60b6b3eeaa8ed0e4e7e5ea7

Superior : Fossa incudis.

Significance :

1. The electrodes of the cochlear implants are passed through this are from posterior to medial wall.
2. Opening to remove the limited disease in the middle ear after clearing mastoid (posterior tympanotomy).

When we raise the tympanic membrane : Only bulge of fallopian canal (bony canal of facial nerve) is seen running horizontally and vertically.

Sinus tympani area /hidden layer /infrapyramidal recess : m/c site of residual disease of cholesteatoma. Present behind the vertical segment of facial nerve canal.

Crests of bone behind the vertical segment of facial nerve :
(mnemonic : Police Station)
Upper : Ponticulus.
Lower : Subiculum.

Active space

Leave Feedba

Pyramid : Attachment of stapedius (protects inner ear from noise trauma : Stapedial reflex).
Stapedius is supplied by facial nerve.
Stapedial reflex : Both 8th (afferent) and 7th nerve (efferent).

Ear ossicles

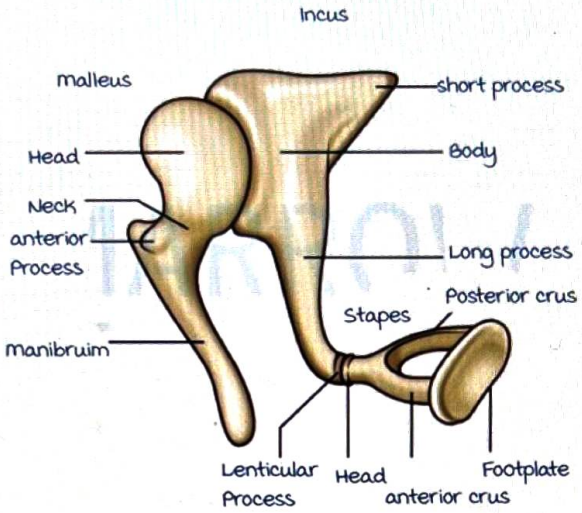

Lateral process of malleus : Projection on tympanic membrane.

Type of joint between malleus and incus : Saddle joint.
Type of joint between stapes and incus : Ball & socket joint.

Malleus and incus are in vertical orientation.
Stapes is present in the horizontal orientation.

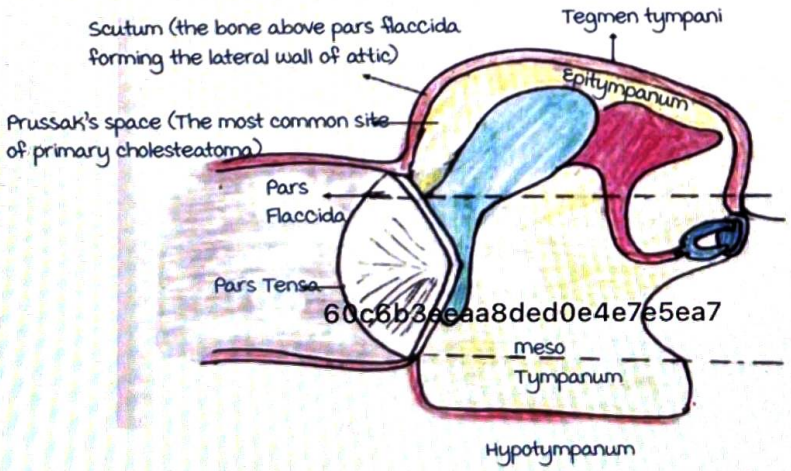

60c6b3eeaa8ded0e4e7e5ea7

Active space

Leave Feedba

Anatomy of the ear :

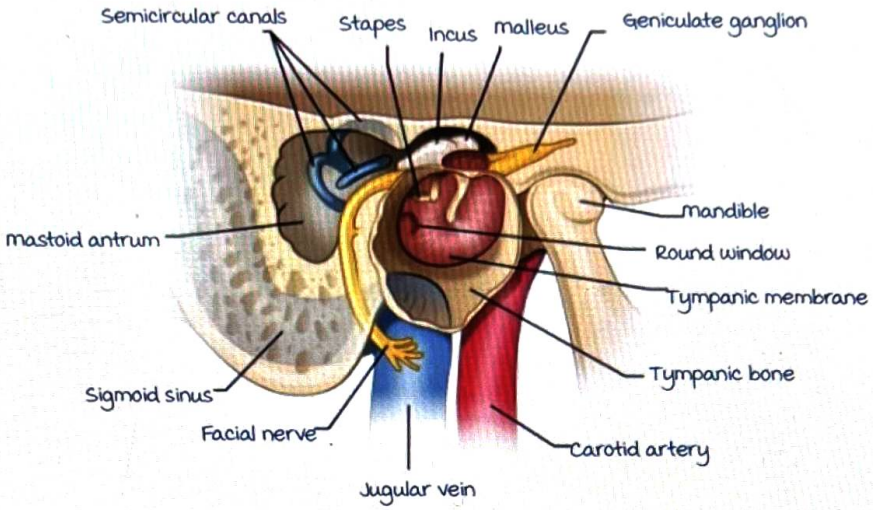

kumarankitindia1@gmail.com

Mastoid forms the common posterior wall for both middle ear and external auditory canal.

Close up view of the facial recess area :

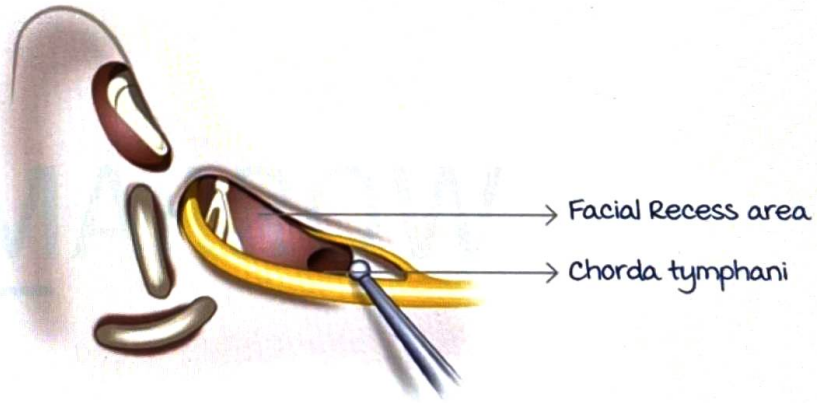

Active space

Leave Feedba

Round window

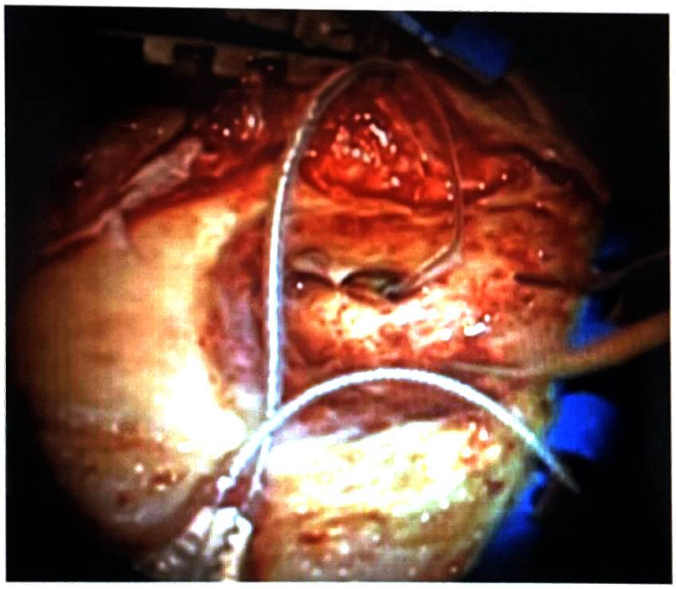

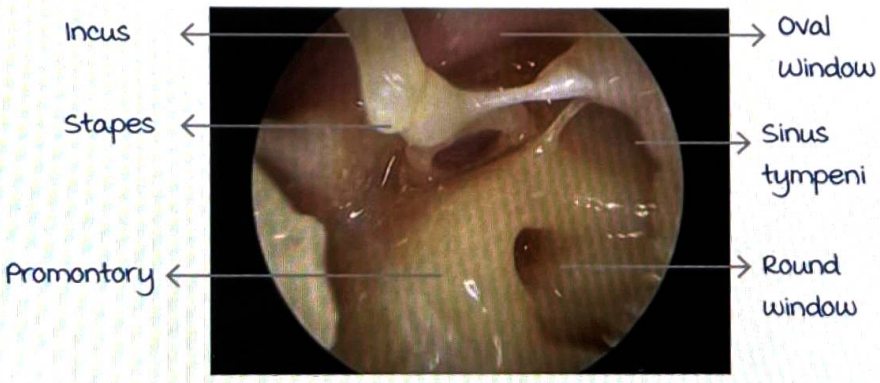

Active space

Leave Feedbac

CLINICAL ANATOMY OF MIDDLE EAR : PART 2

Anterior wall (carotid wall) of the middle ear 00:02:24

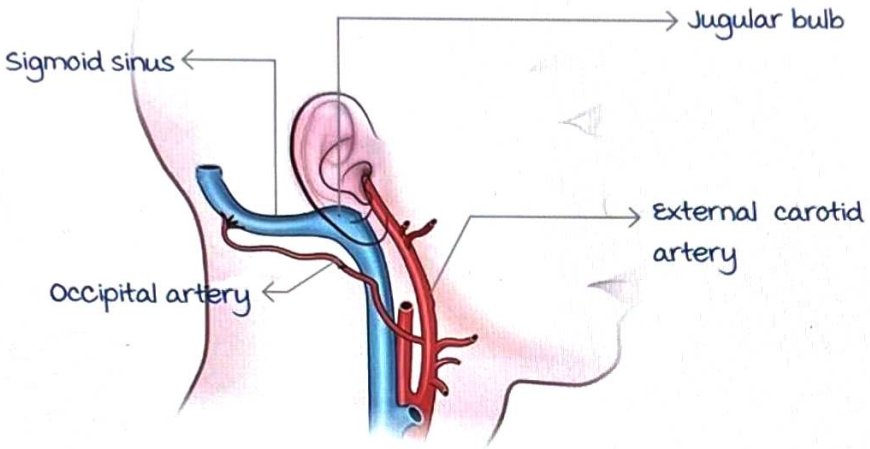

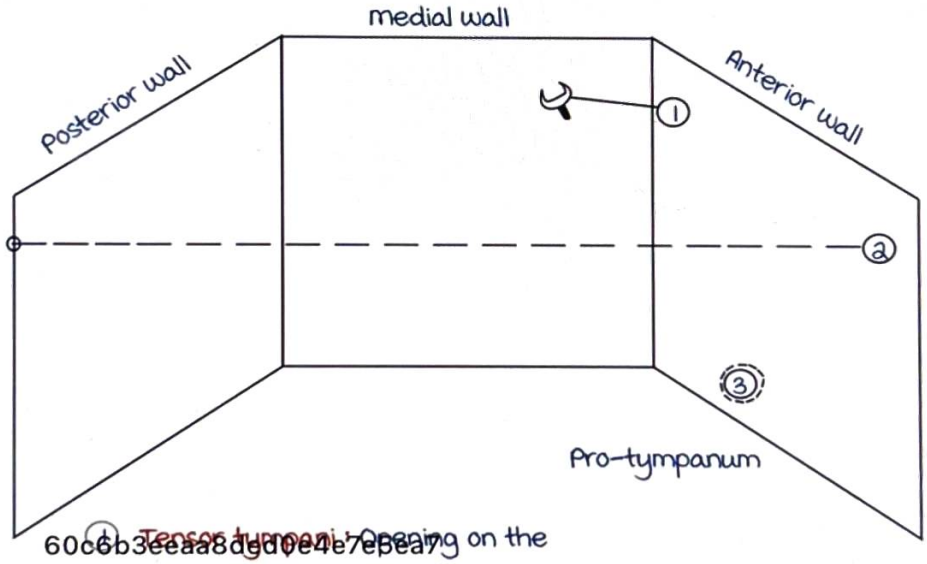

60c6b3eeaa8dgd0e4e7ebea7

① Tensor tympani : Opening on the anterior wall attach to upper end of handle of malleus.

② Chord tympani exit : Canal of Huguier. Goes to anterior $^{2}/_{3}^{rd}$ of tongue (for taste).

③ Eustachian tube : (ET)
Protympanum : Area of anterior wall around ET orifice

Active space

Leave Feedba

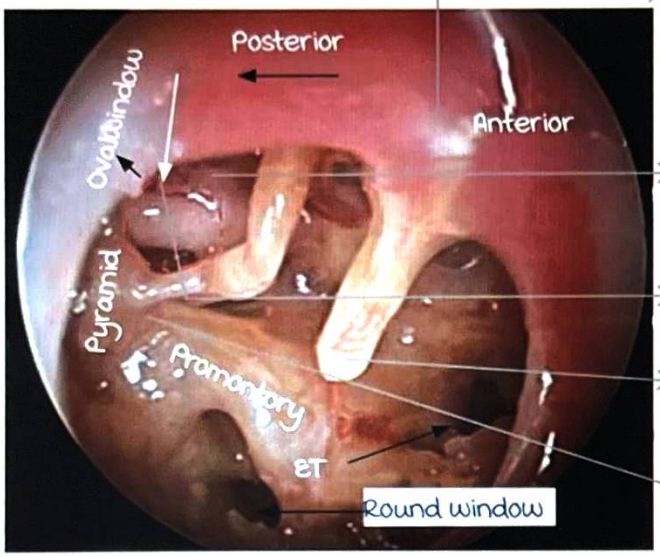

Roof of the middle ear/ Tegmen tympani :

- It is present on the anterior slant of petrous part of temporal bone.
- Any infection of middle ear through tegmen tympani goes superiorly to involve middle cranial fossa (temporal lobe).
- Roof and floor of the middle ear are in the base of skull.

60c6b3eeaa8ded0e4e7e5ea7

Cog :

- It comes up to the level of processus cochleariformis from the roof of the middle ear
- It also acts as a landmark for geniculate ganglion (1st Genu).

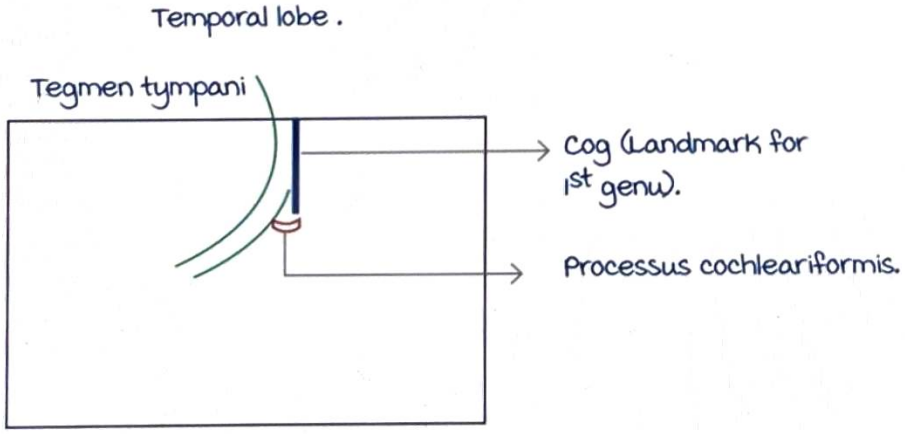

Active space

Leave Feedba

Floor of the middle ear

00:12:06

- Glossopharyngeal nerve (IX) enters middle ear through the floor and forms tympanic plexus on the promontory.
- Tympanic plexus : Sensory supply to the middle ear.
- It also gives pharyngeal branches that supply tonsils and base of the tongue.
- In case of tonsillitis/ carcinoma base of the tongue : Referred pain in the middle ear, due to involvement of cranial nerve IX.

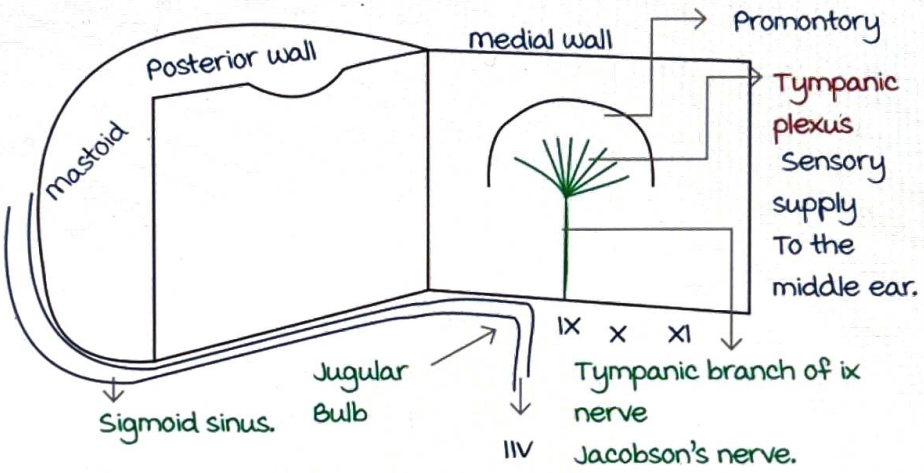

Nerves in the middle ear : Chorda tympani, facial nerve, glossopharyngeal nerve.

Muscles in the middle ear : Tensor tympani, stapedius.

60c6b3eeaa8ded0e4e7e5ea7

Cavities of the middle ear :

Cavities of middle ear is divided into 3 parts by 2 lines (upper line through upper part of pars tensa & lower line through lower part of pars tensa) :

1. Epitympanum/ Attic.
2. Mesotympanum (Assesed via pars tensa).
3. Hypotympanum.

Active space

Leave Feedba

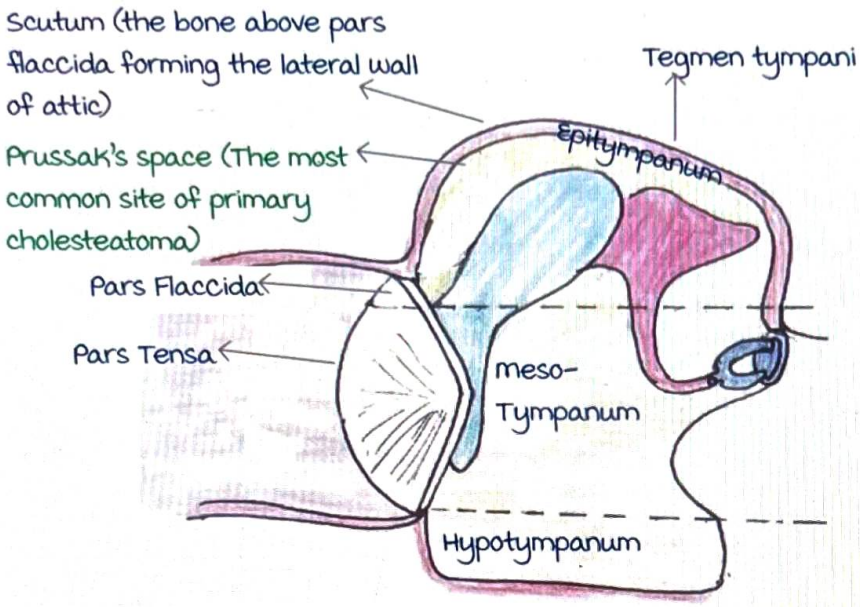

Pars flaccida forms the lateral part of epitympanum only in the lower part. The rest upper part of epitympanum in the lateral wall is bony & is called Scutum.

The space of middle ear next to (medial to) Pars flaccida : most common site of retraction pockets & is called Prussak's space.

kumarankitindia1@gmail.com

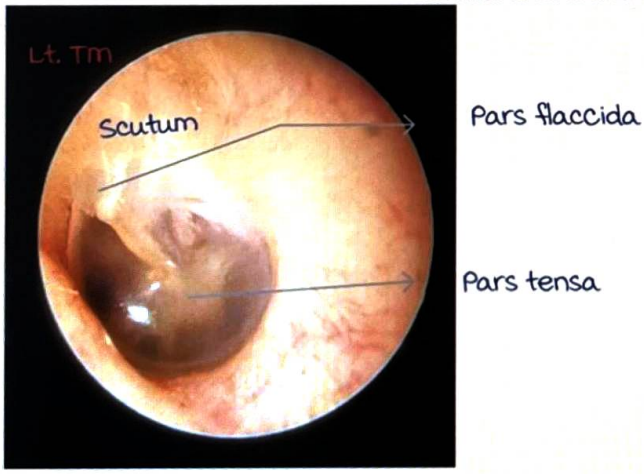

Boundaries of Prussak's space :

Medial → Neck of malleus.

Lateral → Pars flaccida.

Inferior → Lateral process of malleus

Active space

Leave Feedbac

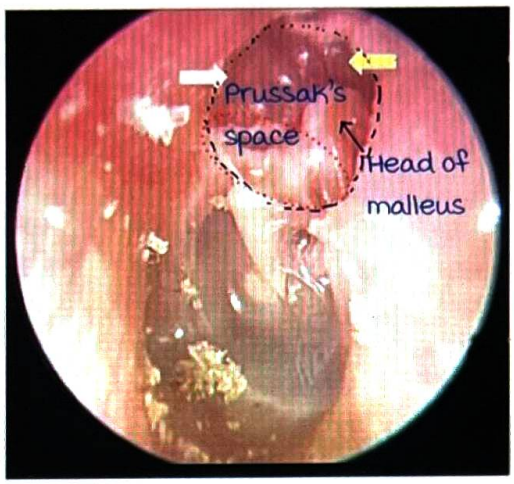

Erosion of scutum

Pars tensa

Note :

Narrowest part of middle ear cavity : meso tympanum (2 mm).

Smallest part of the middle ear cavity : Hypotympanum.

Widest/Largest : Epitympanum (6 mm).

Endoscopic anatomy of the middle ear cavity

00:28:42

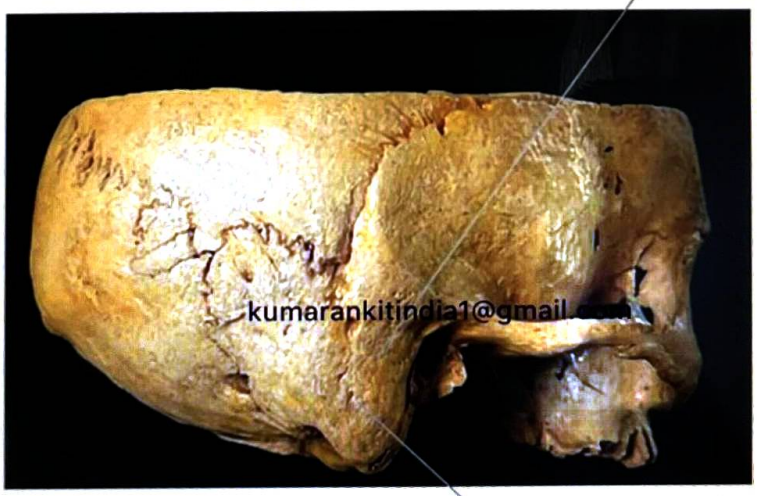

kumarankitindia1@gmail.com

Active space

Leave Feedba

Macewen's/ Suprameatal triangle : Boundaries :

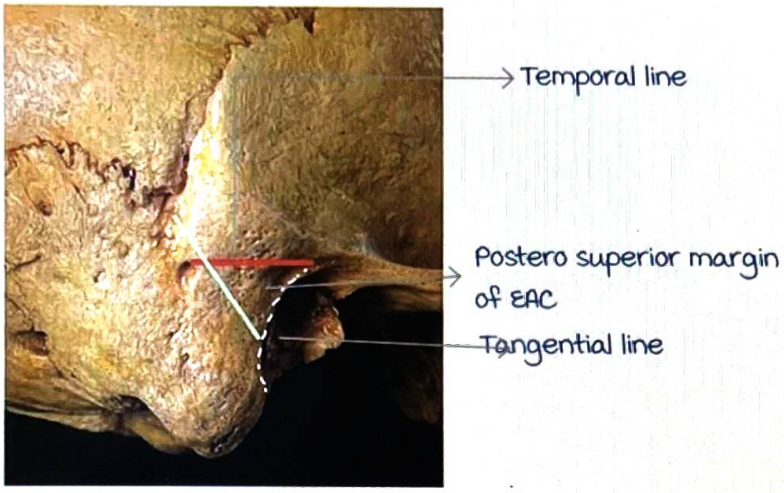

Macewen's (suprameatal) triangle

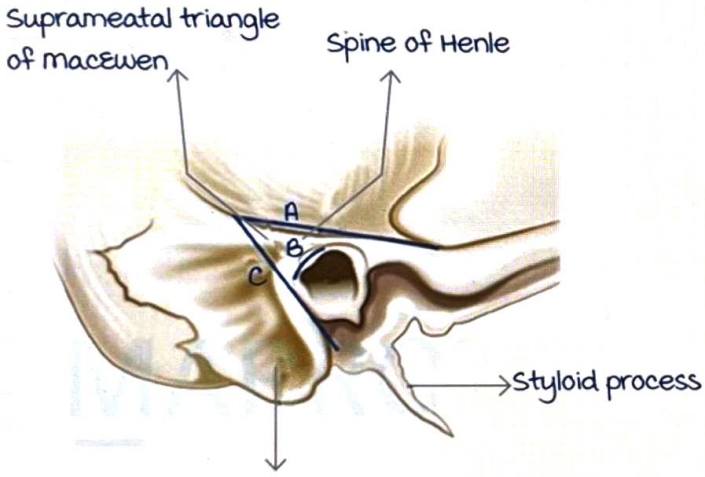

The triangle is bounded by temporal line (A), posterosuperior segment of bony external auditory canal (B), and the line drawn as a tangent to the external canal (C).

Superiorly → Temporal line.

Anteriorly → Postero superior margin of external auditory canal bony part.

60c6b3eeaa8ded0e4e7e5ea7

Inferiorly → Tangent from posterior margin of EAC and cutting the temporal line.

Spine of Henle is a landmark for Macewen's triangle as the triangle lies behind spine of Henle.

Active space

Leave Feedba

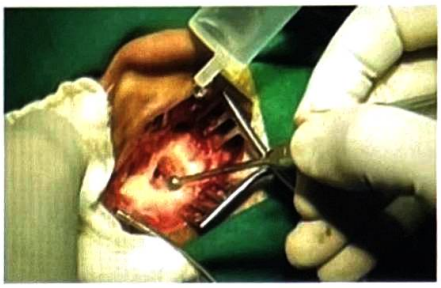

Sinodural angle/ angle of Citelli's

00:36:32

Angle between Dural plate and sinus plate also known as Citelli's angle

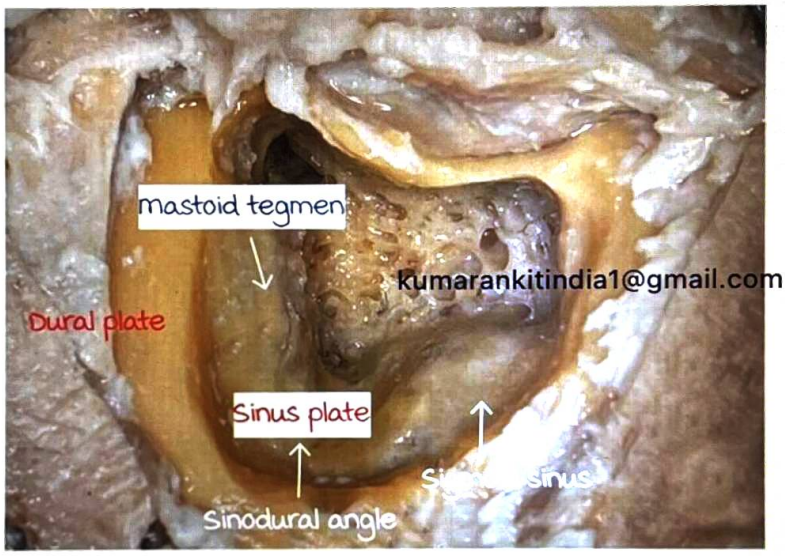

kumarankitindia1@gmail.com

Anatomy of the ear : Lateral view

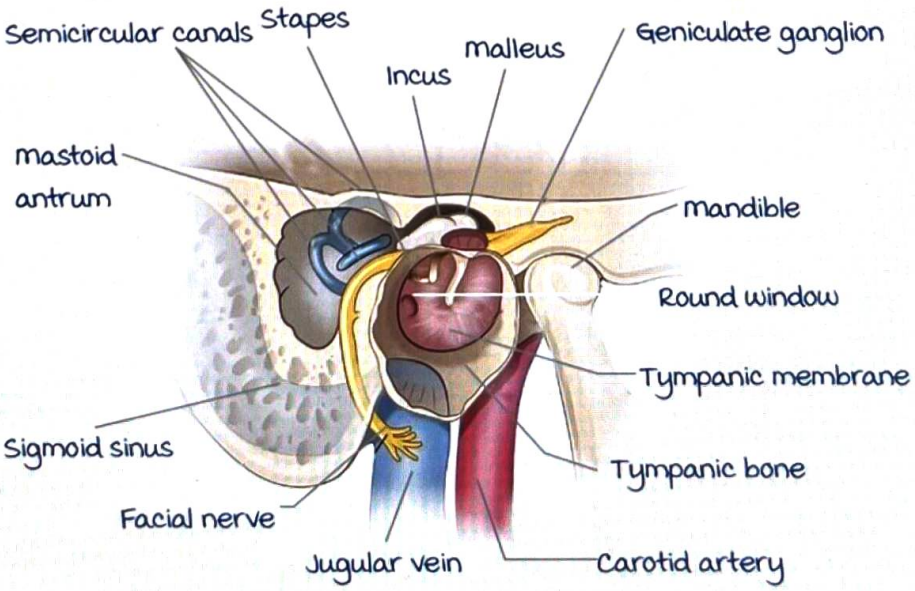

Active space

Leave Feedbac

- Posterior wall of the EAC is the common wall between the EAC and mastoid. Posterior wall of the middle ear is also the common wall between the middle ear and mastoid.
- Part of the semicircular canal project on the medial most wall of the mastoid antrum : Posterior canal (closest to the mastoid).
- Semicircular canals are present towards the mastoid.

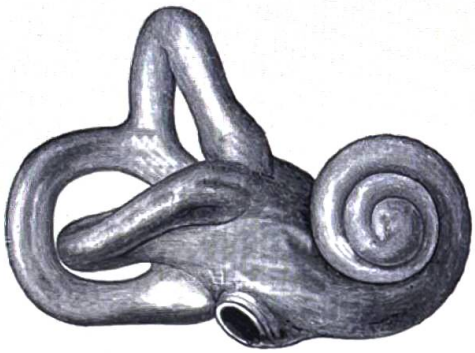

Semicircular canal (Right ear)

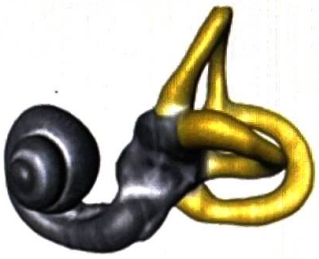

Semicircular canal (Left ear)

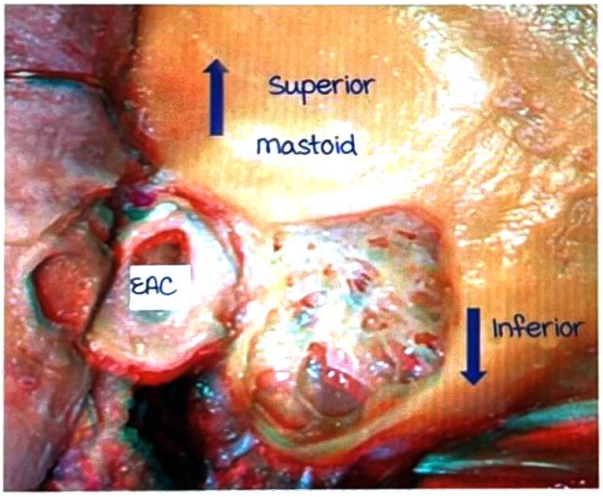

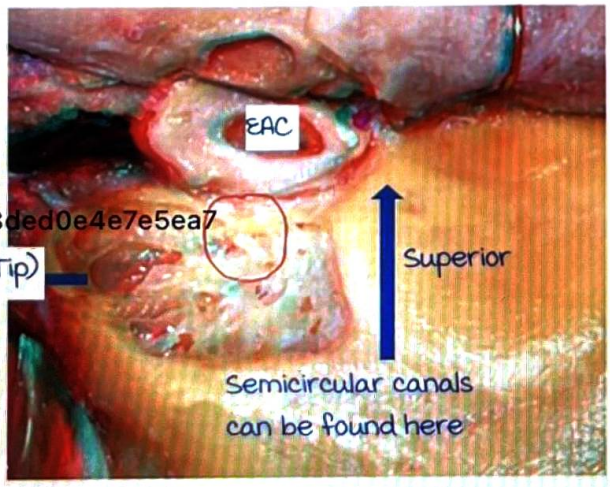

60c6b3eeaa8ded0e4e7e5ea7

Active space

Leave Feedback

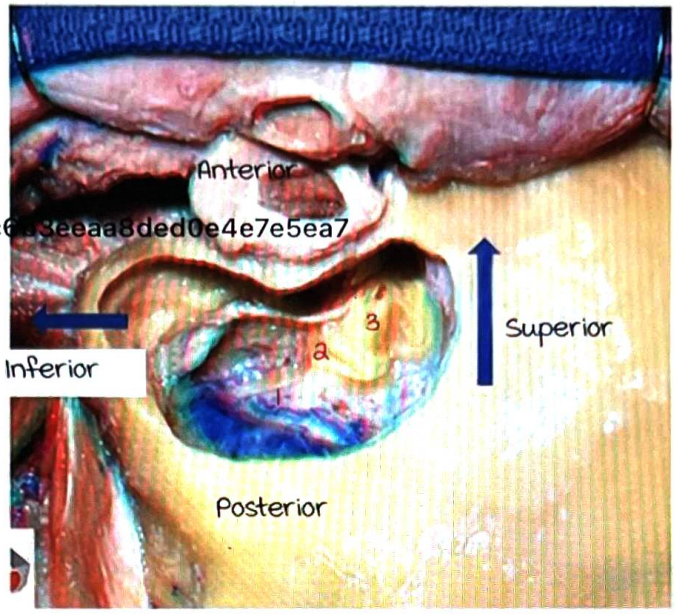

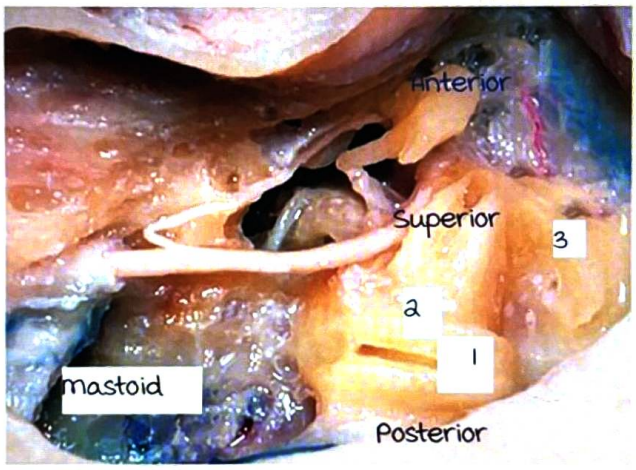

1. Posterior Semicircular canal
2. Lateral Semicircular canal
3. Superior Semicircular canal

Donaldson's line

00:50:29

- It is an imaginary line from lateral semicircular canal to posterior semicircular canal.
- Endolymphatic sac lies below it.
- Endolymphatic sac lies intradurally (over the Dura) of the posterior cranial fossa.

Active space

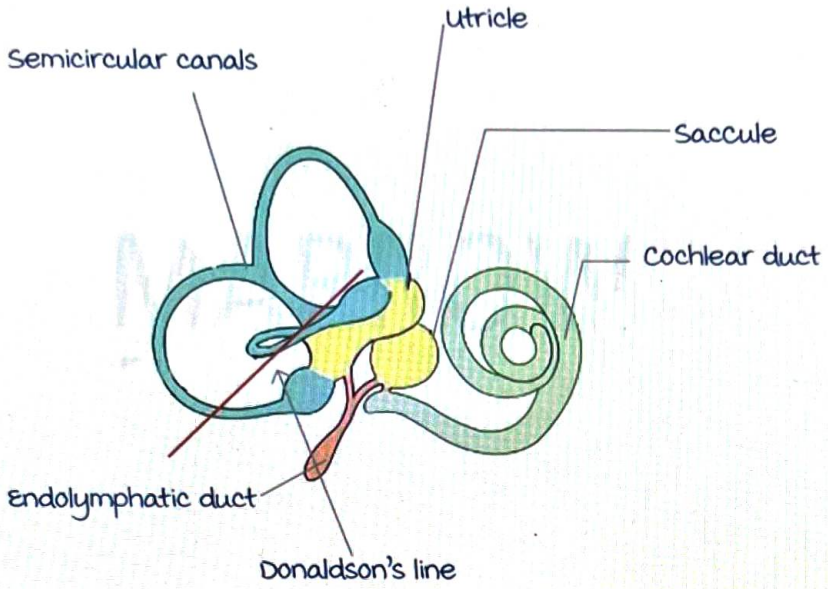

- It is an imaginary line from lateral semicircular canal to posterior semicular canal.
- Endolymphatic sac lies below it.
- Endolymphatic sac lies intradurally (over the Dura) of the posterior cranial fossa.

60c6b3eeaa8ded0e4e7e5ea7

When the mastoid is drilled, the structures that can be approached are middle ear, inner ear, endolymphatic sac & posterior cranial fossa.

When the tumor has to be removed from the posterior cranial fossa, it is better to approach above the Donaldson's line. (Because just below it, endolymphatic sac present. If it is damaged, inner ear will be affected).

Trautmann's triangle 00:56:08

It is the area on the medial wall of mastoid antrum through which we can enter into the posterior cranial fossa.
Boundaries Trautmann's triangle :
Posteriorly → Sigmoid sinus.
Superiorly → Superior petrosal sinus (tributary of sigmoid sinus).
Anteriorly → Inner ear/ Bony labyrinth.

Active space

Leave Feedba

Trautmann's triangle

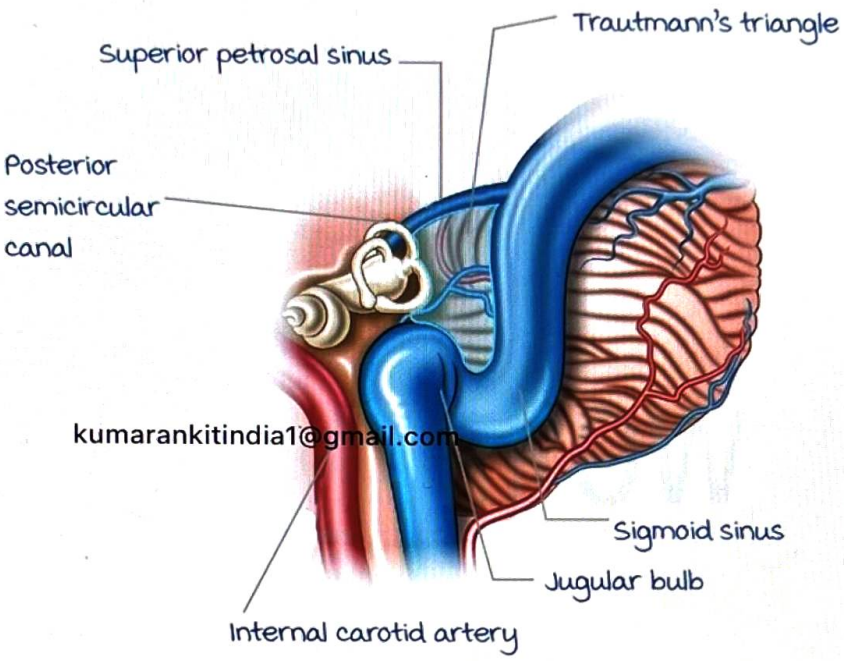

kumarankitindia1@gmail.com

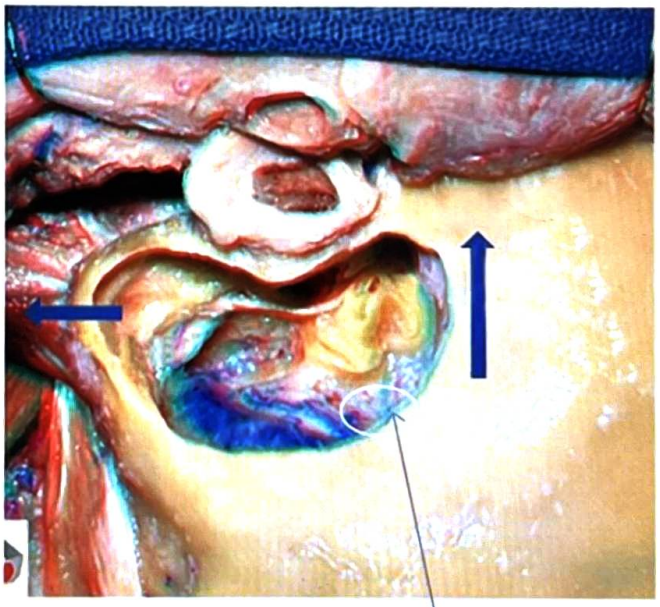

Active space

CLINICAL ANATOMY OF INNER EAR

60c6b3eeaa8ded0e4e7e5ea7

Organ of Corti

00:01:12

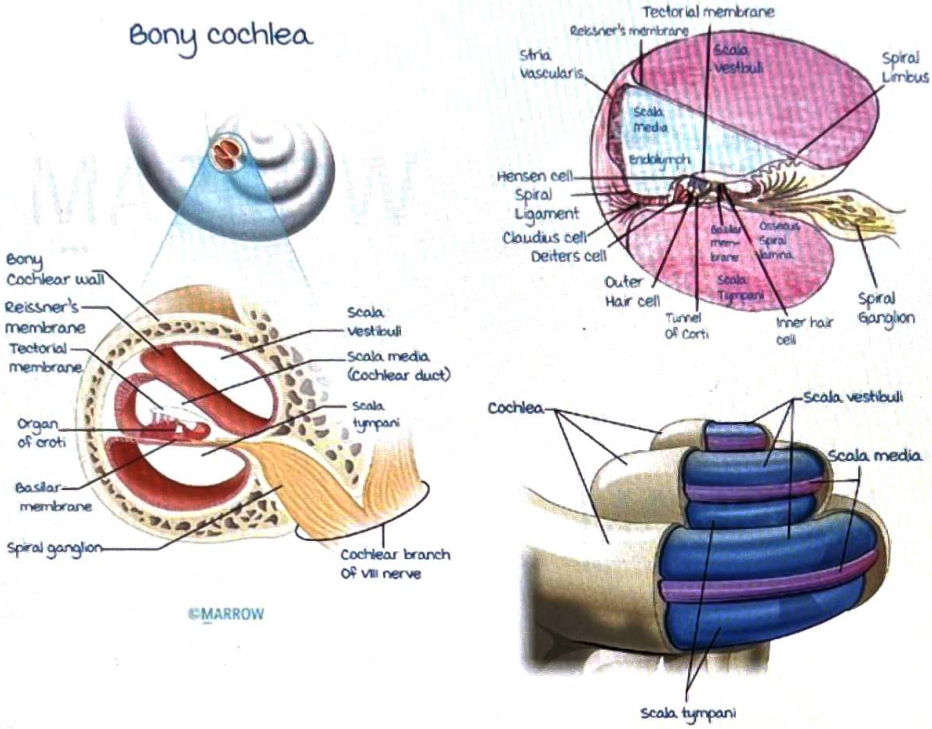

Organ of Corti present in scala media (divides bony labyrinth into upper scala vestibuli and lower scala tympani).

Structures around scala media :

- Reissner's membrane : Separates scala media and scala vestibuli.
- Basilar membrane (organ of corti present here) : Separates scala media and scala tympani.
- Stria vascularis (site of production of endolymph) : Present on the lateral surface of scala media.

Endolymph : Fluid in the scala media.

- Has electrochemical gradient of +85mV (maintained by the $Na^+/K^+/2\ Cl$ in the stria vascularis).
- Furosemide (loop diuretic, acts on $Na^+/K^+/2\ Cl$) : Ototoxic because acts on the stria vascularis (because of same channels).
- Meniere's disease (overproduction of endolymph) : sodium restricted diet recommended.
- Absorption of endolymph occurs from the endolym phatic sac.

Active space

Leave Feedba

- Perilymph : Fluid present in the scala vestibuli and scala tympani.

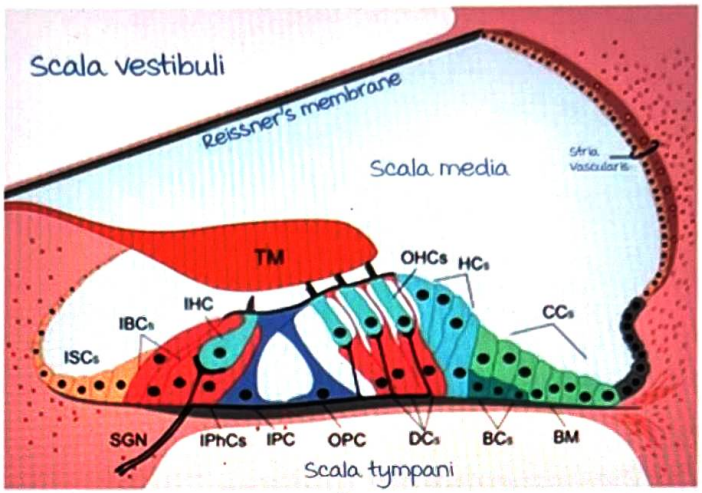

organ of corti

- Have hair cells (inner and outer) and supporting cells.
- Difference in inner hair cell and outer hair cell :

Inner hair cell	Outer hair cell
• Arranged in one row	• Arranged in 2-3 rows
• Less in number	• more in number
• Less prone to damage	• more prone to damage by drugs, noise
• Afferent nerves are present	• Efferent nerves are present
	• Produces OAE (oto acoustic emission)

- Inner hair cell (IHC) transmits auditory stimuli whereas outer hair cell modulates IHC function.

Transduction of sound :

- conversion of mechanical sound energy into electrica impulses.

Transmission of sound

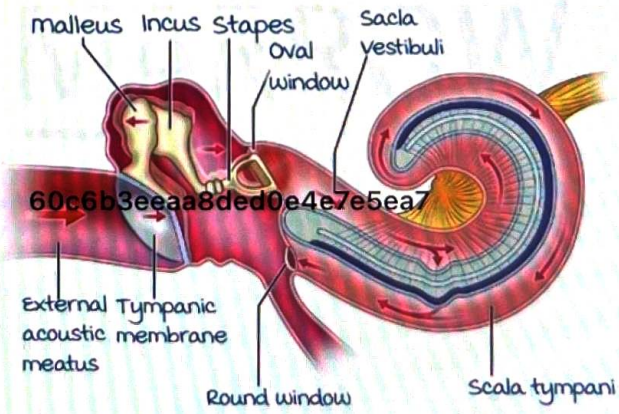

60c6b3eeaa8ded0e4e7e5ea7

Active space

Leave Feedba

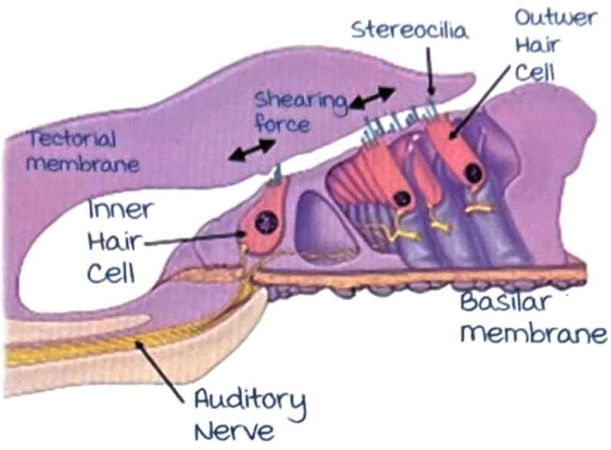

- Opposite movement of scala vestibuli and scala tympani create a shearing action which leads to movement of the basilar membrane. This stimulates the organ of corti.
- The highest tip of hair cells (arranged in ascending order of height) projects onto the tectorial membrane.
- The basilar membrane moves but the tectorial membrane doesn't, which also creates a shearing force.

The tips have K^+ channels and they open

↓

K^+ enters into hair cell from endolymph

↓

Voltage gated Ca^{a+} channels open – Ca^{a+} influx

↓

Causes release of excitatory neurotransmitter glutamate

Anatomy of inner ear

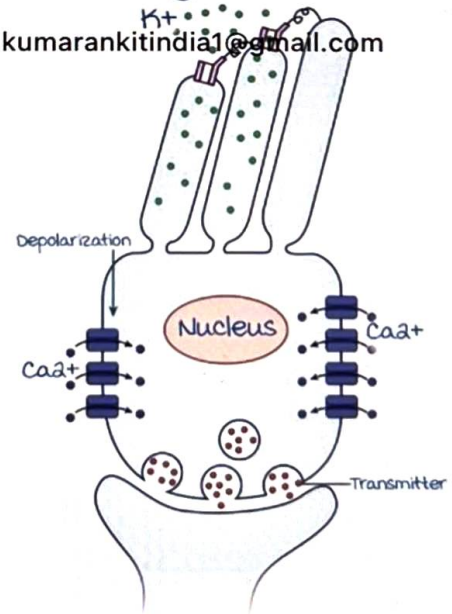

kumarankitindia1@gmail.com

Active space

Leave Feedback

Auditory pathway

00:15:52

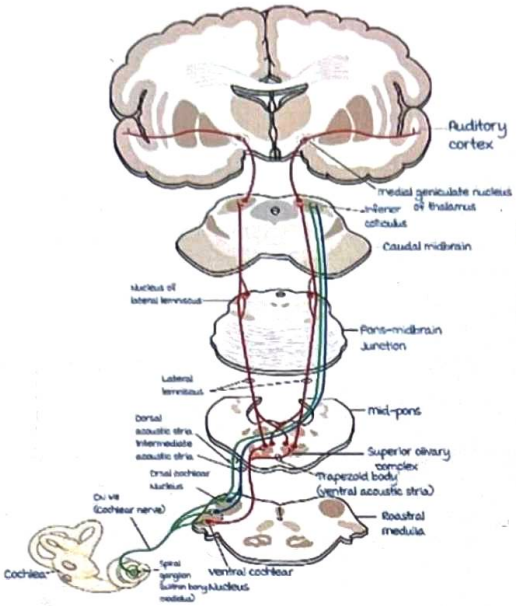

Inner hair cell
↓
Afferent nerve
↓
Cochlear nerve
↓
Spiral ganglion
(exits through internal acoustic meatus)
↓
Brain stem (ventral and dorsal cochlear nuclei)
S – Superior olivary complex
↓
L – Nucleus of Lateral lemniscus
↓
I – Inferior colliculus
↓
m – medial geniculate body
↓
Auditory cortex (area-41) – Superior temporal gyrus

- It is tested using BERA.
- The nerves of auditory pathway cross to other side of brain and are interconnected
- The fibers cross at the level of the superior olivary complex (through the trapezoid body).
- Superior olivary nucleus :
  - Starting point for localization of sound
  - Centre for stapedial reflex (Interconnection of VIII nerve to VII nerve)
    ↓
    Response to high intensity sound

60c6b3eeaa8ded0e4e7e5ea7

- Superior temporal gyrus : Appreciation of sound

Dark Cells : Maintain the electrochemical gradient of endolymph in utricle and saccule.

Active space

Leave Feedback

Structure of cristae and maculae 00:24:46

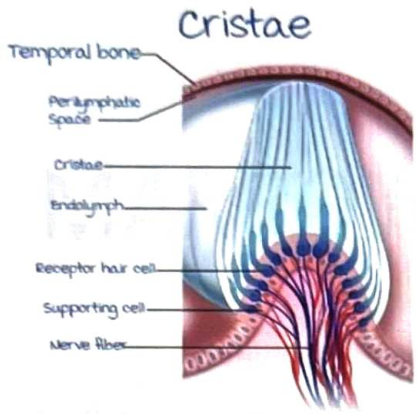

- Contain type 1 and type 2 hair cells.
- In cristae, hair cells project into gelatinous material called Cupula.
- In maculae, hair cells project into gelatinous material covered by calcium carbonate crystals, called Otolith.
  - Following trauma / pathology : Otolith gets dislodged

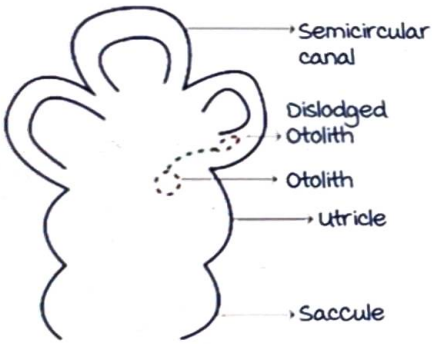

↓

Goes into semicircular canal (SCC) (m.c – Posterior semicircular canal)

↓

Stimulates SCC and causes vertigo

↓

After sometime, $CaCO_3$ crystals settle due to gravity decreases vertigo

↓

head movement causes vertigo again (cycle repeats)

↓

Positional vertigo (m.c – vertigo)

↓

C/F : vertigo on changing posture Lasting for few seconds

- Posterior semicircular canal is supplied by singular nerve (branch of inferior vestibular nerve)

Active space

Leave Feedba

Vestibular nerve & internal acoustic meatus :

Cristae & maculae

↓

vestibular nerve arises

(superior & inferior vestibular nerve)

↓

Exits through Internal acoustic meatus

Maculae

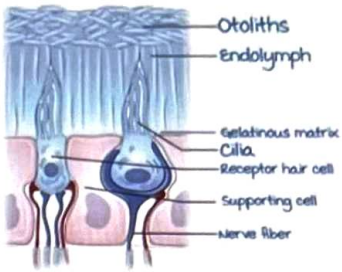

Internal acoustic meatus : An opening in the petrous bone (posterior slant)

Structures passing through internal acoustic meatus

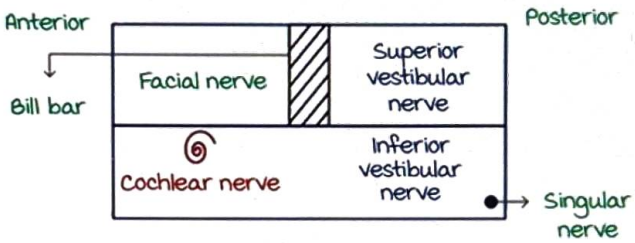

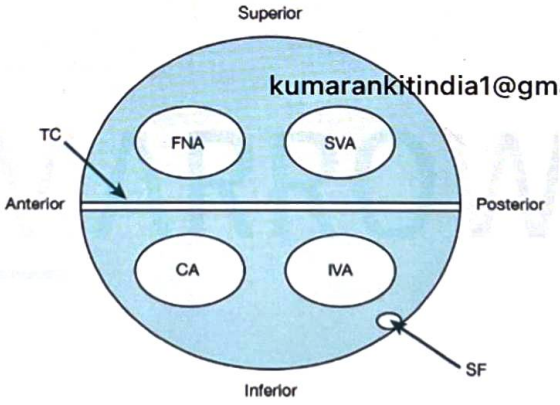

kumarankitindia1@gmail.com

Internal acoustic meatus

Superior part

↓

- Bill bar – crest of bone divide superior part into two

↓

Nerves – Facial nerve
Superior vestibular nerve

Inferior part

↓

Nerves – Inferior vestibular nerve
singular nerve (branch of inferior vestibular nerve
cochlear nerve

Active space

Leave Feedback

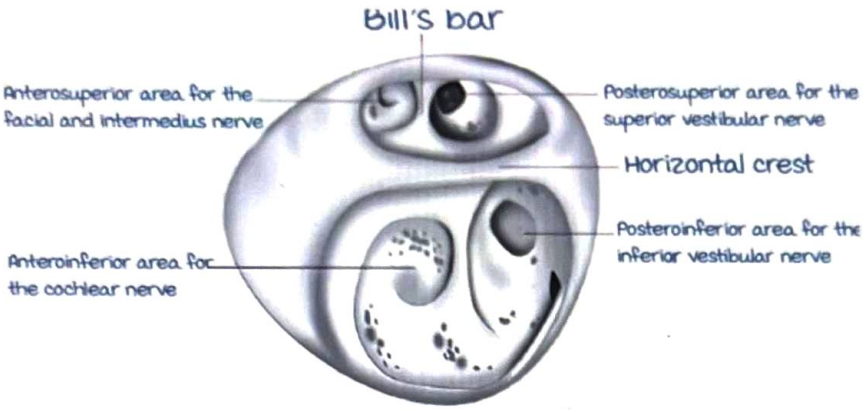

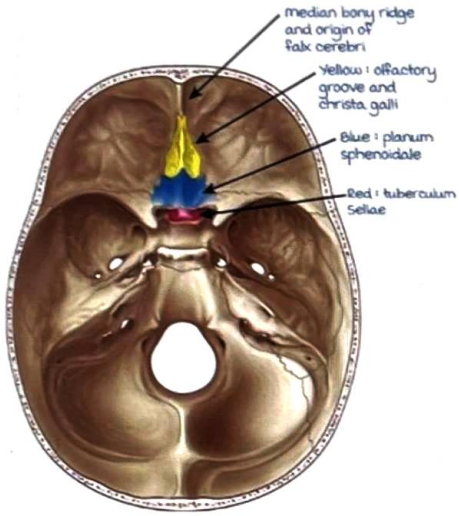

Acoustic neuroma :

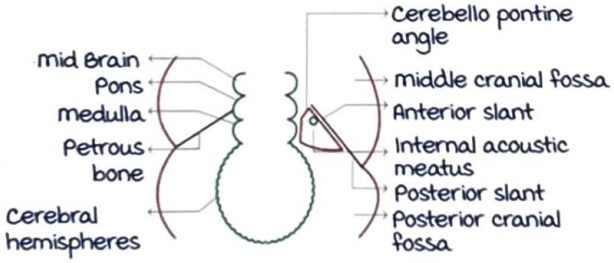

Acoustic neuroma – M.C benign tumor of cerebello pontine angle

↓

It Arises from inferior vestibular nerve in internal acoustic meatus

↓

The upper pole of the tumor involves – 5, 6 cranial nerves

↓

The lower pole of the tumor involves – 9, 10, 11 cranial nerves

60c6b3eeaa8ded0e4e7e5ea7

Active space

Leave Feedba

NERVE SUPPLY OF EAR

Pain sensations to ear

00:01:08

Inner ear pathologies never lead to pain because there are no sensory nerves.

Pain in ear → External or middle ear pathologies or referred pain from other organs.

60c6b3eeaa8ded0e4e7e5ea7

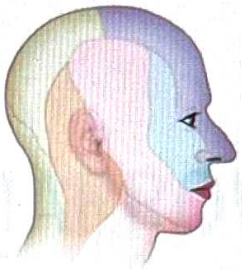

Nerve supply of pinna :

5 nerves :

Location	Supplies	Nerve
Anterior	Tragus. Ascending crus of Helix.	Auriculotemporal nerve (mandibular branch of Trigeminal nerve)
Posterior	Lesser (small) part of Pinna	C2 branch – Lesser occipital
Lateral	Angle of jaw. most of lateral and medial surface of Pinna	Greater Auricular nerve (C2-C3)
Concha area	Concha	Auricular branch of Vagus nerve (Arnold's or Alderman's nerve)
Postero-superior	Postero-superior part of external auditory meatus. Adjacent part of external auditory canal.	Facial nerve

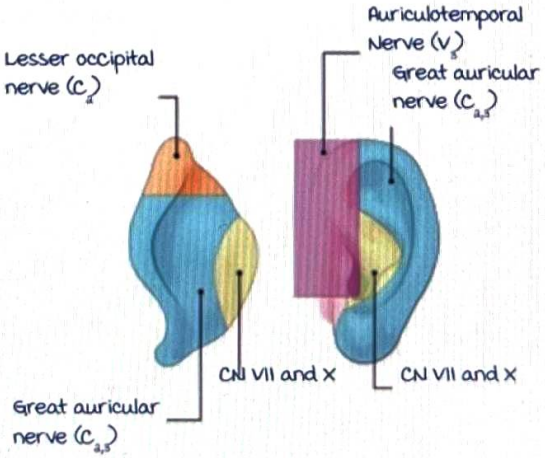

Active space

Mnemonic : GOAA

Greater Auricular (C2, C3).

O : Lesser occipital (C2).

A : Auriculotemporal nerve (Mandibular nerve).

A : Arnold's nerve (Auricular branch of Facial nerve).

Facial nerve.

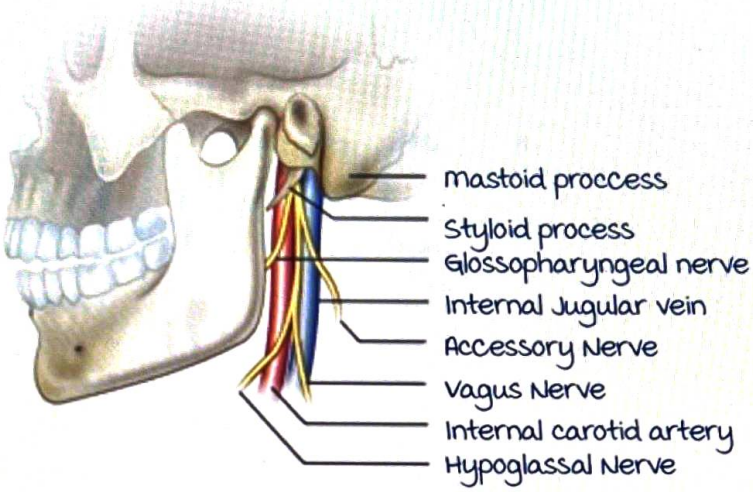

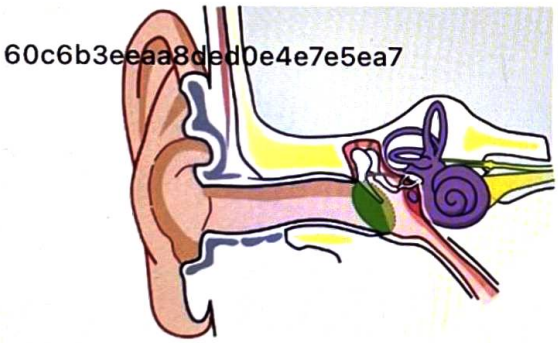

If patient is undergoing parotidectomy, the lazy S incision can injure greater auricular nerve. Therefore, post surgery there will be anaesthesia in this area, which is the shaving area and involves the lobule.

Active space

Leave Feedba

Referred pain

00:16:50

- Pain ear : Primary otalgia.
- Referred pain in ear : Secondary otalgia.

Referred pain in	Damage in	Through nerve	Note
Tragal area	TM joint. Mandible : Teeth, anterior 2/3rd of tongue, parotid gland.	Auriculotemporal nerve	
Concha	Larynx. Thyroid.	Vagus nerve	
External auditory meatus(EAM) (Posterior part)	Acoustic neuroma	Facial nerve (Sensory branch : Nervus Intermedia/ nerve of Wrisberg)	Hypoesthesia in Posterior part of EAM (Hitzelberger sign)
Ear : Posterior + Lateral parts	Cervical Spondylitis	C2, C3	

kumarankitindia1@gmail.com

Nerve supply of External Auditory Canal

00:22:58

Auriculotemporal nerve : Anterior wall and roof of EAC.
Auricular branch of Vagus (Arnold's nerve) : Posterior wall and floor of EAC.

Tympanic membrane :
Lateral surface :
Auriculotemporal nerve.
Auricular branch of Vagus (Arnold's nerve).

Medial surface :
Jacobson's nerve (branch of glossopharyngeal nerve) :

- Middle ear.
- Posterior 1/3rd of tongue.
- Tonsils.
- Soft palate.
- Pharynx.

Active space

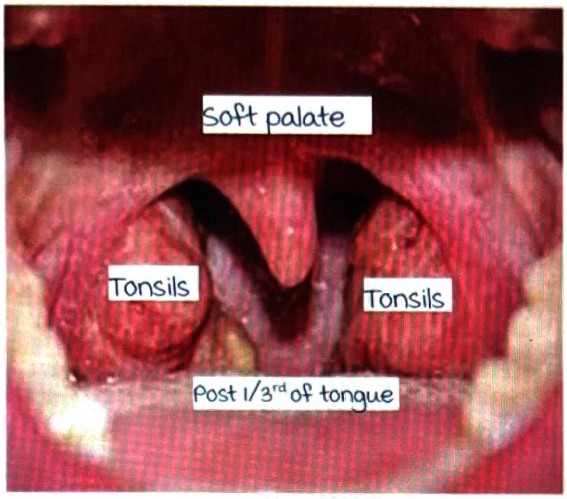

Pain referred to the ear from	The common nerve, responsible
TM joint and dental conditions. Parotid infections /tumour. Anterior 2 /3 of tongue.	Auriculotemporal (V3)
Acute tonsillitis, peritonsillar abscess. Carcinoma base of tongue or tonsils (oropharynx).	Glossopharyngeal (IX) (Jacobson's)
Carcinomas of the larynx (cough) and hypopharynx and thyroid	Vagus (X) (Arnolds/ Alderman's)
Cervical spine degenerative conditions	Greater auricular (C2, C3) (numbness parotidectomy) lesser occipital nerve C2
Hitselberger sign (Acoustic neuroma)	Facial (VII) (nervus intermedius / Wrisberg)

60c6b3eeaa8ded0e4e7e5ea7

Active space

Leave Feedba

AUDIOLOGY AND EVALUATION : TUNING FORK TESTS

Normal pathway :

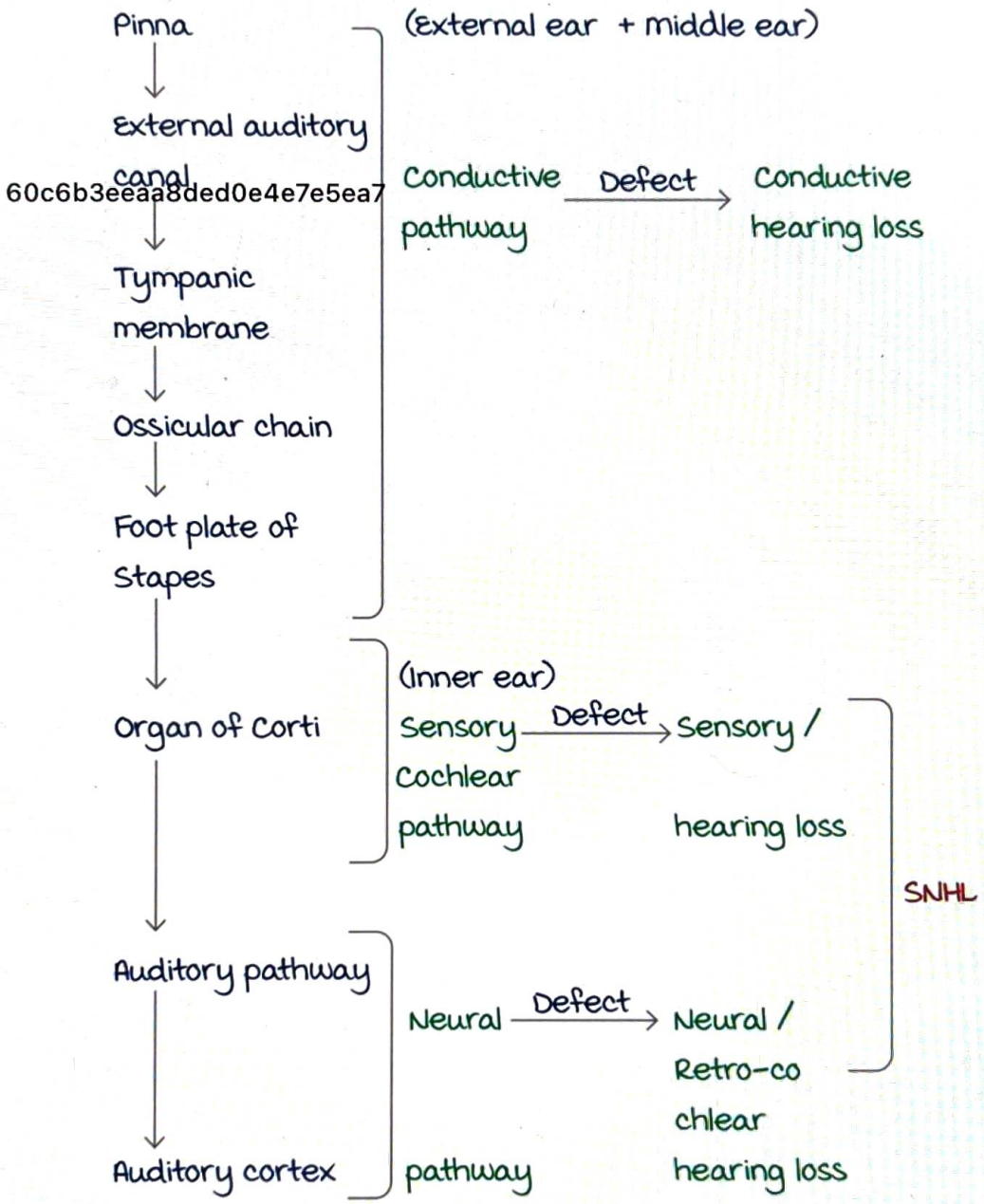

60c6b3eeaa8ded0e4e7e5ea7

Functions of the middle ear 00:05:00

1. Impedence matching :

   Also known as Transformer action.

   Amplification of sound to overcome reflection due to change

   in medium from air to fluid.

Active space

Leave Feedbac

2. Dampening of sound by Stapedial reflex

Amplification of sound :

- Areal / Hydraulic ratio :
  Sound travels from the tympanic membrane (larger surface area) to footplate of stapes (small surface area) via the ossicular chain.

- Effective vibratory area of tympanic membrane : 55 mm^2
  Footplate area : 3.2 mm^2

  $$\text{Areal ratio} = \frac{\text{Effective vibratory area of tympanic membrane} = 17}{\text{Footplate area}}$$

- Lever ratio :
  The long process of incus : 1.3 times smaller than the handle of malleus.
  Lever ratio = 1.3
- Total transformer ratio :
  Total transformer ratio = Areal ratio X Lever ratio
  = 17 X 1.3
  = 22
- Phase difference :
  Difference in phase between compression (oval window) and
  rarefaction (round window).
  Prevents noise cancellation and hearing loss.

Tuning fork tests 00:16:09

- Most common frequency used : 512 Hertz.
- Ears are sensitive to : 20 Hz – 20,000 Hertz.
- Speech frequencies : 500 Hz, 1000 Hz, 2000 Hertz.
- Tuning forks of frequencies less than 512 Hertz are used to assess vibration sense.

60c6b3eeaa8ded0e4e7e5ea7

Active space

Leave Feedbac

Air conduction and Bone conduction 00:21:08

Air conduction :

- measure of conductive, sensory and neural pathways.
- The most important part of conductive pathway : middle ear (amplification of sound).

Bone conduction :

- measure of sensory and neural pathways.
- Vibrating tuning fork is placed on mastoid.

↓

Cochlear fluids move.

↓

Basilar membrane and hair cells stimulated.

↓

Auditory pathway

↓

Auditory cortex

Air conduction is better than bone conduction, because the amplified sound reaches sensory neural pathways.

Rinne test 00.25.34

Air conduction (AC) and Bone conduction (BC) are tested and compared :

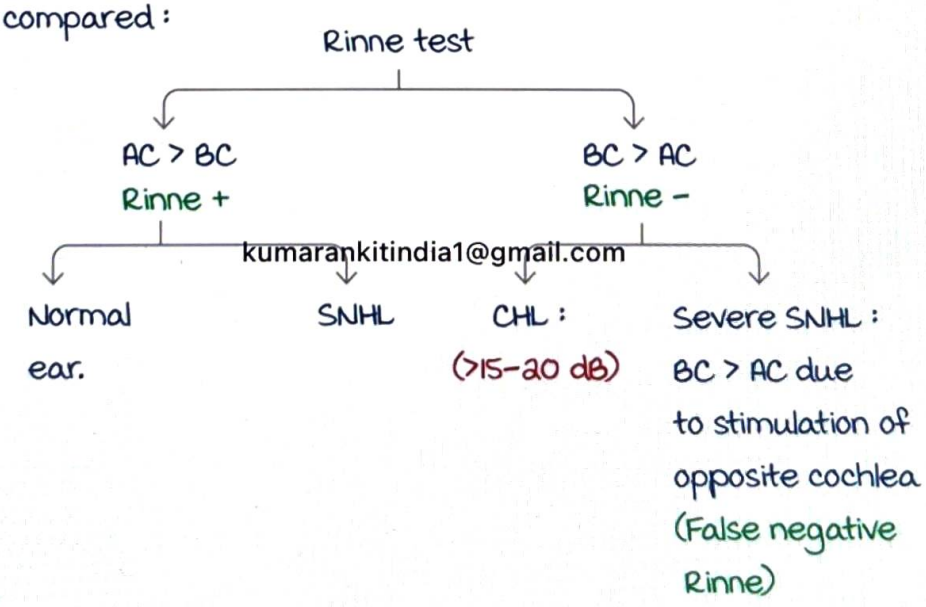

kumarankitindia1@gmail.com

Rinne test becomes negative only if the hearing loss is more than 15 dB.

Active space

Leave Feedbac

Sudden severe SNHL :

- Due to viral infection / idiopathic.
- Sudden edema, ischemia, compression of inner ear is seen.
- Reversible with immediate steroid administration.

Weber test 00.41.55

The tuning fork is placed on the forehead, vertex or upper teeth.

Tests bone conduction.

60c6b3eeaa8ded0e4e7e5ea7

To assess the lateralisation of sound.

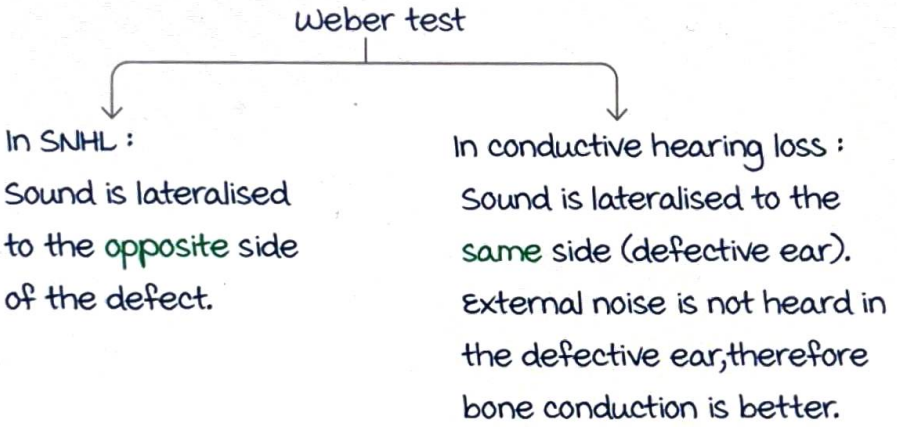

Mnemonic : SO CS

- SNHL : Lateralised to opposite side
- Conductive : Lateralised to same side

Patient complaints of decreased hearing in right ear :

- Rinne test negative : It is suggestive of CHL and Severe SNHL.
- Weber test : Towards left ear.
- Diagnosis : Severe SNHL

Patient complaints of decreased hearing in right ear :

- Rinne test negative : It is suggestive of CHL and Severe SNHL.
- Weber test : Towards right ear.
- Diagnosis : Right CHL

Conductive hearing loss :

- Serous otitis media
- Otosclerosis

Active space

Leave Feedba

Sensorineural hearing loss :

- Meniere's disease
- Acoustic neuroma

Acoustic bone conduction test and Schwabach test

00:59:27

Acoustic bone conduction test (ABC) :

- To assess the bone conduction (SNHL assessment).
- The bone conduction of the patient is compared to that of the examiner's.

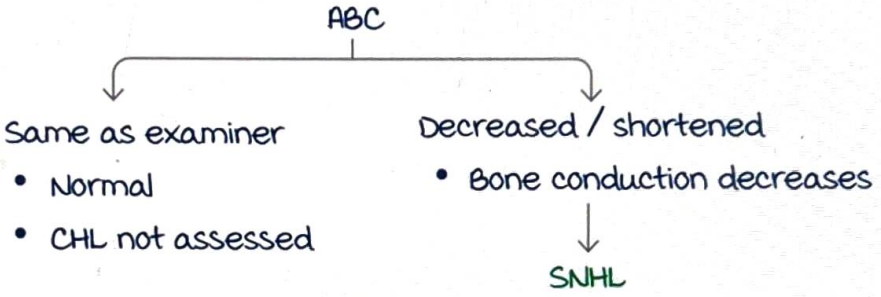

Schwabach test : 60c6b3eeaa8ded0e4e7e5ea7

- Similar to ABC test but tragus is not covered.
- To reconfirm CHL and SNHL.

Compare the bone conduction of the patient to the examiner's

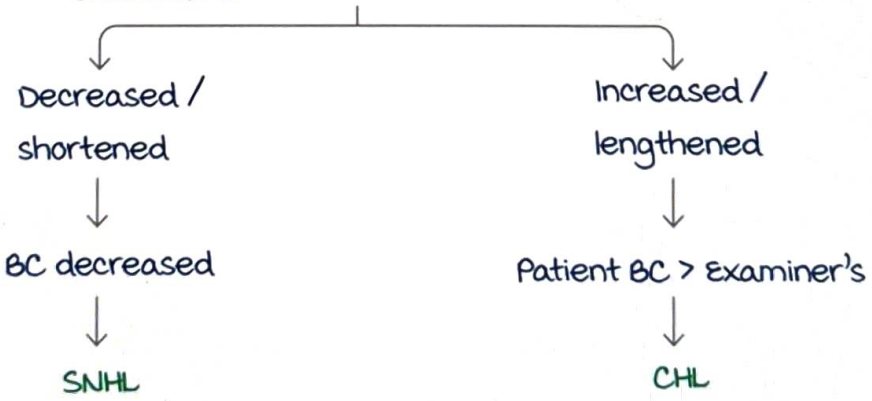

Gelle test and Bing test

01:10:46

Gelle test :

Test for otosclerosis.

Siegel's speculum is used to alter the external auditory canal

pressure.

Negative Gelle : No change in hearing with pressure variation (ossicular chain fixation).

Active space

Leave Feedba

Bing test :

No change in hearing on pressing and releasing tragus : CHL.

There is change in hearing on pressing and releasing tragus : Normal.

Q. In a patient of decreased hearing, Rinne test in Right ear is negative and in Left ear is positive. Which is true? (AIIMS)

A. 40 db CHL in Left ear
B. Bilateral 40 db CHL.
C. Left SSNHL, Right normal
D. Right SSNHL, Left normal

Q. A 38 year old gentleman reports of decreased hearing in the right ear for the last 2 years. On testing with a 512 Hz tuning fork, the Rinne test is negative on the right ear and positive on the left ear. With the Weber test the tone is perceived as louder in the left ear. Most likely the patient has :

A. Right conductive hearing loss
B. Right severe sensorineural hearing loss
C. Left sensorineural hearing loss
D. Left conductive hearing loss

Q. In a patient, Rinne test positive/ AC >BC, in both ears, Weber's lateralises to the right. Next step?

kumarankitindia1@gmail.com

A. No intervention as both the ears normal
B. Remove wax from right ear
C. Repeat Rinne test
D. Do Shwabach test

Active space

Leave Feedba

AUDIOLOGY AND EVALUATION : AUDIOGRAM (PTA)

Estimation of hearing loss

00:01:50

Negative tuning fork test frequency	Hearing loss
256 Hz	15 dB
512 Hz	30 dB
1024 Hz	45 dB

Condition	Hearing loss
Complete obstruction of external auditory canal (EAC).	30 – 40 dB
Tympanic membrane (TM) perforation. maximum hearing loss seen in : • Increasing size of perforation. • When phase difference is absent.	10 – 40 dB
TM perforation + ossicular discontinuity	40 dB
Ossicular discontinuity + intact TM	55 dB
Complete fixation of stapes foot plate (Otosclerosis).	60 dB

Introduction to pure tone audiometry

00:08:26

The ear is sensitive to frequencies from 20 – 20,000 Hz.

60c6b3eeaa8ded0e4e7e5ea7

Speech frequencies : 500, 1000, 2000 Hz.

Indications of Pure tone audiometry (PTA) :

1. To determine type of hearing loss : Conductive, sensorineural or mixed hearing loss.

Active space

2. To determine the degree of hearing loss.
3. To determine the affected frequency.

PTA is a subjective test.

Normal range of hearing : -10 to 25 dB

PTA results are plotted on a graph known as Audiogram.

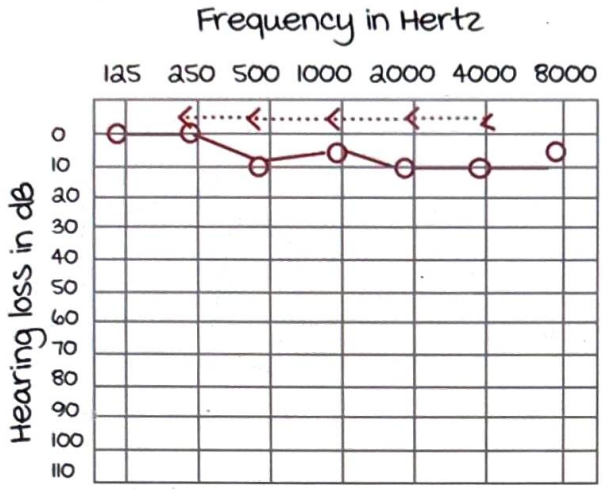

Grading of hearing loss

00:16:41

American speech and hearing association (ASHA) classification :

- commonly followed.
- Indication for cochlear implant : >70 dB hearing loss.

Pure Tone Average Range in dBHL	Degree of hearing loss
-10 to 25	Normal Hearing Sensitivity
26-40	Mild Hearing Loss
41-55	Moderate Hearing Loss
56-70	Moderately Severe Hearing Loss
71-90	Severe Hearing Loss
>91	Profound Hearing Loss

60c6b3eeaa8ded0e4e7e5ea7
Active space

Leave Feedba

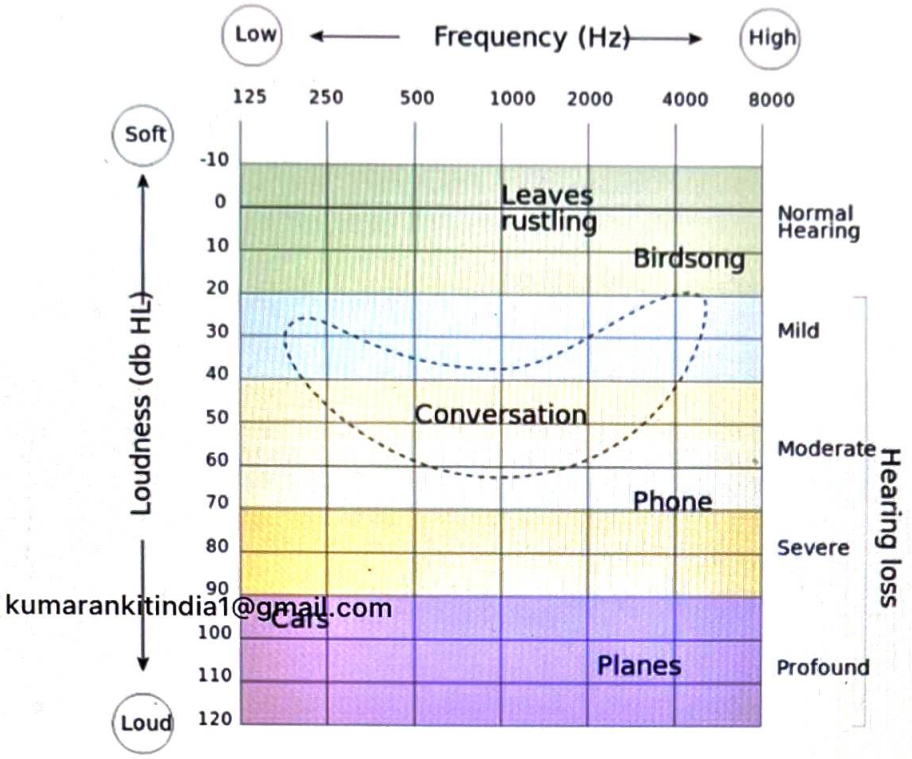

kumarankitindia1@gmail.com

WHO classification :

Interpretation of an audiogram 00:23:43

Localization of sound :

- The ear in the direction of a sound hears it louder.
- There is loss of 40 dB in the opposite ear.

Masking : While testing one ear, white noise is played to the opposite ear to eliminate its contribution.

Symbols in an Audiogram :

Active space

	Right (Red)	Left (Blue)
Air conduction (AC) unmasked	○	×
Air conduction masked	Δ	□
Bone conduction (BC) unmasked	<	>
Bone conduction masked	[	]

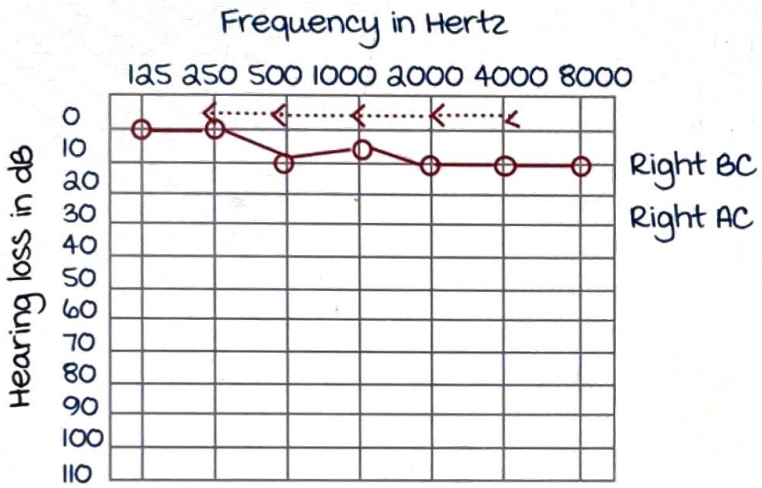

60c6b3eeaa8ded0e4e7e5ea7

Normal audiogram

00:30:15

- AC and BC up to 25 dB.
- If AC is normal : Both sensorineural (SN) and conductive(C) hearing are normal.

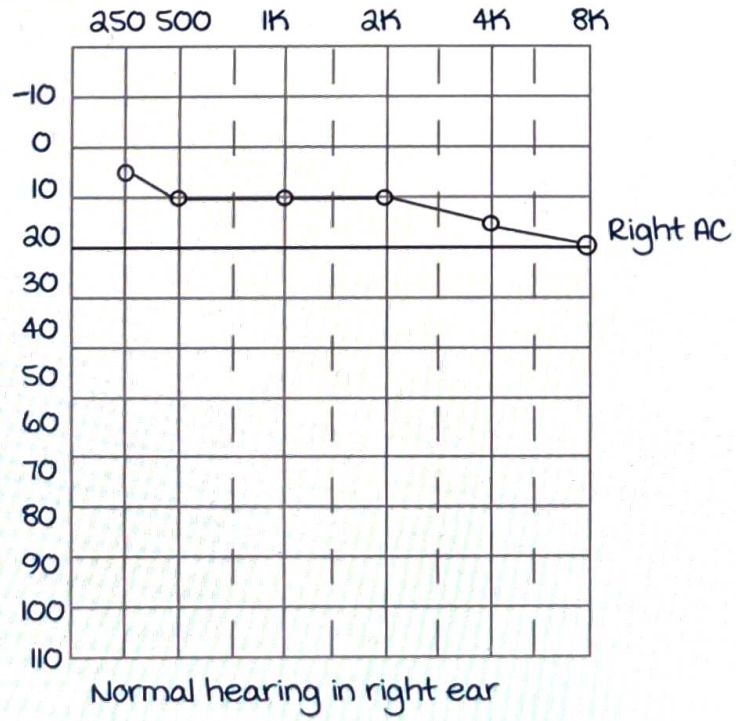

Active space

Leave Feedba

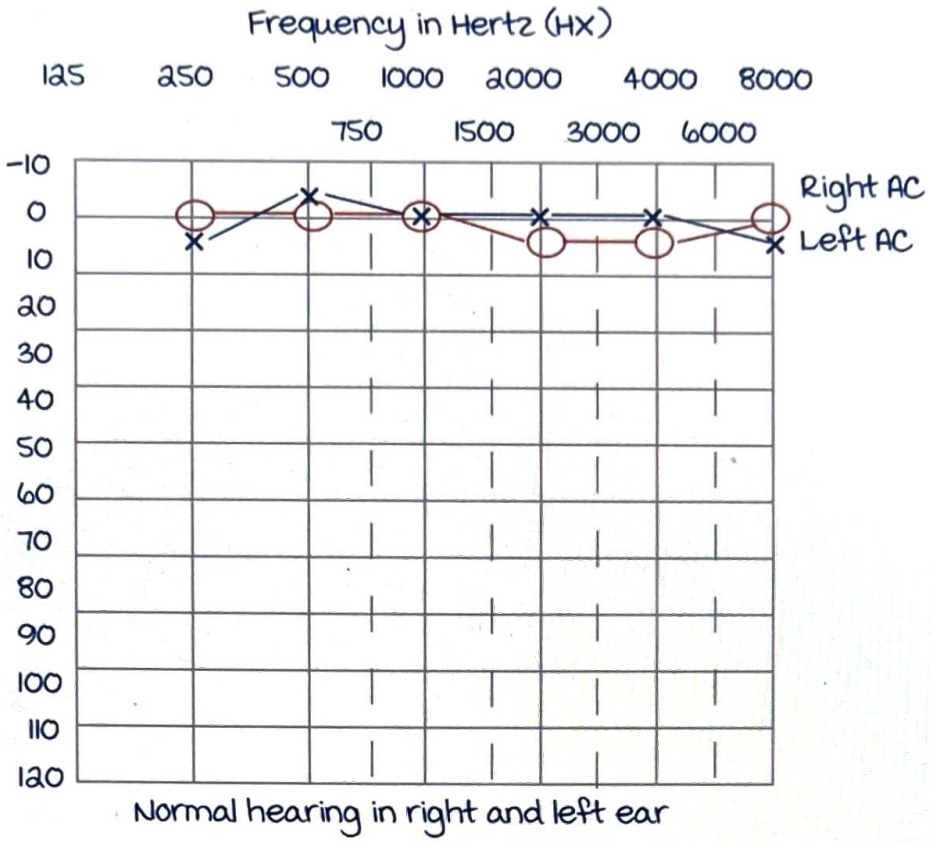

Normal hearing in right and left ear

Conductive, sensrineural and mixed hearing loss audiogram

00:33:17

Moderate right conductive hearing loss (CHL) :

- Right BC normal (Normal SN).
- Right AC defective
  (Normal SN + Defective C)
- In speech frequency : 50 dB loss.
- AB Gap > 15 dB : Defective C.

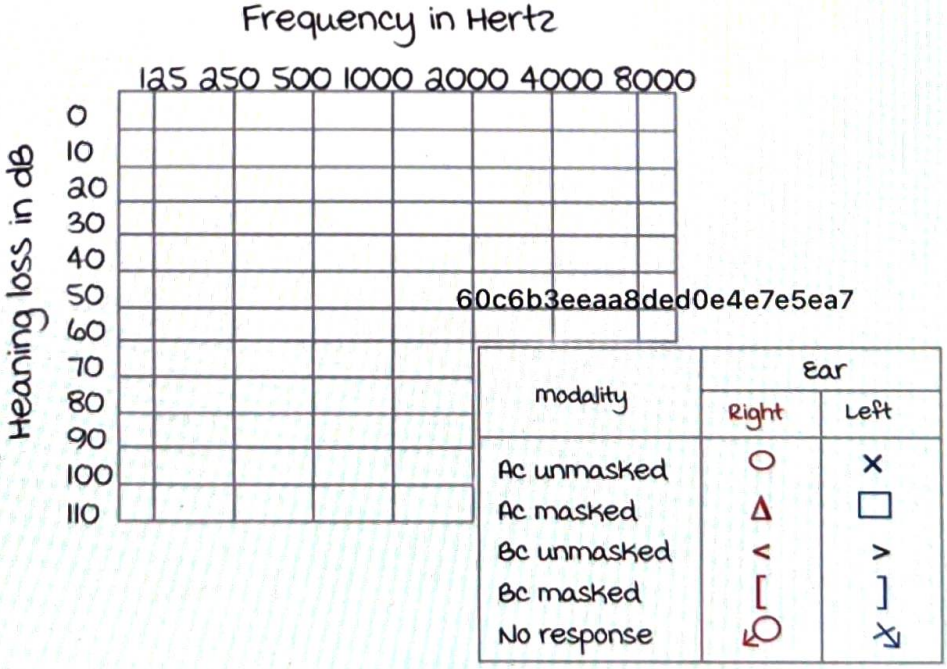

Modality	Ear	
	Right	Left
Ac unmasked	O	X
Ac masked	Δ	□
Bc unmasked	<	>
Bc masked	[	]
No response	↙O	X↘

Active space

Leave Feedba

Right sensorineural hearing loss (SNHL) :

- Right BC defective (Defective SN).
- Right AC defective.
- AB gap < 15 dB : C is not affected.

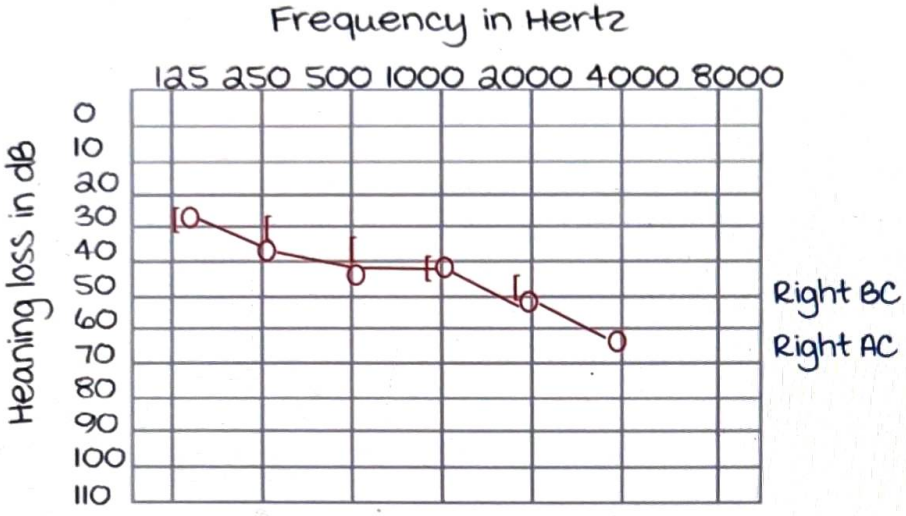

If AB Gap > 15 dB : Defective conductive hearing.

Left mixed hearing loss :

- Left BC defective (Defective SN).
- Left AC defective.
- AB gap >15 dB : C is affected.

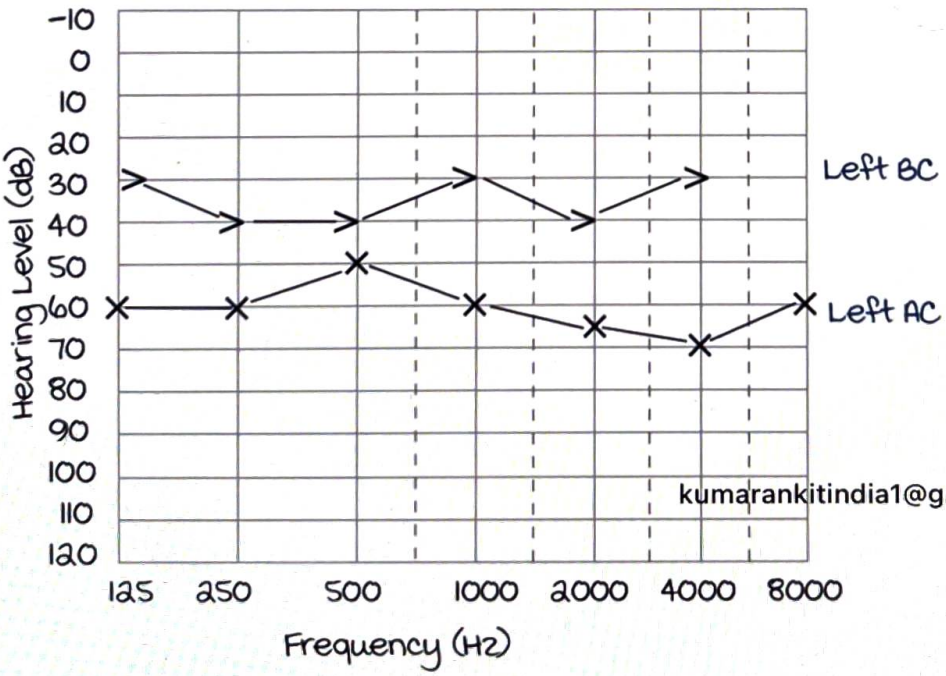

kumarankitindia1@gmail.com

Right and Left CHL :

Right CHL :

- Right BC normal (Normal SN).

Active space

Leave Feedba

- Right AC defective.
- AB gap > 15 dB : C is affected.

Left CHL :

- Left BC normal (Normal SN).
- Left AC defective.
- AB gap > 15 dB : C is affected

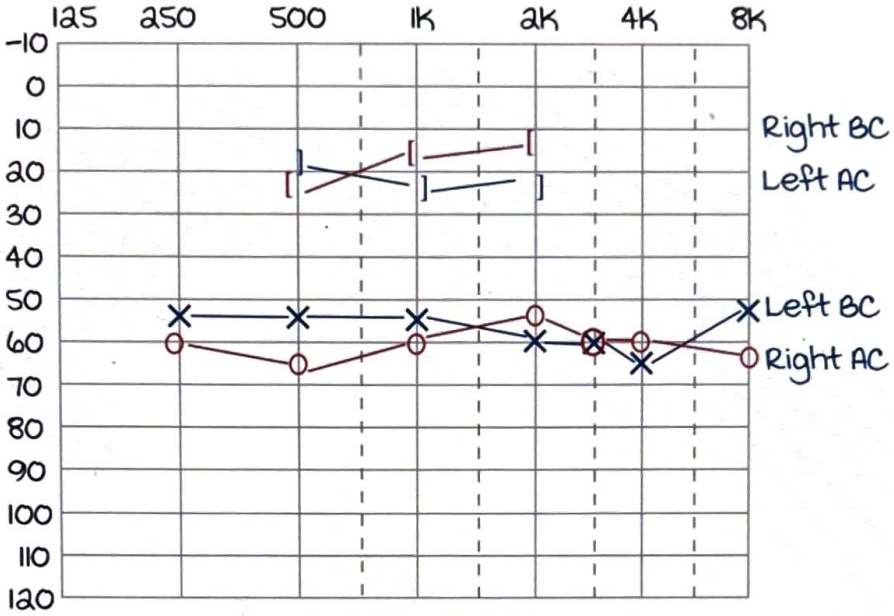

Right CHL :

Normal left ear

- Left AC : Normal (SN and C normal)

Right CHL :

- Right AC defective.
- Right BC not given : Normal.

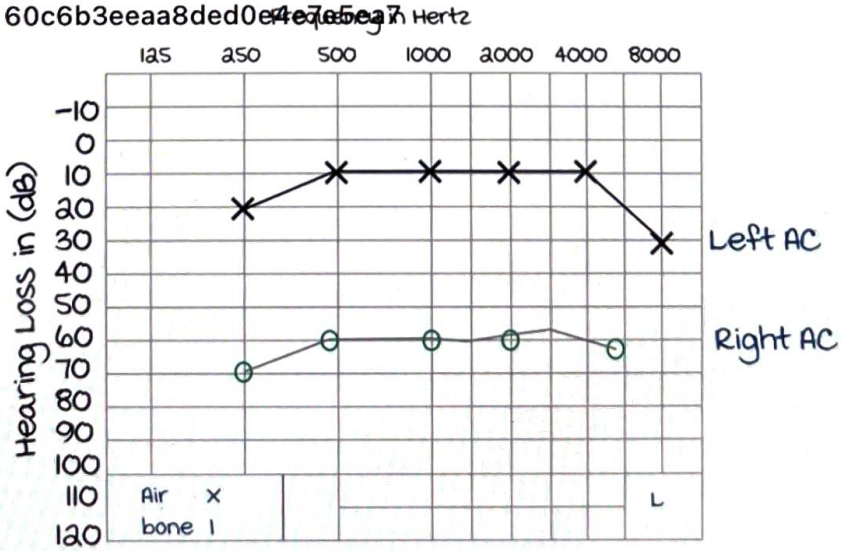

If BC is not given it is normal.

Active space

Leave Feedba

High and low frequency sensorineural hearing loss audiogram

00:52:55

Bilateral high frequency SNHL : Down-sloping audiogram.

Right high frequency SNHL :

- Right BC defective.
- Right AC defective.
- AB gap absent.

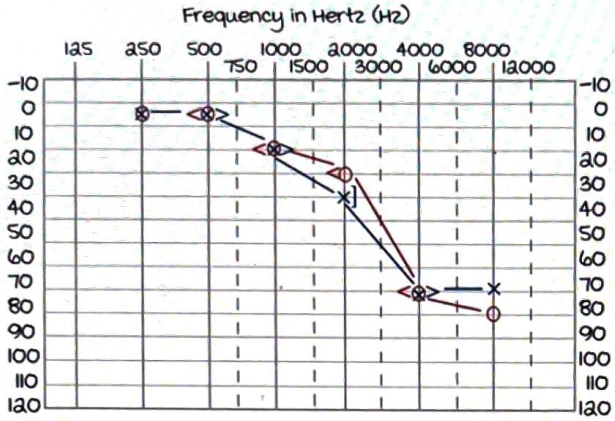

Left high frequency SNHL :

- Left BC defective.
- Left AC defective.
- AB gap absent.

Left low frequency SNHL : Up-sloping audiogram.

60c6b3eeaa8ded0e4e7e5ea7

Normal right ear :

- Right AC normal.

Left low frequency SNHL :

- Left AC defective.
- Left BC defective.
- AB gap absent

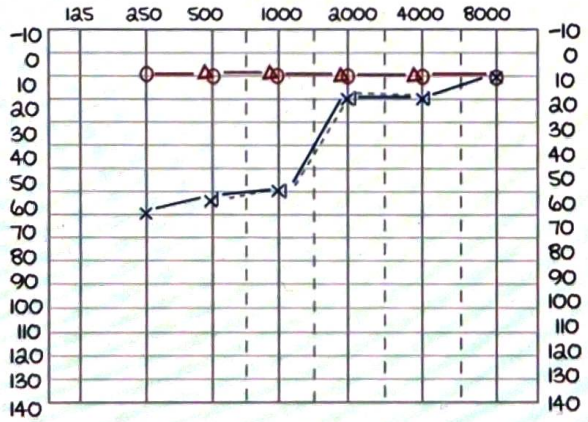

Active space

Leave Feedbac

Noise induced hearing loss and otosclerosis audiogram

00:52:55

Bilateral SNHL with acoustic dip.

Left and right SNHL :

- BC defective.
- AC defective.
- AB gap absent

kumarankitindia1@gmail.com

Acoustic dip at 4000 Hz : First change in noise induced hearing loss (NIHL).

In later stages of NIHL : Down-sloping audiogram.

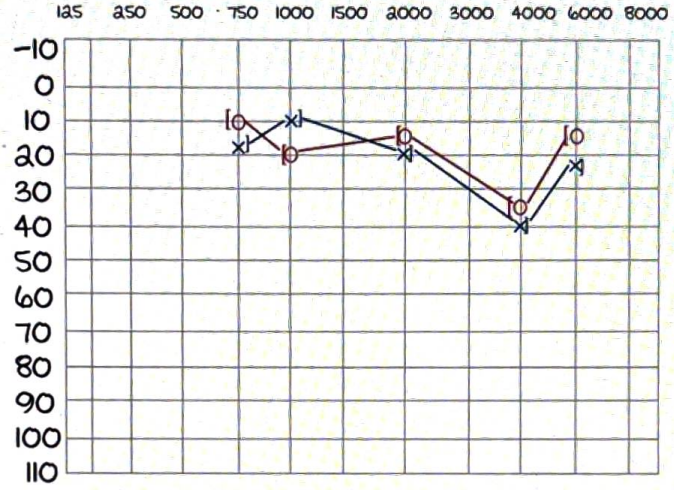

Left CHL with Carhart's notch : Otosclerosis.

Left CHL :

- Left BC normal.
- Left AC defective.
- AB gap present

Carhart's notch :

- Dip in BC at 2000 Hz.

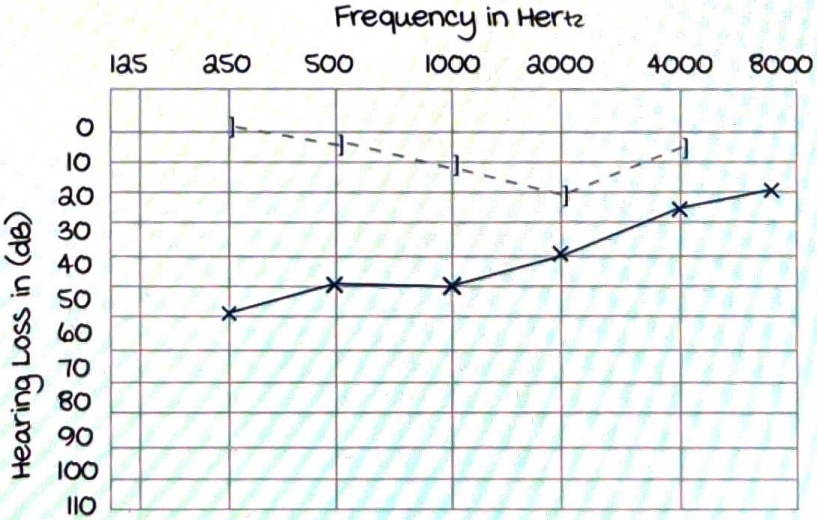

Active space

Leave Feedback

Steps for reading pure tone audiometry 01:01:30

1. Determine which ear : Left, right or both.
2. Determine if normal.
3. AB gap :
    - Absent : SNHL
    - >15 dB : CHL
    - BC normal + AB gap : CHL
    - BC defective + AB gap : Mixed hearing loss.

Characteristic audiograms :

Down-sloping : High frequency hearing loss



- Noise induced hearing loss
- Ototoxicity
- Presbycusis.

Up-sloping/ rising : Low frequency hearing loss



- Meniere's disease

Dip at 4000 Hz : Noise induced hearing loss.

U-shaped/ cookie bite/ Trough : Mid frequency (speech frequency) hearing loss

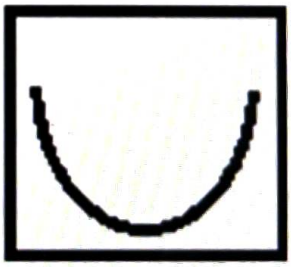

- Congenital SNHL

kumarankitindia1@gmail.com

CHL (AB gap) + Carhart's notch : Otosclerosis.

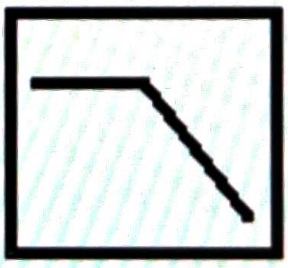

Active space

Leave Feedbac

AUDIOLOGY : PART 3 TYMPANOMETRY AND STAPEDIAL REFLEX

Evaluation of a patient with hearing loss 00:01:04

To localize the condition if it is due to either an external ear, middle ear or inner ear :

Examine the ear of the patient :

- If pinna, external auditory canal and tympanic membrane appears normal, lesion could be either in middle or inner ear.
- Then we can perform tuning fork tests to find out if it is conductive or sensorineural hearing loss.
- If sensorineural hearing loss : Lesion is in inner ear.
- If conductive hearing loss : Lesion is in middle ear. Confirm with audiogram.

Middle ear condition with normal tympanic membrane and conductive hearing loss can be due to :

- Discontinuity of the ossicular chain.
- Ossicular fixation.
- Fluid collection in middle ear.

To find out the condition of the middle ear, impedance audiometry should be done.

Impedance audiometry :

- Tympanometry.
- Stapedial Reflex.

Tympanometry :

A probe containing 3 openings is passed into the external auditory canal. Through one of the openings, a sound of 220-226 HZ is passed.

60c6b3eeaa8ded0e4e7e5ea7

Depending upon the condition of the middle ear, some sound is transmitted, and some sound gets reflected back.

The reflected sound is picked up by the second opening.

Active space

If most of the sound is reflected back and picked up by the second opening, it indicates middle ear is not functioning well.

Third opening changes the pressure of the external auditory canal, and the movement of tympanic membrane is checked (compliance) along with middle ear pressure.

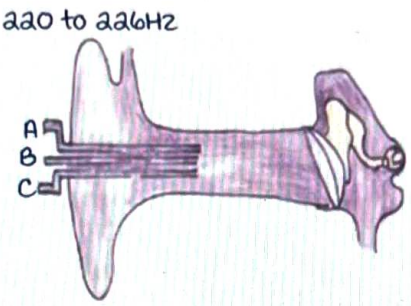

- Mobility of tympanic membrane (compliance) is increased if there is discontinuity of the ossicular chain.
- Mobility of tympanic membrane is decreased in ossicular fixation or if there is fluid in middle ear due to eustachian tube obstruction.
- If eustachian tube is functioning normally, and tympanic membrane is moving less : Ossicular fixation.
- If eustachian tube is obstructed, and tympanic membrane is moving less : Fluid in the middle ear.

60c6b3eeaa8ded0e4e7e5ea7

Function of eustachian tube : Ventilates the middle ear and maintains the middle ear pressure.

Middle ear pressure is an indication of eustachian tube function.
It helps to differentiate whether it is eustachian tube obstruction leading to serous otitis media and fluid collection or there is ossicular fixation.

Pressure in external auditory canal is changed from (-400) to (+200) in tympanometry. The pressure of external auditory canal at which maximum transmission of sound is seen (least amount of reflection) is noted.
It is equal to middle ear pressure.

Note :
For proper transmission of sound, pressure in the external auditory canal should be equal to pressure in the middle ear.

Active space

Leave Feedba

If pressure in the external auditory canal is more than the middle ear pressure → Tympanic membrane is pushed inside → Ossicular chain mobility is restricted.

If pressure in the external auditory canal is negative (lesser than middle ear pressure) → Tympanic membrane is pushed outside → Ossicular chain is stretched and transmission is restricted.

Indication of tympanometry 00:13:04

To find out the condition of middle ear with intact tympanic membrane.

Example case :
A 6 year old child is brought by the parents with the complaint of decreased hearing since the past one week. On examination, the external auditory canal appears normal. The tympanic membrane is intact, and appearance of the tympanic membrane is same in both the ears. The bone conduction is better than air conduction in both the ears. What is the next step to confirm the diagnosis?

Answer : Tympanometry.
It is an objective test. Result is obtained in the form of a graph called tympanogram.

kumarankitindia1@gmail.com

Active space

Note :

- Normal compliance is between 0.35 to 1.45 mL.
- Normal middle ear pressure is (+50) to (-50) mm H_aO in adults and (+50) to (-150) mm H_aO in children.

Tympanogram :

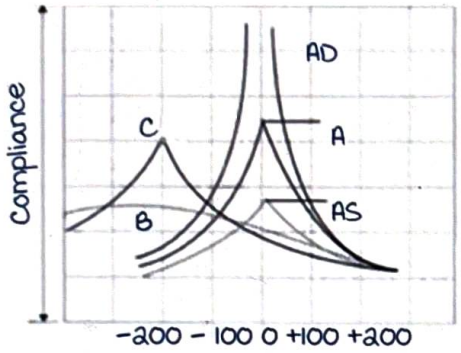

- A curve → Normal middle ear (middle ear pressure and compliance are normal.)
- Ad curve → Ossicular discontinuity (middle ear pressure is normal, but compliance is increased).
- As curve → Otosclerosis (Ossicular fixation/ Tympanosclerosis : middle ear pressure is normal, but compliance is decreased.)
- B curve → Serous otitis media (middle ear pressure is negative, and compliance is decreased. Curve is dome shaped. It can become flat if there is excess fluid and there is no mobility of tympanic membrane.)
- C curve → Early stage of eustachian tube obstruction (middle ear pressure is negative, but compliance is normal.)

A curve :

ECV 1.8 cm^3 peak 0.9 cm^3 L
ER 65 dapa - 55 dapa
1.5 cm^3

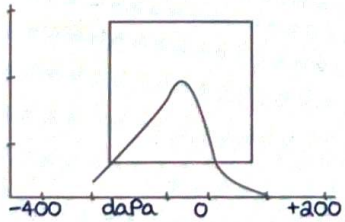

Ad curve :

ECV 1.8 cm^3 peak 3 to 7 cm^3 R
ER 30 dapa 0 dapa
3.0cm^3

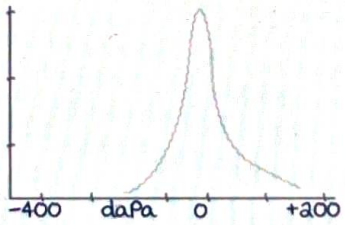

Active space

Leave Feedback

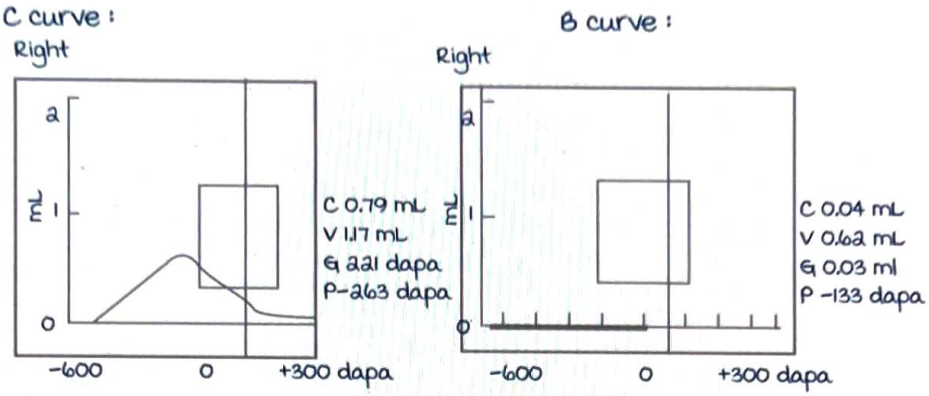

Flat line is seen if there is no mobility of tympanic membrane (excess fluid) or perforation.

Summary

00:28:10

60c6b3eeaa8ded0e4e7e5ea7

	Middle ear pressure	Compliance	Diagnosis
A	Normal	Normal	Normal middle ear
As	Normal	Reduced	Ossicular fixation: Otosclerosis or tympanosclerosis.
Ad	Normal	Increased	Ossicular discontinuity
B/Dome shaped	Negative	Reduced	Serous otitis media
C	Negative	Normal	Early eustachian tube obstruction
Flat	Nil	Nil	Excess fluid or perforation

Other tests for eustachian tube function :

Valsalva maneuver :

Exhalation with closed nostril and mouth → Air passes through eustachian tube into the ear → Sensation of ear drum popping out can be felt.

It can be used to test eustachian tube function.

However, there should be no infection in throat.

Active space

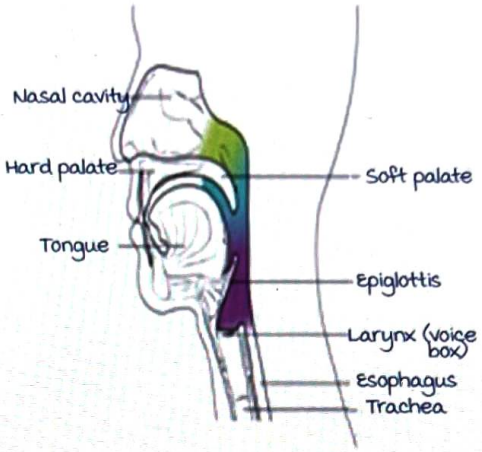

Politzer test :

Patient is asked to close one nostril. Through the other nostril politzer bag is put and pressure is increased. If eustachian tube is functioning normally, it transmits the air to the ear and tympanic membrane pops out.

kumarankitindia1@gmail.com

Politzer test

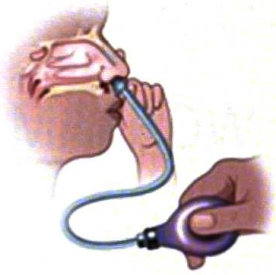

Toynbee maneuver :

Patient is asked to have a sip of water. With the sip of water in the mouth, patient is asked to close the nostrils and swallow. When the patient swallows, negative pressure is created in the eustachian tube area and patient reports pulling in of tympanic membrane. Pulling in of tympanic membrane can also be seen by otoscopy and middle ear pressure can be measured by tympanometry during this procedure.

Eustachian tube catheterization :

Eustachian tube catheter is passed through the floor of nostril into the nasopharynx. A ring at the bottom is in the same direction as the point of the catheter.

Active space

Leave Feedba

When the posterior wall of nasopharynx is reached, tip is turned to 90 degrees towards the septum. It is pulled back till it hinges behind the septum and the tip is rotated 180 degrees.

This points to eustachian tube opening on the lateral wall. A politzer bag is attached and pressure is increased to check if pressure is transmitted to middle ear (popping of tympanic membrane).

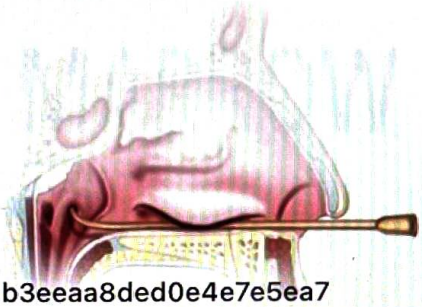

60c6b3eeaa8ded0e4e7e5ea7

Frenzel maneuver :

Mouth and nostrils are closed, and posterior part of tongue is raised (by saying "Ka Ka Ka Ka"). Increased pressure of air is transmitted through eustachian tube into the middle ear. Divers use this maneuver to equalize middle ear pressure with the external ear.

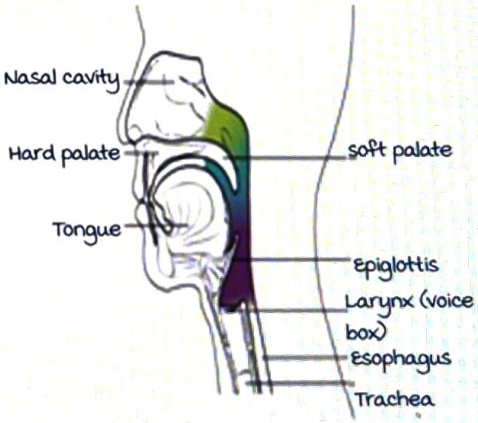

Best test for eustachian tube function is tympanometry.

Stapedial reflex

00:39:39

Active space

It is a protective reflex that protects the inner ear from noise trauma.

Whenever there is a loud noise (70 to 90 db) :

Sound travels as follows :

Afferent : External auditory canal → Middle ear → Inner ear (organ of corti) → Picked up by auditory pathwayat the level of superior olivary complex (centre for stapedial reflex).

Efferent : Sound then travels to the facial nerve of both the ears. Facial nerve supplies the stapedius causing its contraction and pulling the stapes back.

This test is used for malingering, non organic hearing loss (best test is BERA). It is an objective test.

Note :

- Stapedial reflex is mediated by : Afferent (8th nerve) and Efferent (7th nerve.)
- If loud noise is given in right ear for testing → 8th and 7th nerve of right ear and 7th nerve of left ear are tested
- If there is complete destruction of 8th nerve in right ear, Stapedial reflex will be absent in both ears.
- If there is facial nerve palsy on right side → Stapedial reflex will be absent only in the right ear. Site of lesion is in horizontal segment (before the branch to stapedius)
- If there is a defect in middle ear such as ossicular discontinuity, ossicular fixation or fluid in middle ear (conductive hearing loss) → Stapedial reflex will be absent.
- If there is a defect in inner ear (sensory hearing loss) → Fine tuning of loudness is lost (loud sounds are intolerable) →Threshold of stapedial reflex will decrease → Stapedial reflex will be elicited at lower loudness.
- If there is incomplete disruption of auditory pathway (retro cochlear defect/neural defect) → Stapedial reflex is present initially.
  After some time, it will be absent → Stapedial reflex decay.

60c6b3eeaa8ded0e4e7e5ea7

Active space

Leave Feedbac

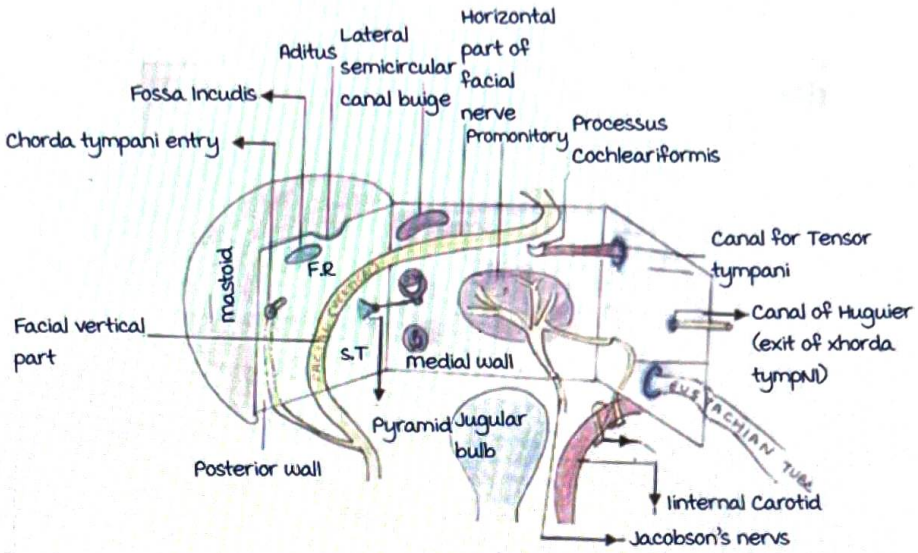

F.R : Farial Recess (suprapyramidal recess)
S.T : Sinus tymphani (intrapyramidal recess)
P : Promontory
O.W : Oval Window
R.W : Round Window

kumarankitindia1@gmail.com

Active space

AUDIOLOGY : PART 4 OAE, ECOG, BERA AND OTHER

Oto-acoustic emission (OAE)/ Kemp echoes 00:00:55

It is the recording of the activity of the outer hair cells.

Spontaneous OAE :

Normally present. But not used for testing as it is absent in 50% individuals.

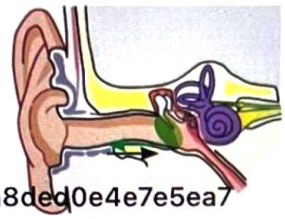

Evoked OAE :

measured after giving a sound

Sounds given are click sound or pure tone.

- Transient evoked OAE :
  Click sounds composed of many frequencies.
  Stimulates the whole of the organ of Corti.
  Screening for hearing loss in neonates.
- Distortion product :
  Pure tone sound composed of single frequency.
  Stimulates specific part of the organ of Corti.
  Specifically used to monitor hearing in noise trauma and ototoxicity.

Uses :

- Screen hearing in neonates.
  Not used in infants in ICU. The infants are screened by BERA (best test).
  Cannot assess the condition of the nerve.
- Monitor ototoxicity.
- Differentiate cochlear and retro-cochlear hearing loss.

Oto-acoustic emissions test



Active space

Leave Feedba

OAE absent

00:10:47

Due to obstruction in external ear, or abnormalities of the middle ear.
If absent, rule out external ear wax, meconium, middle ear pathology.
Defect in outer/ middle ear : ≥ 35 dB hearing loss then OAE usually absent.
The OAE report is given as pass for positive OAE and refer for negative, not fail.

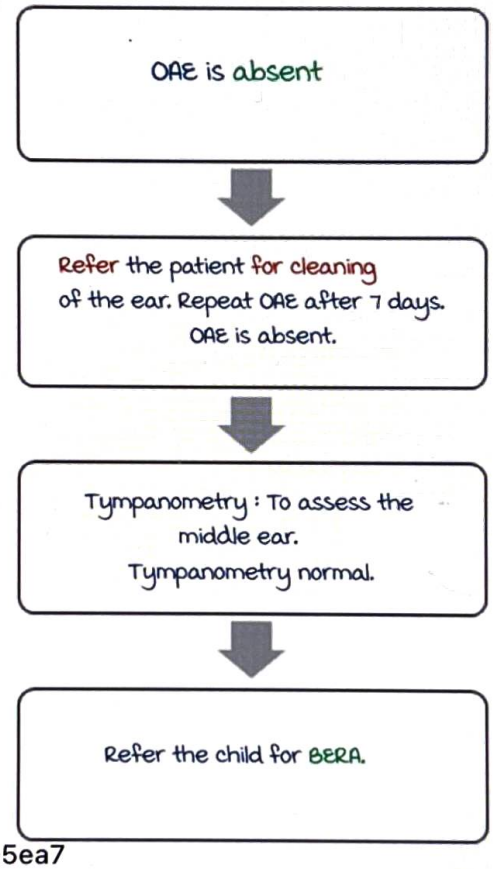

60c6b3eeaa8ded0e4e7e5ea7

Recruitment

00:15:33

Abnormal increase in loudness of loud sounds.
Indication of cochlear deafness.
Cochlea responsible for the fine tuning of loud sounds, especially the loud sounds.
Seen in meniere's disease.

Alternate Binaural Loudness Balance (ABLB) :
0 dB means the patient hears exactly same as the reference

Active space

Leave Feedback

considered normal.
It means 0 dB hearing loss.
Here :
The sound heard at 0 dB in left ear, is heard at 30 dB in right ear.
Similarly, the sound heard at 10 dB in left ear is heard at 40 dB in right ear.
So, the sound heard at 50 dB in left ear should have been heard in 80 dB at right ear. Instead, it is heard at 60 dB.

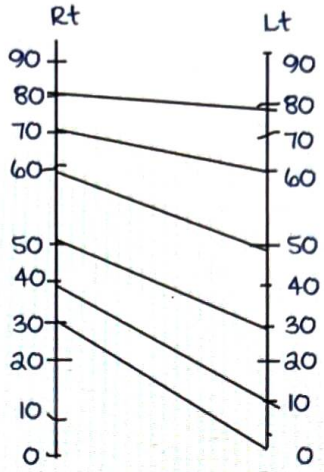

As the level of loudness increases, the hearing loss decreases to be equal to or better than the normal ear.

Short increment sensitivity testing (SISI) :
Sensitivity of recruiting ear to identify short increments in sound.
Even 1 dB increment can be identified.
70 to 100% increments are identified of the total (normal is 0 to 20%) : Signifies cochlear deafness.
kumarankitindia1@gmail.com
Indicates presence of recruitment.

Electrocochleography 00:22:38

Probe is passed through the tympanic membrane to rest on the promontory.
Invasive test.

Response to the sound given is picked by the probe as waves.
3 waves.

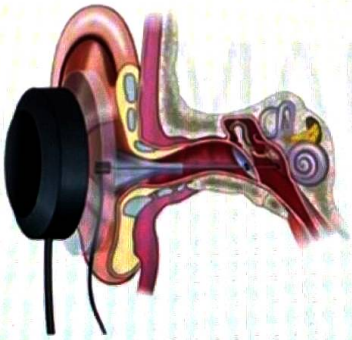

Probe

Active space

Leave Feedba

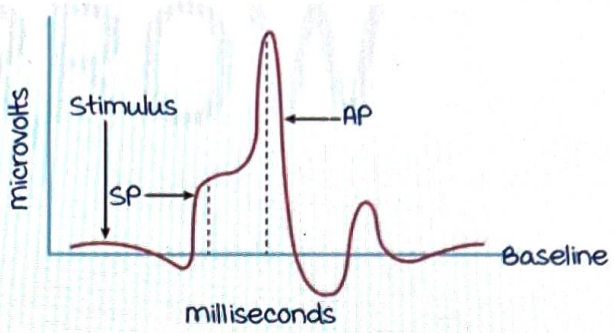

1st wave : Cochlear microphonic.
Produced by outer hair cells.
2nd wave : Summation potential (SP).
Produced by outer and inner hair cells.
3rd wave : Action potential (AP).
Potential of the nerve.
Measures the entire activity of the cochlea.
SP/AP → > 30% : Suggestive of meniere's disease.
SP/AP → > 45% : Diagnostic of meniere's disease.

60c6b3eeaa8ded0e4e7e5ea7

The increase in SP indicates the increase in activity of the hair cells, but without the corresponding increase in AP. This is because the increase in activity is due to irritative activity in cochlea.

Brainstem Evoked Response Audiometry (BERA)

00:28:07

Each part of auditory pathway produces a wave in response to the stimulus given.

Auditory pathway:
Cochlear nerve → Cochlear nuclei → Superior olivary complex → Lateral lemniscus → Inferior colliculus → Medial geniculate body.

BERA

Active space

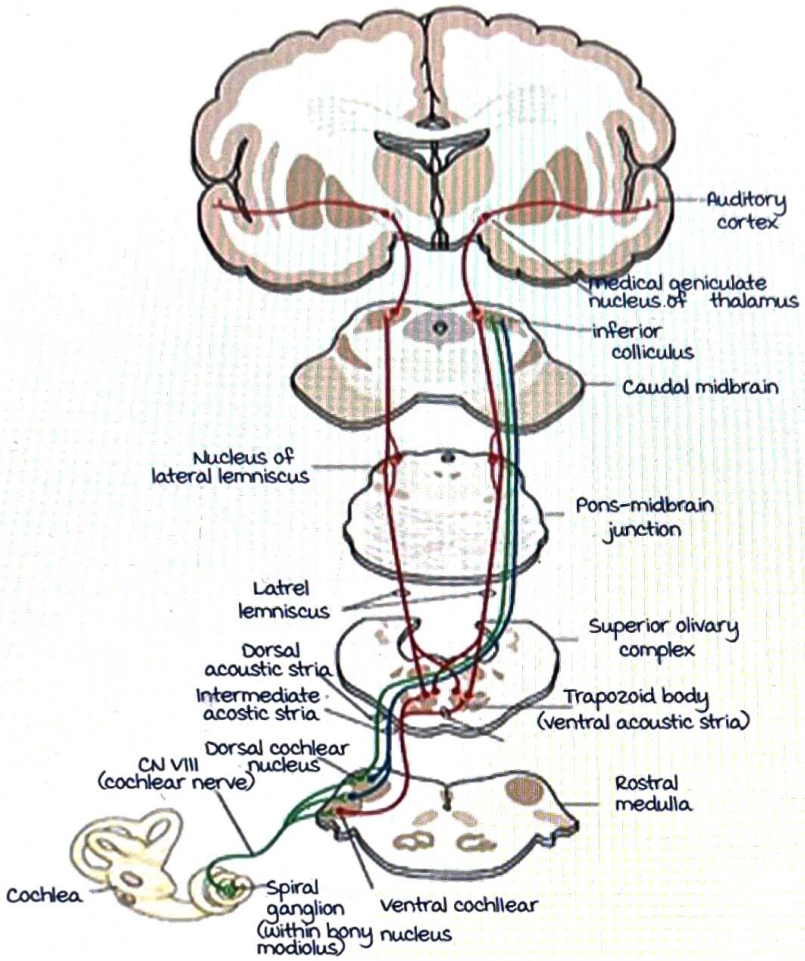

Auditory Pathway

Only tests the first 10 milliseconds of the transmission of sound.

7 waves are obtained.

5 waves are considered.

- Wave 1 : Distal part of cochlear nerve.
- Wave 2 : Proximal part of cochlear nerve.
- Wave 3 : Cochlear nucleus.
- Wave 4 : Superior olivary nucleus.
- Wave 5 : Lateral lemniscus.
  Largest, most consistent wave, always present.

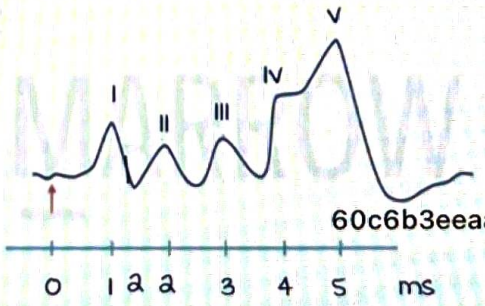

Waves occur at an interval of 1 ms.

60c6b3eeaa8ded0e4e7e5ea7
Active space

Leave Feedba

Uses of BERA

00:32:30

- If the first wave is delayed by 1 ms, that all the waves are subsequently then found after 1 ms : Defect is before wave 1, that is at the organ of Corti.
  Therefore, can differentiate between cochlear and retro-cochlear hearing loss.
- Best audiometric test for retro-cochlear hearing loss.
- Best audiometric test for acoustic neuroma.
  Sometimes only wave 5 is present, because the first wave would not appear due to circulatory compromise to cochlea.
  Inter-aural latency difference of wave 5 → > 0.2ms is diagnostic.
  Increased latency between wave 1 and 5.
- Best investigation for hearing loss in infants.
- Best for screening in ICU neonates.
- The loudness at which wave 5 appears, is the threshold of hearing.
- Used to identify malingering (objective test).

kumarankitindia1@gmail.com

Does not record hearing loss >80 to 90 dB.

Auditory Steady State Response (ASSR)

00:43:24

EEG activity is seen in response to sound.
It can measure hearing loss >80 to 90 dB.
Done with pure tones so it is frequency specific.

Speech audiometry :
Speech reception threshold : Threshold of hearing by spoken words. Loudness at which 50% of spoken words are identified is called the Speech reception threshold.

Discrimination score : Ability to discriminate the words.
0 to 20% score indicates retro-cochlear or neural hearing loss.

Active space

Leave Feedba

Speech audiogram

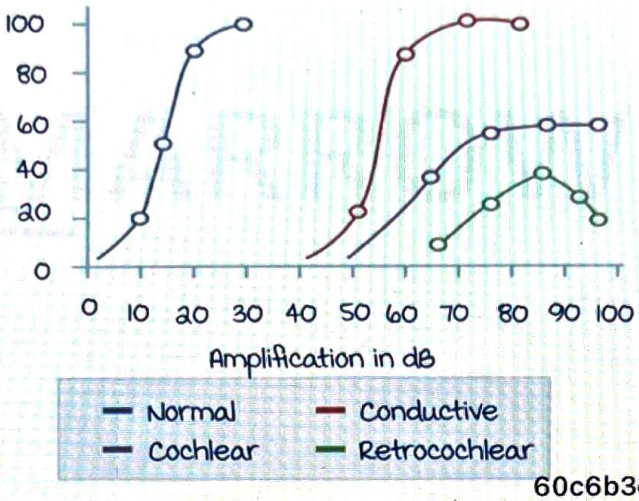

60c6b3eeaa8ded0e4e7e5ea7

Conductive hearing loss :

All words are identified once the loudness is increased.

Cochlear hearing loss :

Not able to identify all words despite increasing loudness.

Retro-cochlear hearing loss :

Cannot identify many words, and the number of words identified, decreases after a point.

Signifies nerve fatigue.

Roll over phenomenon.

Tests for non-organic hearing loss/ malingering

00:51:30

- BERA is the best test to diagnose malingering.
- Repeating pure tone audiometry.
- Compare the hearing threshold of any two tests. Should be ± 10 dB.
- Stenger's test :
  Whenever two tones are presented simultaneously, only the ear receiving the louder tone hears it.

Active space

Leave Feedba

VESTIBULAR PHYSIOLOGY

Maintenance of balance

00:01:34

The sensory input of the balancing system is collected from :

- Inner ear/ vestibular system.
- Vision.
- Proprioception.

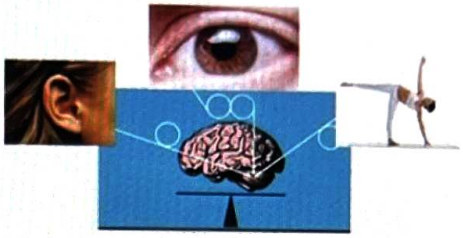

Vestibular system fixes the gaze and stabilizes the gait.

A blurred image is not formed on moving the head.

- movement of the head is sensed by the vestibular system.
- Sends impulses via vestibulo- ocular pathway.
- Resets the position of eye despite head movement, to maintain a steady gaze, so that the image forms on the fovea → Fixing the image of the object.

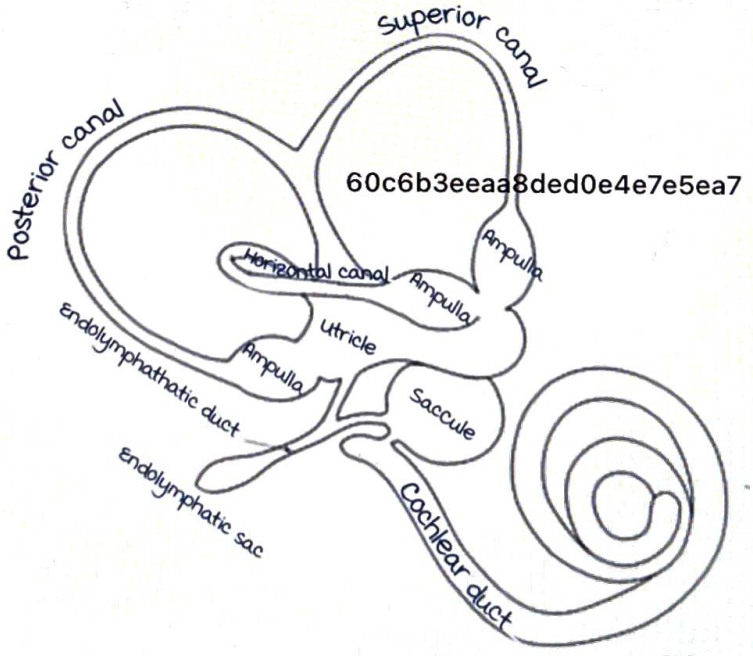

Posture of the body is maintained.

- Vestibular system senses the movement of the head and body.

Active space

- Sends impulses via its connections, vestibulo-spinal pathway, to trunk and limbs.
- Corrects the gait and posture.

Vestibular system comprises of :

- 3 semicircular canals.
- Utricle.
- Saccule.

60c6b3eeaa8ded0e4e7e5ea7

Rotational acceleration is sensed by the cristae of the semicircular canals.

Linear acceleration is sensed by the maculae of utricle and saccule.

Semicircular canals :

- Lateral/horizontal.
- Posterior.
- Superior/anterior.

} Vertical semi- circular canals.

Placed in different planes, at right angles to each other.

The horizontal semicircular canal is at a 30° angle above the horizontal.

The vertical semicircular canals are placed vertically.

- Superior/anterior semicircular canal is placed 45° anterior to the sagittal plane.
- Posterior semicircular canal is placed 45° posterior to the sagittal plane.

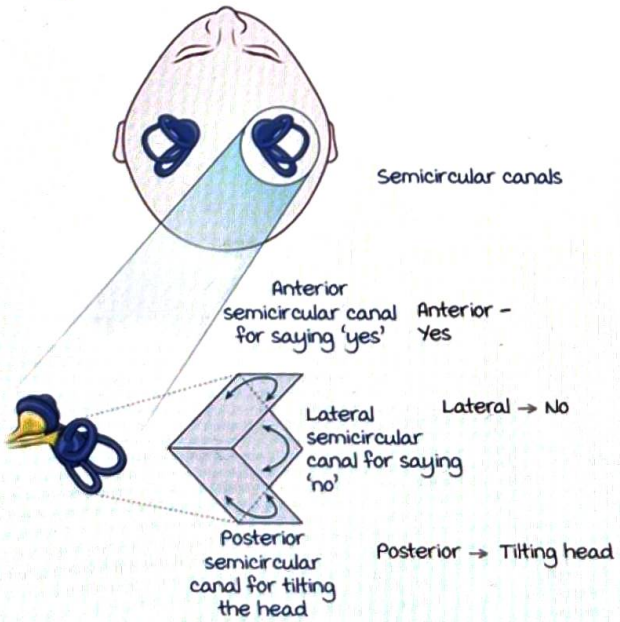

Active space

Leave Feedba

On turning the head towards one side, the vestibular system of that side gets activated.
When the head is looking straight, both vestibular systems are equally active.

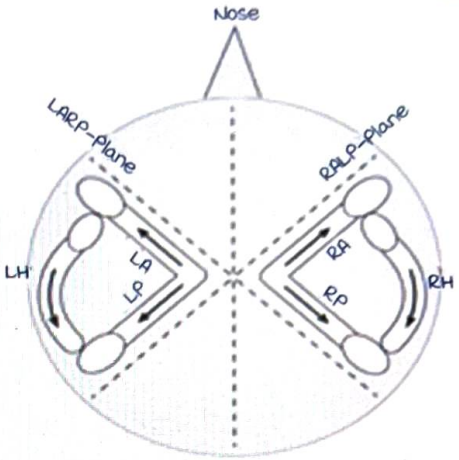

Both vestibular systems activated.

Right vestibular system activated (horizontal SCC)

Left vestibular system activated (horizontal SCC).

kumarankitindia1@gmail.com

Right anterior SCC activated

Right posterior SCC activated

Left anterior SCC activated

Left posterior SCC activated

Active space

Positional vertigo : most common cause of vertigo.

Left horizontal SCC activated.

- Otoliths from the maculae get dislodged and move into the semi-circular canals → Irritate the semicircular canal → Causes vertigo.
- Posterior semicircular canal : most commonly affected.
- Vertigo happens when the direction of that canal is engaged.
- Vertigo that lasts for a few seconds, seen with change in position of head.
- Management is by Epley maneuver : Brings the otolith back into the utricle.

Left posterior SCC activated.

Right horizontal SCC activated.

Rotational acceleration

60c6b3eeaa8ded0e4e7e5ea7 00:14:56

Physiology of hearing :
Sound moves through the EAC → Tympanic membrane → ossicular chain → Foot plate of stapes.

Opposite movement at oval and round windows → Opposite movement at scala vestibuli and scala tympani → Shearing action at the scala media i.e., the basilar membrane → Stimulation of organ of Corti → movement of hair cells → Release of neurotransmitters → Transmitted by cochlear nerve.

Active space

Leave Feedba

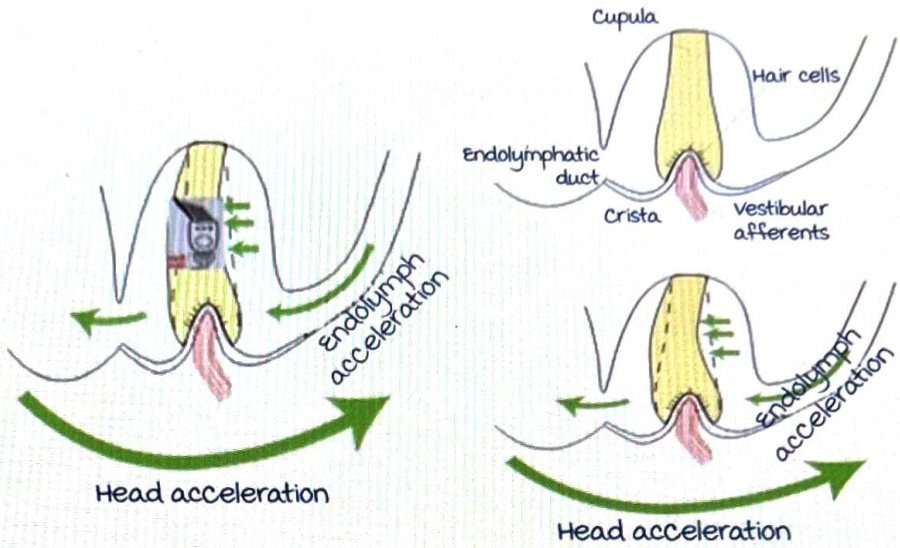

Assuming from the picture that the head is moving towards left.

- As bony labyrinth is embedded within the skull, it moves with the head to the left.
- The endolymph in the membranous labyrinth lags behind due to inertia, and moves initially relatively to the right.
- Endolymph exerts pressure on the cupula.
  One end of the semicircular canals is dilated : Cupula.
  Cupula contains the sensory end organ for rotation : Cristae.
- Pressure exerted on cupula → Stimulation of the hair cells within them.
- Stereocilia, present on the hair cells, are arranged in the ascending order of their height.
  Longest is Kinocilium.
- When all the cilia move towards the Kinocilium, it activates the cristae and release of neurotransmitters.

60c6b3eeaa8ded0e4e7e5ea7

At rest, both vestibular systems are equally active.
In the side activated :

- The cilia moves towards the Kinocilium.
- Activation of cristae.
- Release of neurotransmitters.

In the opposite side :

- Cilia move away from the Kinocilium.
- Decreased discharge of neurotransmitter.

Active space

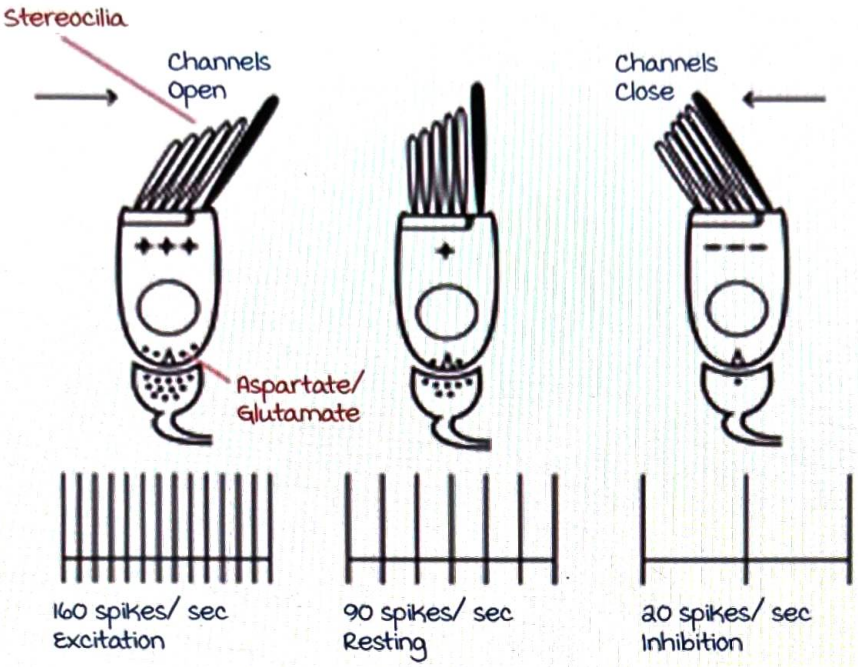

Ewald's second law :

Ampullopetal endolymphatic flow produces a stronger response than ampullofugal flow in the horizontal canal.

Ewald's third law :

Ampullofugal flow produces a stronger response than Ampullopetal flow in the vertical canals, i.e., superior and posterior semi-circular canals.

In the horizontal semicircular canal :

- Kinocilium is towards the utricle.
- movement of stereocilia towards the utricle is stimulatory.
- This movement is utriculopetal.
- Since the ampulla is present towards utricle, it can be said it is ampullopetal.

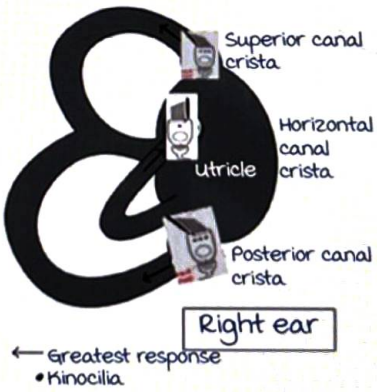

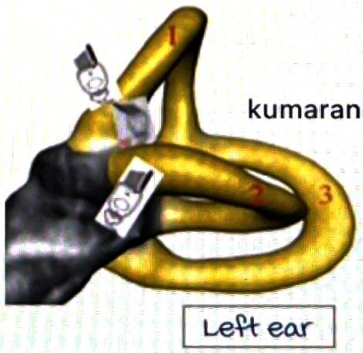

In the vertical semicircular canals :

- Kinocilium is placed away from the utricle.

kumarankitindia1@gmail.com

Active space

Leave Feedba

- movement of cilia away from the utricle/ ampulla is stimulatory.
- Utriculofugal/ampullofugal movement of endolymph is stimulatory here.

Utriculopetal close to ground : Horizontal semicircular canal.
Utriculo/ ampullofugal away from the ground : Posterior and anterior semicircular canal.

Linear acceleration 00:29:22

Sensed by maculae in the utricle and saccule.

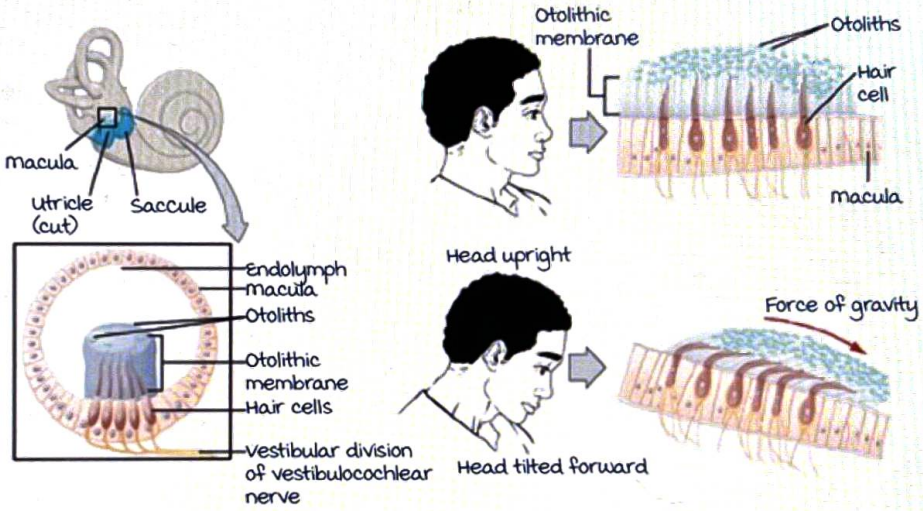

Otolith : Calcium carbonate crystals on top of the hair cells in the maculae.
Linear acceleration is sensed when the otoliths move with gravity → Shearing action on hair cells → moves towards or away from the Kinocilium → Increases or decreases the rate of discharge.

60c6b3eeaa8ded0e4e7e5ea7

In case of vertical linear acceleration :
The maculae of utricle and saccule are not placed in the same plane.
Maculae of utricle → Horizontal plane.
Maculae of saccule → Vertical plane.
Therefore, while going up or down in a lift, the maculae of saccule is activated.

Active space

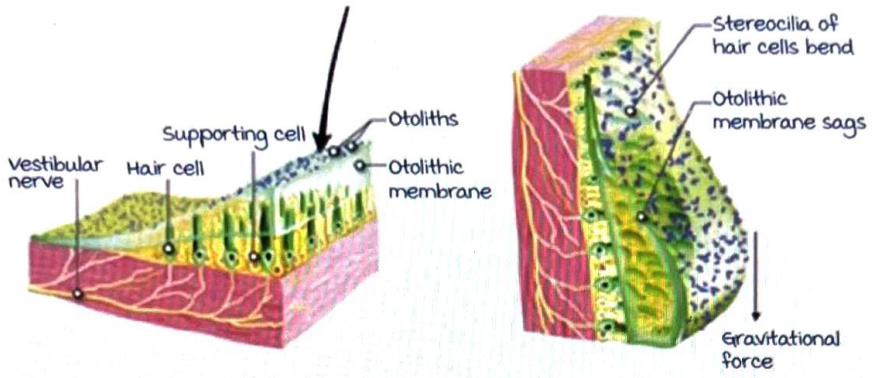

Utricle and Saccule

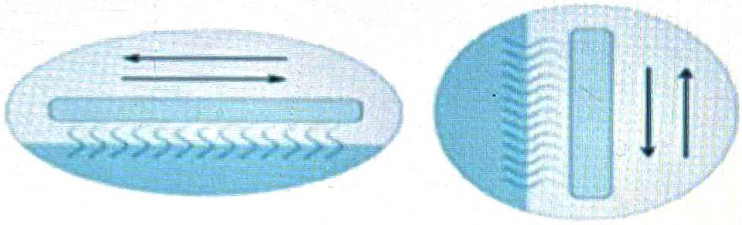

60c6b3eeaa8ded0e4e7e5ea7

Vestibular reflexes 00:31:33

Inferior vestibular nerve is formed by :
Nerve from saccule.
Nerve from posterior semicircular canal via the singular nerve.

Superior vestibular nerve is formed by nerves from :
Superior semicircular canal.
Horizontal semicircular canal.
Utricle.

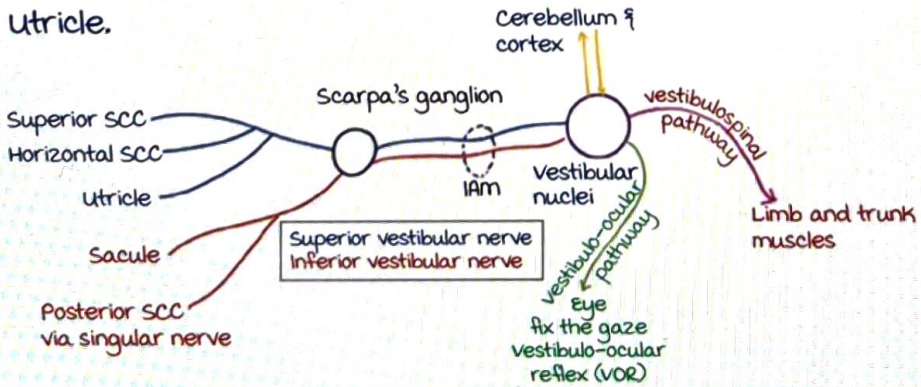

Superior and inferior vestibular nerves go to the Scarpa's ganglion : Vestibular nerve ganglion.
They exit the inner ear via internal acoustic meatus as separate nerves, to the vestibular nuclei.

Active space

Leave Feedback

From the vestibular nuclei :

- Impulses to eye via vestibulo-ocular pathway.
  Fix the gaze.
  Vestibulo-ocular reflex is responsible.
  Can be tested to assess the functioning of the vestibular system.
- Impulses to limb & trunk muscles via vestibulospinal pathway.
- To and fro connections with cerebellum and cortex.

Vestibular system

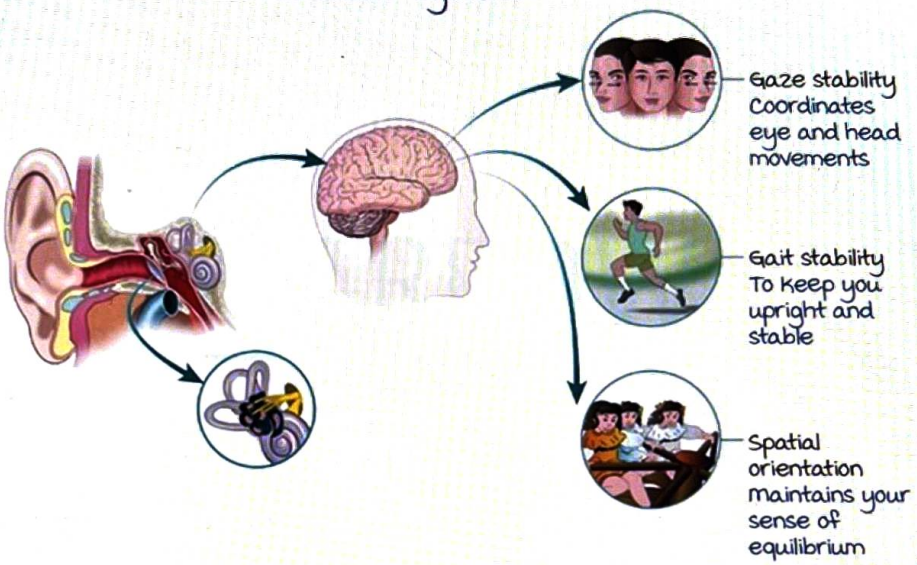

kumarankitindia1@gmail.com

Nystagmus

00:39:30

Ewald's first law :

- The axis of nystagmus parallels the anatomical axis of the semicircular canal that generated it.
- Abnormality in the vestibulo- ocular pathway leads to an abnormal oscillatory movement of the eye, that is nystagmus.

Plane of the nystagmus will be along the plane of the involved semicircular canal.

- Abnormality in horizontal semicircular canal causes horizontal nystagmus.
- Abnormality in vertical semicircular canal causes vertical nystagmus.

Involvement of vestibular canal also adds tortional component to the nystagmus.

Active space

95
Leave Feedba

APPROACH TO VERTIGO AND VESTIBULAR FUNCTION TESTS

Vertigo

00:02:48

Sense of spinning of oneself or the surrounding.
When a patient comes with vertigo, the first thing to be ruled out is positional vertigo or BPPV (Benign paroxysmal positional vertigo).

Otolith in posterior semicircular canal

Benign paroxysmal positional vertigo (BPPV)

00:03:42

Paroxysmal episodes of vertigo occurring with change in position.
m/C cause of vertigo.
The ampulla of posterior semicircular canal is the lower most so that is where the otolith gets dislodged very easily.

60c6b3eeaa8ded0e4e7e5ea7

Pathophysiology :

Otoliths dislodge from utricle into the semicircular canals : Posterior semicircular canal > Horizontal SC > Superior SC.

↓

Otoliths irritate the endolymph.

↓

Otoliths (Calcium carbonate crystals) settle down with gravity.

↓

Relief of symptoms till the patient changes head posture again.

↓

Episodic vertigo on change of head position.

Active space

Leave Feedba

Whenever the patient positions his/her head in a particular direction, the semicircular canal gets activated, and if an otolith is present, the patient experiences vertigo.

Dix-Hallpike manoeuvre 00:08:12

Dix-Hallpike manoeuvre is done for diagnosis of vertical canal BPPV (Posterior and superior SCC).

Dix hall pike manoeuvre (for right posterior SCC)

The head is turned towards right and posteriorly so we are testing the right posterior SCC.

Horizontal semicircular canal BPPV 00:09:00

We can test the horizontal semicircular canal by just placing the head in supine position and turning the head to that side called the supine roll test.

Steps :

1. Patient is supine and head elevated by 30°.
2. Head turned to the right side.
3. Head turned straight.
4. Head turned to the left side.

Positive test : Horizontal nystagmus with torsion towards the affected side.

Supine roll test right side

Supine roll test left side

Active space

The moment the patient starts having nystagmus, he/she will start feeling vertiginous.

For

- Horizontal semicircular canal BPPV : Horizontal nystagmus with torsion.
- Right posterior SCC BPPV : Vertical nystagmus with torsion

Peripheral nystagmus characteristics 00:11:55

- Latency : 10-20 sec.
- Duration : 1 to 1.5 minutes.
- Fatiguable (Disappears with repetition).
- Vertical canals (post., sup.) Horizontal canals.
- Torsion present.
- Disappears with optic fixation (Prevented by Frenzel glasses).
- Direction of nystagmus is always fixed which is the fast component.

Frenzel glasses

kumarankitindia1@gmail.com

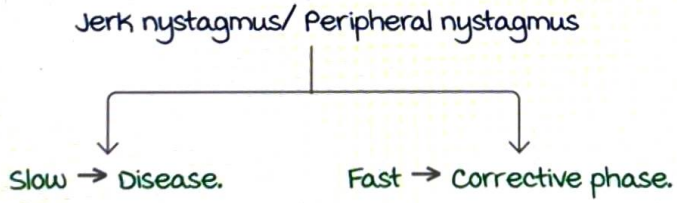

The labyrinth tries to push the eye in the opposite direction. So hyperactive labyrinth will push the eye to opposite direction slowly (slow component).
And it will then be corrected by the central regulatory system in the brain (fast component).

The fast component is always towards the more active ear.
Hyperactive labyrinth : Fast component is towards the diseased side. (Eg : BPPV).
Hypoactive labyrinth : Fast component is towards the normal side. (Eg : meniere's disease).

Active space

Leave Feedba

Vestibular neuritis 00:38:50

Acute infection (viral) of the vestibular nerve compromising

- Superior vestibular nerve.
- Inferior vestibular nerve.
- main trunk of vestibular nerve.

Clinical presentation : Vertigo alone ; Without hearing loss.

- Acute onset vertigo.

	Peripheral	Central
	Vestibular neuritis.	Cerebellar stroke.
History	No cranial nerve involvement, hearing loss(menieres), tinnitus.	Cranial nerve involvement, Dysarthria, Ataxia, dipolopia, motor weakness, headache.
Torsion	Horizontal + Torsional component.	Pure Horizontal / Pure torsional/ Pure vertical component.
Optic fixation	Disappears.	Doesn't disappear.
Direction	Fixed.	Direction changing.

Complete hypofunction of labyrinth 00:48:02

Complete hypofunction of labyrinth causes horizontal nystagmus.

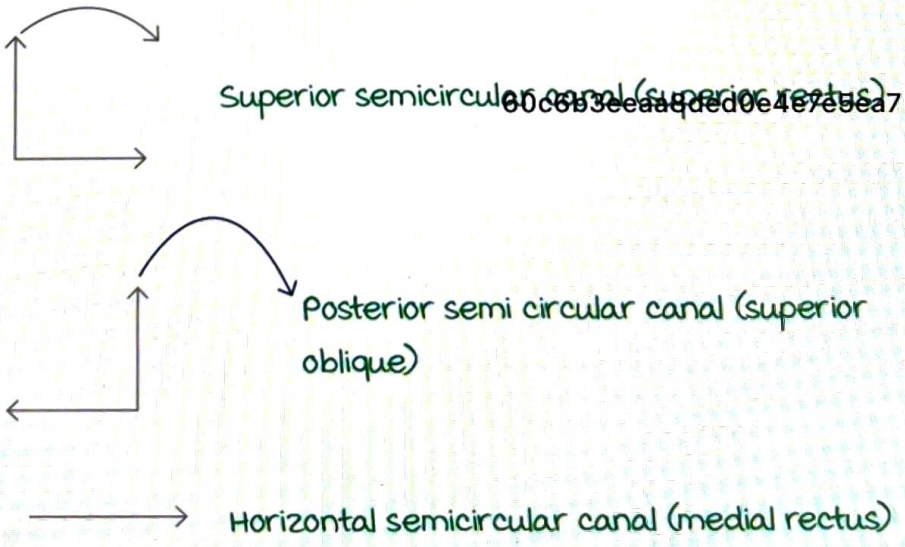

As the movements supported by superior semicircular canal and posterior semi circular canal are opposing each other so we are left with horizontal movement and intorsion.

Active space

Head impulse test 00:54:56

After sudden movements of head check if the patient is able to fix the gaze or not.
The vestibulo-ocular- reflex is assesed through this test.

Head impulse test

Abnormality of labyrinth will lead to an abnormal vestibulo ocular reflex leading to saccades.

Saccades → Rapid, ballistic movements of the eyes that abruptly try to come back the point of fixation/gaze.
Head impulse test is not a very sensitive test.

Caloric test 01:00:59

AKA Fitzgerald-Hallpike manoeuvre / Bithermal caloric test.
The lateral semi circular canal is being tested here with 30° head raised (maximum response in vertical position).
Stimulation of inner ear with hot or cold water.
Temperature used is (+/-) 7° C of body temperature (37° C).

Caloric test

- Hot water (44° C) : makes labyrinth hyperactive, nystagmus towards same side.
- Cold water (30° C) : makes labyrinth hypoactive, nystagmus towards opposite side.

60c6b3eeaa8ded0e4e7e5ea7

Test each labyrinth separately.
If labyrinth is dead or hypo functional : No response/ decreased response.
Gap between cold and warm water should be a minimum of (5-8) minutes.

Active space

Leave Feedba

To confirm if labyrinth is dead,

Kobrak test : Ice cold water is used.

All characteristics of peripheral nystagmus is present.

Cold air caloric test : Dundas grant tube.

It can be used to check brain stem integrity of patients in coma.

Dundas grant tube

Patient need not respond hence making it a good test to check brain stem integrity of patients in coma.

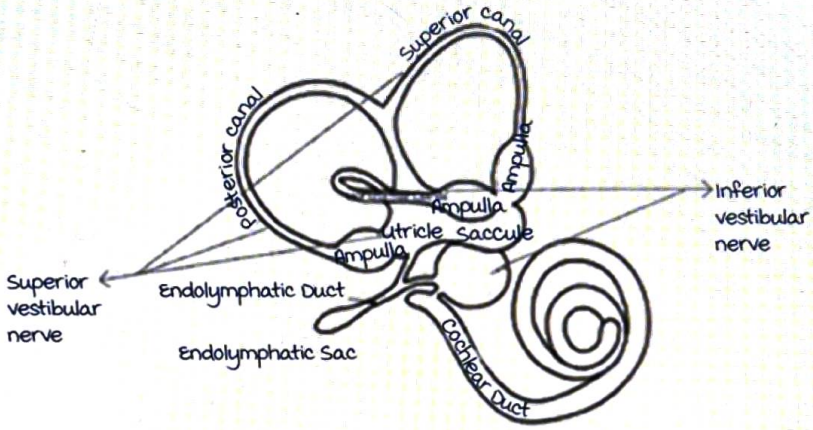

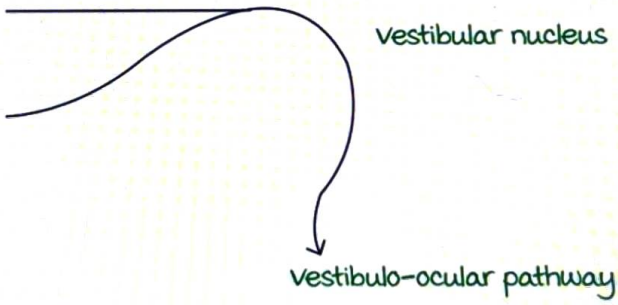

Fistula test

01:16:26

On pressing the tragus repeatedly, the pressure changes get transmitted from outer to middle ear but never to inner ear.

Siegel Pneumatic Speculum

kumarankitindia1@gmail.com

Unless there is a fistula in the medial wall of the middle ear/ fenestration operation.

Active space

Symptoms : Vertigo on external pressure changes : Coughing , sneezing, lifting heavy weights.

Positive fistula test : Fistula in the medial wall (promontory, oval window, round widow, lateral SCC), fenestration operation.

False positive fistula test : Hennebert's sign.
Even if fistula is absent (in medial wall), fistula test can be positive. Seen in conditions where the utricle and saccule is dilated (meniere's) or the foot plate of stapes is hypermobile (congenital Syphilis) , Superior semicircular canal dehiscence.

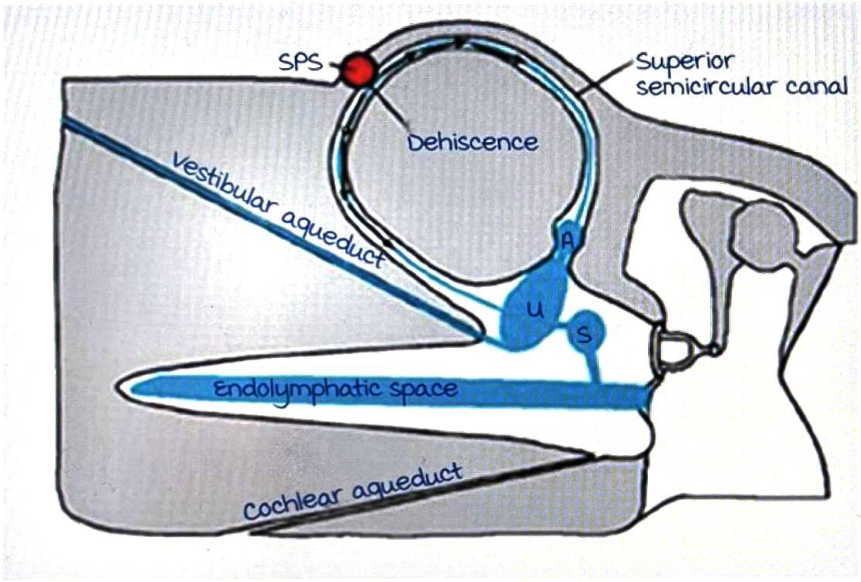

Superior semicircular canal dehiscence

False negative fistula test :

- Cholesteatoma covering the fistula.
- Dead labyrinth.

60c6b3eeaa8ded0e4e7e5ea7

Tullios phenomena 01:26:44

It is mediated by inferior vestibular nerve.
Vertigo on loud sounds.

- Fistula on medial wall.
- Congenital Syphilis.
- Superior semicircular canal dehiscence.
- meniere's disease.

Active space

Leave Feedba

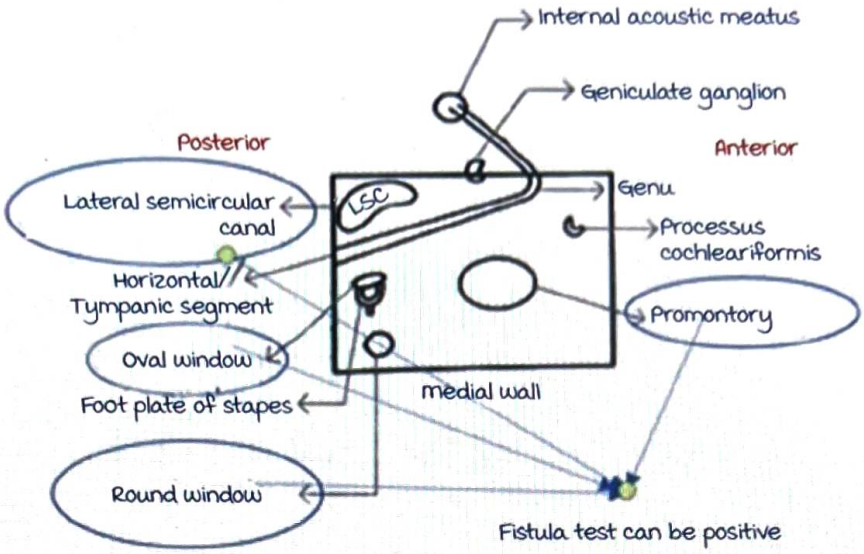

Cervical vestibular evoked myogenic potential (CVEMP)

01:31:14

Relaxation of the sternocleidomastoid along with blinking of the eye in response to loud sounds is called Cervical vestibular evoked myogenic potential (CVEMP) & ocular vestibular evoked myogenic potential (OVEMP).

Vestibular Evoked Myogenic Potential (VEMP) Test

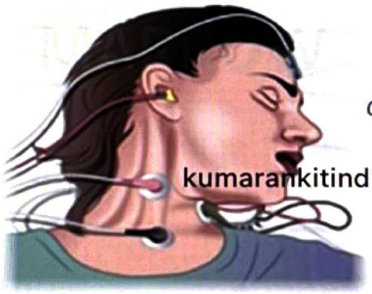

CVEMP

kumarankitindia1@gmail.com

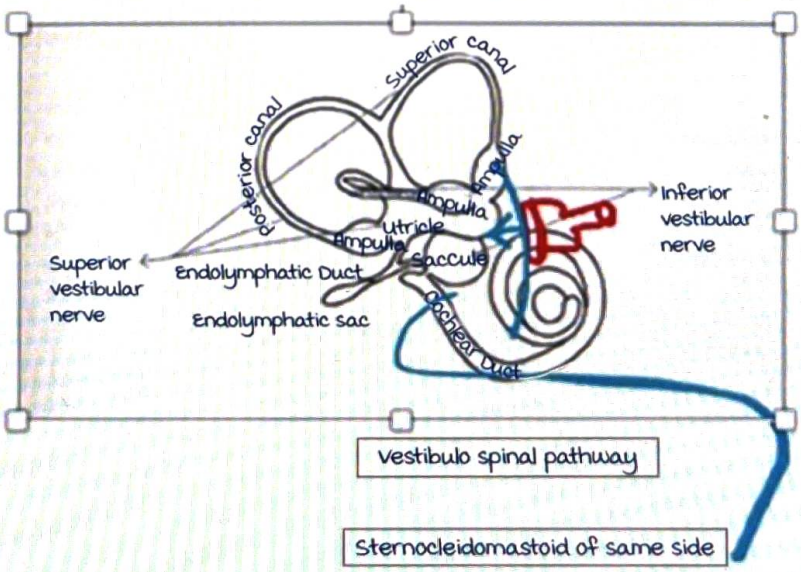

Active space

Vestibulo-spinal pathway :

Loud sound → Stimulates saccule → Inferior vestibular nerve → Sternocleidomastoid of same side (sudden relaxation).

Loud sound → Stimulates utricle → Vestibulo-ocular pathway Eye muscles of opposite side.

CVEMP : Stimulus through inferior vestibular nerve to SCM.
OVEMP : Stimulus through utricle to eyes.

60c6b3eeaa8ded0e4e7e5ea7

VEMP is the test for vestibulospinal pathway.

Unterberger test / Fukudas stepping test 01:34:40

It is also the test for vestibulospinal pathway.
Patient is asked to close his eyes, arms extended and step in same place at 90 steps/min.
Patients moves towards the side of lesion.
Hypoactive labyrinth : Normal side labyrinth will make the body deviate toward the weaker side (> 70° to right and > 50° to left).

Active space

Leave Feedba

DISEASES OF PINNA

Congenital malformations

00:01:16

Pinna develops from 1st and 2nd pharyngeal arches.
Tragus develops from 1st pharyngeal arch. Rest of the pinna develops from 2nd pharyngeal arch.
Pinna develops from 6 hillocks which fuse to form a single elastic cartilage.

Preauricular sinus :

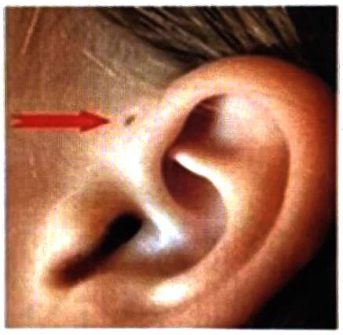

kumarankitindia1@gmail.com

- Fusion defect of auricular tubercles.
- most common site : Root of helix.
- If recurrent discharge/pain → Excision can be done.

Preauricular skin tags :

Active space

Fusion defect of auricular tubercles.

Anotia → Absent pinna.

Microtia → Malformed small pinna.

Stahl ear (spock, elf ear) : Characterized by an accessory third crus in the ear cartilage.

Stahi ear

60c6b3eeaa8ded0e4e7e5ea7

Otoplasty/Pinnaplasty : Cosmetic surgery for changing the size, shape or position of pinna.

Meatoplasty : Widening of the external acoustic meatus.

Reconstruction of pinna is not done before 6 years of age as rib cartilage graft is required.

Autologous costal cartilage is used for reconstruction.

Cpchlear implant is not given as Organ of corti is normal.

Active space

Leave Feedba

Pinna Reconstruction Cartilage Graft

Bone anchored hearing aid (BAHA) : Hearing aid anchored to the bone behind the pinna.
Used for congenital anomalies of the external ear.

Skin on lateral side is very tightly attached to the underlying perichondrium. If there is an infection, it directly spreads to perichondrium. As pinna is a single cartilage, infection spreads to whole pinna.

Hematoma :

- most common cause of hematoma is trauma.
- Injury of the pinna causes shearing action of the skin over the cartilage and perichondrium → Blood vessels rupture → Collection of blood just below the perichondrium → Hematoma.
- management : Aspiration and Contour dressing is done after aspiration to prevent recollection of blood. If it does not resolve, then incision and drainage is done.

60c6b3eeaa8ded0e4e7e5ea7

Active space

Cauliflower ear – treatment

metal disc and magnet in situ

Hematoma formation

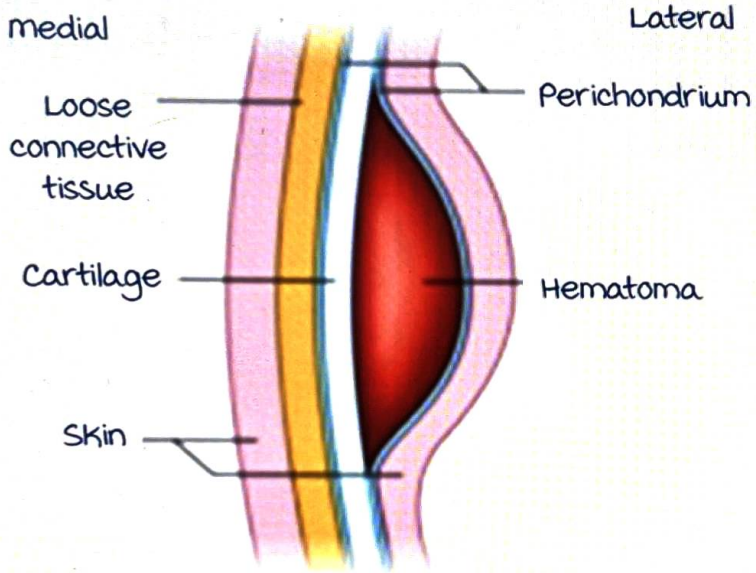

If drainage is not done immediately, chondroblast invasion and cartilage proliferation occurs inside the hematoma, giving rise to cauliflower appearance of pinna : Cauliflower ear (organized hematoma of pinna). It is also known as Boxers/wrestler's ear.

0c6b3eaaa8ded0e4e7e5ea7

Active space

Leave Feedba

management of trauma to pinna :

If pinna is avulsed or separated due to trauma, wash the pinna thoroughly and reattach the avulsed pinna.

Best method → microvascular anastomosis.

If skin over separated part of pinna is totally separated, wash the pinna properly, debride the necrosed part and reattach. Cartilage is attached first, and the exposed part is covered using a retroauricular skin pocket : Pocket method.

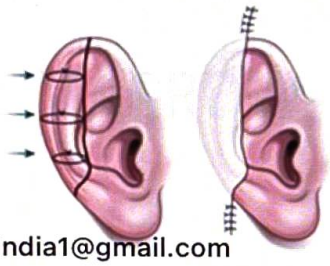

kumarankitindia1@gmail.com

Perichondritis of pinna

00:13:40

- Infection of cartilage : Perichondritis
- Typical appearance : Cartilaginous part is red, and lobule is spared.
- It is common in pinna as perichondrium is close to overlying skin → If there is an infection, it directly spreads to perichondrium.

- Most common organism : Pseudomonas.
- Management : Antipseudomonal antibiotics : Oral Ciprofloxacin.
- Pinna is sensitive to changes in temperature, pressure.

Active space

Leave Feedba

Lempert incision :

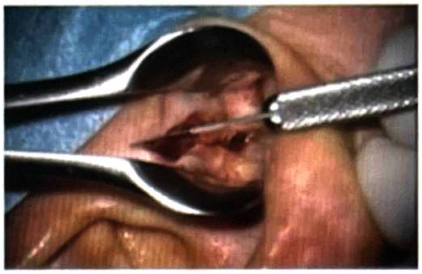

Incision on the cartilage of pinna is not given whenever ear canal/tympanic membrane/ middle ear is approached through the external acoustic meatus due to possibility of perichondritis. Incision is given at incisura terminalis → Known as Lempert incision.

Chondrodermatitis nodularis helicis – Winkler disease :

- Due to very less subcutaneous tissue, pinna cartilage is very sensitive to pressure. If prolonged pressure is put on pinna (hard pillow), painful nodules develop at the area of prominence (helix, antihelix). It is known as chondrodermatitis nodular helicis (Winkler disease).
- It is usually seen in middle aged to elderly males. Biopsy should be taken to rule out basal cell carcinoma and squamous cell carcinoma of the skin.
- Management : Relieve pressure. If no improvement, then excision.

60c6b3eeaa8ded0e4e7e5ea7

Keloid :

Cause : Abnormal healing following trauma.
Genetic and environmental predisposition. Seen in Asians and Africans (dark skin).

Excessive proliferation of fibroblasts and collagen. Scar tissue expands above and beyond the margins of wound.

Active space

Leave Feedbac

On palpation : Firm rubbery nodule.

Management :

First line : Steroid injections.

Most effective : Excision followed by steroid injections.

Others : Radiotherapy, cryotherapy, laser.

Hypertrophied scar

Keloid

Sebaceous cyst :

- Soft compressible nodule.
- Commonly occurs at posterior part of pinna.
- Punctum is seen.
- Management : Excision.

Posterior part of pinna is rich in sebaceous glands

60c6b3eeaa8ded0e4e7e5ea7

Active space

111
Leave Feedba

DISEASES OF EXTERNAL AUDITORY CANAL

Anatomy of EAC

00:00:58

External auditory canal :

Outer one third : Cartilaginous (8 mm).

Inner two third : Bony (16 mm).

Developmental defect in the bony part of EAC : Foramen of Huschke.

Developmental defect in the cartilaginous part of EAC : Foramen of Santorini.

Narrowest part of EAC : Isthmus (5-6 mm lateral to tympanic membrane).

Parotitis can become otitis externa through fissures of Santorini.

To visualize tympanic membrane, EAC is straightened by pulling pinna upwards and backwards.

Nerves supplying EAC : Auriculo-temporal nerve.

Auricular branch of vagus (Arnold's nerve/Alderman's nerve).

Otitis externa :

Diseases of external auditory canal are known as otitis externa.

Presents with :

- Hearing loss.
- Pain in the ear (external or middle ear infections).

Furuncle :

Localized swelling of the EAC in cartilaginous part.

Clinical features :

- Very severe pain.
- Aggravated by movements of pinna (jaw movements).

Active space

Leave Feedbac

Most common organism involved :
Staphylococcus aureus.
Diagnosis :
mostly clinical.
Positive Tragal sign : Pressure on the tragus elicits pain.
Treatment :

- Antibiotics against staphylococcus.
- 10% ichthamol glycerin pack.
- Incision and drainage.

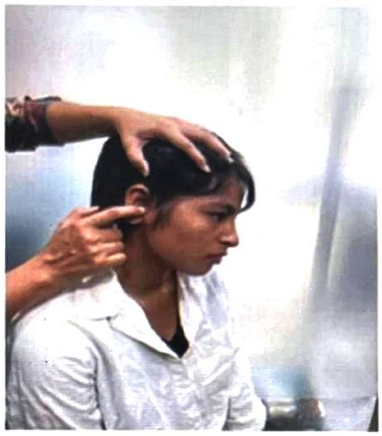

Tragal sign

Recurrent furunculosis : Investigate for diabetes.

Diffuse otitis externa

00:09:31

Also known as swimmer's ear/tropical ear.
Occurs due to itching, which leads to abrasions and infections.
Causative organism :
Pseudomonas.
Management :

- Aural toileting.
- Antibiotics : Ciprofloxacin.
  Topical as Ear drops.
  Systemic as oral antibiotics.

60c6b3eeaa8ded0e4e7e5ea7

EAC filled with discharge.

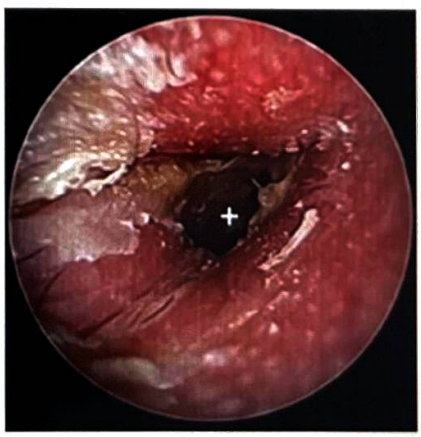

Active space

Malignant otitis externa :

Mimics malignancy, hence the name.

Causative organism : Pseudomonas.

Occurs in immunocompromised individuals (steroid therapy, diabetes).

Presents with severe excruciating pain.

O/E : Necrosis, granulations, ear discharge are seen.

Nerves involved : VII, IX, X and XI.

Most common : VII leading to facial nerve palsy.

Also known as skull base osteomyelitis.

Early diagnosis : Tc-99 bone scan.

Treatment :

- Aural toilet : Debridement of dirty tissue.
- Antibiotics : Ciprofloxacin.
  Alternative: Third generation cephalosporins (ceftazidime, cefoperazone).
  Newer penicillins (piperacillin).
  Antibiotic therapy for 6 weeks.

Resolution assessed by Gallium/Indium scan (shows inflammatory activity).

ESR is an easier alternative to assess effectiveness of therapy.

Otitis externa :

90% : Bacterial.

Most common organism involved : Pseudomonas.

10% : Fungal (Otomycosis).

Otomycosis

00:24:53

kumarankitindia1@gmail.com

Most common organism : Aspergillus niger.
Wet newspaper appearance.

2nd most common organism : Candida.
Cotton ball appearance.

Active space

Leave Feedbac

Management :

- Aural toilet.
- Local antifungal ear drops.

Herpes zoster oticus :

Presents with very severe ear pain.

O/E : presence of vesicles.

Ramsay hunt syndrome :

Herpes zoster + facial nerve palsy.

Management : Steroids and antivirals.

Earwax :

Function : Lubrication and protection.

Produced by ceruminous glands (apocrine glands → exocrine glands) + sebum + hair follicle.

Rx : Self cleansing.

Comes out by jaw movements.

Management of impacted soft wax : Syringing.

Water temperature for syringing : Body temperature.

Direction : Postero superior.

Syringing

60c6b3eeaa8ded0e4e7e5ea7

Active space

Leave Feedback

Contraindications :

- Perforation of tympanic membrane.
- Foreign body (Battery).

Complications :

- vertigo.
- Tympanic membrane rupture.
- Reactivation of otitis media.

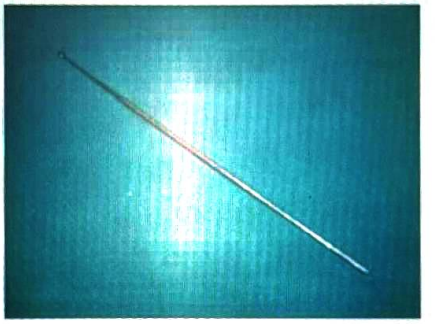

Jobson horne probe

Jobson horne probe with ring curette :

One end : Ring shaped.

Go behind wax and pull it out.

Other end : Serrated.

To roll cotton over it and used to clean discharge.

60c6b3eeaa8ded0e4e7e5ea7

Flaky wax can be pulled out using forceps.

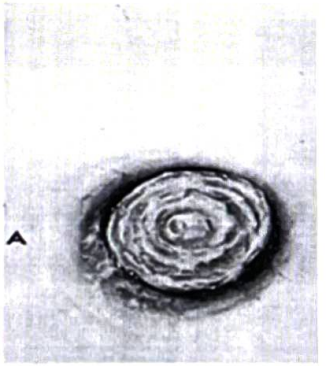

Keratosis obturans

00:35:28

Cause : Abnormal epithelial migration resulting in the accumulation of shedded skin inside external auditory canal.

The collection will have a laminar onion skin appearance.

Presentation : Severe pain with ear block/hearing loss.

Facial nerve palsy is also seen.

EAC appearance : Ballooning of external auditory canal.

Active space

Leave Feedba

Association with other conditions :

- Sinusitis.
- Bronchiectasis.

Management : Removal under local anaesthesia.

kumarankitindia1@gmail.com

Active space

117
Leave Feedba

CONDITIONS OF TYMPANIC MEMBRANE

Features of tympanic membrane 00:02:16

It is the common wall between external ear and middle ear.
It can be affected both by conditions of external ear and the middle ear.
It acts as a window to the middle ear. Its appearance gives a clue for the diagnosis of most of the conditions of the middle ear.

Normal tympanic membrane : Handle of malleus points outwardly towards the same side of the ear. And it points anteriorly.
The given image is of the left tympanic membrane.

Left tympanic membrane

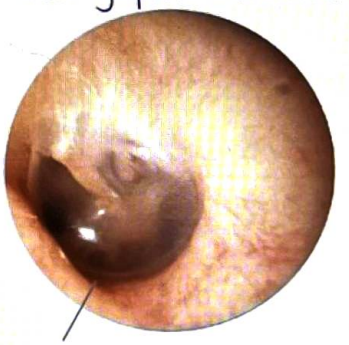

Anterior meatal recess

Cone of light is in the anterior inferior quadrant of the tympanic membrane.
Narrowing of the external auditory canal is seen as a bulge.
Beyond the narrowing is a dilatation called anterior meatal recess where pus can be collected.
Normal colour of tympanic membrane is pearly white or pearly grey and is translucent.

Traumatic perforation of tympanic membrane 00:05:06

Blow to ear or sudden pressure changes (during flights).
History following trauma :

60c6b3eeaa8ded0e4e7e5ea7

- Very severe pain.
- Sudden blocked feeling in ear.
- Ringing in the ear.
- Blood in the ear.

Active space

Leave Feedba

Management :

If not infected :

- Conservative management.
- The perforation heals by itself.
- Prevention of infection, Keep it dry.
- Infection is usually by water or from Eustachian tube in pharyngitis.
- Healing time is around 3 months.

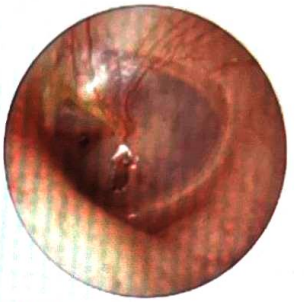

Tympanic membrane perforation & blood clot.

60c6b3eeaa8ded0e4e7e5ea7

If infected :

- If discharge is seen, start on antibiotics.
- Local + systemic antibiotics.
- Healing time is around 3 months after resolution of infection.

If the perforation is large :

- Paper patch method : Patch of very thin paper is glued over the perforation to accelerate healing.
- It acts as a scaffold below which the tympanic membrane grows.

Healed perforation of tympanic membrane

00:08:29

- Very thin layer of tympanic membrane.
- It has healed by itself.
- It heals only by 2 layers.
- Outer epithelial and inner endothelial layers heals.
- Fibrous layer is missing.

Tympanosclerosis : Healed otitis media.

Active space

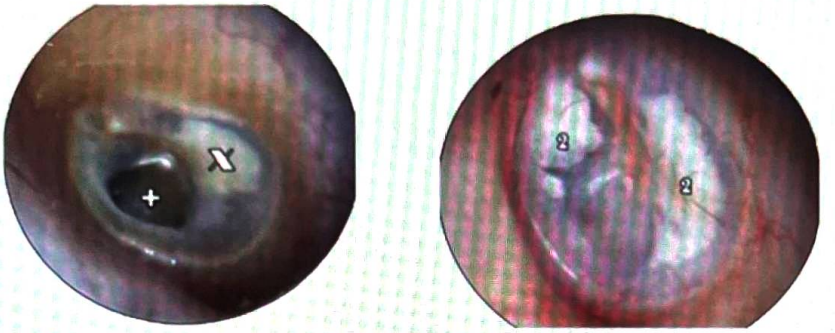

Tympanosclerosis

- Calcium deposition can happen while tympanic membrane heals by itself.
- Tympanosclerosis is calcium deposition in fibrous layer of tympanic membrane.
- Seen in healed chronic diseases of middle ear i.e. healed otitis media.
- Conservative management is treatment of choice as long as tympanic membrane is intact.

Tubercular otitis media :

kumarankitindia1@gmail.com

Tubercular otitis media

Otitis media is infection of the middle ear.
Primary infection from lungs reaches middle ear through the Eustachian tube while coughing out secretions.

Clinical features :

- Hearing loss (more than 40db) due to necrosis of ossicles.
- Painless.
- Foul smelling discharge due to erosion of walls of middle ear.

Active space

Leave Feedba

- most common complication facial nerve palsy due to erosions of walls of fallopian canal (covering of facial nerve).
- O/E : multiple perforations, pale granulations of tympanic membrane.

management is by ATT.

Bullous myringitis

00:13:23

- myringitis is inflammation of myring or tympanic
- membrane.
- Bulla is seen over tympanic membrane.
- Bulge only in specific parts.
- most common bacterial cause is pneumococcus.
- Others organisms include influenza virus, mycoplasma pneumonia.

60c6b3eeaa8ded0e4e7e5ea7

- Tympanic membrane appears congested.
- management is by local + systemic antibiotics.

In acute otitis media :

Bulge of the tympanic membrane is uniform.
most common bacterial cause is Pneumococcus.

Acute otitis media

Eustachian tube

00:15:05

Crucial for functioning of middle ear.
Responsible for ventilation of the middle ear.

Active space

Leave Feedback

Blockage leads to a negative middle ear pressure causing the tympanic membrane to retract.

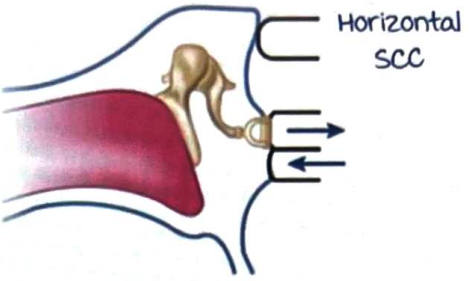

Both pars tensa and pars flaccida may get retracted.
more chronic the blockage of eustachian tube, the more severe is the degree of retraction.

Grading based on severity of retraction of tympanic membrane :

- Pars flaccida retraction has been graded by Tos.
  (Top : Pars Flaccida.)
- Pars tensa retraction is graded by Sade.

(Mnemonic : Sade is Sad, it is down : Pars Tensa.)

Sade stage I :
Retraction of the ear drum not in contact with incus.
Most common presentation of patients is in Sade stage I :

60c6b3eeaa8ded0e4e7e5ea7
Sade stage I

- Dull.
- Cone of light is distorted/absent.
- Handle of malleus : Foreshortened.
- Lateral process becomes prominent.
- Sickelling of anterior malleolar folds.

These features are seen in all other grades.

Sade stage II

Sade Stage II :

- Tympanic membrane is adhered to the incus or stapes, in the posterior part of the middle ear cavity.
- Retracted tympanic membrane touching the incus or stapes

Active space

Leave Feedbac

Sade Stage III – Atelectasis :

- Tympanic membrane touching the promontory.
- middle ear space obliterated.
- No air is available.
- Collapse of middle ear cavity is atelectasis of the middle ear.

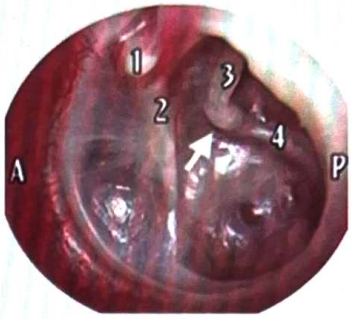

Sade stage III

Sade stage IV – Adhesive otitis media :

Tympanic membrane is adhered completely to the promontory.

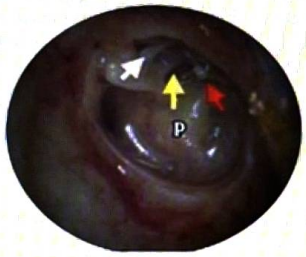

Sade stage IV

Tos classification 00:23:04

Scutum is bony wall which forms the lateral wall of the attic or the epitympanum, above pars flaccida.

kumarankitindia1@gmail.com

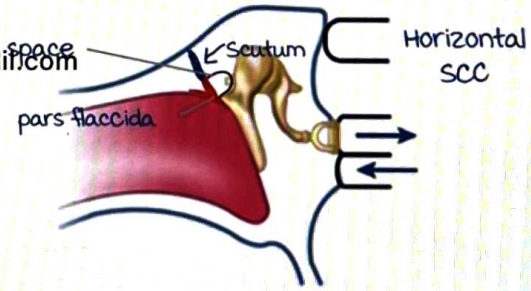

Tos stage I :

- Pars flaccida is retracted than normal but not adherent to the malleus.
- Pars flaccida enters Prussak space as it gets retracted medially.

Tos Stage I

Boundaries of the Prussak space :

- Medially : Neck of malleus.
- Laterally : Pars flaccida.
- Inferiorly : Lateral process of maleus.

Active space

Tos stage II :

- Retraction pocket is adherent to the neck of malleus.
- The full extent of the retraction pocket can be clearly seen.

Tos Stage II

Tos stage III :

- Part of the retraction pocket may be hidden.
- There may also be associated erosion of the outer attic wall (scutum).

Tos Stage III

Tos stage IV :

- Definite erosion of the outer attic wall with full extent of the retraction pocket not seen.

Tos Stage IV

60c6b3eeaa8ded0e4e7e5ea7

Active space

Leave Feedbac

ACUTE OTITIS MEDIA

60c6b3eeaa8ded0e4e7e5ea7

Aetiology of acute otitis media (AOM) 00:01:20

Acute infection of middle ear.
Due to Acute Pharyngitis.
Most common route → Eustachian tube.
Most common organism → Viral.
Usually super imposed by → Bacteria.
Most Common bacteria → Streptococcus pneumoniae (Aka Pneumococcus).

Stages of acute otitis media 00:03:48

- Stage 1 : Stage of Eustachian tube obstruction leading edema.
  Patient c/o blocked ear.
  O/E : Tympanic membrane slightly retracted.
- Stage 2 : Stage of Hyperaemia/ Pre-suppuration.
  middle ear gets filled with fluid.
  O/E : Hyperaemic tympanic membrane (TM)/ Cartwheel TM (diagnostic of AOM).
- Stage 3 : Stage of Suppuration.
  middle ear filled with fluid, exerts pressure on tympanic membrane which bulges and ruptures.
  O/E : Pus in external auditory canal.
  Pulsatile otorrhea /light house sign.
  (Important to differentiate from bullous myringitis).

Stage of Hyperemia
Cart wheel TM

Stage of suppuration

Active space

Leave Feedback

Management of AOM

00:09:05

- Antibiotics (systemic) : Amoxicillin with clavulanic acid.
- Decongestants → To relieve eustachian tube oedema.
- Analgesics → To relieve pain.
- Myringotomy → In cases of impending rupture with or without complications, to ensure it heals.
- If patient comes with ruptured tympanic membrane, only treat the infection, make the ear dry; give both systemic and local antibiotics (ear drops).
  (Acute tympanic membrane perforation heals by itself in 3 months).
- Repair of tympanic membrane needed if it has not healed in 3 months.

Myringotomy

00:15:12

60c6b3eeaa8ded0e4e7e5ea7

OPD procedure.

Instrument used → Myringotomy knife (Myringotome).

Incision given in → Posteroinferior quadrant of tympanic membrane(Curvilinear shaped incision).

Never in posterosuperior quadrant in order to avoid injury to vital structures.

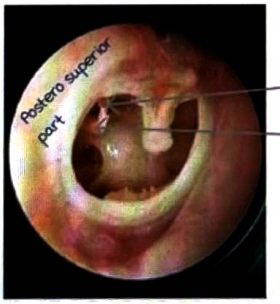

TM perforation showing postero superior quadrant

Curvilinear incision : Incision against the direction of tympanic membrane fibres to facilitate drainage of pus.

Once pus is fully drained and pressure returns to normal, edges of tympanic membrane approximate to heal without scarring.

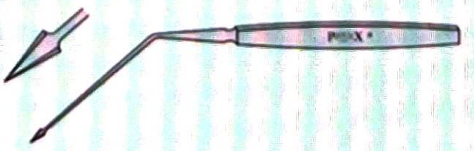

Myringotomy knife

Active space

Leave Feedba

Ear examination 00:20:09

If patient c/o pain or ear discharge : It can only be in external or middle ear.
Otoscope is used with the largest ear speculum, pull pinna of ear posterosuperiorly to bring cartilaginous part and bony part of external auditory canal in a straight line.

Ruptured TM

To hold otoscope in the same side as of ear to be examined i.e., for examining left ear of patient hold otoscope in left hand of examiner.

kumarankitindia1@gmail.com

Acute necrotizing otitis media 00:26:50

If infection is more virulent e.g., Beta haemolytic streptococci.
Perforation will be marginal i.e.,one of the margins of annulus is eroded, no epithelium/mucosal lining.

Ruptured TM

This will predispose the epithelium (stratified squamous) from external auditory canal to migrate into the middle ear, thus forming cholesteatoma.

Types of perforation 00:29:08

1. Central : Perforation of Pars tensa not eroding annulus.

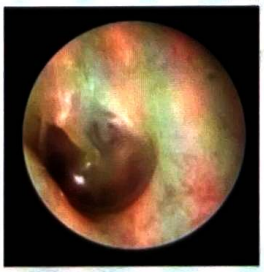

Active space

Leave Feedbac

According to site of perforation :

- Anterior → Anterior to handle of malleus.
- Posterior → Posterior to handle of malleus.
- Inferior → Inferior to handle of malleus.
- Subtotal → Without only a thin rim of pars tensa spared.

Anterior perforation

Posterior perforation

Sub total perforation

According to size :

- Small → Involves 1 quadrant.
- Medium → Involves 2 quadrants.
- Large → Involves 3 quadrants.
- Subtotal → Involves all 4 quadrants, with only a thin rim of pars tensa spared.

Small

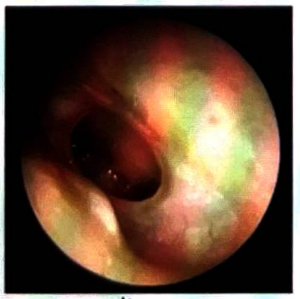

medium

Large

Active space

Leave Feedbac

Subtotal

2. marginal : Perforation of pars tensa involving erosion of annulus along any of the margin and any perforation of pars flaccida (because it has no annulus).

marginal

Question : A 5 yr old child with severe pain in the ear, TM is red & congested (cartwheel TM). Management ?
Answer : Antibiotics, Decongestants & Analgesics.

Question : A 5 yr old child with severe pain in the ear, TM is red & congested (slight bulge). Management ?
Answer : Antibiotics, Decongestants & Analgesics.

Question : A 5 yr old child with severe pain in the ear, TM is red & congested (full & bulging). Management ?
Answer : Impending rupture (with/without complication)

↓

myringotomy.

Active space

60c6b3eeaa8ded0e4e7e5ea7

Leave Feedback

SEROUS OTITIS MEDIA

Also called Otitis media with effusion3eeaa8ded0e4e7e5ea7
Serous fluid (SF) collection in middle ear (ME).
Because of non infective obstruction of Eustachian Tube (ET) drainage (ET opens into nasopharynx).
Most common cause of SOM is non infective mass in ET
children : Hypertrophied adenoids, adults : Nasopharyngeal carcinoma.
Most commonly the mass is a hypertrophied adenoid.

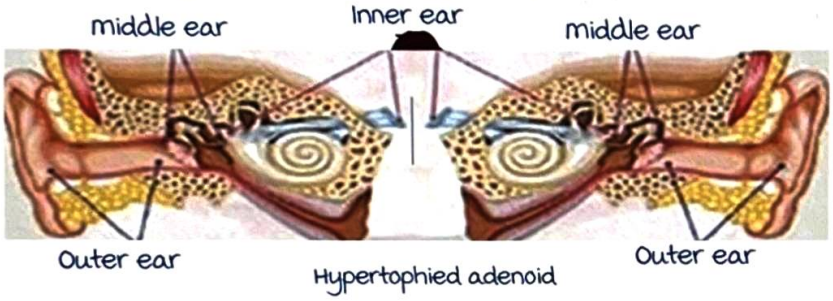

Adenoid is a midline structure in nasopharynx seen in children.
From 12 years of age, it will atrophy and by 20 years will disappear.
Hence SOM is most commonly seen in children than adults.

Causes of SOM

00:04:53

- Decreased drainage like ET tube obstruction :
  a. In children → Bilateral (B/L) SOM due to hypertrophied adenoid.
  b. In adults → Unilateral (U/L) SOM mostly due to nasopharyngeal carcinoma.
  c. malfunctioning of muscles closing ET like in cleft palate.
- Increased production of secretion like allergy.
- Unresolved Acute Otitis media (AOM).

Mechanism : ET obstruction leads to negative pressure in middle ear so transudation of fluid occurs from blood vessels into middle ear.

Active space

Leave Feedbac

Hypertrophy of adenoids occur due to allergy which waxes and wanes, so SOM is usually fluctuating

Clinical features

00:09:27

- Hearing loss(HL)
  Painless (as there is never increased pressure in ME).
  Fluctuating (usually seasonal).
  B/L in children and U/L in adults.

60c6b3eeaa8ded0e4e7e5ea7

  Any case of B/L painless flucuating hearing loss in children : Suspect SOM.
- Delayed speech development.

On examination :Dull and grade I retracted tympanic membrane in SADE classification. Never bulging TM.

Features of retracted TM :

- Foreshortening of handle of malleus.
- Prominent lateral process.
- Sickling of malleolar folds.
- Distorted cone of light.

Bubbles and air fluid level seen behind TM.

Precipitation of cholesterol in fluid called cholesterol granuloma giving TM a bluish appearance.

Because of chronic obstruction, the fluid thickens. So, SOM also called glue ear.

Bubbles and air fluid

Bluish TM

Hemotympanum : Dark blue TM.

Blood collected due to fracture of temporal bone.

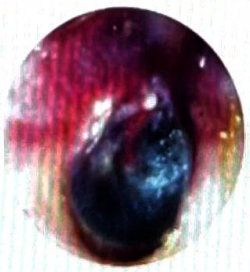

Active space

Leave Feedbac

Confirm by tuning fork test : Conductive hearing loss.

- Rinnes : Negative.
- Webers : Same side/worst ear.
- ABC : Same as examiner.
- Schwabach : Lengthened.
- PTA : AB gap present.
- Impedance : B type curve or dome shaped curve tympanogram (a negative pressure and because of fluid TM mobility is reduced .

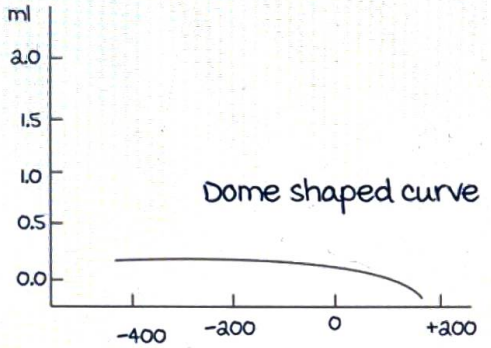

kumarankitindia1@gmail.com

- Stapedial reflex : Not elicited.
  70 db given, there is 30-40 db loss before it reaches internal ear, which is not sufficient to elicit reflex.
- Tympanometry/impedance audiometry (objective test) : Best method.

Management

00:23:08

Medical management :

In children : To reduce size of adenoid with

- Anti-allergic drugs.
- Nasal decongestants.
- Nasal steroid spray to reduce size of adenoid.

Drugs are to be given until there's improvement and can be given for maximum 3 months.

Surgical repair must be done if there's no improvement after 3 months of medical therapy as risk of speech impairment is high with prolonged hearing loss.

Surgical management :

Adenoidectomy + Myringotomy + Grommet insertion.

Grommet/ventilation tube : Put in TM for replacement of function of ET like ventilation and drainage of ME.

Active space

Leave Feedback

Grommet is to be held strongly by the fibers of TM to prevent its extrusion or intrusion. Hence radial incision is made in the TM.

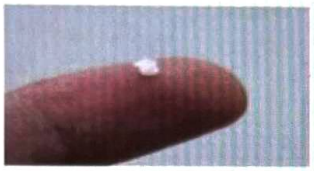

myringotome

myringotomy in	ASOM	SOM
Site	Posteroinferior	Anteroinferior quadrant
Shape of incision	Curvilinear	Radial
Grommet	Not inserted	Inserted

Beer can technique : In case of thick fluid in the ear which is difficult to suction out, a second incision is made inthe anterosuperior quadrant and through this upper opening, air enters and pushes the fluid out through the lower incision.

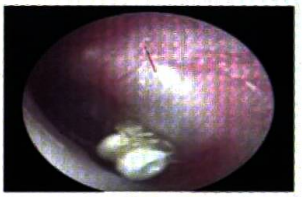

myringotomy never done in posterosuperior quadrant as other structures present and injury possible.

Grommet

00:33:42
60c6b3eeaa8ded0e4e7e5ea7

Does not require removal, falls of by itself and incision heals.

Type → Short term : Shepherd's (< 6 months) m/c used.
Donald's.

Chronic : Shah's (6 months-2 years).
Armstrong's.
T tube (> 2 years).

Shepherd's grommet
< 6 months

Donaldson's grommet

Shah's grommet

Armstrong's grommet

T - tube

Active space

Leave Feedback

Child presents with B/L hearing loss?

Tympanogram :

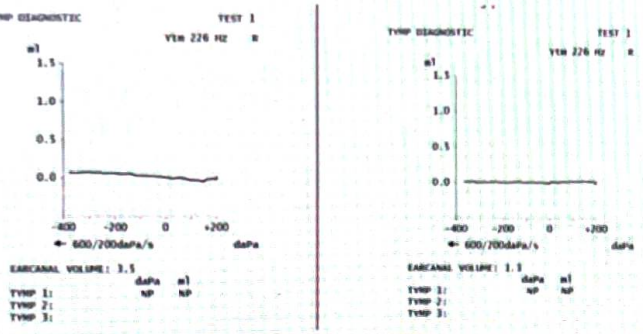

Finding : B/L B type curve.

Seen in serous otitis media.

Adult presents with hearing loss, tympanic membrane is intact.

Tymapanogram :

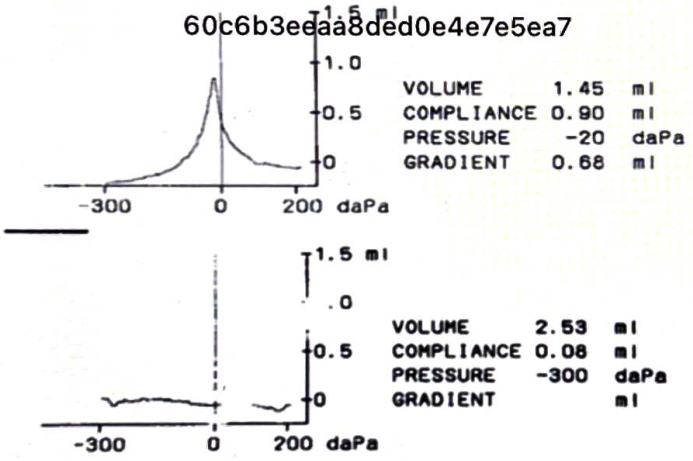

Right ear : A type curve.

Compliance between 1.5 to 3.5.

Peak of graph in middle.

Left ear : B type curve.

Finding : Unilateral SOM in an adult.

Rule out nasopharyngeal carcinoma.

Active space

Leave Feedbac

Otitic barotrauma 00:43:45

Trauma to ear because of pressure changes.
Seen commonly during flight travel.
The fluid compartments (blood vessel, CSF) in our body gets automatically regulated to the same pressure changes as outside.
But in air containing compartments (ME, sinuses, lung) pressue equilibration happens only when there is movement of air into these compartments.
If eustachian tube is blocked → Air does not enter middle ear → Pressure increases → Barotrauma.

During ascent 00:46:51

External pressure is negative, but inside ME is positive.
↓
Pressure difference crosses 15 mmHg.
↓
ET pushed open.
↓
Air moves outside from ET.
↓
Equilibrates air pressure.

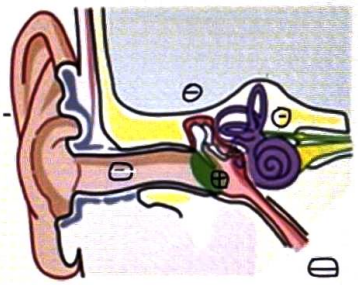

If ET blocked (like in pharyngitis),
Air cannot escape → TM bulging out → TM perforation
↓ further pressure on ascent
Ossicular chain stretched.
↙ ↘
The oval window pushed out. Round window pushed inside.
↓
Round window rupture.
↓
Peri lymphatic fistula.
↓
Sudden onset vertigo.

Active space

Leave Feedback

During descent

00:49:26

more common than ascent.

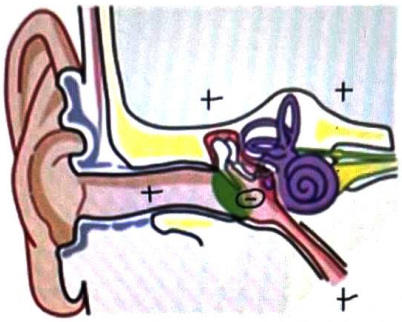

Positive external pressure but inside ME is negative.

↓

Pressure builds up so we chew/ swallow.

↓

ET pushed open.

↓

Air enters to ME

80c6b3eeaa8ded0e4e7e5ea7

↓

Equilibrates air pressure.

If ET blocked, negative pressure builds up in ME causing TM to be pulled inside → TM rupture.

Oval window pushed inside.

Round window pushed outside→ Rupture → Peri lymphatic fistula.

Blood vessels also rupture forming hemotympanum.

Management

00:52:38

Prevention :

1. Avoid flying with sinusitis or blocked nose.
2. Nasal decongestants if clogged ET like in pharyngitis.

If patient has developed barotrauma :

1) Inflation of ME with Valsalva manoeuvre, Politzerization, ET catherization (active insertion of air in ET).

2) myringotomy to drain blood from the ear.

Active space

Leave Feedback

Approach to U/L hearing loss 00:54:40

Patient complains of hearing loss in one ear for few months.

In case of pain, discharge : Involvement of middle/external ear. Inner ear would be spared.
If there are no associated complaints :
1) Rule out external ear conditions by examination via otoscope.
Pull the pinna postero-superiorly to straighten the external canal. Observe the EAC and tympanic membrane.
Congested TM : Acute otitis media.
Retracted TM/normal TM : Confirm type of hearing loss by Tuning fork (TF) tests :

a. Rinnes test :

Procedure :

- TF hit at elbow, knee. Never struck on table as it produces overtones that give false results.
- For air conduction : Place TF 2.5 cm away external meatus parallel/perpendicular to EAC.
- For bone conduction : Then strike again and placed on mastoid (posterosuperior to canal & over the non-hair bearing area).

If bone conduction > air conduction, test is negative
Seen in conductive HL and severe sensorineural HL.

b. Webers : Lateralized to worst ear in conductive hearing loss.

TF struck and placed over root of nose/ midline of forehead, vertex/teeth.

To confirm, perform typanometry.
make differential diagnoses based on patient's symptoms.

Active space

60c6b3eeaa8ded0e4e7e5ea7

Leave Feedback

CHRONIC MUCOSAL OTITIS MEDIA

middle ear (ME) is chronically exposed to infection.
Pre-requisite : Permanent abnormality of tympanic membrane (TM) for > 3 months.
2 Types : Chronic mucosal.
Chronic squamous.

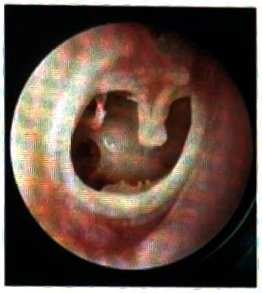

Chronic Mucosal Otitis Media (CMOM) 00:03:00

Called so as mucosa is exposed.
Abnormality : Permanent central perforation of Pars tensa, without annulus involvement.

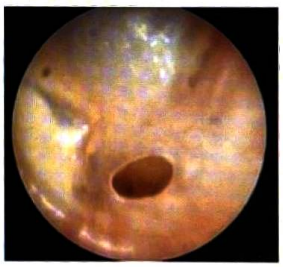

Also called tubotympanic COM.
Earlier called safe CSOM.
3 Layers of TM :
1. Epithelium (outside).
2. Fibrous.
3. Endothelium/ mucosal (inside).

Normal order of healing : Epithelium grows → Endothelium grows → Fibrous
Causes of perforation of TM : Trauma , acute OM.
In the healing of a perforation if the epithelium grows and meets the endothelium causing contact inhibition leading to permanent perforation.

- History of perforation < 3 months → Acute OM.
  > 3 months → Chronic OM.

Active space

Leave Feedback

Clinical features :

1. Discharge :
   - Mucoid/mucopurulent.
   - Mucoid discharge is always from middle ear and not EAC, since EAC has stratified squamous epithelium.
   - Profuse because of involvement of entire ME.
   - Painless.

Discharge occurs only when there is an infection of the middle ear : When water enters the EAC while bathing (therefore advised to place cotton balls in ears during the time of bathing).
Infection of the throat enters middle ear through eustachian tube (hence it was previously called as tubotympanic OM).

- Active mucosal COM : Discharge present.
- Inactive mucosal OM : Discharge absent.

Active

Inactive

60c6b3eeaa8ded0e4e7e5ea7

2. Deafness :
   - 10–40 dB hearing loss.
   - Ischemic ossicular necrosis occurs leading to ossicular discontinuity and if so > 40 db hearing loss.
   - Common ossicle which gets necrosed :
     Lenticular process of incus > Long process of incus > Stapes suprastructure.

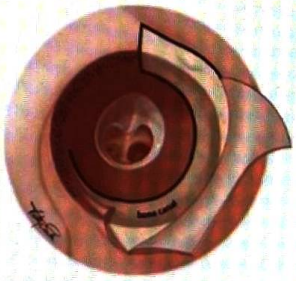

History of disease for > 3 months implies permanent perforation suggesting COM.

Active space

Leave Feedback

Management

00:13:13

- In case of active mucosal COM,
  1. Organism involved : mixed aerobic and anaerobic infection.
kumarankitindia1@gmail.com
  2. Medical management with systemic and local (after aural toileting) antibiotics.
  3. After the course of antibiotics ear must be dry for 6 weeks before it is posted for surgical repair.
- medical management alone would not work as margins will have epithelialized.
- Surgical repair of TM is called myringoplasty. It is done along with repair of the ossicular chain called ossiculoplasty.
- myringoplasty + Ossiculoplasty = Tympanoplasty.
- In case of ossicular discontinuity, the surgery might further aggravate the hearing loss as sound cannot directly reach the oval window via the TM perforation, as it is closed after the surgery.
- Hence, ossicular status assessment is important as otherwise it can lead to worsening of hearing loss inspite of myringoplasty.

Ossicular status assessment can be done by :

1. Examination under microscope (EUM).
2. Otoendoscope.
3. Patch Test : Paper patch is used to close the tympanic membrane perforation.
   If the hearing loss is only due to perforation of TM : Hearing will improve.
   If the ossicles are involved as well : Hearing will worsen.

Aim of Surgery :

1. Dry ear.
2. Hearing improvement.
3. Participate in water sports.

Active space

Leave Feedback

Procedure :

1. Retract pinna forward so that it does not interfere in the access to TM and through the EAC bony part operate on TM (Post aural approach).

Wildes incision

60c6b3eeaa8ded0e4e7e5ea7

2. Incision :

Wildes incision (post aural approach).

Lempert incision (cartilaginous incision on incisura terminalis) : To widen EAC for access of TM.

Lempert incision

Rosen's transcanal incision :

If EAC is wide and small perforation. Incision made lateral to TM on EAC and EAC's skin is raised.

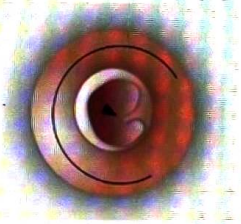

Rosen's transcanal incision

Autologous graft :

- Temporalis fascia (mc).
- Tragal perichondrium.
- Cartilage graft.
- Fat graft.

Tragal perichondrium

Temporalis fascia

Types of myringoplasty

00:24:40

Types of myringoplasty :

- To remove epithelialized margin. Thin rim of perforation's margins removed.

This is called Freshening the margins.

- It is irrespective of placement of graft, over the handle of malleus or under it.

Overlay : After raising the epithelial layer of TM, graft is placed over the fibrous layer and epithelium reposited.

Underlay : Entire TM raised and graft placed under the whole of TM.

Active space

Leave Feedback

Overlay/underlay myringoplasty

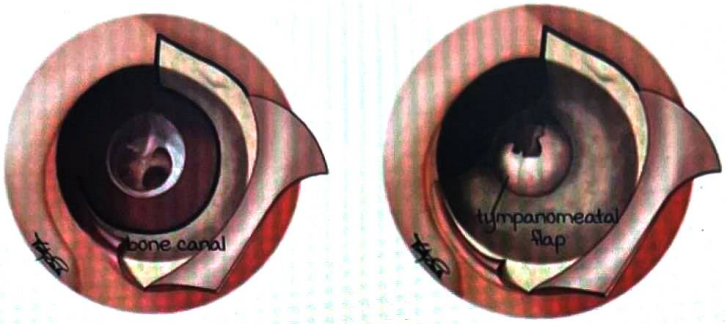

Wullstein classification of tympanoplasty 00:33:32

Wullstein classification of tympanoplasty :

- Type 1/myringoplasty : Graft is placed in contact with malleus (1st ossicle)
- Type 2 : Graft is placed in contact with incus (2nd ossicle)
  - Partial Ossicular Replacement Prosthesis (PORP) is placed over head of stapes
- Type 3/columella tympanoplasty / myringostapediopexy : Graft is placed in contact with stapes (3rd ossicle)
  - Total Ossicular Replacement Prosthesis (TORP) is placed over footplate
- Type 4 :
  - whenever sound reaches both oval and round window at same time , it will cancel each other.
  - So here round window is closed and the oval window is opened to maintain phase difference.
- Type 5/fenestration :
  - Initially footplate was thought to be fixed .
  - Here a fenestration was made in the bulge of lateral semicircular canal.
  - Any pressure change or loud sound would stimulate inner ear causing vertigo and leads to positive fistula test, hence no more done.

60c6b3eeaa8ded0e4e7e5ea7

Active space

Leave Feedback

Types of tympanoplasty

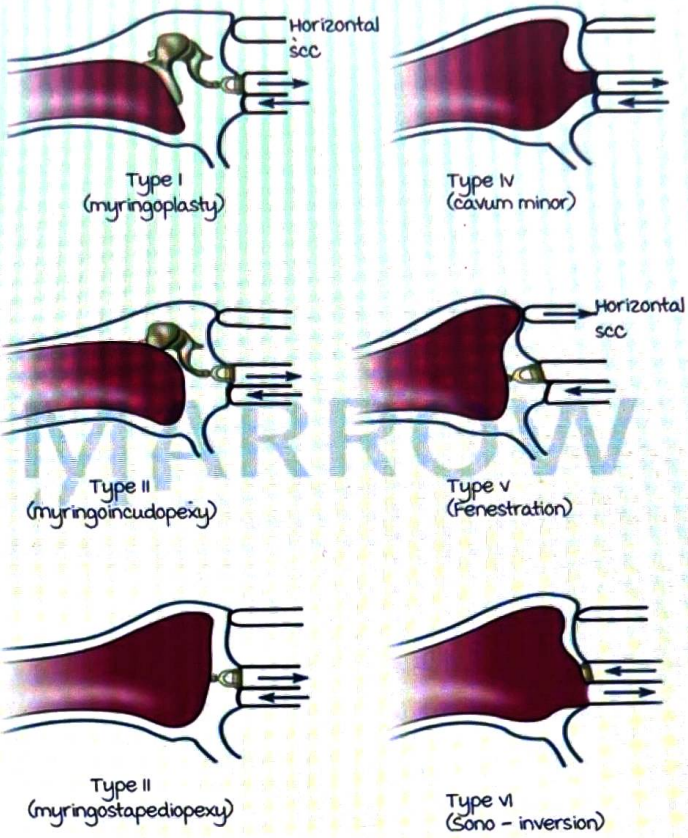

©MARROW

Type 3 Tympanoplasty

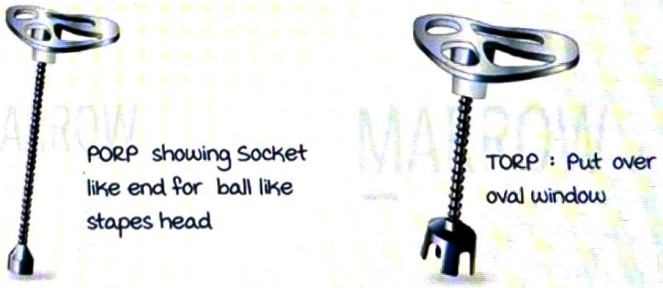

Type IV tympanoplasty

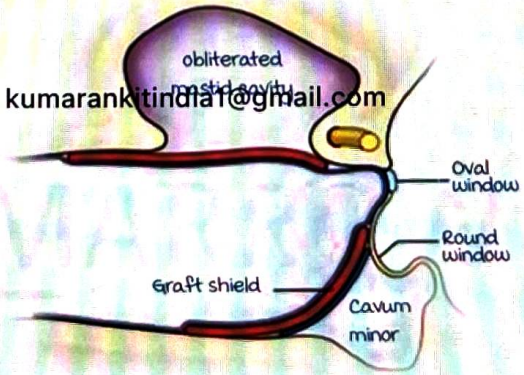

©MARROW

kumarankitindia1@gmail.com

Active space

Leave Feedback

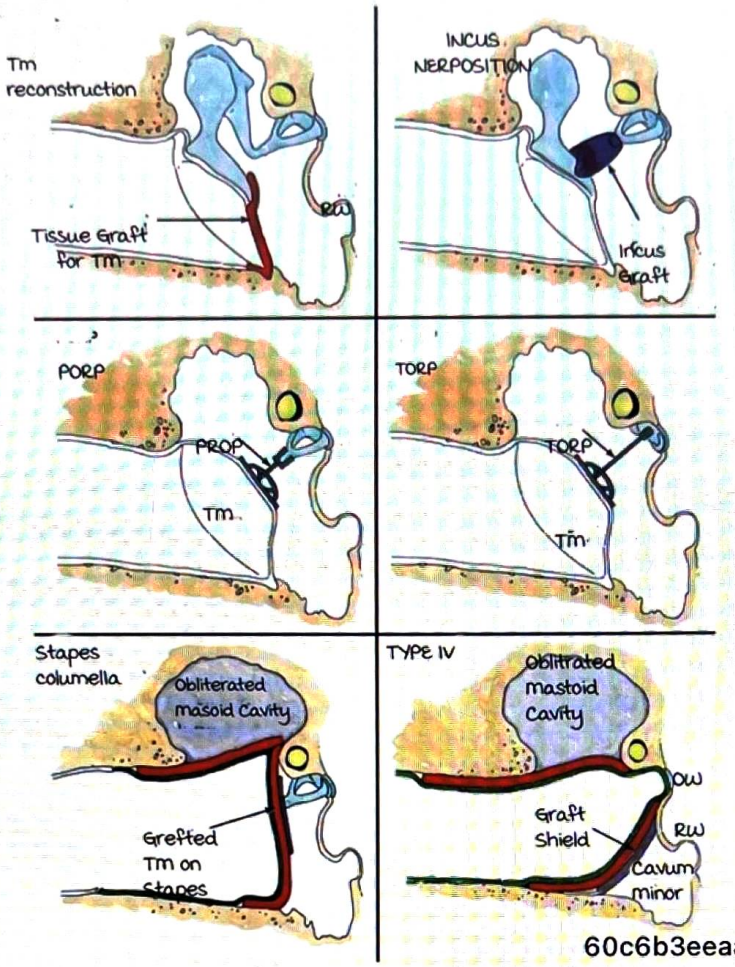

60c6b3eeaa8ded0e4e7e5ea7

1. maximum hearing loss is seen in posterosuperior perforation of TM.
2. Round window baffle/shielding Effect : Round window is covered by the discharge/pus or it is protected thereby maintaining the phase difference providing better hearing in discharge hearers.

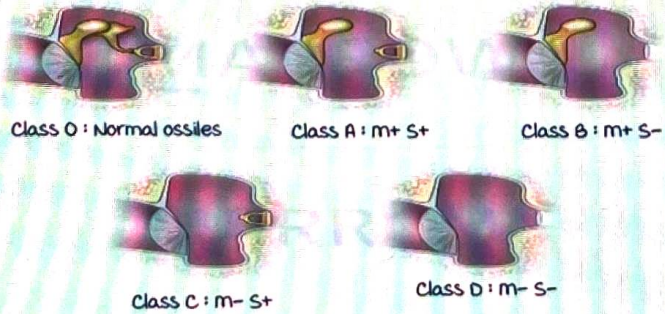

Austin's classification of ossicular discontinuity

Active space

Leave Feedback

Austin classification of ossicular discontinuity :

- Based on presence of either handle of malleus or head of stapes.

60c6b3eeaa8ded0e4e7e5ea7

- Incus will be commonly absent
- Class A : Malleus present stapes present (M+ S+).
- Class B : Malleus present stapes absent (M+ S-).
- Class C : Malleus absent stapes present (M- S+).
- Class D : Malleus absent stapes present (M- S-).

Austin-Kartush classification : Kartush added 3 more classes as a modification to Austin's classification with the following :

O : Normal ossicular chain.

F : Footplate is fixed.

E : Head of ossicles fixation.

Treatment of choice for mucosal COM :

Myringotympanoplasty > tympanoplasty alone.

Active space

145
Leave Feedba

CHRONIC SQUAMOUS OTITIS MEDIA

Chronic otitis media :

Presence of permanent abnormality of tympanic membrane.

Types :

- Chronic mucosal otitis media.
- Chronic squamous otitis media.

Chronic mucosal otitis media :

Permanent central perforation of pars tensa ⟶ chronically expose the middle ear mucosa to infections from the outside.

Presents with discharge and deafness.

myringoplasty or tympanoplasty, depending on the involvement of the ossicular chain.

Chronic mucosal otitis media

60c6b3eeaa8ded0e4e7e5ea7

Chronic squamous otitis media 00:02:39

Also known as unsafe CSOM/ atticoantral chronic otitis media.

Presence of keratinized stratified squamous epithelium in the middle ear or mastoid or anywhere in the temporal bone, where it is normally absent ⟶ Cholesteatoma.

Types :

Congenital cholesteatoma :

Congenital presence of keratinized stratified squamous epithelium in the middle ear due to developmental abnormality.

Acquired cholesteatoma : The keratinized squamous epithelium migrates from EAC into the middle ear. Can be 1° or 2°.

Active space

Leave Feedba

Keratosis obturans :
Keratin accumulation in EAC.

EAC cholesteatoma occurs when there is a fracture of the temporal bone, causing a cut in it ⟶ Keratin accumulation in the cut in the bone. 60c6b3eeaa8ded0e4e7e5ea7

Keratosis obturans

2° acquired cholesteatoma :
Occurs secondary to a marginal perforation of the tympanic membrane.
Not seen in the central perforation of chronic mucosal otitis media because of contact inhibition by the endothelium of the middle ear that prevents growth & migration of epithelium from EAC into middle ear.
In marginal perforation ⟶ Annulus is eroded.
The bone under the annulus is exposed.
Occurs due to acute necrotizing otitis media.

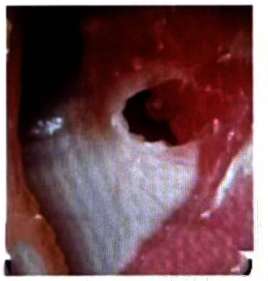

Marginal perforation of TM

Bone below annulus is exposed ⟶ Keratinized stratified squamous epithelium migrated to the area and into the middle ear.
Macrophages recruited in response to Keratin deposition in middle ear ⟶ undergoes transformation into osteoclasts ⟶ further bone erosion (including mastoid).
Multiple erosions and subsequent complications ⟶ Unsafe otitis media.

Active space

Theory of migration of epithelium from EAC to middle ear
⟶ Habermann's theory of migration (for 2° cholesteatoma)
Most common site of marginal perforation through which migration occurs is posterosuperior margin.

Keratin deposition in middle ear

1° cholesteatoma

00:16:39

Not secondary to perforation.
Most common route is through the retraction pocket ⟶ most commonly in pars flaccida.
Obstruction of eustachian tube ⟶ negative pressure in middle ear ⟶ Serous otitis media/ otitis media with effusion ⟶ Retraction pocket follows serous otitis media.
Fluid occupies the Prussak's space of epitympanum.
The retraction pocket can get adhered to malleus neck.
Persistent eustachian tube obstruction ⟶ Further retraction of the pars flaccida ⟶ Hides behind the scutum.

Defective clearance of keratin from the retraction pocket ⟶ Chronic inflammation results in macrophage recruitment ⟶ Conversion to osteoclasts ⟶ Erosion of bone and mucosal epithelium.
This is the Wittmaack's theory.

kumarankitindia1@gmail.com

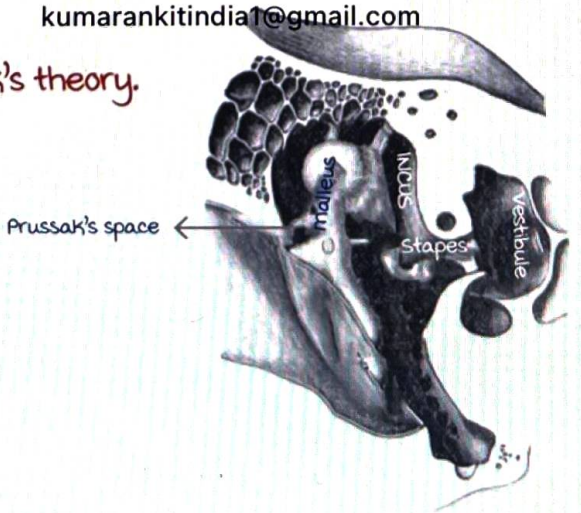

Active space

Leave Feedba

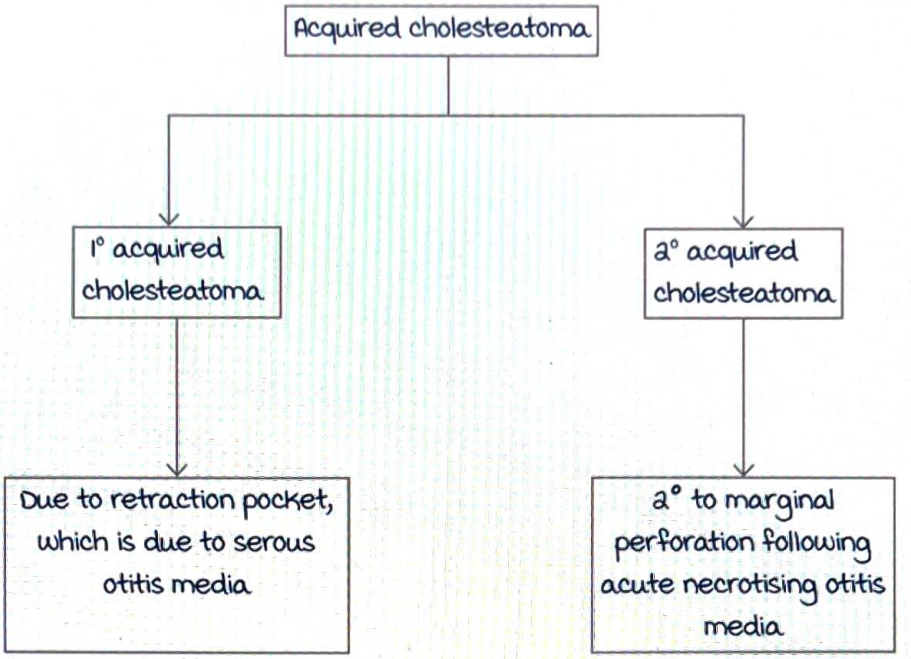

Retraction pocket in pars flaccida : Inactive disease

Adherence of retraction pocket to malleus neck – Tos 2 grade of retraction

60c6b3eeaa8ded0e4e7e5ea7

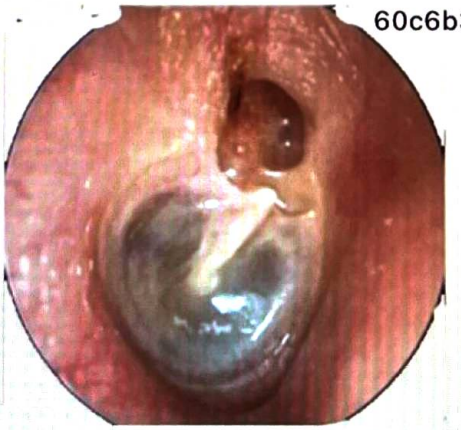

Retraction leading to erosion of scutum (lateral wall of attic of epitympanum above pars flaccida)

Grade IV retraction : Active disease

Active space

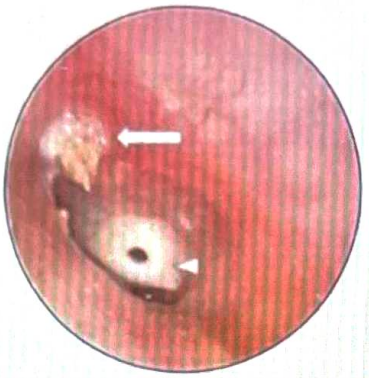

Grade IV retraction : Active disease

Squamous otitis media :
Active ⟶ Actively eroding due to cholesteatoma.
Inactive ⟶ No erosion, but has the propensity to become active.

Chronic squamous otitis media can move into the mastoid antrum via the aditus ⟶ also known as atticoantral CSOM.

Atticoantral or unsafe CSOM

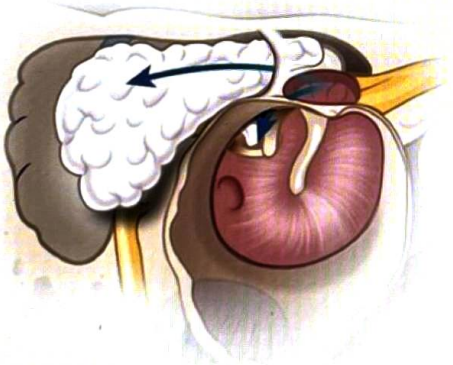

Most common site of 1° cholesteatoma is the Prussak's space ⟶ most common site of retraction pocket.
Retraction pocket can also occur in posterosuperior area of tympanic membrane ⟶ 2nd most common site for 1° cholesteatoma.

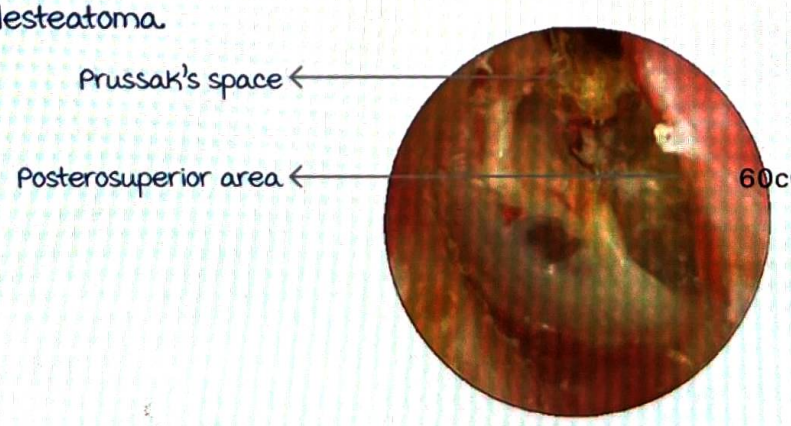

60c6b3eeaa8ded0b4e7e5ea7

Leave Feedbac

Routes of primary cholesteatoma :

- Wittmaack's theory.
- Sade's theory : Repeated infection of middle ear via eustachian tube can cause squamous metaplasia.
- Ruedi's theory : Repeated trauma causing microfissures ⟶ Exaggerated healing where basal epithelium grows inside ⟶ Basal cell hyperplasia.

Route of secondary cholesteatoma : Habermann's theory.

Congenital cholesteatoma

00:31:31

Embryonic cell rests in the ME transform into Keratinized stratified squamous epithelium instead of mucosal epithelium.

kumarankitindia1@gmail.com

Normal tympanic membrane is seen, with a whitish mass behind it.

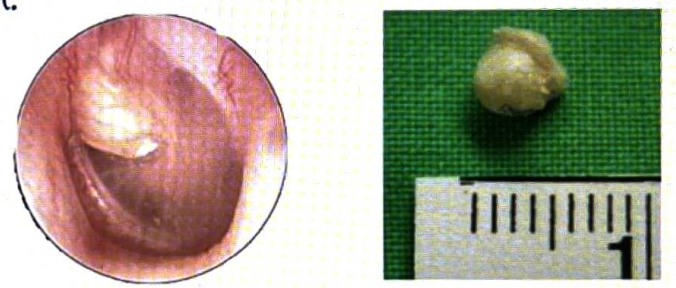

Congenital cholesteatoma as viewed from outside and after resection

Levenson criteria ⟶ For the diagnosis of congenital cholesteatoma.

Most common site : Anterosuperior quadrant.

Levenson criteria for congenital cholesteatoma :

- White mass medial to normal tympanic membrane.
- Normal pars flaccida and densa.
- No history of otorrhea or perforations.
- No prior otologic procedures.
- Prior bouts of otitis media not grounds for exclusion (rule out perforation).

	Congenital cholesteatoma	Acquired cholesteatoma
Age	Seen in children	Seen in adults
Most common site	Anterosuperior quadrant	Posterosuperior quadrant
Chances of ossicular erosion	Very high	Present

Active space

Leave Feedba

Clinical features of cholesteatoma 00:38:36

Scanty foul-smelling discharge, as it is from bony erosion.
Discharge noted while cleaning the ear.
Painless condition.
Bony erosions ⟶ Enzymatic activity of collagenases and acid phosphatases released from osteoclasts.
Not due to pressure due to cholesteatoma.
Hearing loss ⟶ main complaint most of the time.

Management :
Surgical management only, no role for medical management.
Aims of the surgery :

- To provide safe ear.
- To provide a dry ear.
- Restore the hearing.

Investigations :
The extent of the cholesteatoma must be assessed ⟶ High resolution CT of temporal bone.
Examination under microscope (EUM) ⟶ Assess ossicular status and to assess the middle ear structures.
Pure tone audiometry to assess the hearing loss.

60c6b3eeaa8ded0e4e7e5ea7

Surgical management 00:45:54

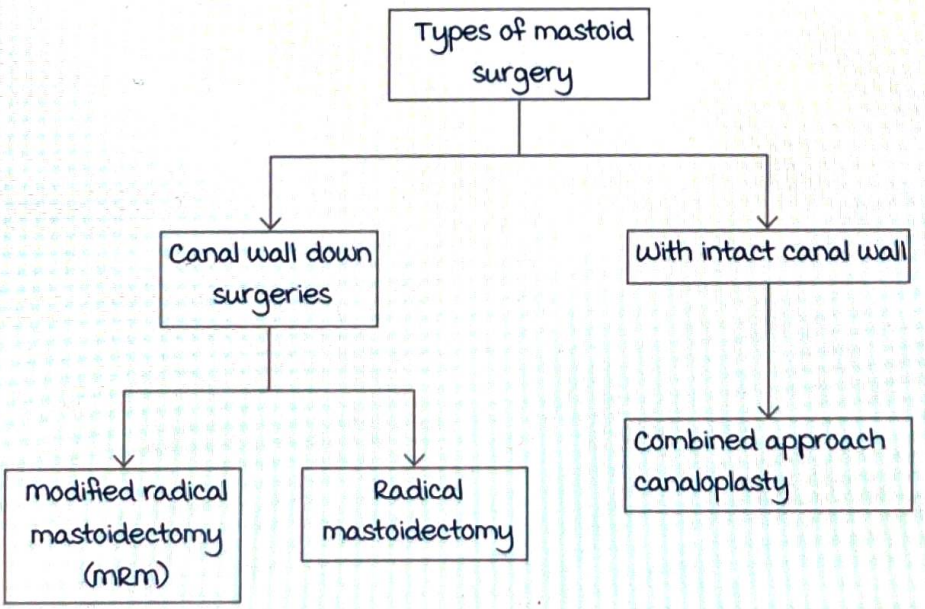

Active space

Leave Feedba

Intact canal wall mastoidectomy :

For limited disease.

1) The mastoid is entered and cleared of the disease upto antrum.

2) middle ear is entered via the facial recess (between posterior canal wall & middle ear) and limited disease in middle ear is removed.

3) middle ear is also approached anteriorly by raising the TM, and unhealthy TM is removed.

Canal wall down surgery :

For extensive disease.

The complete posterior wall between the EAC and mastoid, and the middle ear and the mastoid is removed upto descending part of facial nerve.

The EAC, mastoid and middle ear becomes a common cavity.

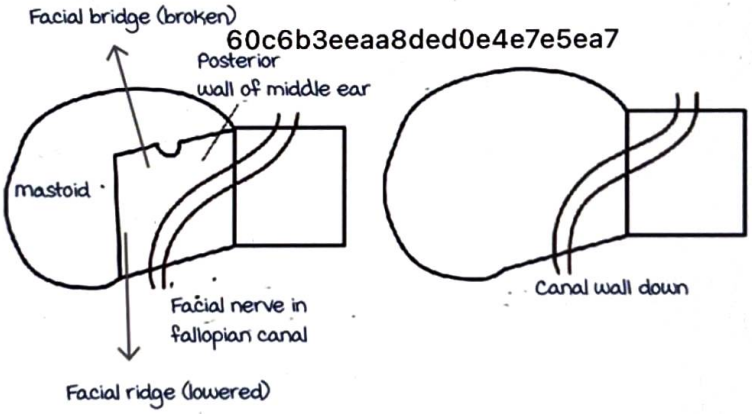

In both radical and modified radical mastoidectomy, the posterior wall of the EAC and middle ear is removed. Chorda tympani nerve is sacrificed. Hearing aids can't be used as cavity is too large.

	modified radical mastoidectomy	Radical mastoidectomy
Posterior canal wall	Lowered	Lowered
Ossicles	Healthy ossicles are preserved	All mucosa, ossicles except footplate of stapes (if healthy) is removed (footplate intact to prevent fistula formation).
Eustachian tube	Left open	Closed
Tympanoplasty	Done	Not done

Active space

Leave Feedba

Indication	All squamous otitis media with / without complication	When inner ear is dead

Radical mastoidectomy is done in any patient of squamosal otitis media, if the disease has destroyed the inner ear ⟶ Reconstruction of middle ear is of no use.
Eustachian tube is closed to prevent infections.
All other cases of chronic squamous otitis media with/ without complications ⟶ Modified radical mastoidectomy.

kumarankitindia1@gmail.com

Intact canal wall surgery

01:09:03

Intact canal wall surgery is also known as combined approach tympanoplasty as approach is both anterior & posterior.

- Approached via mastoid to remove the disease in the mastoid.
- middle ear is approached by the facial recess.
  This is to assess the hidden area of the middle ear, the sinus tympani/ infrapyramidal recess which lies medial to the vertical segment of the fallopian canal.
  This area is the most common site of residual/ recurrent cholesteatoma.
- Approached via the EAC to repair the tympanic membrane and the ossicular chain.

Anatomy of the ear – Lateral view

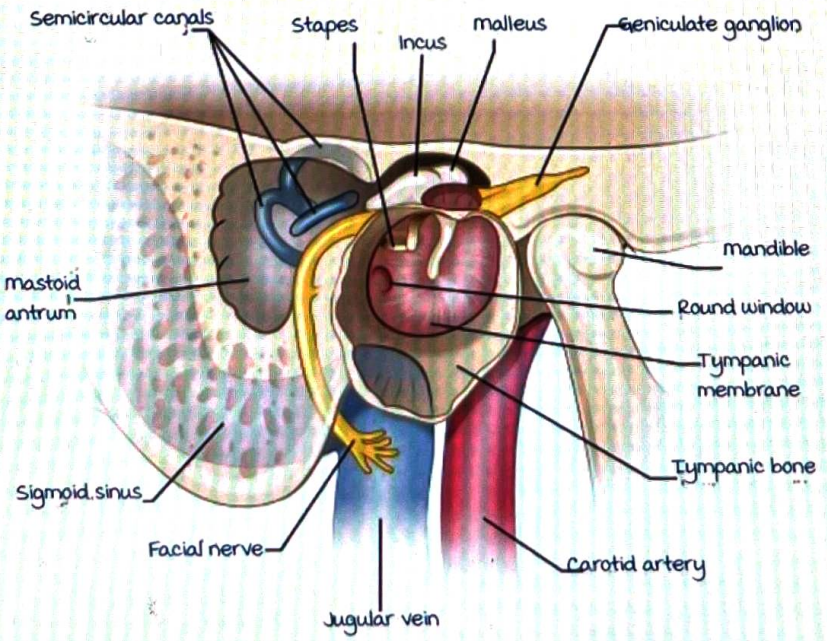

Active space

Leave Feedba

Extensive disease management ⟶ Canal wall down surgery is done.

Recurrence/ residual disease is common in intact canal wall surgery.

Cavity cleaning problems ⟶ Lots of debris collected ⟶ Associated with canal wall down surgery.

Chorda tympani is sacrificed in canal wall down surgery ⟶ Taste of one side of tongue will be nil after surgery.

Hearing aid can be used after intact canal wall surgery, not after canal down as EAC is too large.

Posterior canal wall is reconstructed after canal wall down surgery ⟶ Avoid the cavity cleaning problems and to enable the use of hearing aids.

Reconstruction done with bone or cartilage like concha.

Mastoid cavity is obliterated.

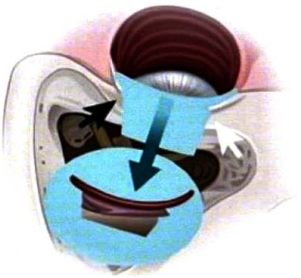

Reconstruction of posterior canal wall

meatoplasty :

The external acoustic meatus is widened to allow the drainage and clearance of wax formed from the widened cavity, if the posterior wall reconstruction is not done, after canal wall down surgery.

kumarankitindia1@gmail.com

The cartilaginous part of EAC is widened.

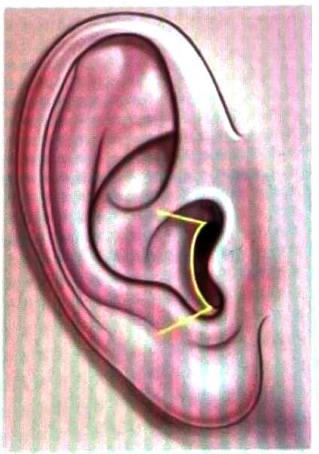

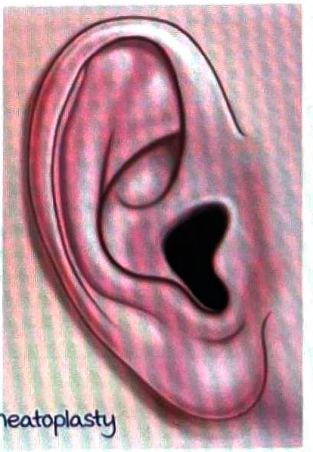

meatoplasty

Active space

Patient of squamous otitis media with extensive disease ⟶ modified radical mastoidectomy.

Patient of squamous otitis media with facial nerve palsy ⟶ modified radical mastoidectomy.

microscopic surgery

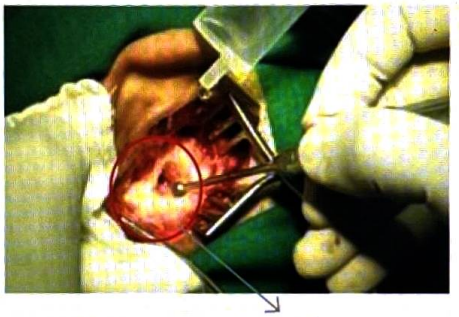

Post aural incision – William Wilde incision

mc Ewan's triangle

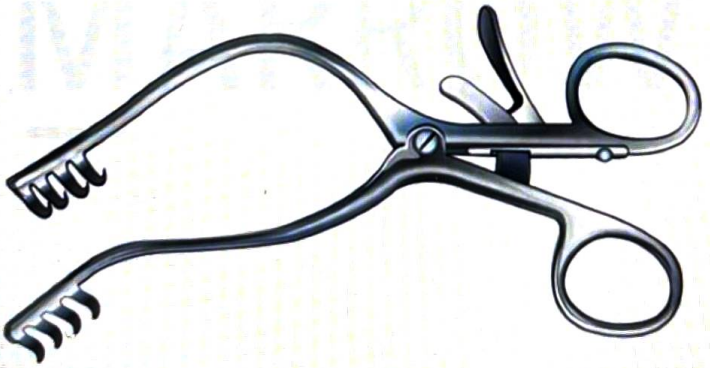

Self- retaining hemostatic mastoid retractor – to retract pinna forwards

Cutting/ diamond burr used to drill the mastoid

Active space

Leave Feedbac

Initially cutting burr with sharp edges is used at the beginning of the surgery.
Diamond burr with smooth edges is used when close to vital structures like facial nerve.
Biggest size burr possible for a particular area is always used, as smaller sized burr appears to be pointed, which if slipped can pierce surrounding structures.

Mastoid is cleared

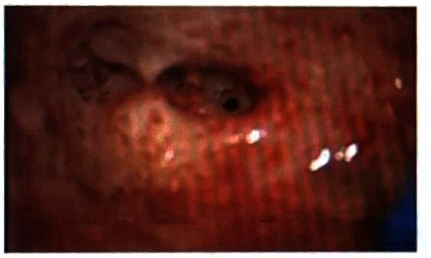

Hole made at the facial recess

Otoendoscope

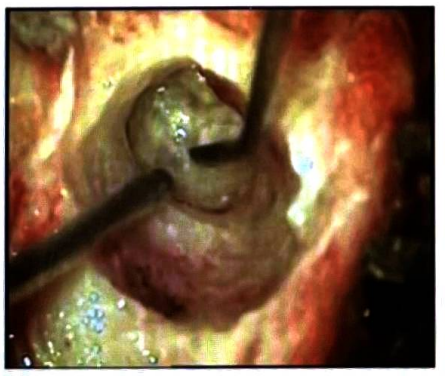

Cholesteatoma seen in mastoid

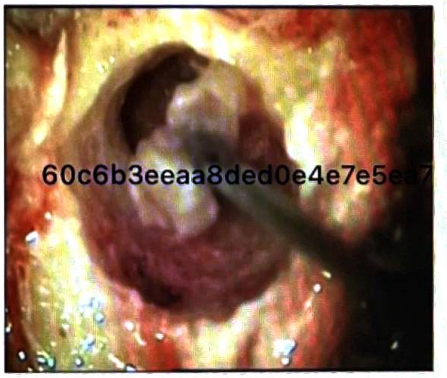

Removal of cholesteatoma

Irrigation done while burring :
To remove the bone dust.
To reduce the heat.

Active space

Removal of disease from epitympanum via the aditus

Disease is extensive in middle ear

kumarankitindia1@gmail.com

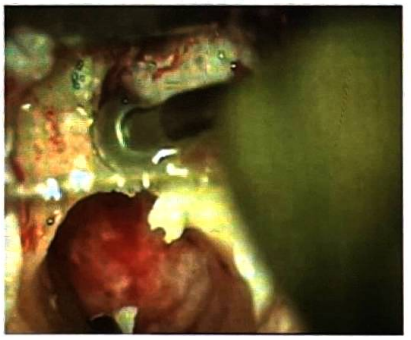

Removal of the common wall –

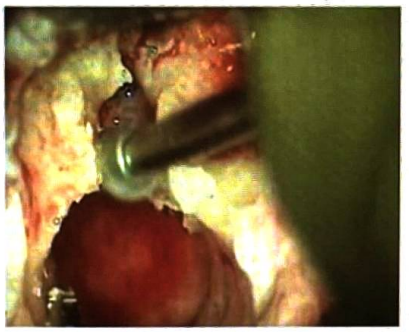

Removal of the bridge

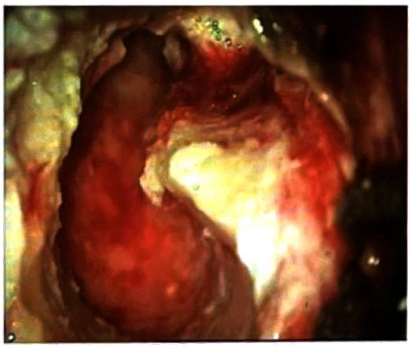

Removal of the common wall

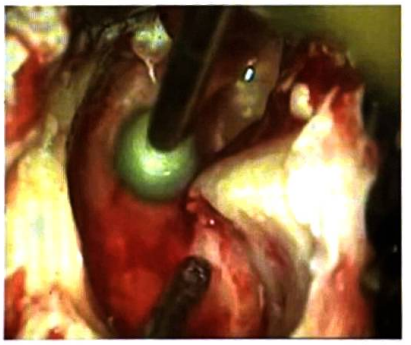

Removal continued up to the descending part of fallopian canal

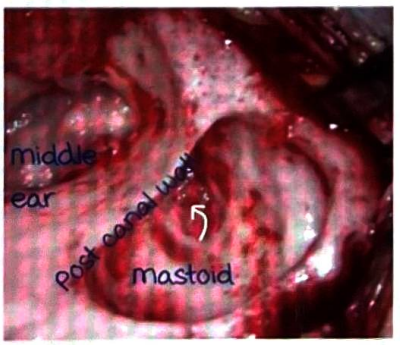

Intact canal wall

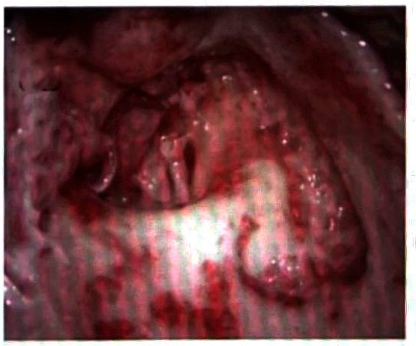

Canal wall down

Active space

Leave Feedba

COMPLICATIONS OF OTITIS MEDIA

Complications of otitis media 00:01:10

60c6b3eeaa8ded0e4e7e5ea7

Complications in chronic squamous otitis media > chronic mucosal otitis media.

Infection from middle ear can spread through :

- Natural openings like oval window, round window, aditus.
- Congenital dehiscence : Fallopian canal, tegmen tympani etc.
- Dehiscence following trauma : Surgical or non-surgical.
- Bone erosions in CSOM.
- Venous thrombophlebitis.

Intratemporal/extracranial complications :
When infection spreads beyond middle ear but is localised within the temporal bone.

- Perforation of tympanic membrane (TM).
- Labyrinthitis (medial extension).
- Facial nerve palsy.
- Mastoiditis (posterior extension).
- Petrositis (posterior extension).

MC following ASOM : Perforation of TM > mastoiditis.
MC following active COM : Mastoid abscess.

Acute mastoiditis : Pathophysiology 00:07:25

MC organism : Streptococcus pneumoniae.
Low immunity → The infection goes into the mastoid from the middle ear via the aditus.
Mucosa of mastoid air cells become hyperaemic → Exudation of fluid → Suppuration of fluid → Pressure on tymphanic membrane → Rupture of tymphanic membrane .
Hyperaemic decalcification thins the walls and causes it to breakdown.
Air cells coalesce and gets converted to a single pus filled cavity : Coalescent mastoiditis.

Active space

Pus ruptures and extends in different directions.

1) Middle ear and EAC :
   Reservoir sign : Pus keeps refilling the middle ear each time after cleaning.
2) Superiorly : Zygomatic abscess.
3) Posteriorly : Post auricular abscess (mc).
   In a child < 2 years of age, superior and horizontal incision given to avoid injury to facial nerve.
4) Inferiorly :
   Bezold abscess : Along sternocleidomastoid muscle.
   Citelli's abscess : Along posterior belly of digastric.
5) Anteriorly towards EAC : Luc's abscess (seen as sagging of posterior wall).

> Angle of Citelli :
> Sinodural angle.
> The air cells in this area must be cleaned to remove the disease completely.

Acute mastoiditis : Clinical features

00:15:02

Pinna :

- Pushed outwards and forwards.

Retro-auricular area :

- Ironed out appearance due to subperiosteal edema.
- Tenderness.

EAC :

- Sagging of posterior wall.
- Reservoir sign.

Posterior auricular abscess

Active space

Leave Feedbac

Management of acute mastoiditis

00:20:03

Medical management done first.

- Antibiotics and supportive care is given.
- No response in 48 hours → surgical management opted.

Surgical management :

Simple/cortical mastoidectomy/Schwartze operation.

- Wilde's incision.
- Mastoid is drilled.
- Pus is removed from the air cells.

Abscess : Incision and drainage.

Incision

Drilling the mastoid

kumarankitindia1@gmail.com

Mastoid cleared of pus

Battle sign : Seen in fracture of base of skull.

EAC would show hemotympanum (bluish discoloration tympanic of membrane).

Battle sign

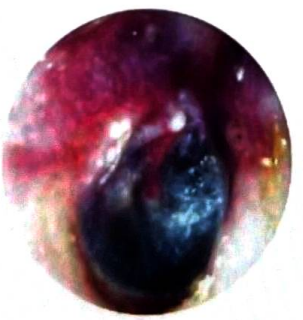

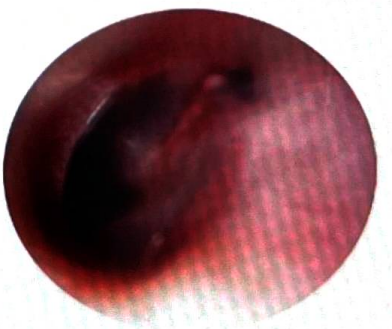

Active space

Leave Feedback

Petrositis

00:24:12

Mastoid air cells communicate with petrous group of air cells.
Only 30% people have well pneumatised petrous bone.
Infection passes from mastoid to petrous air cells.
Suppuration of petrous air cells occurs.
All air cells coalesce to pus filled space, that reaches the petrous apex → Petrositis.

1) 5th cranial nerve involvement.
   - Retro-orbital pain.
   - Paraesthesia over face.
2) 6th nerve palsy.
   - Diplopia.
3) Persistence of ear discharge.

— Gradenigo's triad.

A patient of chronic otitis media presents with diplopia. HRCT of temporal bone done which is given below.

60c6b3eeaa8ded0e4e7e5ea7

Left lateral rectus palsy

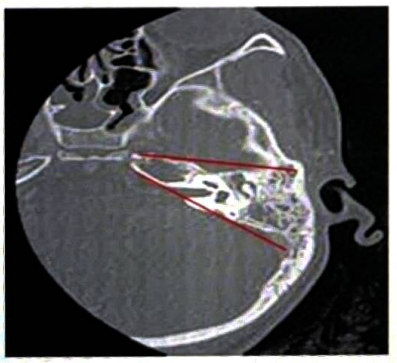

Fluid filled petrous

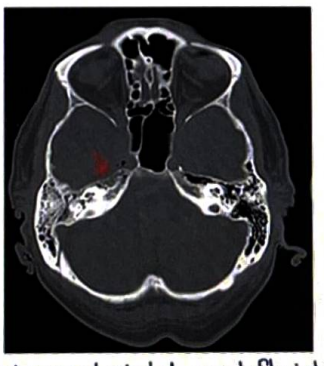

Normal right and fluid filled left petrous

Intracranial complications

00:32:44

Dural plate :
Separates the mastoid from the dura of middle cranial fossa.
Sinus plate : Separates the mastoid from the sigmoid sinus.

Active space

Leave Feedbac

Infection moves superiorly :

- Extradural abscess.
- Subdural abscess.
- Meningitis : most common.
- Temporal lobe abscess : most common otogenic brain abscess > cerebellar abscess (infection goes medially from antrum → posterior cranial fossa → cerebellum).

Infection erodes sinus plate, form an abscess around the sigmoid sinus → Damage the endothelium of sigmoid sinus→ Sigmoid sinus thrombosis → Can cause lateral sinus thrombosis.

Temporal lobe abscess

00:37:33

- Nominal aphasia (cannot name objects).
- Convulsions present.
- Homonymous supra quadrantanopia : Pie in the sky anopia.
- Contralateral motor palsy.

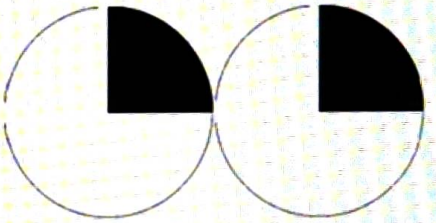

Management of temporal lobe abscess :
Abscess drainage followed by MRM.
MRM is done when the patient is stable.

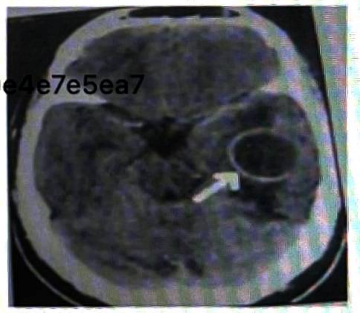

60c6b3eeaa8ded0e4e7e5ea7

Sigmoid sinus thrombosis/lateral sinus thrombosis :
Infection moves from mastoid posteriorly.

- Peri-sinus abscess.
- Intra-sinus abscess.
- Intra-sinus thrombosis.

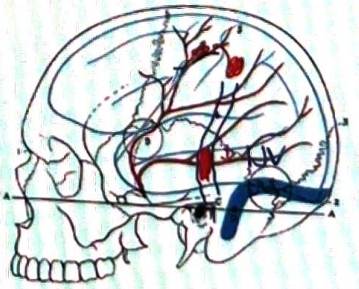

Location of the thrombus :
As it comes into the jugular fossa as jugular bulb.
Embolises superiorly to the mastoid emissary vein.

Active space

Griesinger's sign :
mastoid congestion, edema and tenderness.
No reservoir sign or sagging of posterior wall of EAC.

Internal jugular vein thrombus 00:44:16

Occurs by extension of thrombus from sigmoid sinus.
Jugular vein appears cord like.
Presents with severe pain in neck.
Tenderness +++ overlying the jugular vein.
Examination of pharynx, larynx is normal.
Crowe Beck sign : Sudden papilledema on applying pressure over the normal IJV.

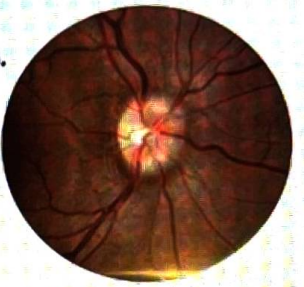

Tobey Ayer/Queckenstedt's test :
Increase in CSF pressure seen in lumbar puncture.

- The normal side has collaterals formed from the affected side, and takes up the function of the affected side.

Picket fence/ Hectic type of fever seen in sigmoid sinus thrombosis : Embolus released into systemic circulation → Peak of fever → Recovery → Further release of infective emboli→ Fever → Recovery.

MRI shows delta sign/empty triangle sign : Thrombus does not take up the contrast.

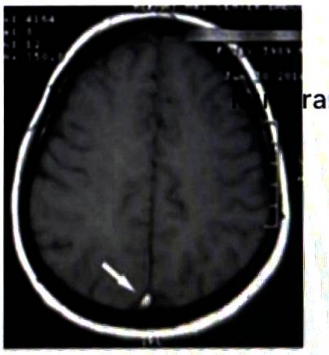

rankitindia1@gmail.com

Otitic hydrocephalus 00:53:58

Non-infective embolus from the sinus thrombosis, lodges in another cerebral vein.
Venous flow blocked → Impaired absorption of CSF → hydrocephalus.
No features of infection.

Active space

Leave Feedba

Presents with features of increased intracranial tension.

CSF findings normal on lumbar puncture.

- Pseudotumor cerebri : mimics the presentation of a tumour.
- Also called benign intracranial hypertension.

kumarankitindia1@gmail.com

Active space

OTOSCLEROSIS

Membranous labyrinth develops from surface ectoderm.
Bony labyrinth develops from the mesoderm that surrounds the membranous labyrinth.
Mesoderm develops into cartilage, which ossifies by endochondral ossification.
Area that fail to ossify :
Area anterior to oval window → Fissula ante fenestram.
This area retains stem cells, and divides on external stimuli → Bone overgrowth occurs → Fixing of footplate of stapes → Otosclerosis.

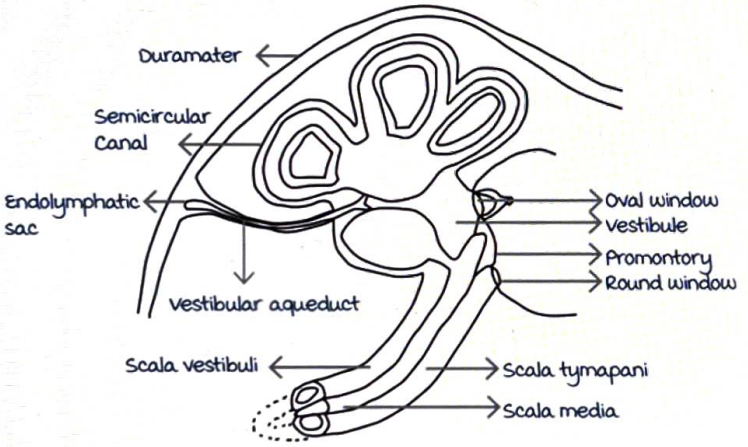

Fissula ante fenestram is the most common site of origin of otosclerosis.

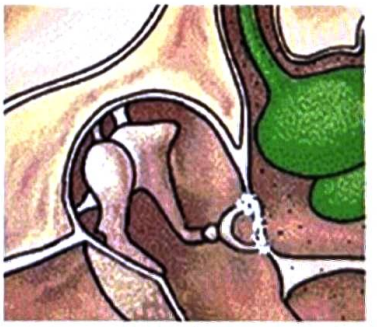
Otosclerosis

Otospongiosis :
Normal endochondral bone is converted into wavy spongy bone.
Microscopy : Blue mantle of Manasse.
New blood vessels surrounded by new bone formation (stains blue on H & E).
60c6b3eeaa8ded0e4e7e5ea7
Can involve cochlea → cochlear otosclerosis.



Active space

Leave Feedba

Clinical presentation

00:05:18

Usual clinical presentation :
30 year old pregnant female presents with bilateral progressive conductive hearing loss. Her mother also had similar history.

Commonly seen in 3rd decade.
Male to female ratio is 1 : 2.
Pregnancy (Hormonal changes) and measles infection are aggravating factors.
Bilateral conductive progressive hearing loss : most common cause in adults.

60c6b3eeaa8ded0e4e7e5ea7

Autosomal dominant.
Paracusis willisii → Paradoxically hears better in noisy surrounding (raised voice crosses hearing threshold).

Usually, tympanic membrane appears pearly white (90% of cases).
Schwartze sign : Flamingo pink appearance of tympanic membrane (active otosclerosis).

- Occurs when there is active division occurring at the promontory area → Increased blood vessels → Pinkish hue in tympanic membrane.
- Usually seen at the posterior part.
- Only seen in 10% cases.

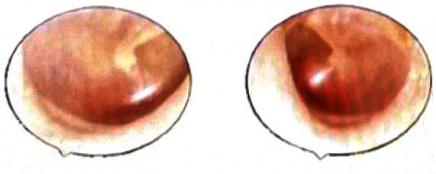

Schwartze sign

Flemingo

Active space

Leave Feedbac

Tuning fork tests

00:16:05

In case of right ear having otosclerosis : Rinne's test :
Negative.
Webers test : Towards the worst ear.
Absolute bone conduction : Same as examiner.
Schwabach : Lengthened.
Gelles : Negative.

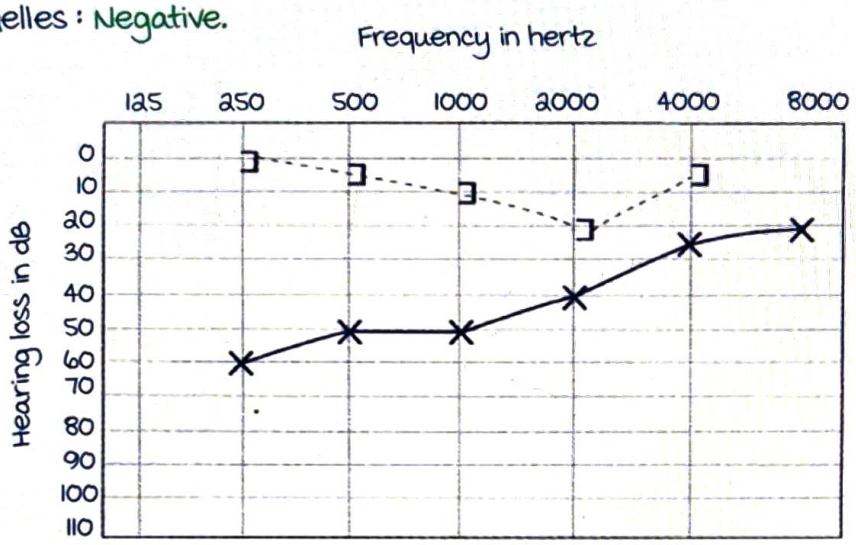

Pure tone audiometry.
AB gap : Present.
Carhart's notch : Dip at 2000Hz, only in bone conduction curve.
Within normal limits.
Seen as the footplate of stapes vibrates at 2000 Hz.
Reversible dip after surgery.

Impedance :
Tympanometry : Compliance decreased → As curve.
Single test for diagnosis.
Stapedial reflex : Absent.

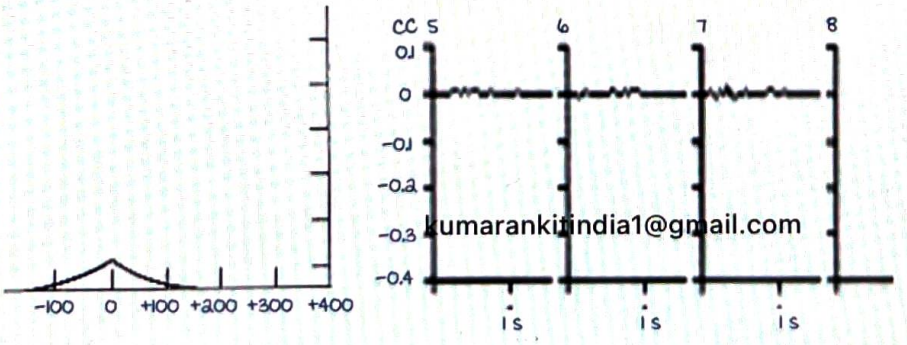

kumarankitindia1@gmail.com

Active space

Leave Feedba

HRCT shows thickening and narrowing of footplate of stapes, lucent and hypodense area of otic capsule in active cases.
Best test for diagnosis but usually not needed.

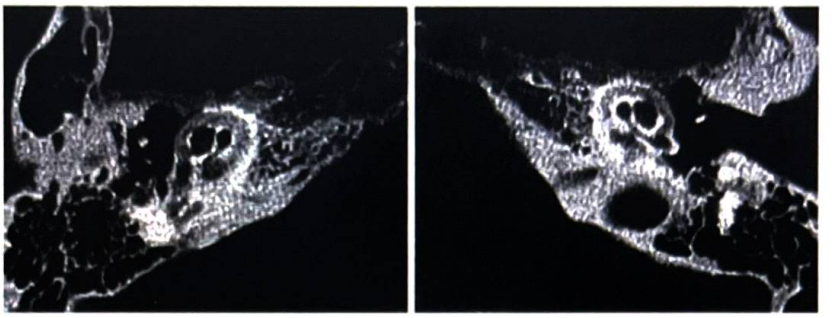

Double ring sign seen in HRCT

Van Der Hoeve syndrome :
Comprises of :

- Otosclerosis.
- Blue sclera.
- Osteogenesis imperfecta.

Tympanogram is As type of curve.

Management of otosclerosis

00:30:29

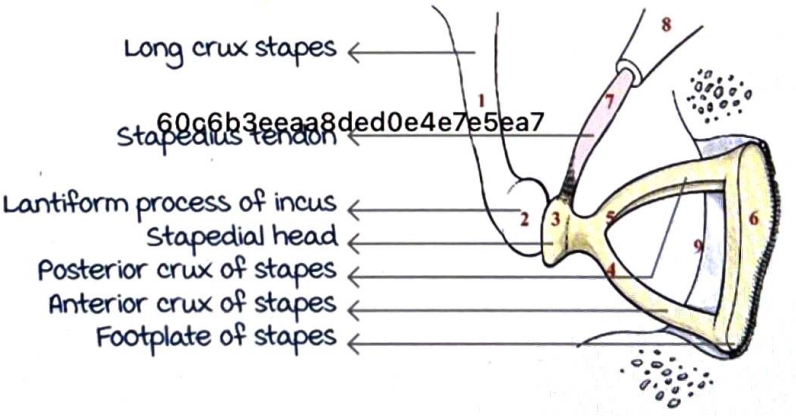

60c6b3eeaa8ded0e4e7e5ea7

Stapedectomy :
No longer done.
Stapedius tendon is cut → Incudostapedial joint is separated → Removal of complete stapes.
Oval window is exposed → increased chance of fistula formation. Increased chances of SNHL.

Active space

Leave Feedba

Stapedotomy :
Only supra-structure removed.
Stapedius tendon is cut → Dislocate incudostapedial joint → Head, neck, anterior and posterior crura of the stapes removed leaving the footplate behind.
Opening made in the center of the fixed footplate.
Piston placed in the opening, other end of which is attached to the incus.
Done in one ear first → Worst ear first → Wait for one year → No complication → Surgery on the better ear.

Alternative for surgery is hearing aid.

60c6b3eeaa8ded0e4e7e5ea7
Active otosclerosis is diagnosed by Schwartze sign → Not operated upon.
Medical management is given with Sodium Fluoride to stop all destruction.

- Decrease the proteolytic enzyme activity.
- Decrease osteoclastic activity.
- Increase bone formation by increasing the maturity.

Once the bone has matured → Stapedotomy of the worst ear first.
Contraindication for surgery :

- When only one ear is function. In this patient, only management is hearing aid.
- Active otosclerosis → Surgery done after maturation.
- Pregnancy → Surgery after delivery of baby.
- Stapedectomy is not done in pilots.
  Stapedotomy is done, but have to be cautious of the abrupt pressure changes.
- In Meniere's disease, the piston has to be places cautiously as the dilated endolymphatic sac is dilated and close to footplate.
  If the piston is placed very close to utricle → Stimulation of endolymphatic sac with movement of piston → Vertigo.

Active space

Leave Feedba

Varius pistons used in stapedotomy

Pistons can be made of teflon, titanium, steel.

Post operative :

Carhart's notch disappears.

Ad type of curve seen in tympanogram.

Post operative causes of hearing loss :

Conductive hearing loss due to :

- Refixation (takes years).
- Dislocation of piston.
- Necrosis of long process of Incus due to tight attachment of the piston.
- If there is SNHL/mixed hearing loss → Fistula suspected.

kumarankitindia1@gmail.com

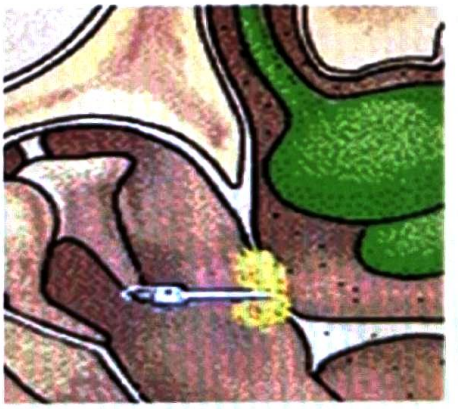

Active space

Leave Feedbac

Complications following surgery 00:48:38

Dehiscence of fallopian canal → Continuous compression of facial nerve → Facial nerve palsy.

- Surgically remove the piston/change the position.

60c6b3eeaa8ded0e4e7e5ea7

Type V tympanoplasty, i.e., fenestration operation → Done on the lateral semicircular canal. Not done now.

- Formation of fistula on the lateral semicircular canal → Vertigo on any pressure change.

Active space

Leave Feedbac

MENIERE'S DISEASE

Conditions of the inner ear :

1. Conditions which involve cochlear and vestibular parts : Hearing loss and vertigo.
2. Conditions which involve only vestibular part : Vertigo
3. Conditions which involve only cochlear part : Sensorineural hearing loss.

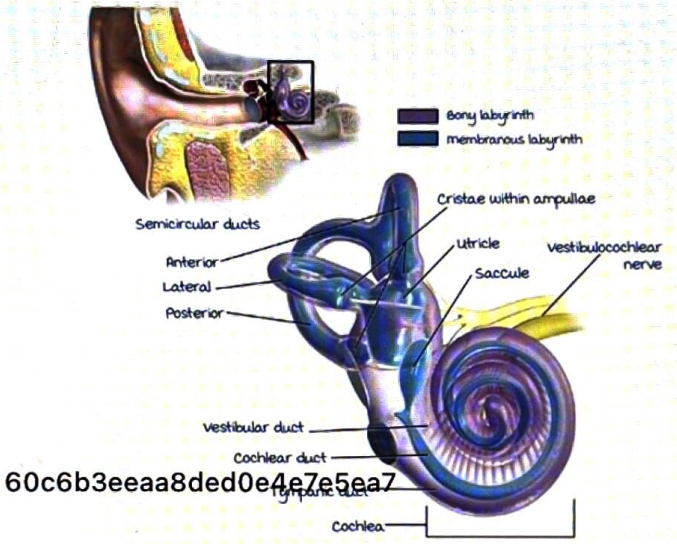

60c6b3eeaa8ded0e4e7e5ea7

Conditions of the Inner ear leading to hearing loss and vertigo :

- meniere's.
- Superior semi-circular canal dehiscence.
- Perilymph fistula.
- Labyrinthitis.
- Ototoxicity.

Meniere's disease 00:02:38

Also known as endolymphatic hydrops.

Endolymph is increased in amount in the whole of the membranous labyrinth, leading to its dilatation.

Dilatation starts in the scala media from its apex to its base.

Later, the utricle and saccule are also dilated.

Active space

Leave Feedbac

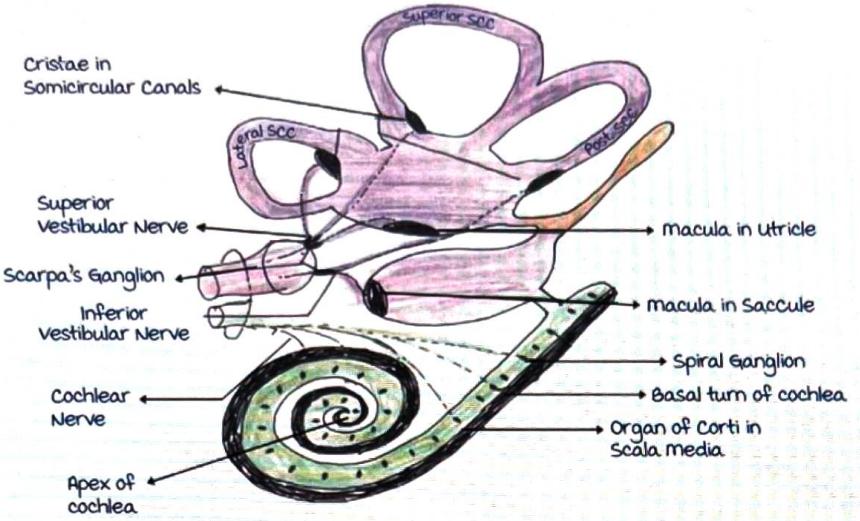

Endolymph increases either due to sodium and water retention or due to decreased absorption from the endolymphatic sac.

Etiology :

Idiopathic : Cause unknown (more common).

Secondary Meniere's : Secondary to a known cause.

Genetic cause (10-15%) : Mutation in the short arm of chromosome 6.

Male : Female = 1 : 1.

Presenting features

00:07:10

Episodes of Vertigo :

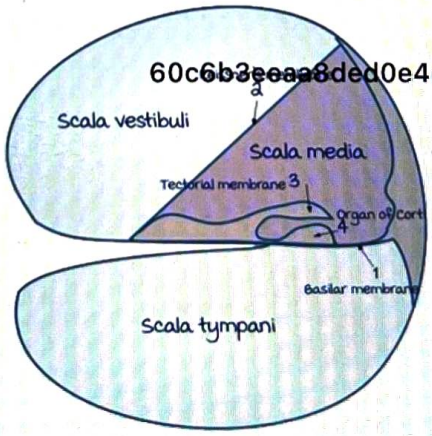

- Earliest symptom.
- The increased pressure of the endolymph in scala media results in rupture of the Reissner's membrane.
- Imbalance in the fluid compartments of endolymph and perilymph leads to vertigo.
- Duration : 20mins to 24hours.
- Vertigo is resolved due to the healing of Reissner's membrane and the balance of pressure in fluid compartments.

60c6b3eeaa8ded0e4e7e5ea7

Active space

Leave Feedbac

Fluctuating hearing loss :

- Hearing loss increases during episodes of vertigo.
- Due to damage to hair cells by Na^+ in the endolymph.
- Sensorineuronal type of Hearing loss.
- The low frequency sounds will be affected first.
- Hearing loss gets better after healing of the Reissner's membrane.

kumarankitindia1@gmail.com

Diplacusis : Double hearing.

Loss of fine tuning of frequency in the affected ear.

Recruitment : Intolerance to loud sounds.

- Loudness distortion : Loud sounds are heard as abnormally loud.
- Due to loss of fine-tuning of loudness by the inner ear.

Subjective tinnitus : Ringing in ears without any external stimuli.

Fullness of ears.

Dilatation of utricle and saccule 00:19:12

Utrivle & saccule present in the vestibule of bony labyrinth which is connected to the oval window.

Dilatation in interior of utricle and saccule :

- Drop attacks : Tumarkin crisis due to distortion of maculae. The patient tends to fall while walking.

Dilatation in exterior of utricle and saccule:

- Vertigo to loud sounds : Tullio's phenomenon, as footplate is closer to utricle and saccule, hence it moves more as in loud sound and leads to vertigo.
- Vertigo on pressure changes as the footplate touches the utricle and saccule stimulating them : Hennebert sign.

Investigations 00:26:08

Tuning fork tests:

- Rinnes : Positive.

Active space

Leave Feedba

- Webers : Towards the normal side.
- Absolute bone conduction : Shortened.
- Schwabach : Shortened.

Audiogram :

- AB gap : The difference between air conduction and bone conduction is negative.
- The slope of the graph : Upsloping.
- In the given graph 69c6b3eeaa8ded0e4e7e5ea7
  - Red colour : Right ear.
  - Pink colour : Left ear.

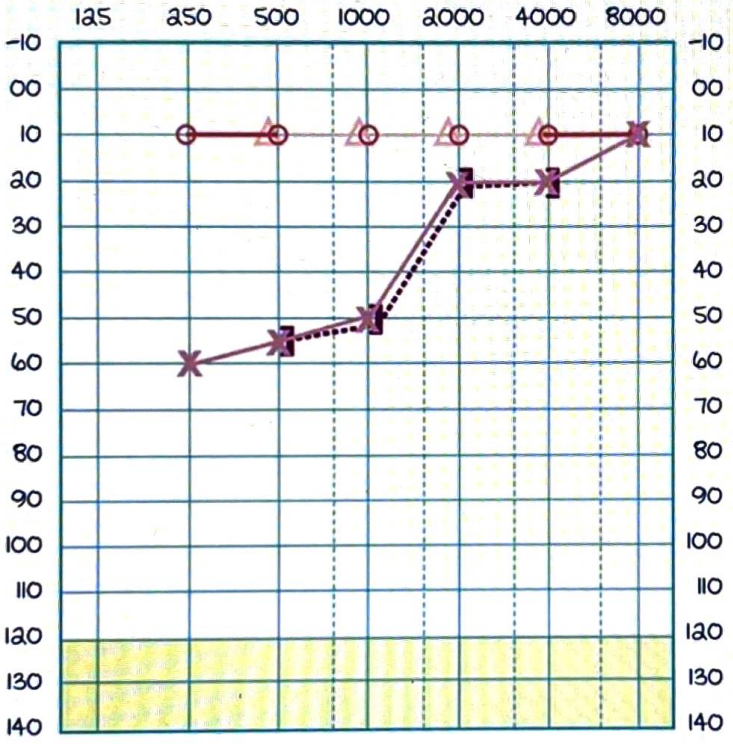

- Among hearing recorders in various frequencies : Normal is within 25 dB.
- Here, the left ear shows both bone conduction and air conduction equally : Sensorineural hearing loss is affected in the low frequencies.

Short increment Sensitivity/SISI Index:
SISI score is 70 to 100 %.
Due to recruitment, the patient can differentiate most of the increment in loudness.

Impedance test : The threshold for stapedial reflex is

Active space

Leave Feedba

reduced. It is an objective test.

Electrocochleography 00:32:40

It is a confirmatory test.

A probe is passed through the tympanic membrane and is placed over the promontory.

60c6b3eeaa8ded0e4[illegible]

Sound is passed through the probe and electrical responses are picked up.

Summation Potential (SP) : The sum of all the activity of inner and outer hair cells.

It is increased.

In Meniere's disease, hair cell depolarization activity is increased due to more Na^+ surrounding it.



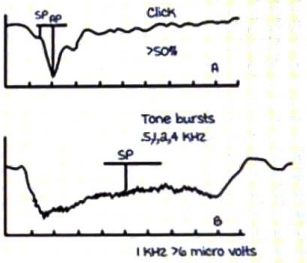

Action Potential (AP) : The potential of the cochlear nerve, is generated by sound. Hence remains the same in meniere's disease.

SP to AP ratio is increased. Normal is less than 30%.
more than 30% is suggestive of meniere's.
more than 45% is diagnostic of meniere's.

Active space

Leave Feedba

Glycerol test : Positive.

When glycerol is given, symptoms are reduced and electrocochleography becomes normal.

MRI with Gadolinium enhancement :

- A needle is passed through the tympanic membrane, through the round window and gadolinium is injected.
kumarankitindia1@gmail.com
- Enhancement is normally expected in the perilymphatic compartment as gadolinium was injected into the scala tympani.
- In meniere's disease, dye is seen both in endolymph and perilymph.

Lermoyez syndrome/reverse meniere's:

A variant of meniere's disease.

Otoconia in saccule is dislodged and blocks the connection between saccule and scala media.

Features:

- Initially hearing loss.
- Followed by sudden vertigo due to pressure changes.
- Hearing becomes normal following vertigo.

A very rare presentation, only few cases seen.

Management of vertigo 00:39:46

Prevention :

Salt restriction.

Caffeine restriction.

Acute Episode:

Labyrinthine sedatives :

- Promethazine.
- Prochlorperazine.
- Cinnarizine.

Vasodilators :

Betahistine (histamine derivative) : most commonly used.

Diuretics.

Active space

Leave Feedba

Transtympanic low-pressure therapy :

Meniett device is used. Causes redistribution of endolymph.

60c6b3eeaa8ded0e4e7e5ea7

Meniett pulse generator

Transtympanic low pressure therapy

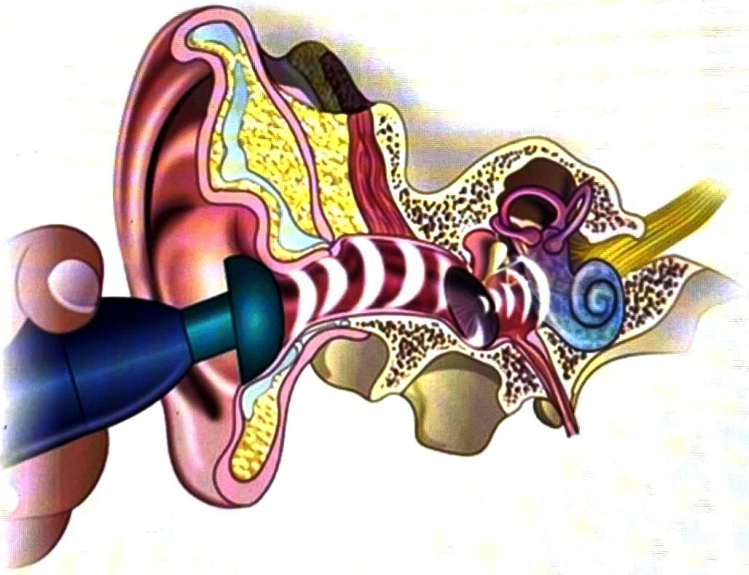

If the symptoms are not relived on medical treatment leading to a severe debilitating condition, destruction of the vestibular hair cells can be considered.

Microwick window

00:45:36

Continuous infusion of drugs is given through the micro wick which is passed through the round window.

Active space

Leave Feedba

Microwick



Wick | Tube | Wick inserted in tube | Hydrated wick in tube

Microwick microcatheter device

60c6b3eeaa8ded0e4e7e5ea7

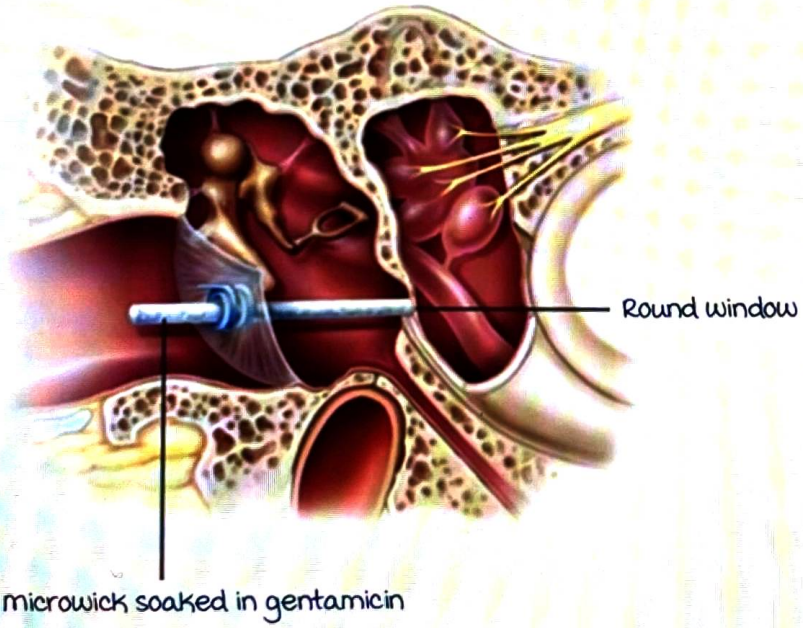

Drugs given :

Transtympanic Steroids.

Chemical labyrinthectomy : Vestibulotoxic drugs like low dose Streptomycin & Gentamycin (preferred).

Surgical management :

If the hearing is good : Vestibular neurectomy.

If no hearing : Total labyrinthectomy.

Active space

Leave Feedba

Endolymphatic sac decompression

00:53:50

The endolymphatic sac lies below Donaldson's line.

Approach : Drilling of mastoid.

Donaldson's line :

An imaginary line from the lateral semicircular canal which bisects the posterior semicircular canal.

The endolymphatic sac lies just above the meningeal dura of the posterior cranial fossa.

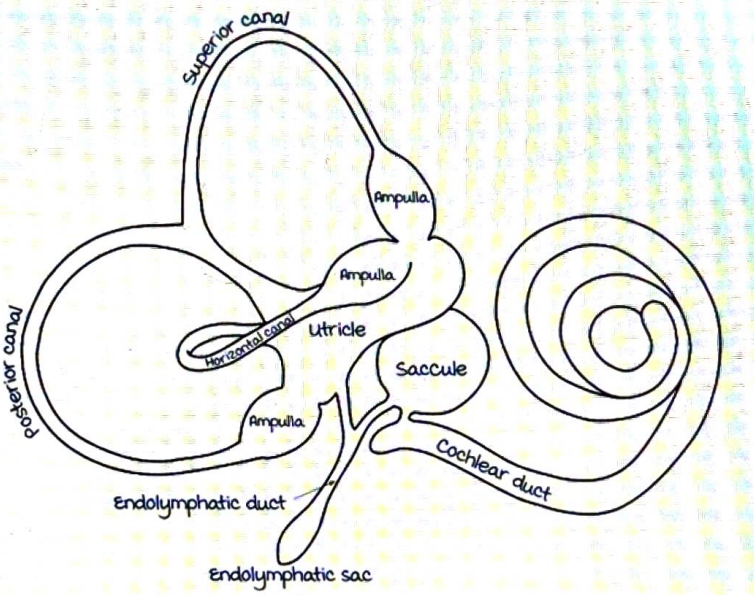

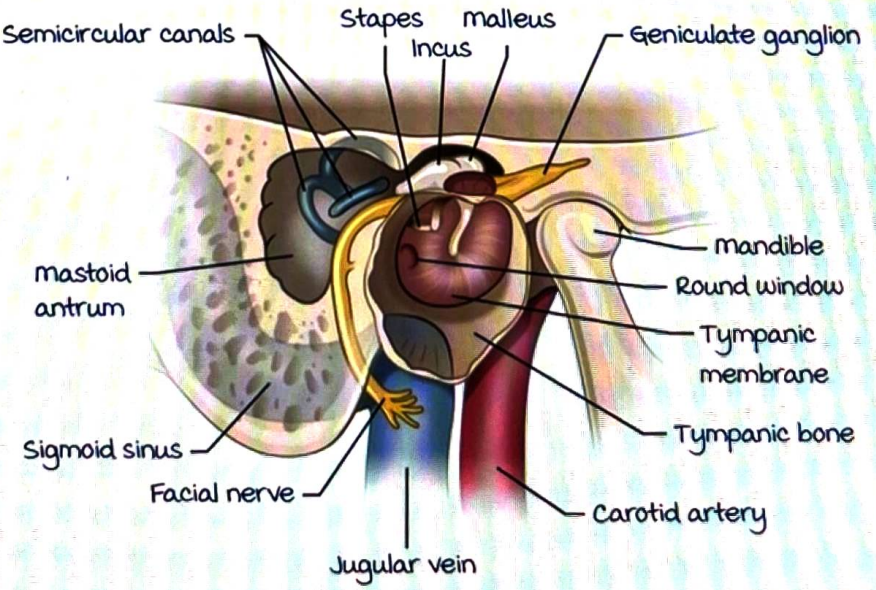

The mastoid cavity is opened for endolymphatic decompression.

Active space

kumarankitindia1@gmail.com

Leave Feedbac

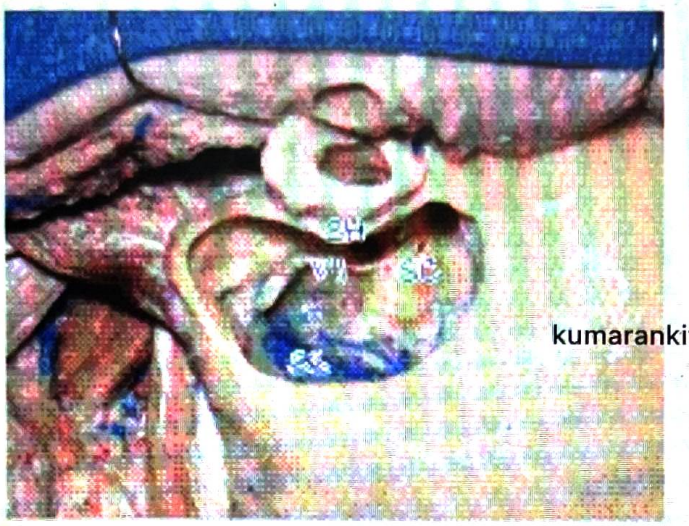

kumarankitindia1@gmail.com

Orientation :

Semicircular canal : Posterior.
Opposite to it : Anterior.

Superior semicircular canal : Superior part.
Opposite to it : Inferior.

Active space

Leave Feedba

SUPERIOR SEMICIRCULAR CANAL DEHISCENCE

Inner ear pathologies

00:00:55

Conditions of inner ear leading to hearing loss and vertigo :

1. Meniere's.
2. Superior semicircular canal dehiscence.
3. Perilymph Fistula.
4. Labyrinthitis.
5. Ototoxicity.

Superior semicircular canal (SSC) dehiscence :

- Gap in the bone overlying the SSC canal (congenital/ traumatic).
- AKa 3rd mobile window.

Arcuate Eminence

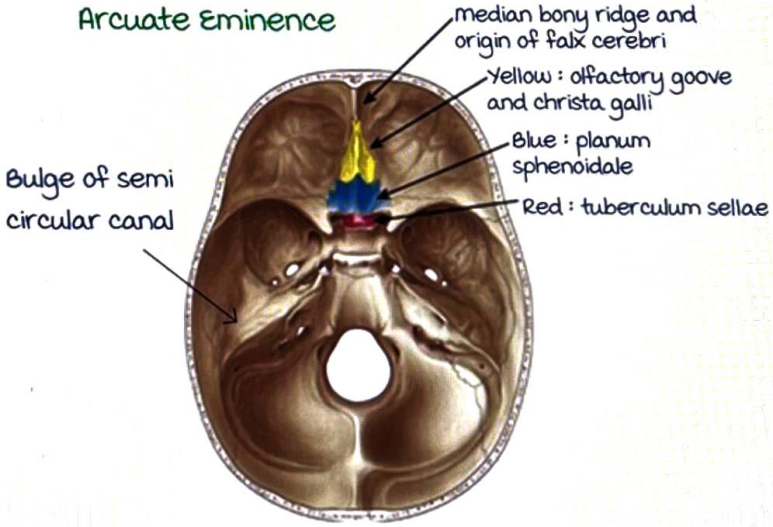

Clinical features :

1. Vestibular symptoms :

- Loud sound → Stimulation of utricle and saccule through inferior vestibular nerve → Impulses go to the Sternocleidomastoid muscle → Vestibulospinal reflex.
- 3rd window → Vertigo on loud sounds (abnormal movement of endolymph) → Tullio's phenomenon.
- Any kind of external pressure changes (sneezing/coughing/ Valsalva) → Abnormal movements of endolymph → Vertigo (Hennebert sign).

60c6b3eeaa8ded0e4e7e5ea7

Active space

Leave Feedbac

2. Cochlear symptoms :

- Abnormal extra opening → Bone conduction sounds enter excessively into inner ear → Appears abnormally loud (autophony).
- Patient will hear footsteps (louder), eye movements etc.
- Air conduction sounds → middle ear to inner ear → Some sound is lost before reaching organ of corti through the opening → manifests as conductive hearing loss.

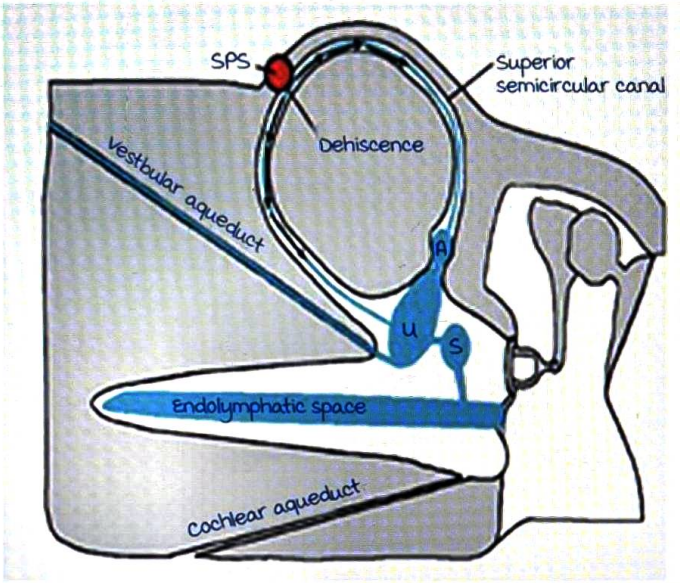

Bone conduction Vs air conduction 00:09:59

Bone conduction → Sensorineural pathway.

Air conduction → [illegible] sensorineural pathway.

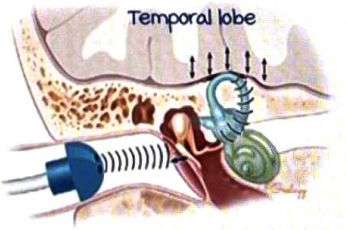

On tuning fork tests,

BC > AC → Rinne's negative

→ Conductive hearing loss (no problem with conductive pathway).

Investigations :

Rinne's : Negative.

Weber's : Lateralized to the defective ear.

Audiogram : Conductive hearing loss (CHL).

Tympanometry :

Normal (A-type) → middle ear normal.

HRCT : Confirmatory test.

Active space

Leave Feedba

VEMP test (Vestibulo Evoked Myogenic Potential) :

Normally the saccule and utricle get stimulated by loud sounds (due to the movement of footplate of stapes).
through the saccule the Inferior vestibular nerve the impulses go to the sternocleidomastoid on the same side.
This leads to relaxation of the sternocleidomastoid.
In people with Dehiscence of the 3rd window : The amplitude of the wave in the VEMP test is increased.

Threshold of sound which elicits VEMP is reduced.

Audiogram

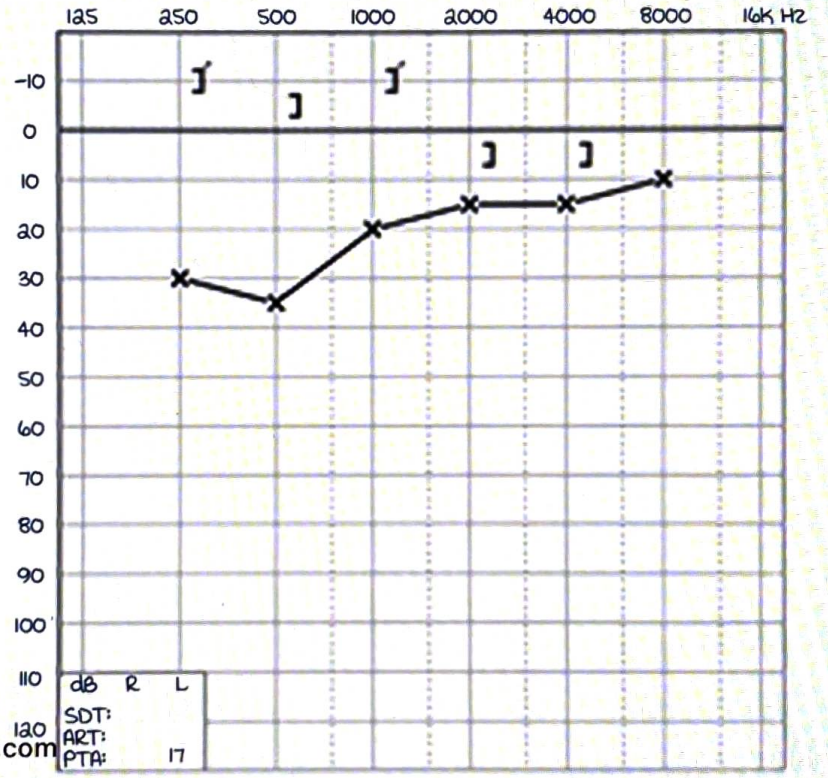

kumarankitindia1@gmail.com

Vestibular Evoked myogenic Potential (VEMP) Test

Active space

Leave Feedbac

Management of SC dehiscence 00:19:10

Definitive → Repair the window.
Pt. is comfortable → No intervention.

Perilymph fistula

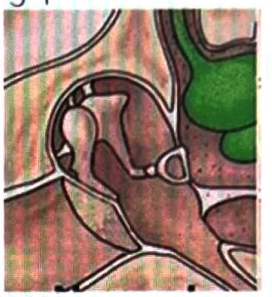

Perilymph fistula :

- Erosions/cholesteatoma/trauma to middle ear (stapedectomy/ barotrauma) → Perilymph leakage from inner ear to middle ear → Perilymphatic fistula.

- Fistula in the medial wall → Inner ear hyper excitable to high sounds and external pressure changes → Vertigo (Tullio's phenomenon).

Surgery where fistula specifically made on medial wall of middle ear → Fenestration operation (discontinued now).

- Fistula test : Positive.

Cochlear symptoms :
Perilymph leakage → Pressure changes in inner ear → Organ of corti damage → Sensorineural hearing loss.
Depending on the etiology → Conductive hearing loss also possible.
60c6b3eeaa8dee0e4e7e5ea7
Hearing loss in fistula : Sensorineural or conductive or mixed type of hearing loss.

Diagnosis :

- HRCT.
- Exploratory tympanotomy.

Management : Repair of the fistula.

Active space

Leave Feedback

Differential diagnosis

00:27:35

	Meniere's disease	SC dehiscence	Fistula
Vertigo	20 mins – 24 hours.	Only on loud sounds/ pressure changes.	Only on loud sounds/ pressure changes.
Tullios	+	+	+
Hennebert	+	+	+
Fistula test	False positive.	False positive.	Positive
Hearing loss	Sensorineural hearing loss (low frequency affected early).	Conductive hearing loss.	Sensorineural/ conductive/ mixed.
Fluctuating	Yes	No	Yes
History of trauma.	No	Yes	Yes
History of surgery.	No	No	Yes
History of CSOM.	No	No	Yes

60c6b3eeaa8ded0e4e7e5ea7

Severe sudden vertigo lasting for 20 mins or more + tinnitus + fullness → Think of Meniere's disease.

Labyrinthitis

00:33:45

Acute inflammation of the labyrinth.

Due to :

- Fistula in middle ear.
- Meningitis (Inner ear to and fro from cranium through cochlear aqueduct).

Clinical features :

- Vertigo (continuous for ≥ 72 hours).
- Sensorineural hearing loss.

Management :

- Otitis media/CSOM → MRM, IV antibiotics.
- Meningitis → IV antibiotics.

Active space

187
Leave Feedback

BENIGN PAROXYSMAL POSITIONAL VERTIGO

Conditions of the inner ear leading to only vertigo

00:03:15

1. BPPV : most common cause of vertigo.
2. Vestibular neuritis : Acute inflammation of the vestibular nerve.

Posterior semi-circular canal

BPPV :

Episodic and positional.

In the macula of the utricle, otolith gets dislodged because of infection/trauma.

Since they have now become free floating, they can enter any of the semicircular canals.

most commonly they enter posterior semicircular canal because of its dependent nature.

The second most common being the horizontal semicircular canal.

The superior semicircular canal is almost never involved because of its superior orientation and even if an otolith gets dislodged here, it returns.

Once the otolith enters the semicircular canal, every time the canal gets active during positional change, the otolith moves and irritates the endolymph causing vertigo.

Since the composition of the otolith is calcium carbonate crystals, because of gravity it will immediately settle until he/she changes posture of his/her head again.

The episode of vertigo only lasts for few seconds on posture change.

management is to bring back the otolith into utricle by a repositioning manoeuvre.

This manoeuvre is different for each canal.

Active space

Leave Feedba

Therefore it is important to locate which canal is involved
This can be found by stimulating that particular semicircular canal.
If the patient has BPPV of the posterior semicircular canal of the right side, positioning the patient (Dix-Hallpike) with the head towards the right and slightly extended, the otolith will move and stimulate the canal causing severe vertigo.
This will also be associated with nystagmus.

Characteristics of nystagmus 00:07:06

- Latency : 10-20 sec.
- Vertical canals (posterior, superior) : Posterior semicircular canal BPPV hence nystagmus is vertical with torsion.
- Horizontal canals : Horizontal nystagmus with torsion.
- Direction : Towards the hyperactive side (fast component).
- Duration : Limited (1 - 1.5 mins).
- Fatiguable : Yes.

Left posterior semicircular canal :

- If a patient comes with history of vertigo whenever he/she turns towards the left.
- Episodic lasting for few seconds.
- Diagnosis of BPPV is made .

When the left canal is being tested, the head of the patient is turned towards her left side, activating her left canal.
If there is an otolith in the left posterior semicircular canal, the canal gets activated in that particular position.
The otolith moves and irritates the semicircular canal and leads to severe vertigo associated with nystagmus.
The nystagmus will have the characteristics of peripheral nystagmus such as :

- Latency.
- Disappear after some time.
- Since the posterior semicircular canal is vertical the nystagmus will also be vertical.

Active space
60c6b3eeaa8ded0e4e7e5ea7

Leave Feedba

- Torsional component.
- The direction of nystagmus will be towards the hyperactive ear.

Dix-Hallpike manoeuvre :

It is done to rule out a posterior canal BPPV.

1. If negative, a supine roll test to rule out horizontal canal BPPV (as it is the next most commonly canal involved).
   To test the horizontal canal the head of the patient must be placed in the plane of the horizontal canal. (That is, the head must be turned horizontally to the right to test the right and left ear respectively).
   If otolith is present, there will be horizontal nystagmus with torsion and the direction will be fast component (towards the hyperactive /involved ear).
   If the test is positive, it can be reverted with the barbeque roll manoeuvre /Gufoni manoeuvre.
2. If positive, reposition to bring back the otolith from the semi-circular canal. This is known as Epley's manoeuvre (is done for posterior canal BPPV).

Epley's manoeuvre

00:18:37

Epley's manoeuvre

kumarankitindia1@gmail.com

Active space

Leave Feedbac

VESTIBULAR NEURITIS

Vestibular neuritis 00:00:20

Acute inflammation of the vestibular nerve.
Usually follows viral infections.
Severe continuous vertigo lasting for 3–7 days.
Clinical presentation :

- Vertigo alone without hearing loss.
- Acute onset in nature.

(H/O diplopia, dysarthria, ataxia, dysphonia other CN involvements should be checked to R/O cerbellar stroke).

Vertigo on postural change : BPPV.
Vertigo on pressure changes or loud sounds : Fistula or any abnormal openings.
Acute onset severe continuous vertigo :

- meneier's disease.
- Labrynthitis.
- Vestibular neuritis.
- Cerebellar stroke (early stage).

Vestibular neuritis v/s cerebellar stroke 00:05:30

60c6b3eeaa8ded0e4e7e5ea7

By HINTS test : Head Impulse, Nystagmus & Test of Skew.

	Vestibular neuritis	Cerebellar stroke
Nystagmus :		
Type	Peripheral.	Central.
Direction.	Fixed & towards active (normal) ear	Direction changing.
Optic fixation.	Disappears	Not disappear
Head thrust test.	Defective (saccades)	Normal
Skew	Absent	Present
History & examination :		

Active space

Leave Feedbac

Cranial nerve involvement	Absent	Present
Dysarthria, dysmetria, diplopia, dysphonia, ataxia	Absent.	Can be present

60c6b3eeaa8ded0e4e7e5ea7

Head impulse test :

Also called head thrust test.

Tests the vestibulo ocular reflex.

Procedure :

- Ask the patient to keep eyes fixed on examiner's nose.
- Quick head impulses to right or left.

Normal test : Patient able to maintain gaze on desired object.

Abnormal test :

Eyes move along with motion and not able to fix gaze on desired object.

Eyes try to come back to gaze on the desired object by making corrective movements called saccades.

Peripheral nystagmus :

1. Direction is fixed and is towards active side (normal).
2. Cause : Destruction of labyrinth of one side.
3. Horizontal nystagmus with torsion.

Test of skew :

Procedure :

- Maintain gaze of patient on examiner's nose.
- Cover one eye.

Positive test : Sudden diagonal movement of eye either in the upward or downward direction - S/O central pathology.

Alexandar's law 00:19:30

Followed by peripheral origin nystagmus.

Intensity of nystagmus increases when the patient looks in the direction of fast component.

Active space

Leave Feedbac

SUDDEN SNHL : NOISE TRAUMA, OTOTOXICITY AND PRESBYCUSIS

Sudden sensorineural hearing loss 00:01:50

Medical emergency and diagnostic dilemma.

Definition : >30 dB hearing loss in 3 consecutive frequencies over a period of 3 days.

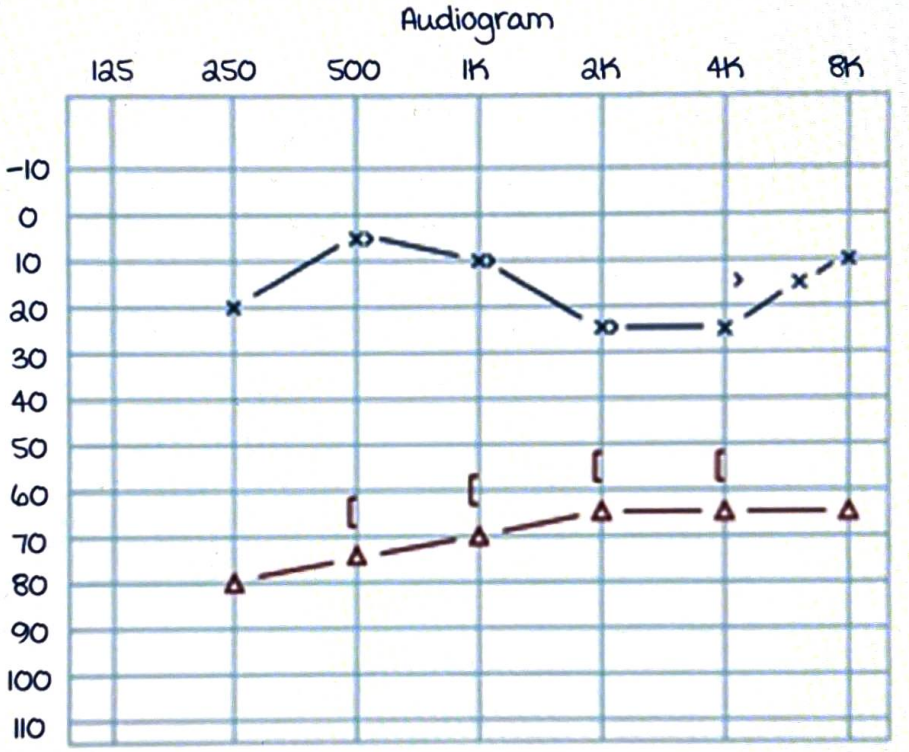

Causes :

- m/c Idiopathic (Viral infections).
- Trauma.
- Tumors (5 – 10% cases of Acoustic neuroma).

Tuning fork test :

Rinne's test : AC > BC → + ve

Weber's test : Lateralizes to the better ear.

Pure Tone Audiometry (PTA) : No AB gap → SNHL.

90c6b3eeaa8ded0ef4e7e5ea7

Active space

Leave Feedba

Management 00:09:19

- Steroids :
  Oral steroids → No improvement → Trans tympanic steroids (Reduce edema and ischemia → hearing loss is reverted).
- Antivirals (Acyclovir).
- Vasodilators.
- Hyperbaric Oxygen.
- Carbogen : 95% oxygen and 5% Carbon dioxide.

If the hearing loss is severe, i.e., >70 dB.
Rinne's test : BC > AC (transcranial transmission → misinterpreted as CHL).
If not treated earlier, it can not revert SNHL.

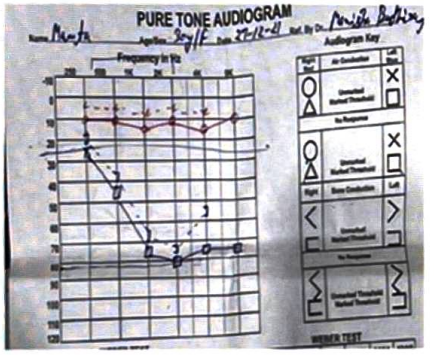

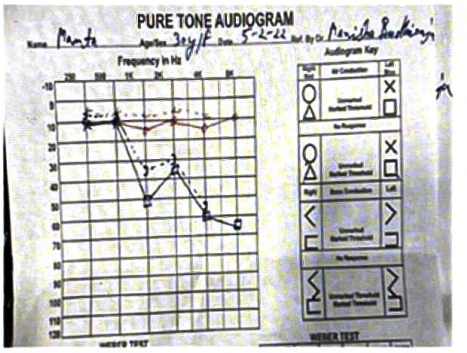

If Rinnes is negative, rule out CHL or severe SNHL by doing Weber's test.
Other conditions of inner ear leading to only hearing loss :

- Noise trauma.
- Ototoxicity.
- Presbycusis.

→ B/L symmetrical high frequency hearing loss

Noise induced hearing loss 00:24:40

Normal recommendation : Maximum of 85 dB for 8 hours a day for 5 days a week.
Whisper : 30 dB.
Normal conversation : 60 dB.
Shout : 90 dB.
Temporary threshold shift : Hearing loss is temporary, where hearing is reverted within 24 hours.

Active space

Leave Feedbac

Permanent threshold shift : Irreversible.

Noise exposure → Early damage of outer hair cell.

Outer hair cell tests : Otoacoustic emission (OAE) → Distortion product is specific.

OAE

Pure tone audiometry can also be used but can be detected only up to 8000 Hz.

Earliest change in PTA : Dip at 4000 Hz bilaterally (acoustic dip) → SNHL.

(Dip at 2000 Hz : Carhart's notch seen in otosclerosis).

Frequencies that are affected early → > 8000 Hz.

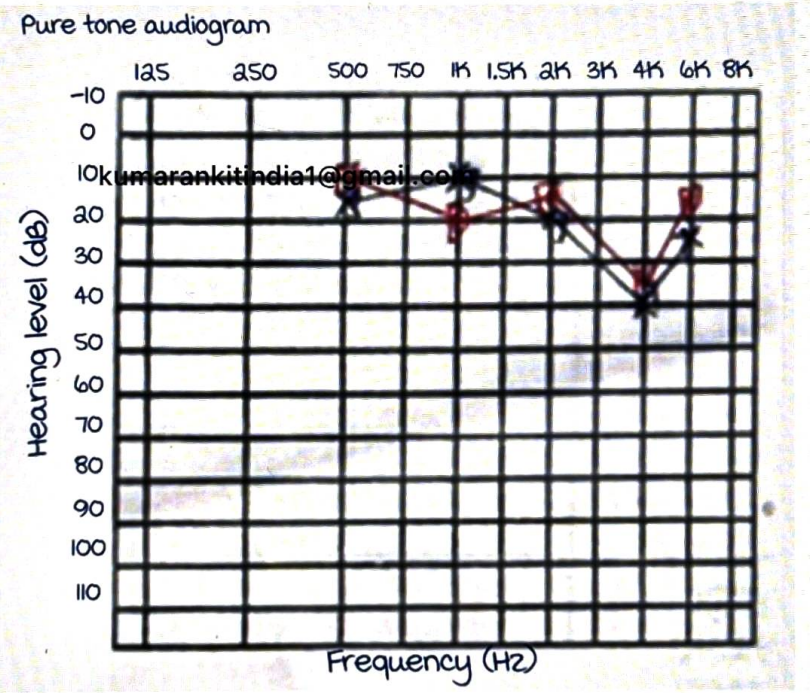

kumarankitindia1@gmail.com

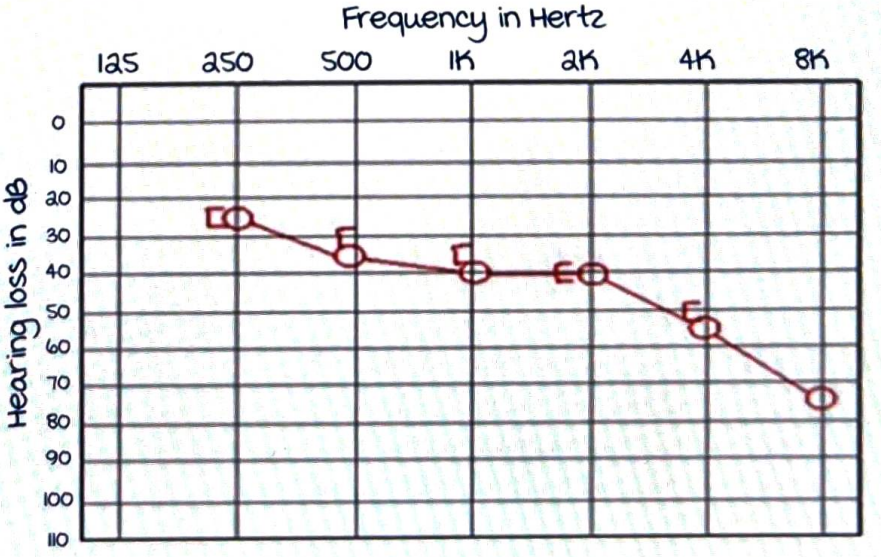

Ear is sensitive up to 20 Hz to 20000 Hz & cannot be detected by usual audiometry.

Active space

Special audiometry used for detection : High frequency audiometry (not normally available).

60c6b3eeaa8ded0e4e7e5ea7

Later all frequencies are affected : Down sloping audiogram (high frequencies are affected).

Impairment measurement 00:35:18

The average pure tone hearing level in the 3 speech frequencies 500, 1000 and 2000 Hz are calculated. If the average is x, then 25 is deducted from it.
E.g., x – 25. This value is multiplied with 1.5.
Average of 3 speech frequencies subtracted from 25 and the value is multiplied by 1.5.

Threshold in 500, 1000, 2000 frequencies is 30dB, 45dB, 60dB respectively.
30+45+60 divided by 3 = 45.
45 – 25 = 20 dB.
20 X 1.5 = 30% hearing impairment.
Hearing loss : 26dB – 92dB = 66dB.
20 = x/100 X 66.
X = 20 X 1.5
X = 30 %.

Hearing handicap :
Hearing impairment in both ears are assessed.
[(Better ear % X 5) + (Worse ear %)] ÷ 6.

Management 00:41:33

Prevention :
Ear plugs & ear muffs → benefit of around 30dB and 40dB respectively.
Treatment : Hearing aid.

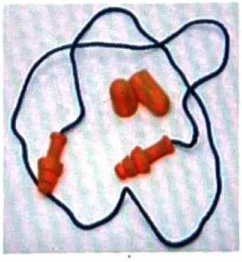

Plug

muff

Active space

Leave Feedbac

Presbycusis

00:43:30

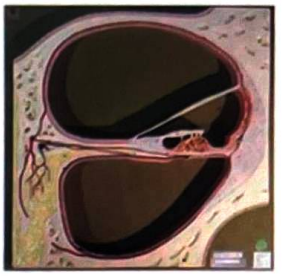

Age related hearing loss.
more than 50 years.
Bilateral symmetrical SNHL.

Parts affected :
Basilar membrane, hair cells of organ of corti,
stria vascularis, nerve starting from organ of coti.

If defect is in :

1. Basilar membrane thickening : Cochlear conductive.
2. Hair cells of organ of corti : Sensory.
3. Stria vascularis : metabolic or vascular.
4. Nerves atrophy : Neural (most common) → Down sloping audiogram (high frequency is affected early).

60c6b3eeaa8ded0e4e7e5ea7

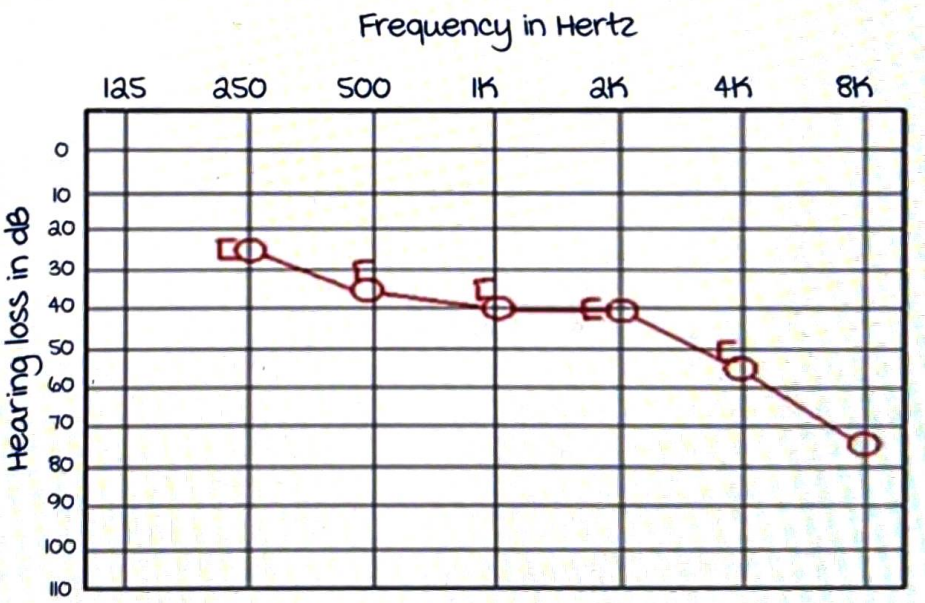

Management :

- Hearing aid.
- If bilateral profound : Cochlear implantation.

Ototoxicity

00:48:34

Drugs are :
Mnemonic : AVCD

Active space

- A : Aminoglycosides, Analgesics, Anti malarials.
  Aminoglycosides : Cochleotoxic and vestibulotoxic.

  Cochleotoxic → Act on inner and outer hair cells.
  (mnemonic : KAN) Kanamycin, Amikacin and Neomycin.
  Neomycin → Most cochleotoxic.

  Vestibulotoxic → Act on Type 1 and Type 2 hair cells.
  Streptomycin and Gentamycin.
  Gentamycin used for chemical labyrinthectomy in meniere's disease.

- V : Vancomycin
- C : Cytotoxic drugs (Cisplatin).
- D : Diuretics (Loop diuretics), act on stria vascularis.
- Macrolides : Erythromycin, Azithromycin , etc.
- Organic solvents : Toluene (causes addiction).

Irreversible hearing loss are :
Cytotoxic drugs like Cisplatin and Aminoglycosides.
Causes apoptosis by free radicals → Permanent hearing loss.

Early diagnosis : Test outer hair cells with OAE (distortion product).

PTA : Bilateral symmetrical high frequency hearing loss (down sloping).

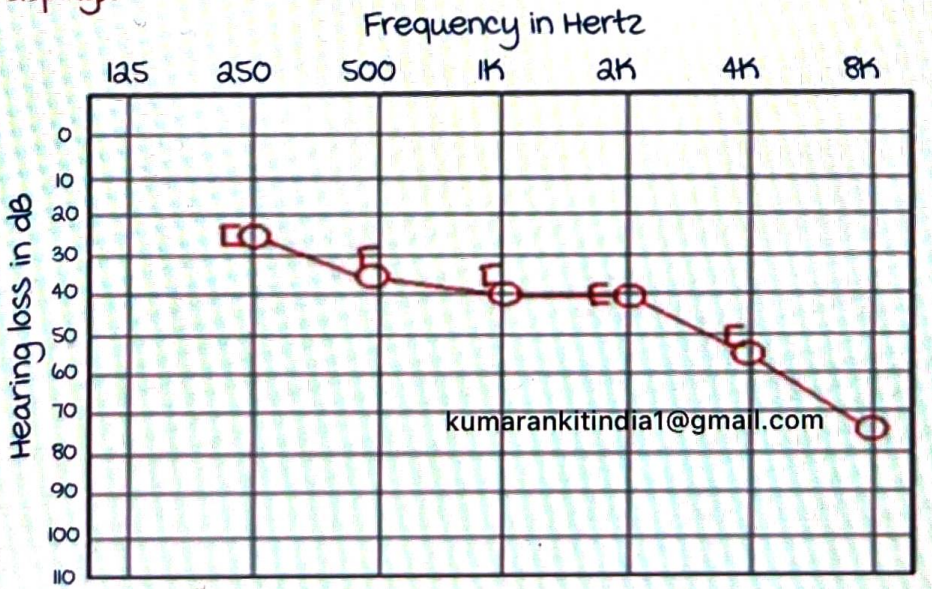

kumarankitindia1@gmail.com

Active space

Leave Feedba

TUMORS OF EXTERNAL AND MIDDLE EAR

Carcinomas of the external ear

00:00:50
60c6b3eeaa8ded0e4e7e5ea7

most common (mc) carcinoma of pinna : Basal Cell Carcinoma (BCC)> Squamous cell carcinoma(SCC).
BCC seen in the sun exposed area : Pinna
mc carcinoma in External Auditory Canal (EAC) : SCC.

Predisposing factors for SCC in the EAC :

- Chronic irritation due to discharge from CSOM.
- Exposure of ear to the radiotherapy of head and neck carcinomas.

Carcinomas of EAC have similar presentations like that of otitis media like discharge, itching, hearing loss and thus leads to a late diagnosis/ its misdiagnosed as COM.
So, any elderly presenting with COM which is not healing, rule out carcinomas of the EAC.
Malignant otitis externa (infective condition) also presents like carcinoma of the EAC.

Presentation of CA of EAC :

- Pain.
- Discharge.
- Necrosis.
- Nerve palsies (mc is facial nerve palsy).

Management :
Early stages : Excision.
Late stages : Surgery followed by radiotherapy.

Exostosis

00:04:28

It is the mc benign tumor of EAC.
There are multiple bony outgrowths present in the deeper

Active space

Leave Feedbac

parts of the bony EAC.
These are physiologically present in seals to protect their ears from cold water.
These are also seen in humans who are repeatedly exposed to the cold water.
It occurs as a reflex to protect the tympanic membrane from caloric stimulation.
Caloric stimulation (with cold /hot temperatures) of the inner ear leads to vertigo.
AKA Surfer's ear.

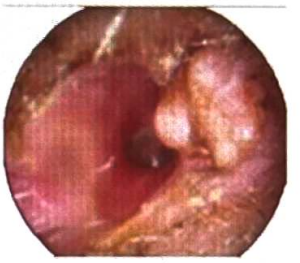

Swimmer's ear : Diffuse otitis externa.
Differential diagnosis : Osteoma (single bony outgrowth from the lateral EAC).
Management : Excision if symptomatic (like impaction of wax, repeated otitis externa).

Glomus

00:08:47

It is the MC benign tumor of the middle ear.
Benign but locally invasive tumor.
Slow growing tumor.
Another term for paraganglioma (cells of neural crest origin, which are more prominent in the areas of nerve plexus).
Paragangliomas of the ear arising from :

kumarankitindia1@gmail.com

- Tympanic plexus(Jacobsons nerve/9th cranial nerve + sympathetic plexus around the internal carotid artery) on the promontory : Glomus tympanicum (MC).
- Jugular bulb in the floor of middle ear (9th, 10th, 11th cranial nerves) : Glomus Jugulare.
  9th cranial nerve : Jacobson's nerve.
  10th cranial nerve : Arnold's nerve.
  Pheochromocytoma is also a paraganglioma which secretes catecholamines.

Active space

Leave Feedbac

Glomus tympanicum and glomus jugulare are the paragangliomas which usually do not secrete any hormones (non-chromaffin tumors).

But, rarely these can present as chromaffin tumor (hormone secreting).

Urinary VMA (vanillylmandelic acid) test is done to rule out chromaffin tumors and to rule out multicentric origin of the tumor.

In around 10% of the cases, these are a part of multicentric tumor.

Sites of head and neck paragangliomas :

- Glomus tympanicum (tympanic plexus).
- Glomus Jugulare (jugular bulb).
- Vagus nerve.
- Carotid body (at the bifurcation of the common carotid).

60c6b3eeaa8ded0e4e7e5ea7

Glomus is more common in females.

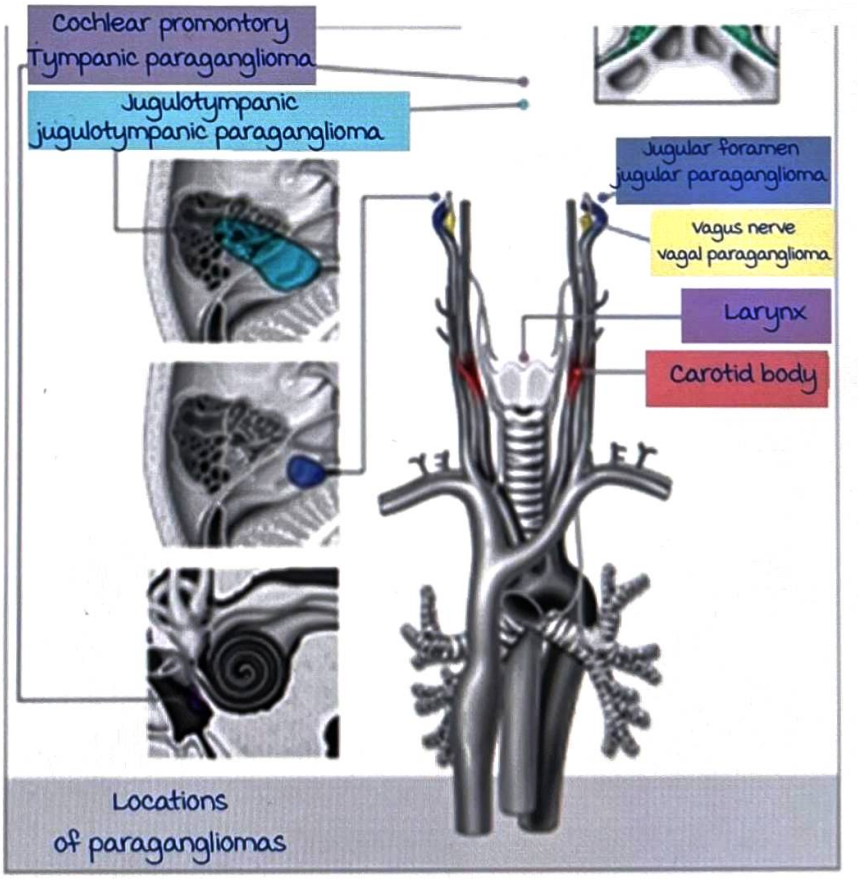

Active space

Leave Feedba

Presentation of Glomus tumor

00:21:10

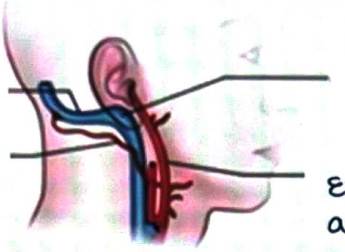

- Conductive hearing loss.
- Pulsatile tinnitus (ringing sensation in the ear without any external stimulus, objective type i.e., loud enough to be even heard by the examiner).
  In case with pulsatile tinnitus always rule out glomus.

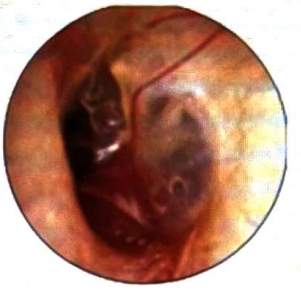

Red reflex/rising sun

- Pulsatile tinnitus of the glomus jugulare is due to the transmission of pulsations from the internal carotid artery.
- Aquino sign : On compression of the internal carotid artery, the pulsatile tinnitus disappears.

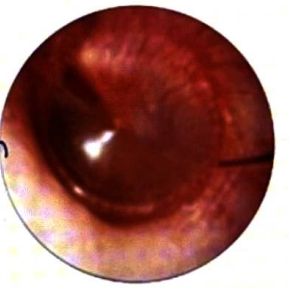

Red TM : ASOM

- Red reflex/rising sun/Setting sun appearance of the tympanic memebrane : Due to the presence of red vascular mass behind the tympanic membrane.

Red tympanic membrane and cartwheel appearance of TM is seen in ASOM which is due to hyperemia of the TM.

60c6b3eeaa8ded0e4e7e5ea7

Siegel pneumatic speculum

- Pulsation sign/ Brown's sign : Blanching of the TM on changing the presures of the EAC with Siegel pneumatic speculum.

Pulsatile otorrhea and Light House sign is seen in ASOM.

Active space

Leave Feedbac

IOC : CECT brain (to look for erosion of the bony part which is pesent between the jugular formen and the carotid canal).

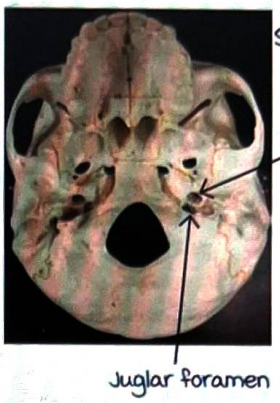

Phlep's sign (on CECT) : Absence of crest of bone which is between the jugular bulb and internal carotid artery. It is seen in Glomus jugulare tumors.

MRI brain : Salt and pepper appearance (due to multiple flow voids along with microhemorrrhages) over the promontory/ jugular bulb area.

Fisch classification of Glomus tumor 00:32:35

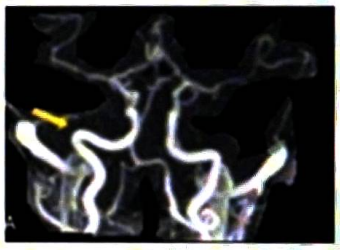

Based on the size of the tumor.

Type A : Tumor is confined to the ME.

60c6b3e8aa8ded0e4e7e5ea7

Type B : ME + Mastoid.

Type C : Infralabyrinthine spread to the carotid arteries.

C1 : Limited involvement of the vertical part of carotid artery.

C2 : Extensive involvement of the vertical part of carotid artery.

C3 : Involvement of the horizontal part of carotid artery.

Intracranial spread :

Type D1 : < 2cm intracranial.

Type D2 : >2cm intracranial.

Tumor spread :

- Laterally to TM :

Presents as a bleeding polyp of the EAC.

Polyp of the EAC should never be avulsed because it could be

Active space

Leave Feedbac

a glomus tumor.

- medially :

The inner ear.

60c6b3eeaa8ded0e4e7e5ea7

- Into the floor :

9th ,10th ,11th cranial nerves get involved.

- Posteriorly :

To the mastoid and involvement of 7th nerve.

Management :

1. Wait and watch : In elderly with very small tumors.
2. Radiotherapy : In elderly who are not fit for surgery and inoperable tumors.
3. < 3cm in size : Sterotactic radiosurgery/gamma Knife.
4. >3 cm in size : Surgical excision.

   Preop investigation includes urinary VMA.

   Preop embolization of the feeding vessels (Ascending Pharyngeal artery, 1st branch of external carotid artery).

Active space

Leave Feedbac

ACOUSTIC NEUROMA

Aka vestibular schwannoma.
It is the most common benign tumor of the CP angle (cerebello-pontine angle).
It arises from the internal acoustic meatus and then extends into the CP angle.
It is benign but locally invasive.
mostly seen in elderly, usually unilateral.
In young individuals, it is seen associated with :

- NF-2 (Neurofibromatosis type 2) : B/L acoustic neuroma.
- NF-1 : Only 5% cases are associated with acoustic neuroma which is usually unilateral.

It is a slow growing tumor.
Not encapsulated tumor. 60c6b3eeaa8ded0e4e7e5ea7

Presenting features :
Growth of tumor in internal acoustic meatus :
It arises most commonly from the vestibular nerve (inferior vestibular nerve > superior vestibular nerve; Recent studies have shown equal incidence in superior and inferior vestibular nerve).

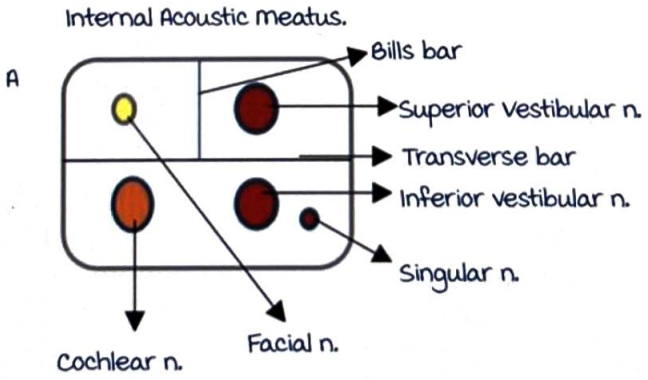

- Due to compression of cochlear nerve : U/L SNHL and tinnitus.
- Due to compression of the vestibular nerve : Patient never presents with vertigo since it's a very slow growing tumor. Due to which vestibular compensation occurs at

Active space

the normal side and at the vestibular centers in the brain and compensates the loss at the affected side (same is the case in vestibular neuritis/chemical labyrinthectomy).
Only mild occasional imbalance can occur.

- Due to compression of the facial nerve (sensory part of nerve is affected first) : Hypoesthesia/anesthesia of the posterosuperior part of the EAC (Hitzelberger sign). It is seen in <25% of the cases only . Difficult to assess and the results are inconclusive. So, this test is clinically insignificant.

Differential diagnosis : Presbycusis (B/L), whereas acoustic neuroma is U/L.

Growth of tumor in the CP angle : Due to involvement of :

- 5th nerve : Paresthesia of face.
  Absent corneal reflex (earliest nerve involved is ophthalmic nerve).
- 6th nerve : Diplopia.

Upper pole of the tumor compresses 5th and 6th cranial nerve.
Lower pole of the tumor compresses 9th,10th & 11th cranial nerves.

Important points 00:21:33

Earliest symptom : U/L SNHL (gradually progressive) and tinnitus. 60c6b3eeaa8ded0e4e7e5ea7
In 5-10% cases there can be sudden SNHL due to compression of the artery which enters through the internal acoustic meatus.
Earliest nerve involved : 8th nerve.
Second nerve to be involved : 5th nerve.

Earliest ocular sign : Loss of corneal reflex > diplopia.
Loss of corneal reflex : 5th nerve > 7th nerve.
If the 5th nerve (absence of corneal reflex) is involved (growth till the CP angle) then the tumor is at least 2.5 cm - 3cm in size.

Active space

Leave Feedba

Investigations for Acoustic Neuroma

1. Tuning fork tests :
   - Rinnes : Positive.
   - Webers : Lateralized to the opposite side.
   - ABC : Shortened.
   - Schwabach : Shortened.

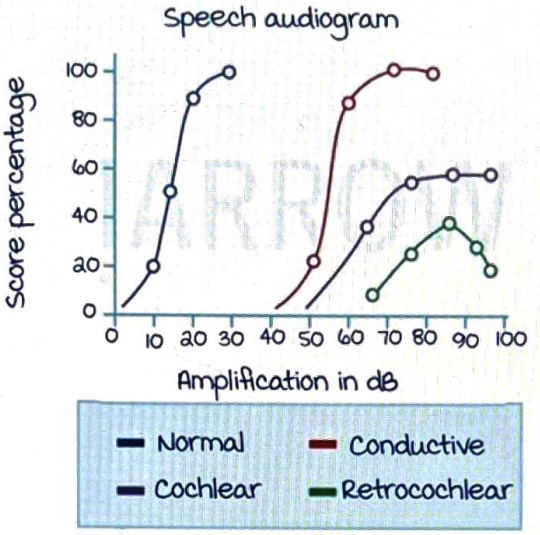

2. Pure tone Audiometry (PTA) : No AB gap.
3. Impendence test (tympanometry and stapedial reflex) : Stapedial reflex decay is seen due to nerve fatigue.
4. Recruitment (it is intolerance to loud sound, feature of cochlear deafness) : Negative.
5. SISI : 0 to 20 % in retrocochlear nerve deafness.
6. Discrimination score (ability of the patient to discriminate between the words) : Very poor.
7. Roll over phenomena : Present (due to nerve fatigue after a certain level of loudness).
8. BERA : It is the best audiometric test.

   Waves seen on BERA :
   - Wave 1 : Distal part of cochlear nerve.
   - Wave 2 : Proximal part of cochlear nerve.
   - Wave 3 : Cochlear nuclei.
   - Wave 4 : Superior olivary complex.
   - Wave 5 : Lateral lemniscus (largest wave and the last wave to disappear in any pathology).

kumarankitindia1@gmail.com

Active space

Leave Feedbac

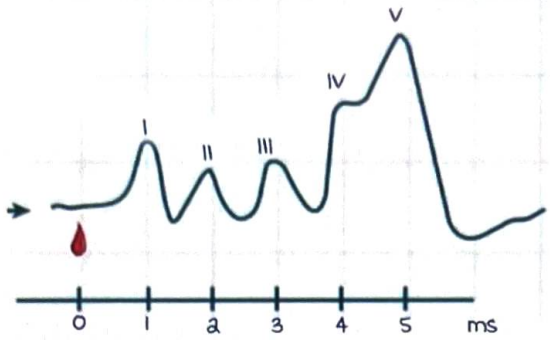

- Wave 2 is affected in BERA because the tumor arises from the Internal acoustic meatus, wherein the progression of wave 2 is delayed.
- The latency between wave 1 and 5 will increase (2nd best finding).

MRI cystic

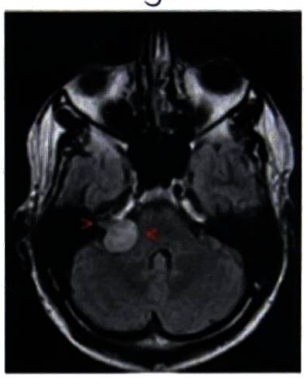

- Wave 1 is also affected sometimes if there is compression of the vascular supply to the distal part of the nerve.
- Interaural latency difference of wave 5 of more than 0.2 milli seconds is suggestive of acoustic neuroma (best finding).

$0c6b3eeaa8ded0e4e7e5ea7

9. MRI with gadolinium enhancement : It is the best investigation overall.
   - Ice-cream cone appearance.
   - Size of the tumor.
   - Cystic tumor (sudden growth).

Antoni A and B

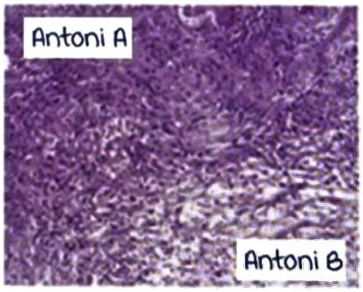

10. Histopathology of acoustic neuroma :
    - Antoni A cells : Tightly packed.
    - Antoni B cells : Loose arrangement with cystic areas (bad prognosis).
11. VEMP (vestibular evoked myogenic potential) : To identify if the tumor is arising from superior vestibular nerve or the inferior vestibular nerve.

Active space

Leave Feedba

- If tumor arises from superior vestibular nerve, then ocular reflex is abnormal.
- If tumor arises from the inferior division, the SCM reflex is abnormal.

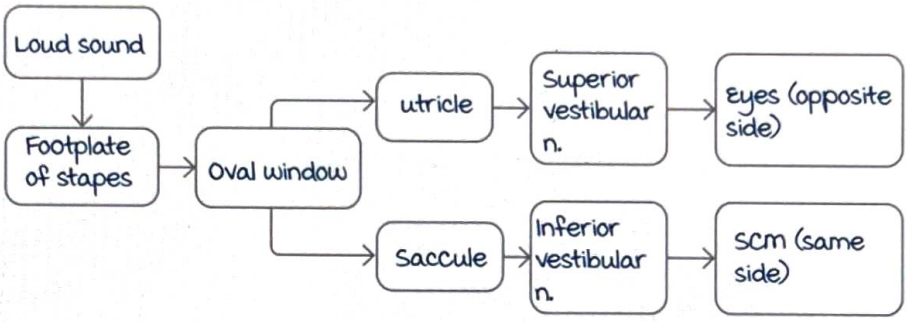

Management of acoustic neuroma 00:41:18

- Elderly, slow growing tumor limited to the IAC which is not cystic : Wait and watch.
- < 3 cm in size : Stereotactic radiosurgery/Gamma Knife (radiation is focused on the tumor).
- > 3 cm in size and cystic tumors of any size : Surgical excision of the tumor.

Rehabilitation of hearing post surgery in B/L cases :
By ABI (Auditory Brain Stem implant).
Electrode of the cochlear implant is passed through the middle ear, round window and into the Scala tympani and directly stimulating the cochlear nuclei in the lateral recess of the 4th ventricle.

60c6b3eeaa8ded0e4e7e5ea7

Active space

Leave Feedbac

FACIAL NERVE : PART 1

Parts of facial nerve

00:01:10

Intracranial part :
From origin to
internal acoustic meatus (IAM)

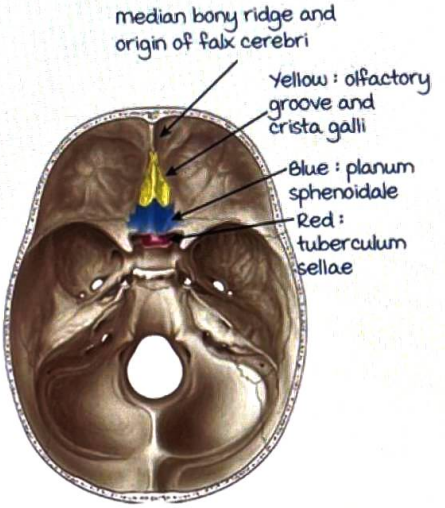

Intratemporal Part :
From internal acoustic meatus
to stylomastoid foramen.

Extracranial part :
From stylomastoid foramen
to structures supplied by it.

meatal segment : In internal acoustic meatus.

Labyrinthine segment :
In inner ear.
Covered by the shortest and narrowest part of the fallopian canal.
Most commonly involved in viral infections leading to compression and ischemia of facial nerve palsy.

60c6b3eeaa8ded0e4e7e5e37

Enters into the medial wall of the middle ear.
Takes turn : 1st genu of the facial nerve.

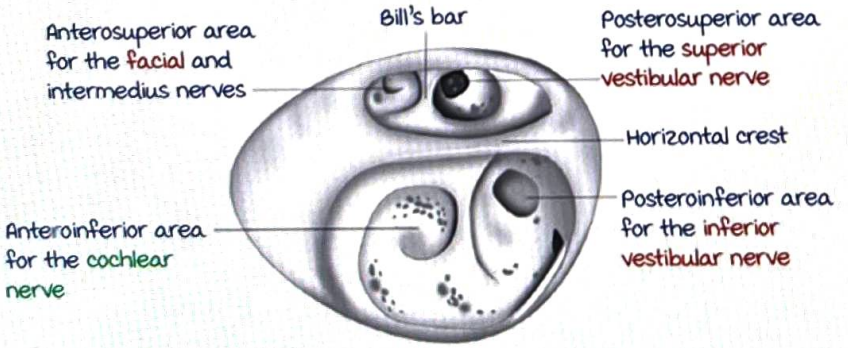

Horizontal/Tympanic segment :
Runs horizontally on the medial wall.

Active space

Leave Feedback

Landmarks :

- Processus cochleariformis.
- Oval window.
- Lateral semicircular canal.

Most common site of dehiscence of fallopian canal.
Most common congenital abnormality of the temporal bone.

Mastoid segment :
Known as descending or vertical segment.
Longest segment ~ 13mm.

Landmarks :

- Pyramid : The facial nerve is posterior and lateral here.
- Aditus : The facial nerve is inferior to it.
- Fossa incudis : The facial nerve is medial & inferior to it.
- Chorda tympani : The facial nerve is medial to it.

Most commonly injured in mastoid surgeries : 2nd Genu area.

60c6b3eeaa8ded0e4e7e5ea7

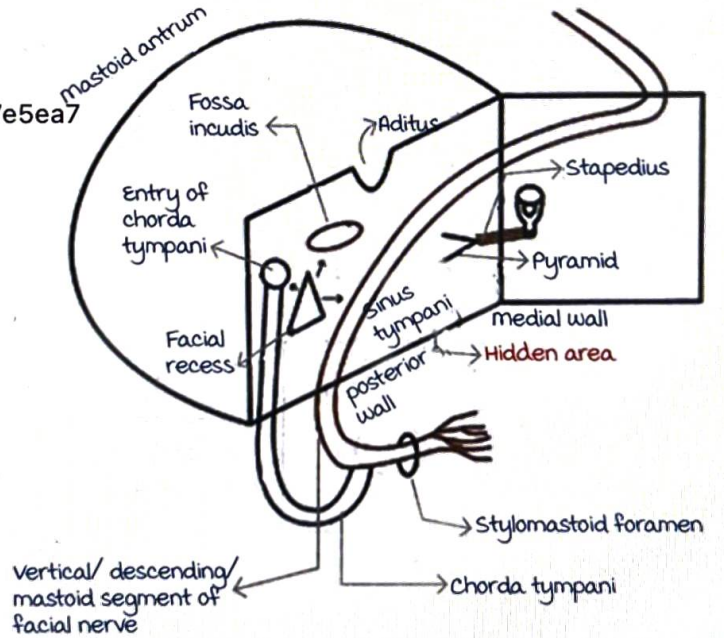

Branches of Facial nerve 00:13:55

1st branch : From the 1st genu, greater superficial petrosal nerve goes to the sphenopalatine ganglion. Responsible for :

- Lacrimation.
- Nasal secretion.
- Palatine secretion.

Active space

Leave Feedbac

If damaged : Dry eye (detected by Schirmer's test).

2nd branch : Given off at the pyramid.
In the middle ear lies the nerve to stapedius.
Injury : Absence of stapedial reflex.
kumarankitindia1@gmail.com
Leads to hyperacusis : Normal sounds become loud.

Just 4-6mm before stylomastoid foramen : Chorda tympani (3rd branch).

- Enters middle ear through the posterior wall.
- Exits middle ear through anterior wall by foramen of heuer.
- Supplies Anterior 2/3rd of tongue : Taste.
- Salivation from Sublingual & Submandibular salivary glands.

Vertical/descending/mastoid segment of facial nerve :
Branch : Sensory auricular branch supplies posterior superior external acoustic meatus + adjacent part of external auditory canal.

Topodiagnostic test : Will tell about the site of the lesion.

- Schirmer's test.
- Stapedial reflex.
- Taste.
- Salivation : Tested by electrogustometry.

Electrodiagnostic test : Will assess the prognosis.

1. Electroneuronography (ENOG) : Nerve is stimulated to look for muscle response & it is compared with normal nerve. Wait for 3 days after injury.

Nerve injured : Wallerian degeneration takes around 3 days.

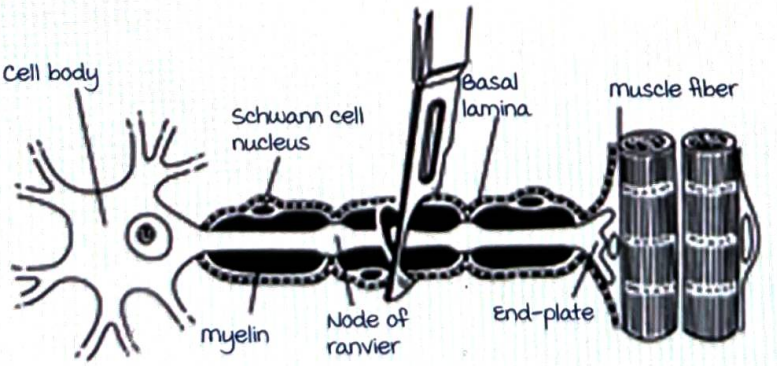

Active space

Leave Feedba

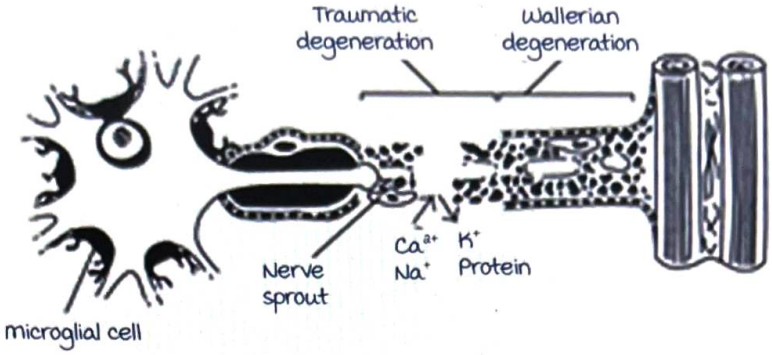

2. Electromyography (EMG) : Electrodes are placed in the muscles and response are monitored.

After 3 weeks.

Action potential indicates a sign of recovery.

Fibrillation potential indicates bad prognosis.

Functions of facial nerve :

- Taste from ant. 2/3 : Special visceral Afferent.
- Parasympathetic secretomotor supply to lacrimal, submandibular and sublingual salivary glands : General visceral efferent.
- Cutaneous sensation from pinna : General somatic Afferent.
- Motor supply to facial muscles : General Somatic Efferent.

Bell's palsy

00:31:10

Acute onset Lower motor neuron facial palsy (after nuclei).

60c6b3eeaa8ded0e4e7e5ea7

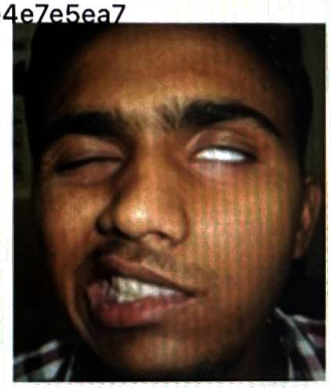

Cause : Idiopathic.

In 60% patients HSV I infection seen.

Site : Labyrinthine segment.

Presentation :

- Dry eye.
- Hyperacusis.
- Loss of taste in anterior 2/3rd of tongue + Salivation.
- Facial palsy on the same half of face.

In upper motor neuron palsy(before nuclei) the forehead is spared. As forehead has dual supply.

Active space

Management :

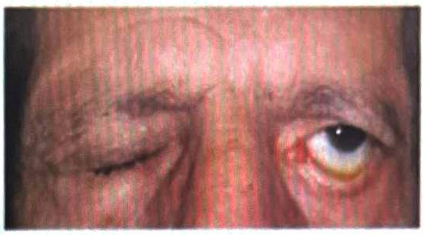

- Within 3 days : Antivirals.
- Steroids.
- Physiotherapy : Facial exercises, nerve stimulation.
- Eyecare.
- Lubrication : Eye drops.
- Closure of eyes.
- Vitamin B12.

60c6b3eeaa8ded0e4e7e5ea7

Recurrence ~ 10 %.

Increased chances in Diabetes, AIDS, Pregnancy.

If decompression is required it is to be done on the Labyrinthine segment.

Melkersson Rosenthal syndrome 00:44:20

Idiopathic facial nerve palsy.

Recurrent and alternating palsy.

Swelling of lips and fissuring of the tongue.

Infections and injuries causing Facial nerve palsy.

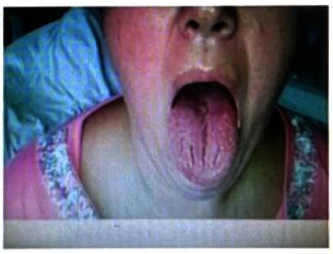

External auditory canal : malignant otitis externa.

Herpes zoster : Ramsay Hunt syndrome.

Acute otitis media : Only seen if there is dehiscence of fallopian canal. Managed by myringotomy.

Chronic otitis media : Modified radical mastoidectomy.

malignant otitis externa

Active space

Leave Feedba

FACIAL NERVE : PART 2

m/c surgical cause of facial palsy → Parotid.
Facial nerve is protected by the bony canal of mastoid while running through it.
Facial nerve lies exposed in the parotid gland and divides it into superficial & deep (risking injury in both surgeries).

Traumatic iatrogenic causes of facial nerve palsy

00:00:48

MC Iatrogenic cause → Parotid surgery.
2nd MC Iatrogenic cause → Mastoid surgery.
MC site injured in Mastoid surgery → Vertical segment (2nd Genu).

Precautions taken to prevent injury to facial nerve during mastoid ear surgery :

- Pre-op HRCT to get an idea about the disease extension before the surgery.
- Largest sized burr according to the surgical site should be used to prevent injuries.
- Irrigation while drilling the mastoid to clear bone dust and nullify the heat produced by drilling of bone.
- Magnification while drilling through the facial recess.
- Identify the landmarks.
- Drill along the nerve (parallel to the direction of the nerve) while drilling through the facial recesses.

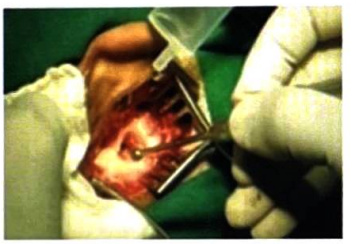

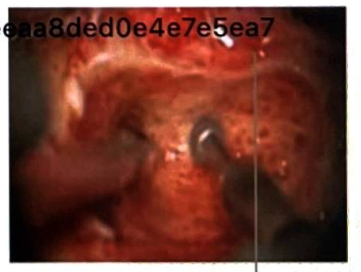

Facial recess



Drill parallel to direction of nerve

Active space

Leave Feedba

- Diamond burr should be used instead of a cutting burr while drilling close to the nerve.
- Intraoperative nerve monitoring should always be done, if available.

Traumatic non-iatrogenic causes of facial nerve palsy

00:08:20
60c6b3eeaa8ded0e4e7e5ea7

Fracture (#) of temporal bone

Types based on relationship to the long axis of the petrous part of temporal bone :

- Longitudinal # of temporal bone (# parallel to the long axis).
- Transverse # of temporal bone (# perpendicular to the long axis).

Longitudinal # passes through the roof of the external auditory canal, middle ear & anterior to inner ear.

Patient will have conductive hearing loss and rupture of tympanic membrane.

Since tympanic membrane is ruptured, CSF will leak through middle cranial fossa → Tegmen tympani → CSF otorrhea.

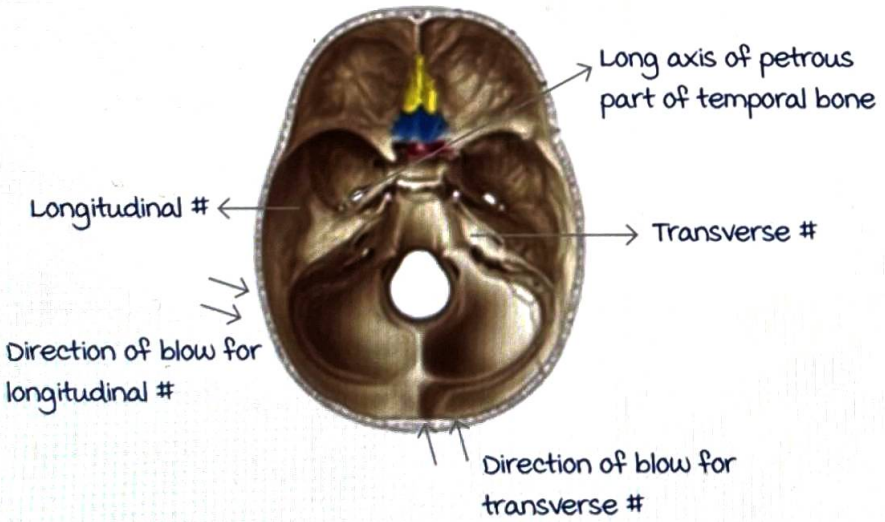

Fracture of temporal bone

Active space

Leave Feedba

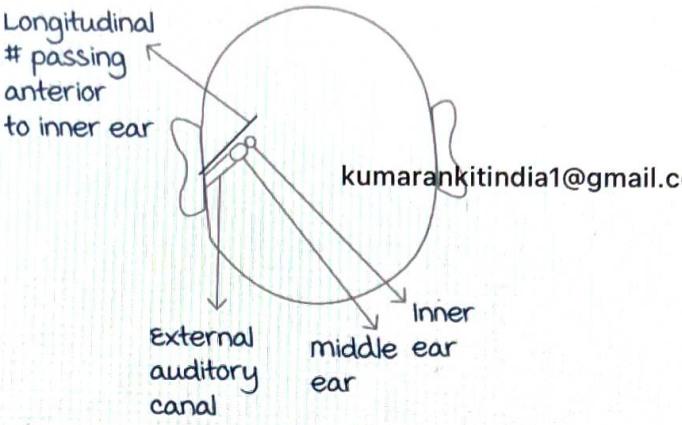

kumarankitindia1@gmail.com

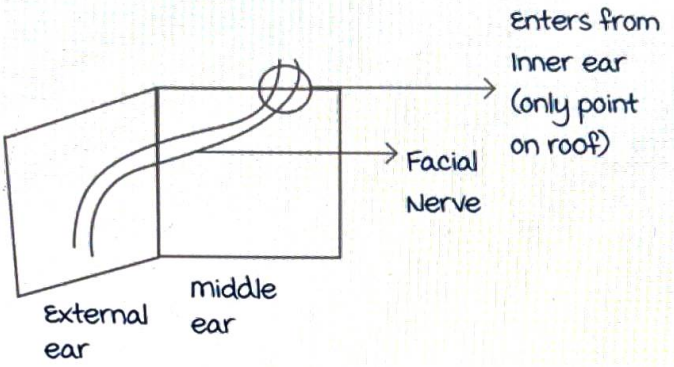

Facial nerve Injury is not common as facial nerve only passes through one point in the roof of middle ear (when it enters middle ear through internal ear).

Transverse # passes through roof of external auditory canal, middle ear.
Tympanic membrane is intact & CSF will collect in the middle ear → Through Eustachian tube → CSF ottorhinorrhea.

	Longitudinal #	Transverse #
Incidence	more common	
Direction of blow	Lateral	Postero-anterior
Tympanic membrane perforation	Present	Absent
Hearing loss	Conductive hearing loss	Sensory-neural hearing loss (SNHL)
Vertigo	No	Yes
Facial nerve	Not common	Yes
CSF otorrhea	Yes	No
CSF rhinorrhea	No	Yes

Active space

Leave Feedba

Investigation of choice : HRCT of temporal bone.

Transverse #

Longitudinal #

60c6b3eeaa8ded0e4e7e5ea7

Hemotympanum

Battle sign

Fracture of temporal bone :

- Hemotympanum (bluish discoloration behind tympanic membrane).
- Bruising & Ecchymosis behind ear → Battle sign. (Basilar skull fracture/ fracture of temporal bone).

Post mastoid surgery → Facial nerve is intact & patient can smile after the anesthesia effect wears off → Paralyzed the next day (late onset palsy) → Surrounding edema causes compression of facial nerve → Steroids.

If immediately post mastoid surgery and anesthesia effect, the facial nerve is paralyzed (sudden onset palsy following trauma) → Facial nerve transection suspected → Immediate re-exploration → End to end repair/grafting of facial nerve from greater auricular nerve.
m/c graft → Greater auricular nerve.
Longer graft → Sural nerve.

Aberrant regeneration of facial nerve 00:24:08

- Synkinesis → When one group of muscles contracts and so does the other group.

Active space

Leave Feedba

- Crocodile tears Gustatory lacrimation (while eating, lacrimation only on side of injury) → Injury before greater superficial petrosal in labyrinthine segment → managed by injection botulinum in lacrimal gland.

60c6b3eeaa8ded0e4e7e5ea7

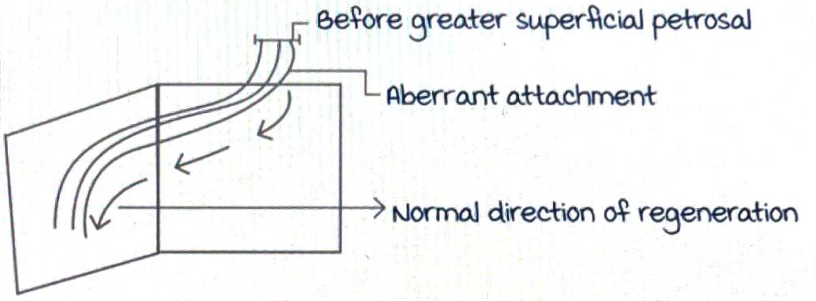

Aberrant attachment while regeneration

Frey's syndrome : Parotid is supplied by otic ganglion through auriculotemporal nerve parasympathetically.
In surgery, if the nerve gets transected during regeneration , the nerve aberrantly attaches to the sympathetic sweat glands of parotid.

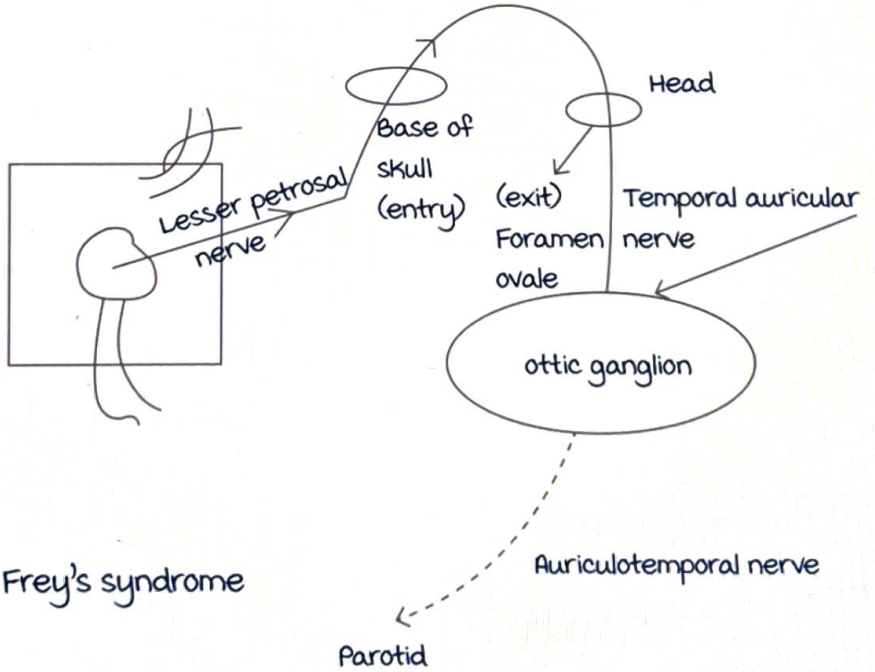

Frey's syndrome

Structures exiting through Foramen Ovale :

- Mandibular nerve.
- Accessory meningeal artery.
- Lesser petrosal nerve.
- Emissary vein.

Active space

Leave Feedbac

Management :

1. Tympanic neurectomy (earlier).
2. Botox injection (temporary).
3. Implantation of graft below skin.

Minor's iodine starch test :
Paint skin overlying the parotid by iodine → Spray starch powder over it. Patient is given something to chew, sweating occurs turning iodine wet turning bluish brown confirming Frey's syndrome and helps marking the affected area.

Minor's iodine starch test

Parts of facial nerve 00:35:54

Intratemporal :

- Meatal segment.
- Labyrinthine (narrowest part of fallopian canal).
- Tympanic (Horizontal) : MC site of dehiscence in fallopian canal.
- Vertical : M/C part injured during mastoid surgery.

Landmarks for identification of facial nerve during parotid surgery :

- Tragal pointer → Facial nerve is 1 cm infero-medial.
- Posterior belly of digastric muscle → Facial nerve is superior and parallel and supplies the muscle.
- Styloid process → Facial nerve is lateral and supplies it.
- Tympanomastoid suture → Facial nerve 6-8 mm deep.
- Facial nerve bisects the angle between mastoid and bony EAC.
- If peripheral branches are identified, facial nerve main trunk can be followed in retrograde direction.

Modified Blair incision : Lazy-S incision is made & skin is raised over the parotid.
Tragal pointer is exposed, facial nerve is 1cm deep and inferior.

Active space

Leave Feedbac

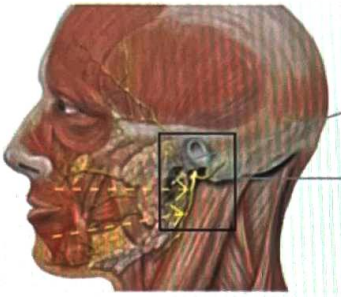



Lazy-S incision

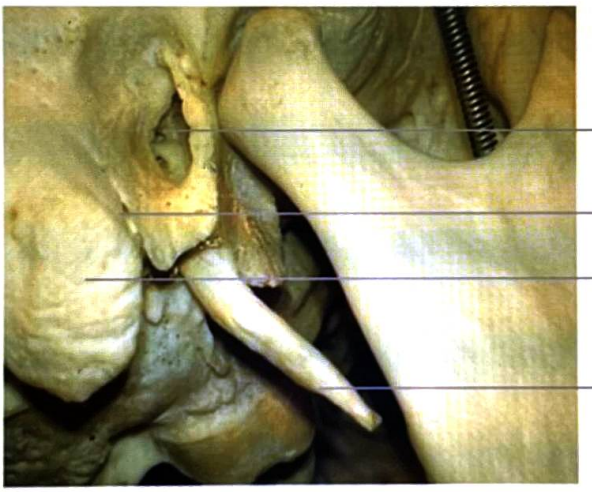

60c6b3eeaa8ded0e4e7e5ea7
Active space

221
Leave Feedbac

HEARING REHABILITATION

Cochlear implant

00:01:58

60c6b3eeaa8ded0e4e7e5ea7

1st artificial sense organ invented by William F House.

Father of neuro otology : William F House.

Cochlear implant replaces organ of corti.

Indications :

- Defect of organ of corti :
  Assessed by Oto acoustic Emission (OAE) & Brainstem evoked response audiometry (BERA).
- Bilateral severe to profound sensorineural hearing loss (SNHL) :
  > 70 db hearing loss in all frequencies.
  > 90 db hearing loss in 2000 & 4000 Hz.
- The nerve has to be functional.
- No result from hearing aid trial of at least 3 months.
- The patient should be mentally and physically stable.
- The cochlea has to be present.
- The central auditory pathway has to be functional.

Types of deafness :

1. Prelingual deafness :
   - Children who are born deaf.
   - Becomes deaf before development of speech because of meningitis like conditions (child has not learned to speak yet).
   - Cochlear implant has to be done as early as 1 year and maximally at < 7 years, because speech centers develop maximally at 3 years of age.
2. Post lingual deafness :
   - In people who have already developed speech (who can understand and speak).
   - A cochlear implant has no age criteria (as early as possible because auditory deprivation leads to nerve becoming dysfunctional).

Active space

Leave Feedbac

Components of cochlear implant

00:12:28

1. External component :

- Microphone :
  Picks up sound.
- Speech processor :
  Convert sounds to digital signals.
- Transmitter coil :
  Transmitting digital impulses inside.

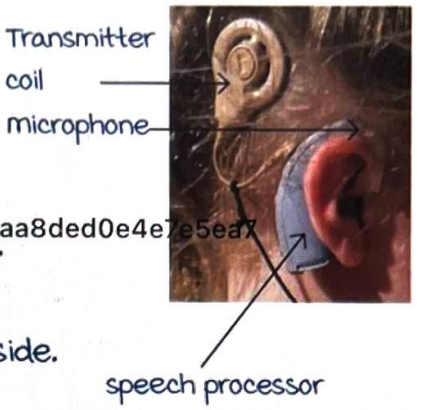

60c6b3eeaa8ded0e4e7e5ea7

2. Internal component :

- Receiver stimulator :
  Receives signal from transmitter coil.
  Converts digital signals into electrical impulses.

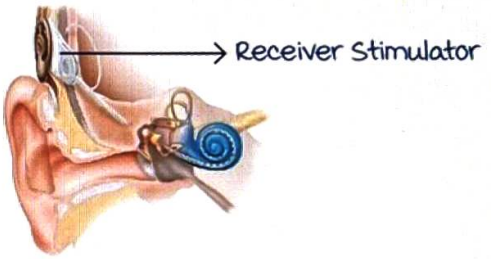

Electrodes ⟶ Mastoid drilled to insert electrodes ⟶ Pass through facial recess into middle ear ⟶ Via round window ⟶ Into inner ear (scala tympani) ⟶ Replace organ of corti ⟶ Stimulate cochlear nerve.

- Mondini's aplasia :

Cochlea has 1.5 turns, hence cochlear implant can be placed.

- Michel aplasia :

Absence of inner ear; Cochlear implant can't be placed.

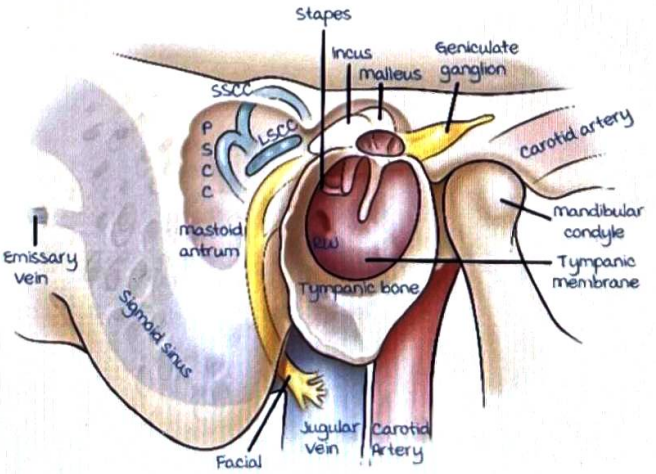

Active space

Leave Feedba

Boundaries of facial recess :

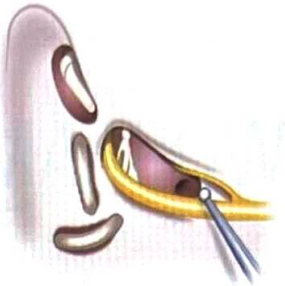

Medially :

Descending part of facial nerve.

Laterally :

Chorda tympani nerve.

Superiorly :

Incus buttress (Near the short process of incus).

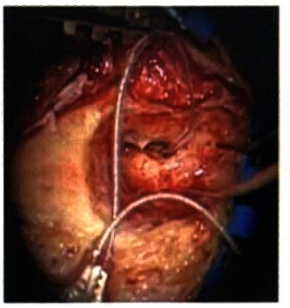

Auditory brainstem implant (ABI) 00:28:20

Indications :

- Bilateral cochlea aplasia.
- Bilateral nerve aplasia/ damage (NF-2).

Placement :

- Lateral recess of 4th ventricle.

kumarankitindia1@gmail.com

Stimulates cochlear nucleus directly.

External component is similar to cochlear implant.

Electrodes placed over lateral recess.

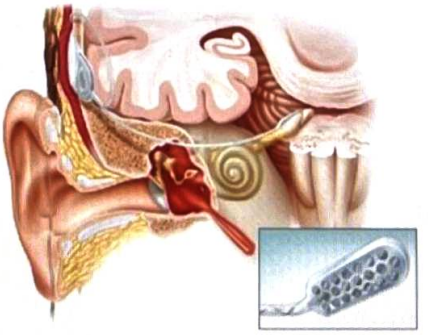

Hearing aids 00:31:43

Bone anchored hearing aids (BAHA) :

Indications :

- Situations where normal hearing aid can't be used :

Active space

Leave Feedbac

1. Congenital deformities of external ear.
2. Discharging ears.
3. Following MRM (Big mastoid cavity).

60c6b3eeaa8ded0e4e7e5e57

- Single side deafness (unilateral deaf ear).

Components of BAHA :

- Implant/ fixture.
- Abutment.
- Speech processor.

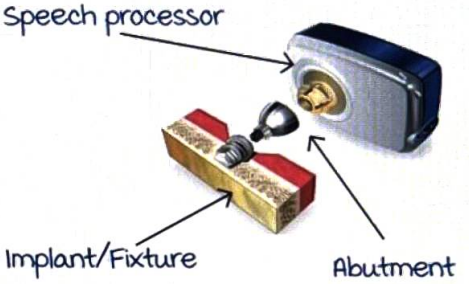

Implant is passed into bone (osseo integration) ⟶
Send vibrations directly into the inner ear.

Eligibility criteria :

Age :

- According to US FDA guidelines, done in children ≥ 5 years.
- Sensorineural hearing loss ≤ 45 db.

Conventional hearing aids :

1. Air conduction hearing aids.

Types :

- Behind the ear hearing aids.
- In the canal hearing aids.
- Completely in the canal hearing aids.

Active space

Parts :

- Microphone : Picks up sound & convert into electrical impulses.
- Amplifier : Amplifies electrical impulses.
- Receiver : Converts electrical impulses back to sound.

2. Bone conduction hearing aids :

Hearing aid placed over the mastoid.

Non invasive.

BAHA has an advantage of 15 db over bone conduction hearing aids.

60c6b3eeaa8ded0e4e7e5ea7

3. Contralateral routing of signals (CROS) :

Patient is placed with 2 air conduction hearing aids like device over both ears.

One side (deaf ear) collects sound and transmits these signals to hearing aid over normal side.

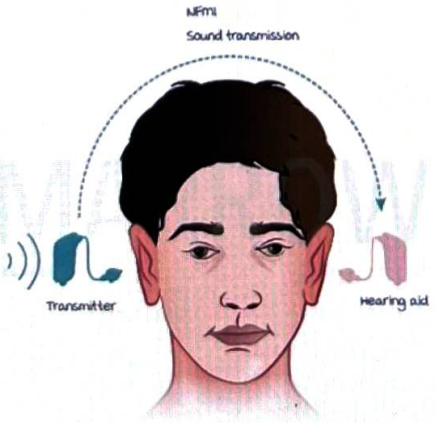

Active space

Leave Feedba

CLINICAL ANATOMY OF EXTERNAL NOSE AND CHOANAL ATRESIA

Choanal atresia

00:01:25

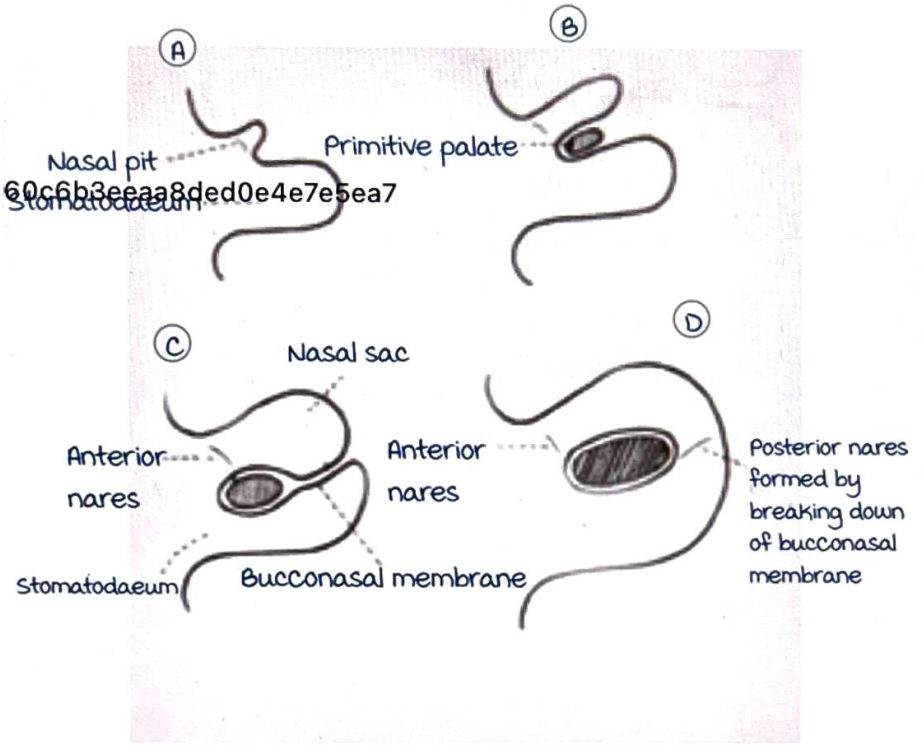

60c6b3eeaa8ded0e4e7e5ea7

Choana : Another term for posterior nasal apertures.

During development there develops a depression known as the nasal pit, this nasal pit grows medially and forms the nasal cavity.
It further grows medially to form the nasopharynx.
Below nasal pit, there is another depression called stomatodaeum that leads to the formation of oral cavity and oropharynx.
The primitive nasopharynx is separated from the primitive oropharynx by a membrane called the bucconasal membrane.
The bucconasal membrane usually disappears after birth and the nasopharynx communicates with the oropharynx.
Choanal atresia is, persistence of the bucconasal membrane.

Active space

Leave Feedback

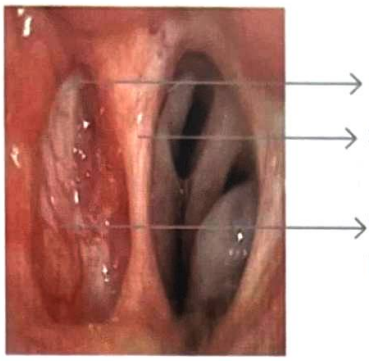

60c6b3eeaa8ded0e4e7e5ea7

Choanal atresia can be unilateral or bilateral/complete or incomplete/bony or membranous or mixed.
70% of choanal atresia is mixed (Bony + Membranous), it is the most common type of choanal atresia.
30% is pure bony.
Patients with unilateral persistent bucconasal membrane/ choanal atresia will not present with respiratory distress. However, they will have nasal obstruction that manifests later.
Infants with bilateral choanal atresia, will have respiratory distress and atresia can be confirmed by passing a nasogastric tube into infant's nostril and checking for it to enter the mouth (normal), in case of bilateral choanal atresia the tube gets stuck.
Infants are obligatory nasal breathers for 4–5 months.
∴ Cyclical cyanosis that relieves on crying.

Immediate management :
Mc Govern's technique is used, where a feeding nipple is taken, and the bore of the nipple is made wider and inserted into the infant's mouth. The mouth is kept open actively and the baby can breathe through it.
Once the child is no longer in distress, CT scan can be taken to confirm choanal atresia.

CT-Axial view depicting b/l choanal atresia

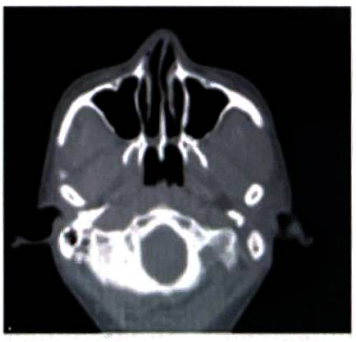

Definitive management :
Excision + Mitomycin C to prevent synechiae formation.

Active space

Leave Feedbac

Choanal atresia is associated with CHARGE syndrome :

Coloboma/cranial nerve abnormalities.
Heart defects.
Atresia of choana.
Retarded growth and development.
Genitourinary defects.
Ear abnormalities.

kumarankitindia1@gmail.com

Charge syndrome

Charge syndrome

Meningocele

00:13:55

Whenever there is a defect in the base of skull (roof of the nose), brain tissues may herniate.
It may be just the meninges called meningocele or it may be meninges + brain called meningoencephalocele.

meningocele

meningocele

meningocele

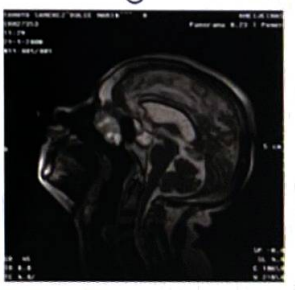

Meningocele v/s Glioma :

In glioma the intracranial connection gets obliterated. The mass is visualized but the connection between the mass and the brain tissue will be absent. There may be a stalk or a fibrotic segment but no open connection between the mass and the intracranial tissue.

Active space

Leave Feedback

	meningocele	Glioma
Intracranial connection	Present.	Absent.
On compression	Soft, Compressible, bluish and pulsatile.	Firm, not compressible, not pulsatile.
Furstenberg test (Whenever the child cries the mass enlarges due to increase in intracranial pressure).	Positive.	Negative.
Transillumination	Present.	Absent.
MC site	Occipital > Frontal.	60% extra nasal, 30% intranasal, 10% mixed.
Complication	Recurrent meningitis, CEF leak, CSF rhinorrhea.	Absent.

Any infant with polypoidal mass in the nostril, differential diagnosis is meningocele, meningoencephalocele, it is never polyp in infants.

60c0b3eeaa8ded0e4e7e5ea7

Imaging investigations like CT and MRI is to be done. CT shows the bony abnormalities whereas MRI shows where the herniation has occurred or what the intracranial defect is.

meningocele endoscopy

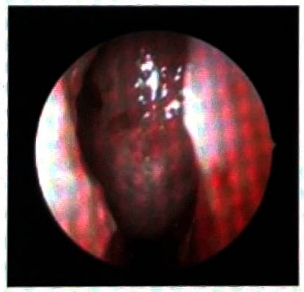

meningocele MRI

meningocele MRI

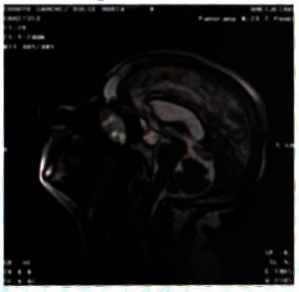

Management :

In meningocele, excision of all the non-functional brain tissue and closure of base of skull defect is done. Whereas in glioma, the mass is excised.

Active space

Leave Feedba

Anatomy of external nose

00:21:18

Upper 1/3rd → Bony.
Lower 2/3rd → Cartilaginous.

In the bony part, there are 2 nasal bones and just lateral to these bones is a process of maxilla coming up, called the frontal process, as it goes up to articulate with the nasal process of frontal bone which comes down.

In the cartilaginous part, there is a 'U' shaped cartilage called the alar cartilage/lower lateral cartilage.
It has a lateral crux which forms the external nose and the medial part which forms the nose. Upper to alar cartilage is the upper cartilage known as the upper lateral cartilage.
Sesamoid cartilage is another paired cartilage.

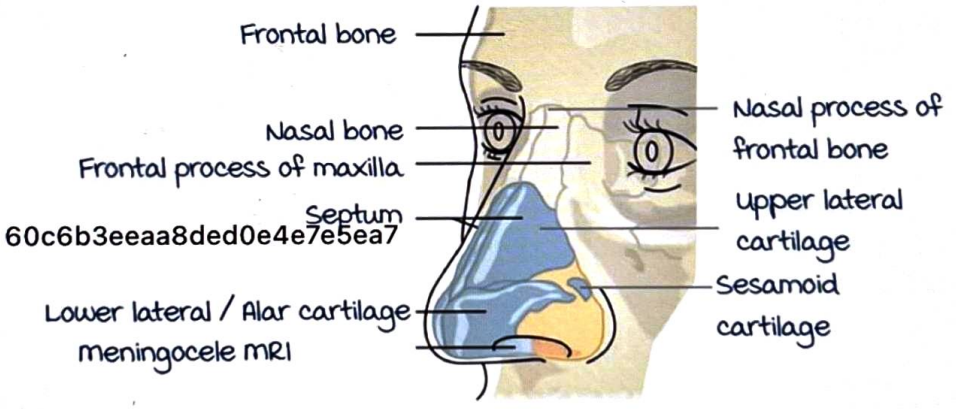

Septum forms the unpaired cartilage of the nose.

∴ The paired and unpaired cartilages of the nose are :

Paired cartilage	Unpaired cartilage
Upper lateral cartilage.	Septum.
Lower lateral cartilage/alar cartilage.	
Sesamoid cartilage.	

Active space

Leave Feedback

Intersection areas

00:25:47

The junction of the frontal bone with the nasal bone → Nasion.
The junction of the nasal bone with the upper lateral cartilage → Rhinion.
The junction of the upper lateral cartilage with the lower lateral cartilage → Limen nasi (forms a part of the nasal valve area, narrowest part of the nasal cavity as the lower border of upper lateral cartilage projects inside).
On the inner surface of limen nasi is the inferior turbinate.

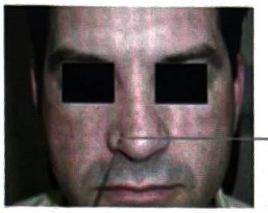

Inferior turbinate

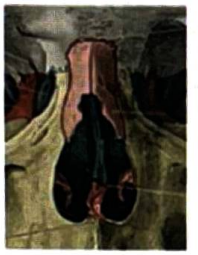

The boundaries of the internal nasal valve area/narrowest part of nasal cavity :

- Lateral boundary : Limen nasi/lower (caudal) border of upper lateral cartilage, inferior turbinate.
- Medial boundary : Septum (where Limen nasi meets the septum).
- Inferiorly : Floor of the nose.

Nasal valve angle = 10–15 °.

kumarankitindia1@gmail.com

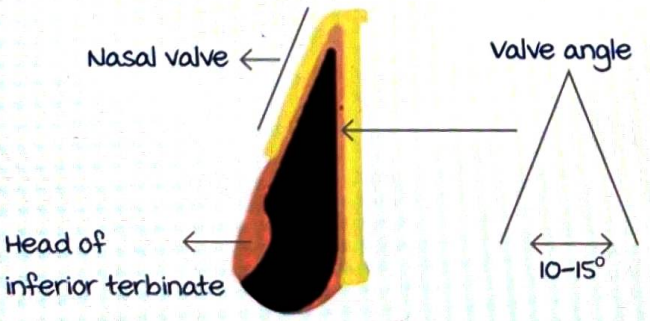

Boundaries of the nasal valve

Active space

Leave Feedba

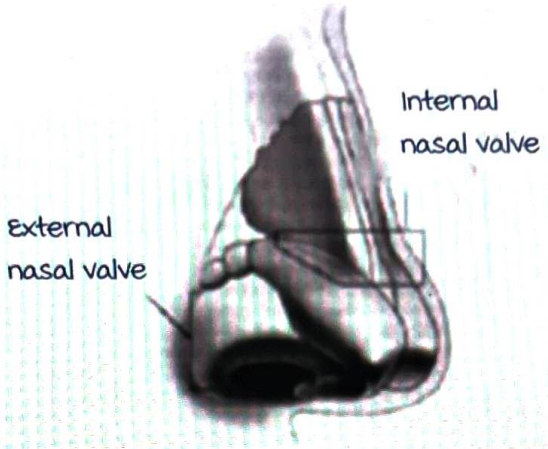

The external opening is called the external nasal valve.

Significance of internal nasal valve area :
Offers maximum resistance to nasal airflow both during inspiration as well as during expiration.

60c6b3eeaa8ded0e4e7e5ea7

During inspiration, the inspired air encounters a sudden resistance at the nasal valve area due to which the velocity of air goes down, giving air enough time to come in contact with the mucosal surface of the nasal cavity. This gives time for the air to be regulated to body temperature as well as humidification of air occurs.

During expiration when air is expired due to narrowing of nasal valve area at the level of inferior turbinate, there is resistance and reverse currents or eddy currents are formed.
These eddy currents are important as they go to ventilate the sinuses.

Sinus ventilation is by eddy currents.

Active space

Leave Feedback

∴ Ventilation of sinuses is during expiration and when an individual develops sinusitis and is advised steam inhalation, it is imperative that both inhalation and exhalation is done through the nose to facilitate the sinus ventilation.

As nasal valve area is the narrowest part, if there is even a mild deformity of the septum in this area it will lead to lot of nasal obstruction in the patient. If a patient comes with nasal obstruction and anterior rhinoscopy is done, there maybe hardly any septal deviation, but it causes disproportionate level of symptoms.

Test for nasal valve patency :
Ask the patient to pull the cheek upward and laterally thus creating space in the nasal valve area. This will relieve the nasal obstruction, if the symptoms are due to further narrowing of nasal valve. This test is known as Cottle's test.

Cottle's test

As the external nose is a very prominent part of the face, injuries of the external nose are also very common. Be it by fall on the face, lateral hit on the face etc. The most common part to be injured is external nose. This is also why deformities of the nose are seen commonly.

Deformities of external nose

00:38:08

60c6b3eeaa8ded0e4e7e5ea7

- Crooked nose is when the dorsum is deviated/ deformed. It can be in 'C' or 'S' shape, but the tip is in midline.
- Deviated nose is when both dorsum and tip of the nose is deviated to one side.
- Hump nose.

Active space

Leave Feedba

'S' shaped crooked nose



'C' shaped crooked nose



kumarankitindia1@gmail.com

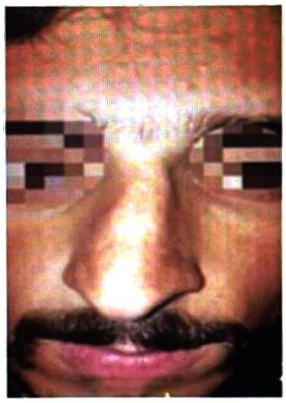

Deviated nose

Hump nose

Management :

All external deformities are managed by Rhinoplasty/plastic repair of the nose.

If there is septal deformity, septoplasty also needs to be done.

∴ Rhinoplasty ± Septoplasty.

Saddle nose :

It is usually not caused by trauma, but due to destruction of septum by any of the granulomatous conditions like TB, syphilis, Lupus, Leprosy or Wegener's Granulomatosis polyangiitis.Thus, the patient has to be investigated for granulomatous condition.



Saddle nose

Active space

CLINICAL ANATOMY OF LATERAL WALL OF NOSE

Interior of the nose anatomy

00:00:54

The interior of the nose is divided by the septum into 2 nostrils.

Each of the nostril has a lateral wall, a septum and a roof and a floor.

The lowermost part of the nostril is lined by the same external skin that is stratified squamous keratinising epithelium.

60c6b3eeaa8ded0e4e7e5ea7

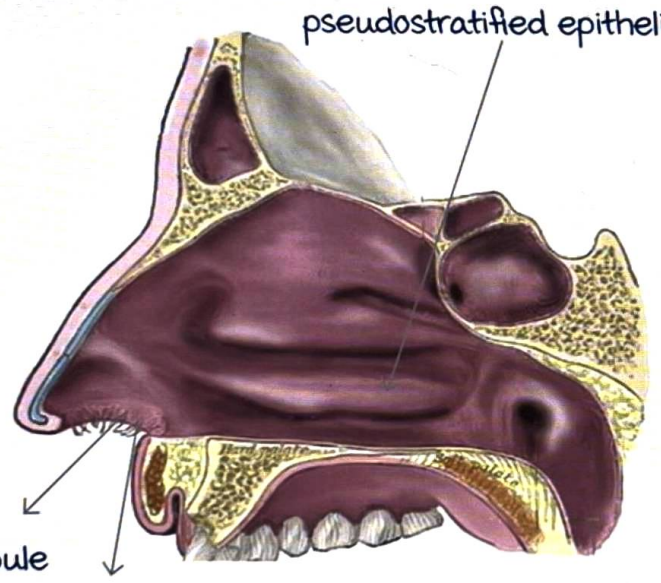

The whole of the anteroinferior part of the nostril is lined by the same epithelium as outside skin that is stratified squamous keratinising epithelium containing hair follicles, sweat and sebaceous glands.

This part of the nose which is lined by stratified squamous epithelium is known as the vestibule of nose.

The main lining epithelium of the nose where there is secretion has cilia which means nose sinuses, airways, nasopharyngeal part is all lined by ciliated columnar pseudo stratified epithelium.

This is also known as respiratory epithelium.

Active space

Leave Feedbac

Another important epithelium is the olfactory epithelium which is present only in the upper 1/3rd of the nasal cavity that is , upper 1/3rd of the septum, upper 1/3rd of the later wall and upper 1/3rd of the nose.

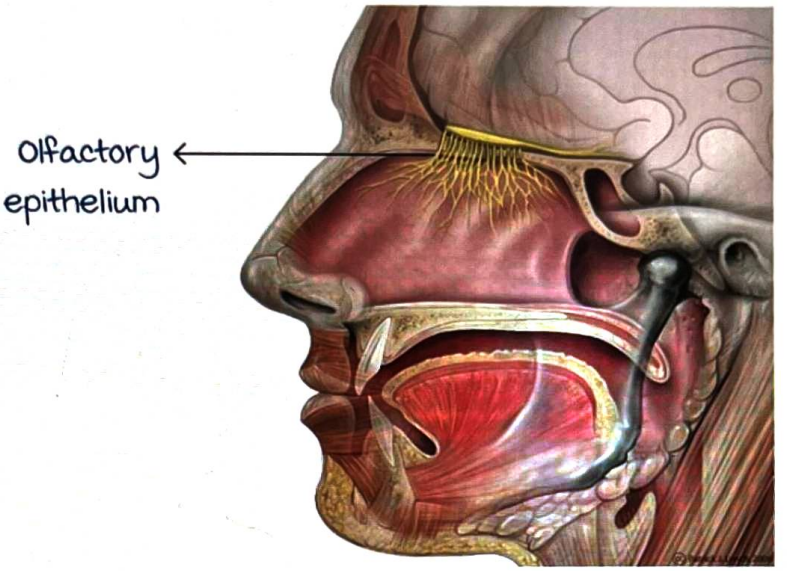

While breathing normally, the air that enters the main airway passes through the middle 1/3rd of nose. Only 10–15% of this reaches the olfactory epithelium.

A furuncle of the nose will be localised only to the vestibule.

A furuncle of the nose is nasal vestibulitis but a vestibulitis of the ear is labyrinthitis.

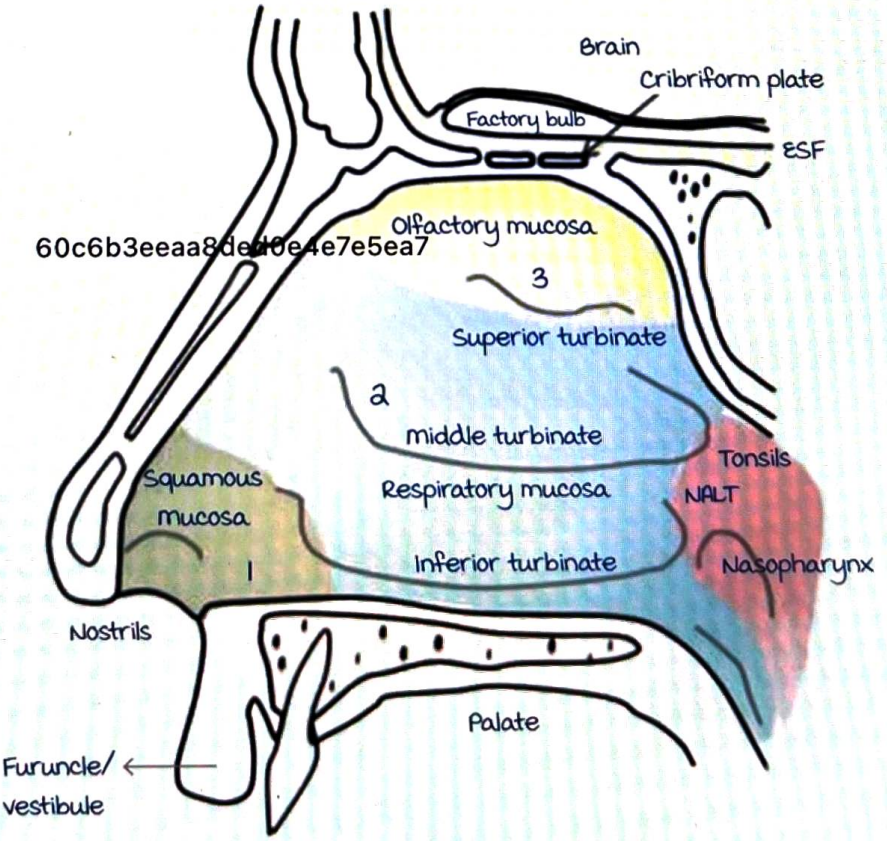

60c6b3eeaa8de0e4e7e5ea7

Active space

Leave Feedbac

1. Stratified squamous epithelium
2. Ciliated columnar pseudostratified epithelium
3. Olfactory epithelium

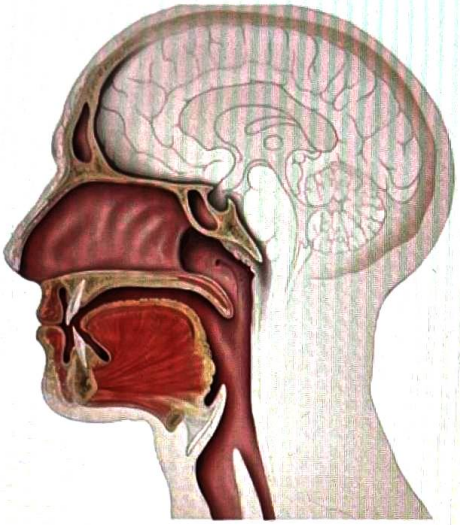

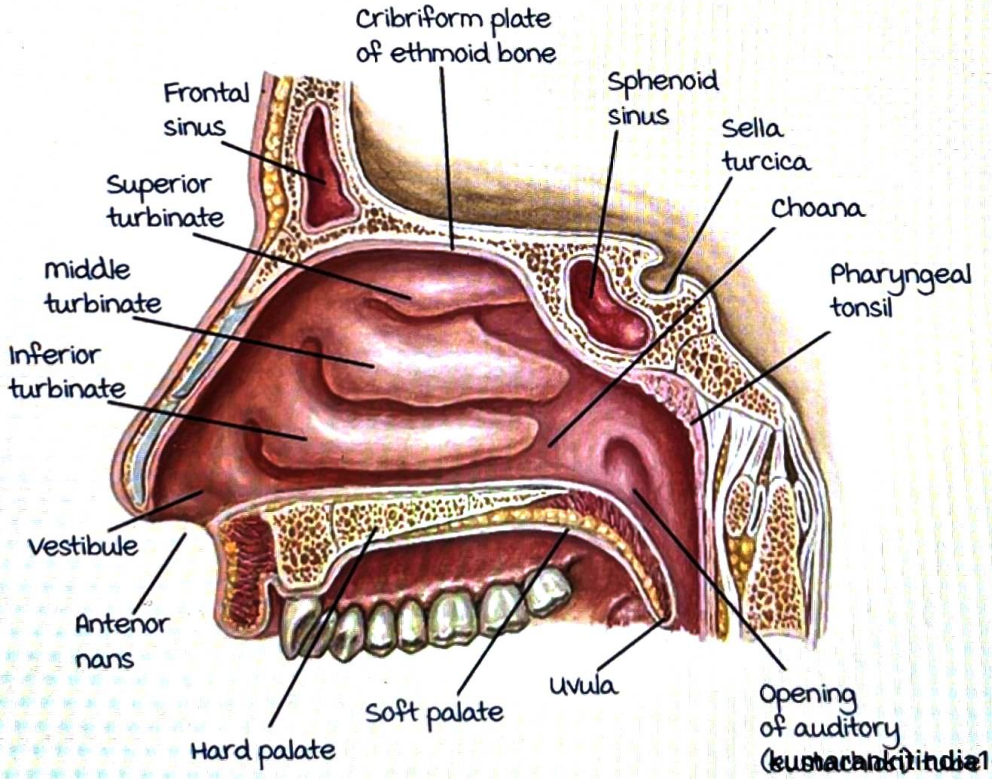

kumarankitindia1@gmail.com

1. Inferior turbinate.
2. middle turbinate
3. Superior turbinate

Active space

Leave Feedbac

Lateral wall of nose

00:08:47

In the centre the septum is located.

Once the septum is removed lateral wall can be visualised.

In the lateral wall there are 3 bony projections called the turbinates.

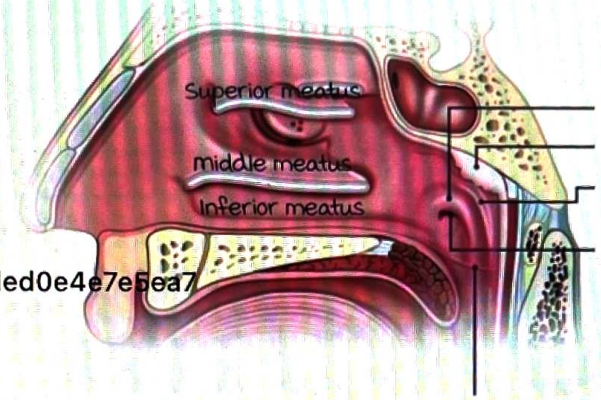

60c6b3eeaa8ded0e4e7e5ea7

Most inferiorly inferior turbinate

The one present in the middle is called as middle turbinate

Present most superiorly : Superior turbinate.

Sometimes a 4th turbinate called supreme turbinate is also found (it is not a common finding).

Inferior turbinate :

It is the largest.

Occupies the anterior to posterior part of the lateral wall.

Middle turbinate :

Lies posteriorly.

It occupies the posterior half of the lateral wall.

The superior turbinate which is also present posteriorly occupies the posterior 1/3rd of the lateral wall.

In area between the lateral wall and the turbinate is called the meatus.

Between lateral wall and inferior turbinate : Inferior meatus (the largest meatus)

Between lateral wall and middle turbinate :

Middle meatus (the most congested).

It is very important has it has the maximum number of sinuses.

Active space

Leave Feedbac

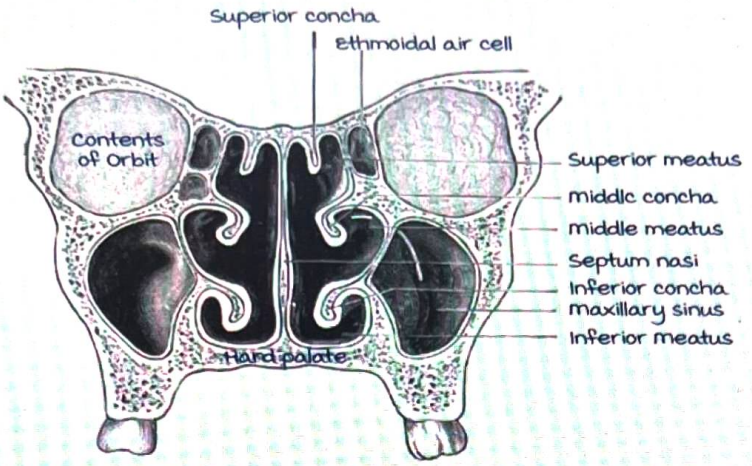

Between lateral wall and superior turbinate :
Superior meatus.
In other words the meatus lies lateral to their respective turbinates.

The turbinates end at the of the lateral wall of nose.
Although the anterior borders of the turbinates are at different levels the posterior borders are at the same for all the turbinates.
The posterior limit of the lateral wall is the end of posterior border of turbinates.
The lateral wall of the nose extends to form the lateral wall of nasopharynx.
The turbinates of the nose is also called the concha of the nose.

Conca Bullosa and Hypertrophy of the turbinates. 00:15:50

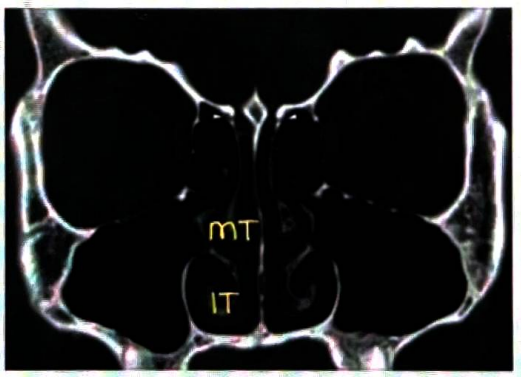

No air inside the turbinate

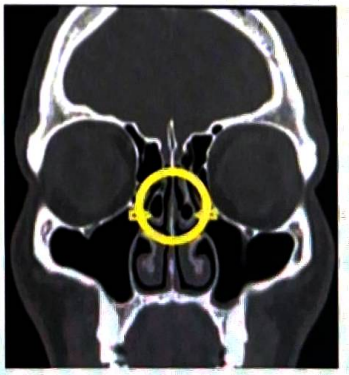

Air present inside the turbinate.
(Concha bullosa)

Active space

Leave Feedba

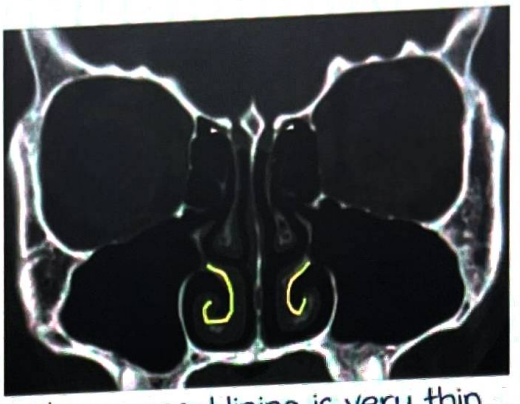

The mucosal lining is very thin

The mucosal lining is very thin

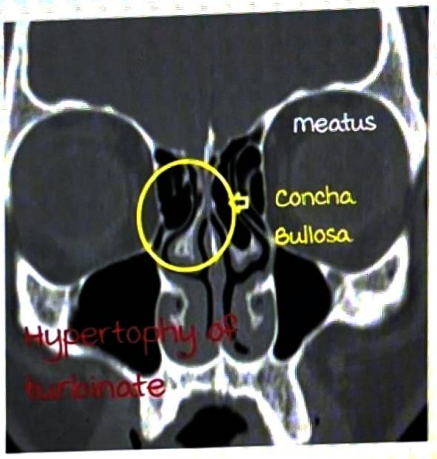

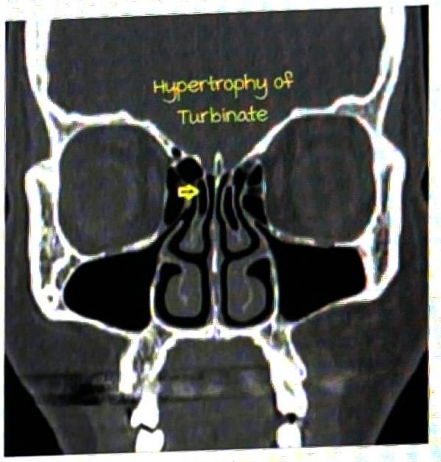

Concha bullosa is the pneumatisation of the turbinates

The mucosal lining outside the turbinate is thin but when it becomes thick it is called hypertrophic turbinate.

This is an external hypertrophy of the sub-mucosal tissue.

The concha bullosa is most commonly seen in the middle turbinate.

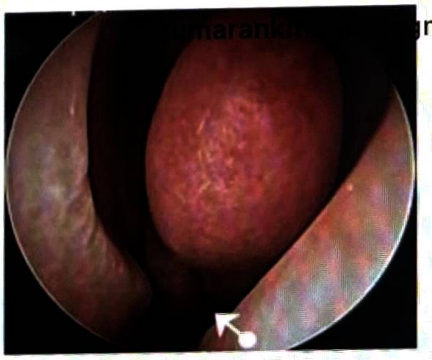

Concha Bullosa

Hypertrophy is seen in the inferior turbinate.

The meatus contain the opening of the sinuses.

When the concha bullosa presses against the meatus it results in the blockage of the sinus openings.

Active space

Leave Feedback

This can lead to recurrent sinusitis.
Whereas, the hypertrophic turbinate leads to nasal obstruction.
Appearance of conceal bullosa is polyp like.
When the hypertrophy is irregular the turbinate looks bumpy.
As a result of which the hypertrophic turbinate gives a mulberry appearance (raw mulberry).

Management 00:22:43

- Conca bullosa : Cut open the turbinate from the middle and the lateral part of the concha which is pressing on the meatus will be removed : Partial turbinectomy.
- Hypertrophic turbinate : Partial turbinectomy.

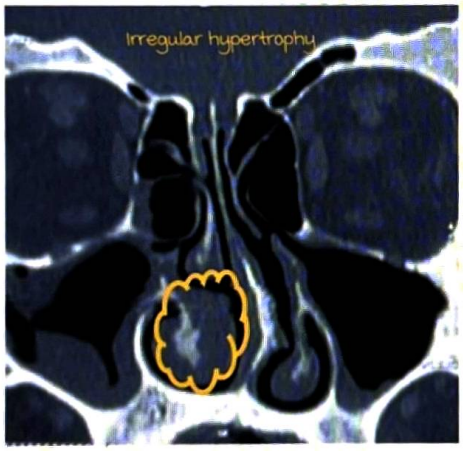

The function of the turbinates is that they increase the surface area of the nose making air exposed to a lot of mucosa leading to immediate humidification and temperature regulation (to body temperature).
60c6b3eeaa8ded0e4e7e5ea7
Hence partial turbinectomy is done (all turbinates are not removed) or turbinate reduction (reduce hypertrophic tissue).

The superior and the middle turbinate are parts of the ethmoid bone whereas the inferior turbinate is an independent bone.

Active space

Leave Feedbac

Ethmoid bone

00:26:03

Single bone on both the sides.

The lateral part is formed by a thin papery bone lamina papyracea. It forms the medial wall of the orbit.

60c6b3eeaa8ded0e4e7e5ea7

It separates the nasal cavity from the orbit.

Since the ethmoid bone is separated from the orbit by a thin bone, in ethmoid sinusitis the pain increases with the movement of eye. Therefore orbital complications are seen the most in ethmoid sinusitis.

Crista Galli is an intracranial projection.

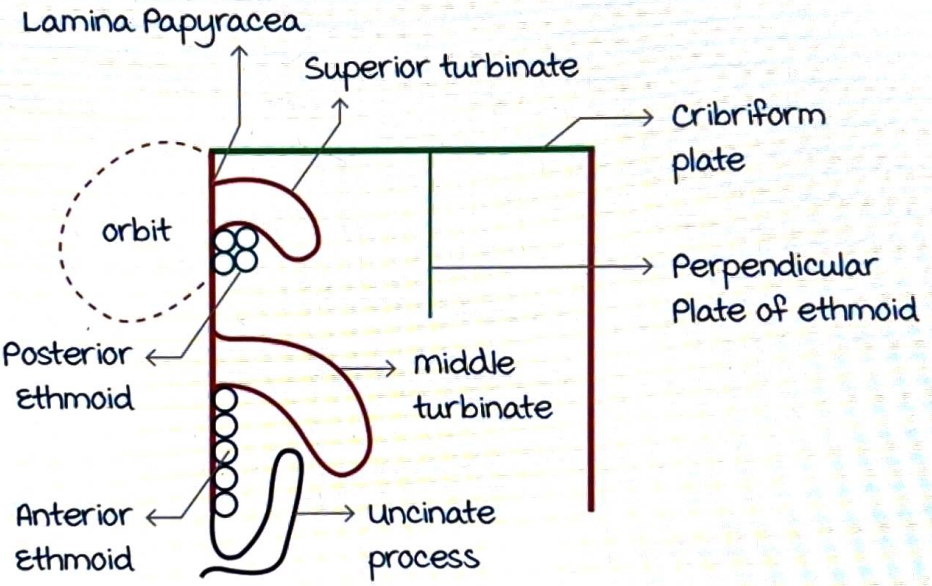

From below, a bone comes in the reverse direction and it is called as the uncinate process.

Superiorly, the part of the ethmoid forms most of the roof of the nose called the cribriform plate (utensil shaped).

It has multiple perforations.

Any surgery on the nose must be done cautiously to avoid damage.

Superior damage (cranial cavity) it can lead to CSF leak.

Whereas laterally, it can lead to the injury of the orbit.

Cribriform plate acts as a passage for the nerves from the nose to the brain.

From the cribriform plate a bone comes down perpendicularly which forms a part of the septum called the perpendicular plate of ethmoid.

Active space

Leave Feedbac

The ethmoid bone has great anatomical significance as it is related to all the parts of the nose.

The ethmoid bone articulates with the inferior turbinate.

The ethmoid bone has multiple air sinuses called ethmoid air sinuses. They are lateral outpouchings from the nose.

The mucosa of the nose out pouches laterally into the accent bone.

The lateral outpouching that goes into the maxillary bone is called the maxillary sinus.

The one that goes into the ethmoid bone is called ethmoid sinus.

The one that enters the frontal bone is called frontal sinus.

The one that enters the sphenoid bone is called the sphenoid sinuses.

The function of the sinuses is to lighten the skull bone (These sinuses enlarge and gets filled with air) and acts as resonating chambers for voice (nasal resonance).

kumarankittindia1@gmail.com

The sinuses are lined by the same ciliated columnar pseudostratified epithelium.

The air cells that develop in the ethmoid bone are known as ethmoid air sinuses.

The ethmoid air sinus present in relation to the middle and superior turbinate are known as anterior ethmoid and posterior ethmoid respectively (as superior turbinate is positioned posteriorly).

Hence the air cells, sinuses are also located posteriorly.

Patients with ethmoidal sinusitis tend to develop orbital hematoma and abscess.

Orbital hematoma is an emergency condition as the hematoma has no room to expand hence can compress the optic nerve leading to blindness. The drainage is done through lamina papyracea via the nose. Caution to be taken superiorly (CSF leak) and laterally (orbital injury).

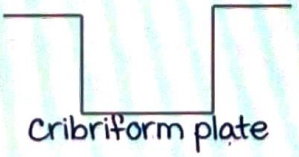

Active space

Leave Feedbac

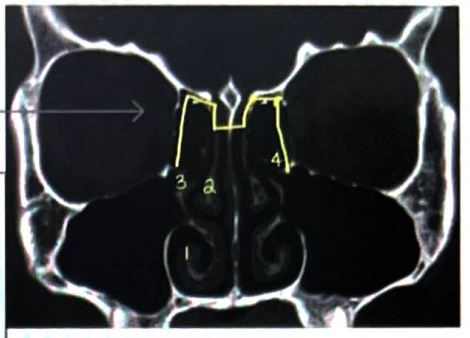

1. Inferior turbinate.
2. Middle turbinate
3. Middle meatal area
4. Anterior ethmoid

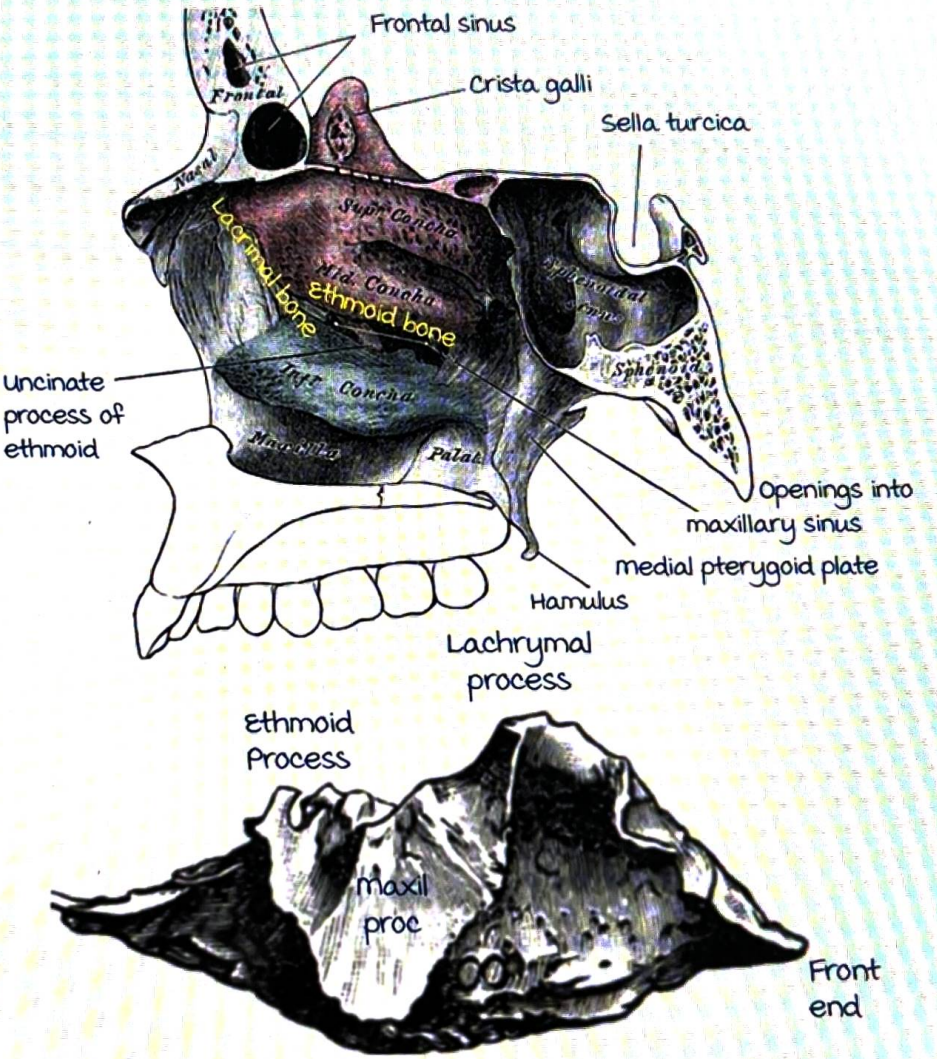

Inferior turbinate

kumarankitindia1@gmail.com 00:39:52

Independent separate bone.

With the help of multiple processes it is attached very tightly to the lateral wall.

The inferior turbinate is attached :

- Superiorly to the ethmoid bone and lacrimal bone.

Active space

Leave Feedbac

- Laterally to the maxillary bone.
- Posteriorly to the palatine bone.

The palatine bone is a L shaped bone which has 2 parts the horizontal and perpendicular part. The horizontal part forms the part of the palate whereas the perpendicular part attached to the ethmoid bone posteriorly.
The inferior turbinate articulates with the help of multiple processes; like maxillary process attaches to the maxilla.
It attaches to the ethmoid bone, lacrimal bone.
Posteriorly it attaches to the palatine bone.

Meatus and nasolacrimal duct 00:43:13

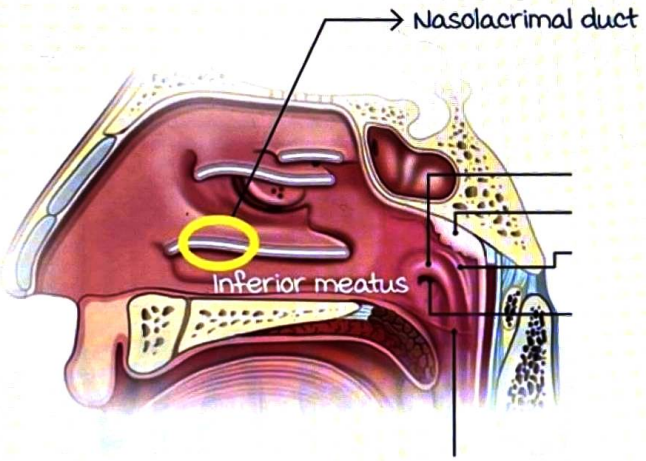

Lateral to turbinates.
The largest meatus is inferior meatus.
middle meatus is the most congested meatus.
The inferior meatus is the opening for the nasolacrimal connecting the nose to the lacrimal sac.
The significance of the nasolacrimal duct is that it drains the secretions from the eye to nose.
When the duct gets blocked the secretions collect and get infected. This is called dacrocyctistis.

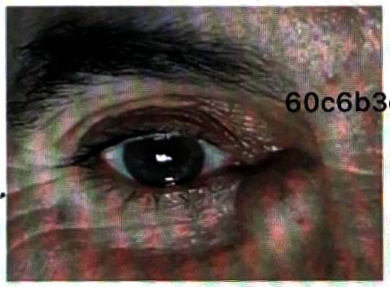

management of dacrocystitis :
The patency of the duct must be maintained.
A syringe is passed through the inferior puncta and force

Active space

Leave Feedbac

saline through the nasolacrimal duct thus opening the duct.

Despite this if the duct does not open, then the lacrimal sac is opened directly into the nostril.

Earlier, the external approach was used where an incision is given on the skin, the sac used to be exposed and the lacrimal sac used to be connected to the nostril inside. This was known as external dacrocystorhinostomy. The site where the lacrimal sac opens inside the nose is just infront of the middle turbinate.

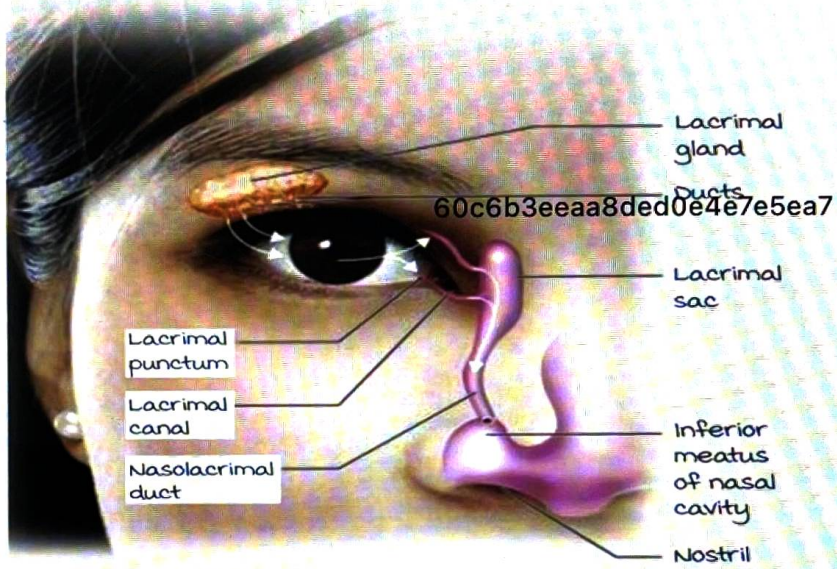

60c6b3eeaa8ded0e4e7e5ea7

Now it is done as an endoscopic procedure and not done externally.

Now the opening is made anteriorly to the middle turbinate, directly into the lacrimal sac.

This is known as endoscopic dacrocystorhinostomy (DCR).

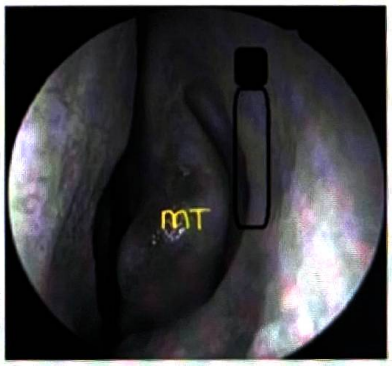

In some instances the nasolacrimal duct is already narrow if they develop rhinitis the nasolacrimal duct gets blocked and the child develops watery eyes.

Even if the rhinitis gets resolved the lacrimal duct continue

Active space

to remain blocked and the child has watery eyes.

In such cases, the parents are advised to massage in the direction of the nasolacrimal duct. This is called the Crigler's massage.

The direction of the nasolacrimal duct is downwards, laterally and backwards. (DOUBLE -DBL).

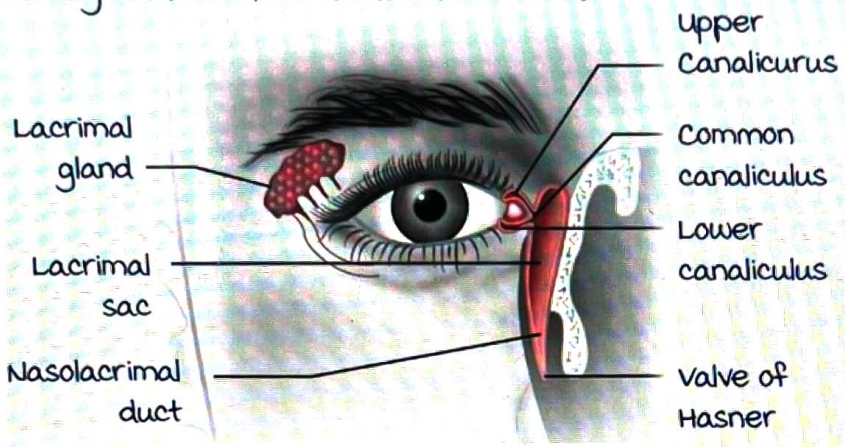

kumarankitindia1@gmail.com

Turbinates	Meatus	Openings.
Inferior turbinate Largest/whole	Inferior meatus : Largest	The nasolacrimal duct. Direction : downwards backwards, laterally. Opening : It opens just below the highest point or at the junction of anterior 1/3rd and posterior 2/3rd. Valve : Hasner's valve
Middle turbinate	Middle meatus : Most congested	Maxillary sinus Anterior ethmoid sinus Frontal sinus All the three sinus along with the structures is called the osetomeatal complex.
Superior turbinate Posterior 1/3rd Spenoethmoidal recess	Superior meatus	Posterior ethmoid The sphenoid sinus opens in the sphenoethmoidal recess.

The nasal endoscopy used to investigate the diseases is called diagnostic nasal endoscopy (DNE).

It is done either with a rigid or flexible endoscope.

Active space

Leave Feedba

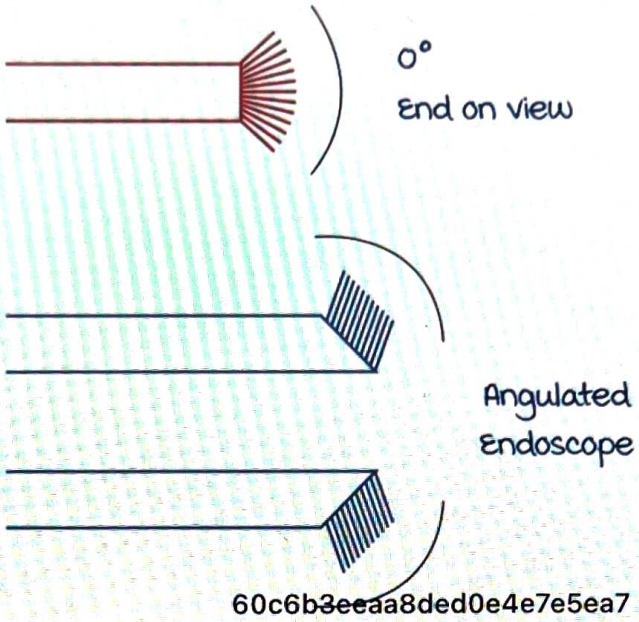

60c6b3eeaa8ded0e4e7e5ea7

Label : Red marking 30 degrees and Green marking is 0 degrees.

They come in different angulations and is marked with different colours.

The colour codes are for easy identification.

There are 4 types: (GRBY)

- Green : 0 degree
- Red : 30 degree.
- Black : 45 degrees
- Yellow : 70 degrees.



Rigid endoscope

When the endoscopy is put inside the nostril if it is 0 degrees, the angle is straight and we get an end on view. (Visualisation of what is in front). In this case the sinuses cannot be viewed as they are situated laterally.

If the endoscope has an angle a wider range of structures can be visualised.

An angulated endoscope gives a better view of the sinuses.

Active space

Leave Feedback

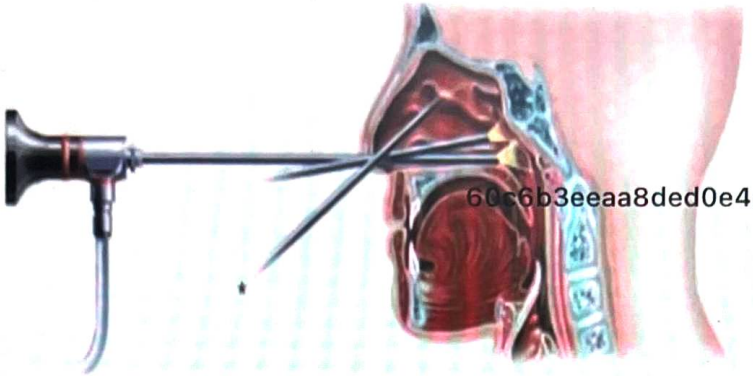

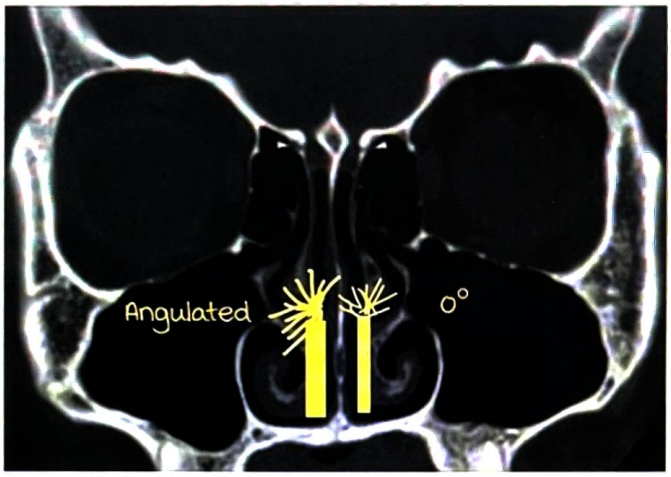

The rigid endoscopy must be done when the patient is lying down.

First, the nose should be anesthetize the nose with a local anaesthetic nasal spray or nasal packs which are soaked in an anaesthetic. After that endoscopy is done

A flexible endoscope can be used when the patient is sitting.

Lateral wall will have turbinates (separate outpouchings) / septum/ inferior turbinate, middle

Active space

Leave Feedba

Endoscopic view of a normal nose

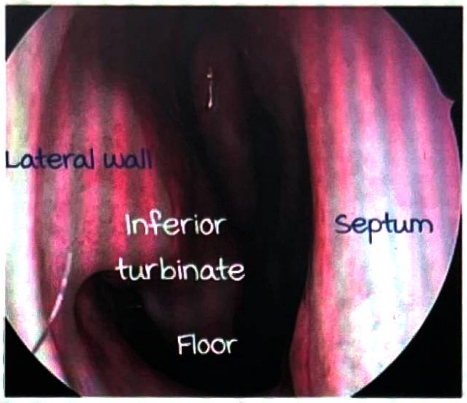

kumarankitindia1@gmail.com



Flexible fiberoptic endoscope



The endoscope is passed through the floor of the nose and the inferior turbinate is extending throughout (largest).
It is then passed in the inferior meatus
Patency of the duct is determined if the secretions are coming out through the nasolacrimal duct. It opens at the junction of the inferior 1/3rd and posterior 2/3rd of the inferior turbinate.

Active space

Leave Feedback

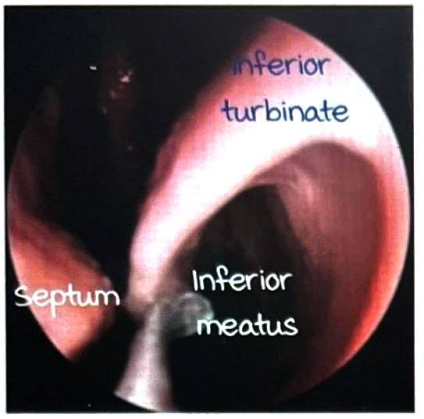

Middle meatus

01:01:04

most congested meatus because large number of openings of the sinuses (the anterior group of sinuses) are present here.

Anterior group includes the frontal, anterior ethmoid, and maxillary sinus.

From the lateral wall the middle turbinate arises. Between these two structures lie the middle meatus.

In the middle meatal area, superiorly a bulge is seen that is produced by the most prominent anterior ethmoidal cell. This is called as bulges of bulla of the ethmoid or bulla ethmoidalis.

Inferiorly lies a sickle shaped bone, called the uncinate process.

The gap between the bulla superiorly and the uncinate inferiorly is the semi lunar opening called hiatus semilunaris.

60c6b3eeaa8ded0e4e7e5ea7

The area between the lateral wall and the uncinate is known as infundibulum. The maxillary sinus opens into the infundibulum.

The frontal sinus opens above the bulla.

The tract from the frontal sinus draining into the middle meatus is called as the frontonasal duct/frontal recess.

All the structures of the middle meatus including the openings is known as osteomeatal complex.

It is called a complex as one disorder affects all the structures.

Active space

Leave Feedbac

Osteomeatal complex

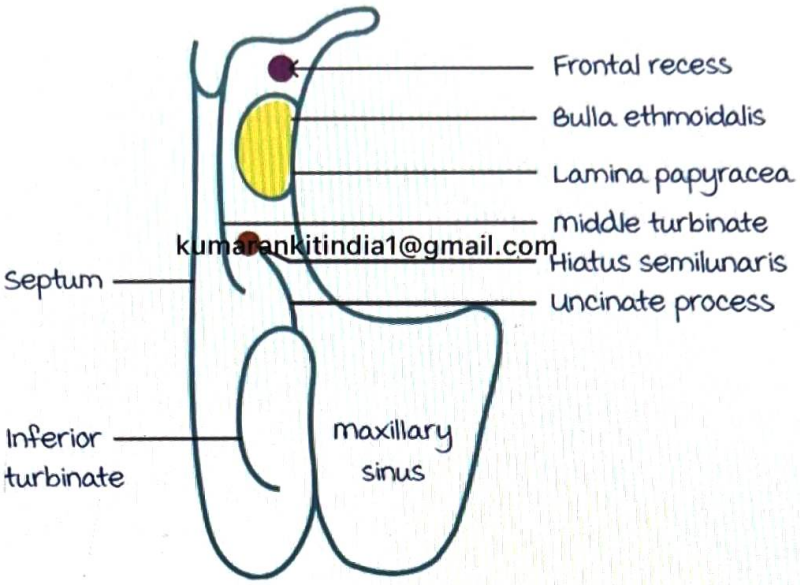

kumarankitindia1@gmail.com

In the lateral wall there are multiple openings which are mostly the sinuses.

Any infection of the nose can reach the sinus via the lateral wall leading to sinusitis.

These sinus are approached via the lateral wall.

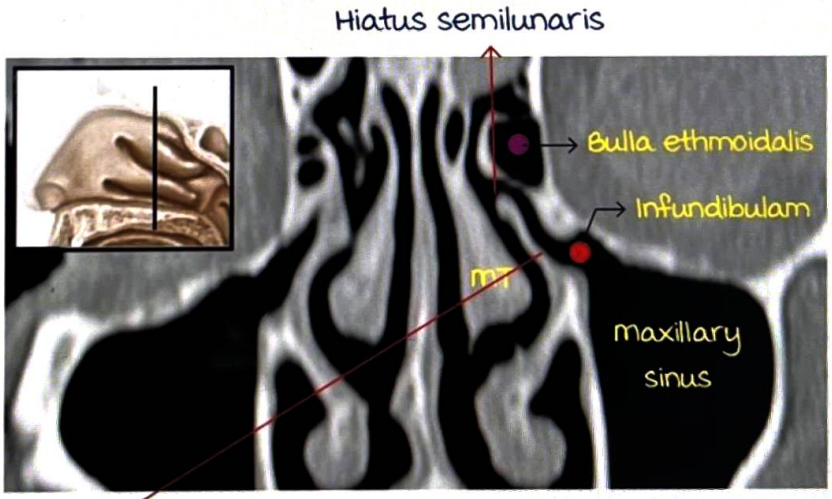

Osteomeatal complex CT

Uncinate process

FESS

01:09:51

FESS : Functional endoscopic sinus surgery.

The maxillary sinus is approached endoscopically via the lateral wall through the middle meatus.

The normal function of ventilation and drainage is restored with the help of FESS.

Active space

Leave Feedback

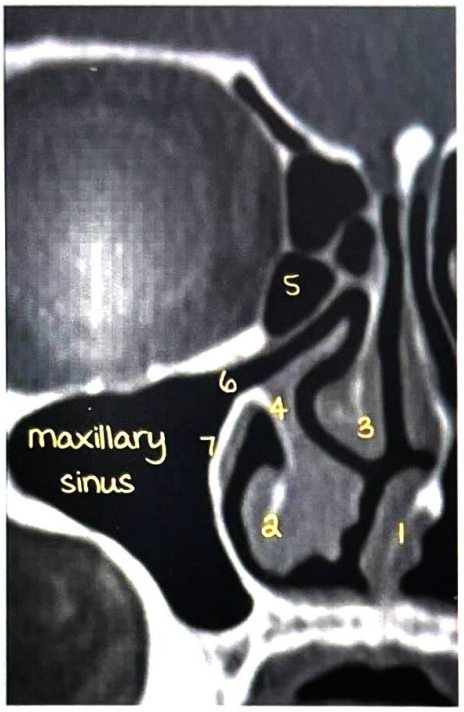

1. Septum
2. Hypertrophied inferior turbinate
3. Middle turbinate
4. Uncinate process
5. Bulla ethmoidalis
6. Hiatus semilunaris
7. Infundibulum.

A rigid endoscope is used as a flexible endoscope will occupy both the hands.

In FESS the first step is the removal of the uncinate process (uncinectomy) to facilitate the ethmoidal approach. It is also the first step in infundibulotomy.

The boundaries of the infundibulum : It lies between the uncinate process and the lateral wall.

The maxillary sinus opens directly into the infundibulum.

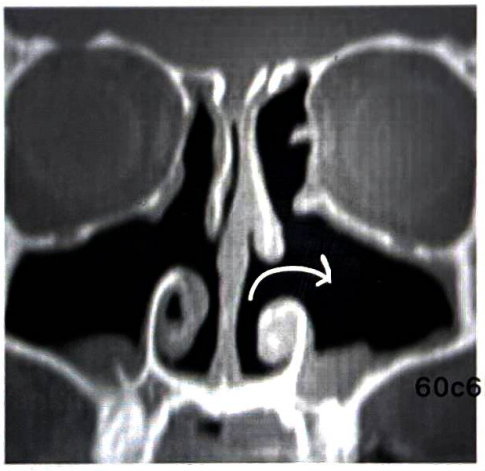

Post-uncinectomy
Uncinate process is absent

CT of a patient with maxillary sinusitis
Uncinate process is present.

60c6b3eeaa8de

Active space

Leave Feedbac

Approach of FESS in maxillary sinusitis

01:16:12

First step : Removal of the uncinate process.

Endoscopic appearance :

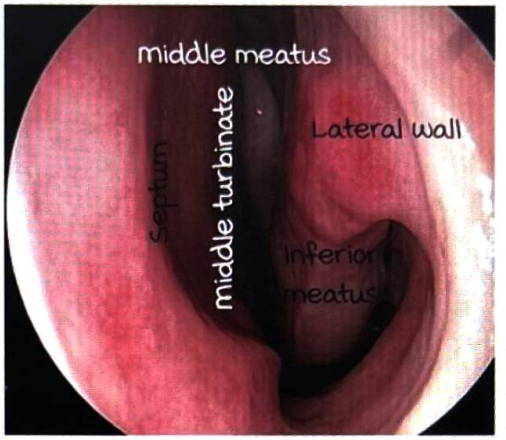

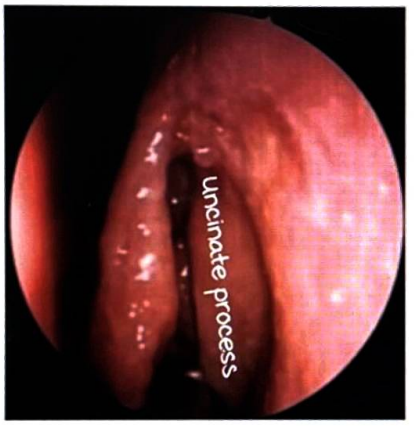

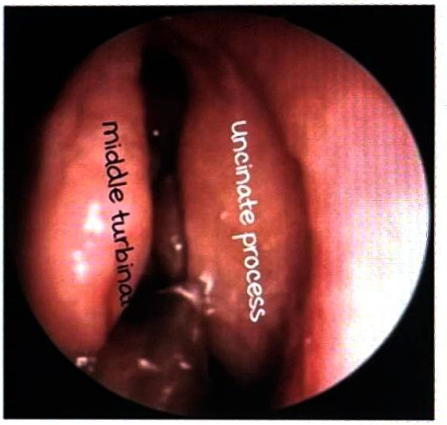

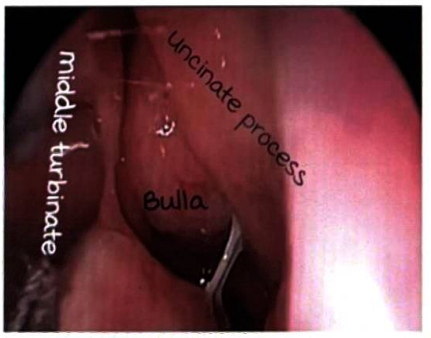

kumarankitindia1@gmail.com

The probe has been passed into the hiatus semilunaris to reach the infundibulum

Active space

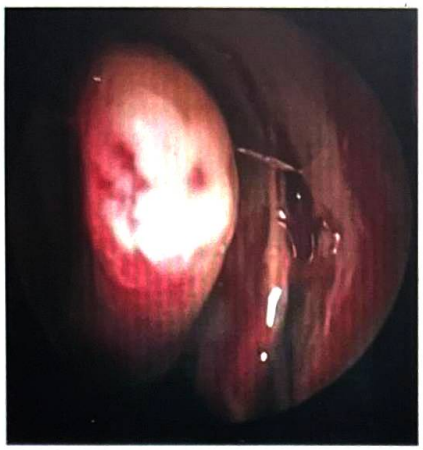

Once the uncinate process is removed we enter the infundibulum

For easier visualisation of the maxillary sinus uncinectomy is done

Site of incision :

Once the uncinate process is removed we enter the infundibulum

Anatomy of the middle meatus

c9c6b3eeaa8ded0e4e7e5ea7

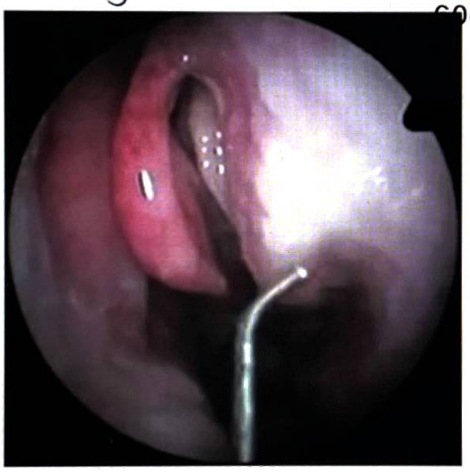

The endoscopic anatomy of the middle meatus :

The following structures in the left nostril can be appreciated.

- middle turbinate
- middle meatal area

The probe is touching the uncinate process.

Active space

Leave Feedba

Via the hiatus semilunaris infundibulum is entered.

Hiatus semilunaris

Uncinectomy is done with the help of a back biting forceps
The uncinate process removed until the maxillary sinus ostia can be visualised.
Widening of the ostia is done to help with the ventilation of the sinus.

Back biting forceps

maxillary sinus ostia

Widening of the maxillary sinus ostia

60c6b3eeaa8ded0e4e7e5ea7

Using an angled endoscope, the inside of the maxillary sinus is visualised clearly.
The maxillary sinus is drained and flushed.
Following FESS the patient's maxillary sinus and middle meatal area is now properly ventilating and draining.

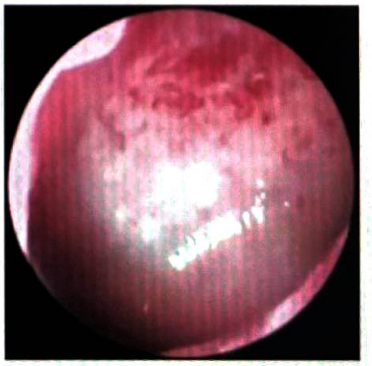

maxillary sinus

Active space

Leave Feedba

When the endoscopy is moved upwards anteriorly the frontal sinus opening and the frontonasal duct/ frontal recess can be visualised.

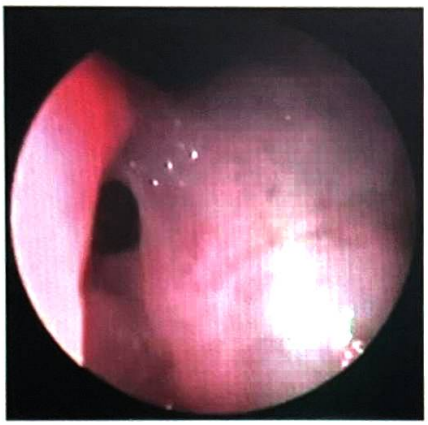

Frontal sinus opening

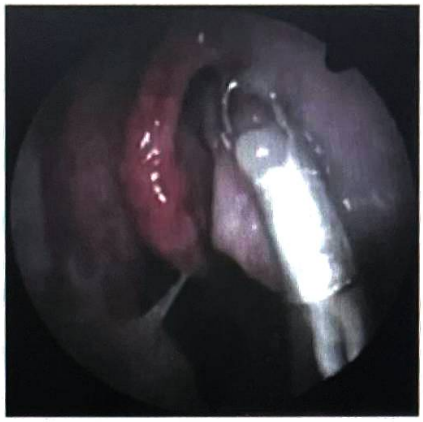

Frontal recess

Removing disease of from the anterior ethmoid using the Blackesley's forceps, the upper part of the uncinate process which was left behind is being removed.

60c6b3eeaa8ded0e4e7e5ea7

The bulla ethmoidalis is opened.

The anterior ethmoidal air cells is opened and disease from the anterior ethmoid is removed.

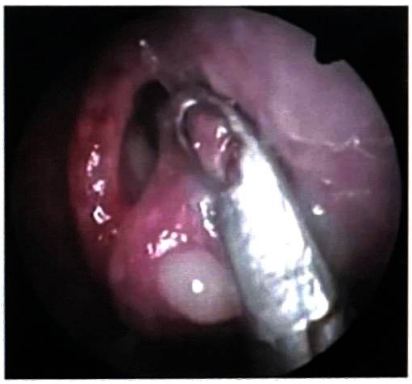

Uncinate process which was left behind is being removed.

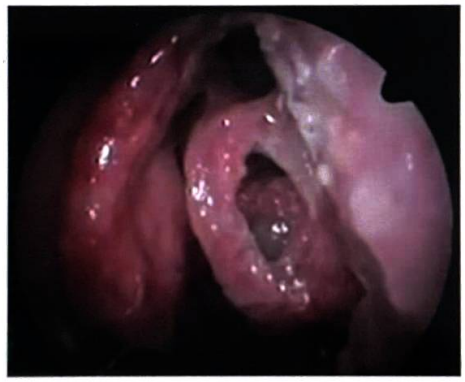

The bulla ethmoidalis being opened.

The frontal sinus opening is present above to remove disease from there.

Frontal sinus opening

Active space

Leave Feedbac

Raw surfaces are created following surgery resulting in synechiae.

Following FESS a pack must be put in the middle meatal area for 4–5 days to prevent the formation of synechiae. The drug that is socked in the pack to help with the prevention of synechiae is mitomycin C (also used in choanal atresia).

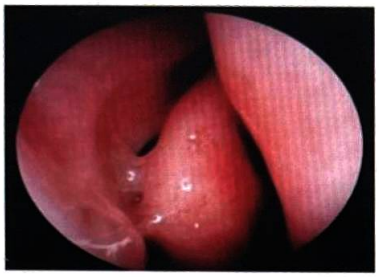

Synechiae

Drug pack to prevent synechiae

Forceps used in FESS

01:26:17

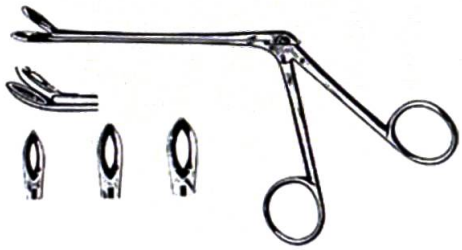

Blackesley's forceps

Only tip opens
It has different angulations.

Backbiting forceps :
Opens behind so that in the lateral wall while performing FESS ostia is engaged & widening is facilitated easily.

Backbiting forceps

Active space
kumarankitindia1@gmail.com

Leave Feedback

Superior meatus 01:28:53

Lies lateral to the superior turbinate.
The posterior ethmoid opens in the superior meatus.
Opening of the sphenoid sinus is in an area above the superior meatus.
This area is a recess between the sphenoid superiorly and ethmoid inferiorly hence is called the spenoethmoidal recess.
The sphenoid sinus opens in the spheno-ethmoidal recess.

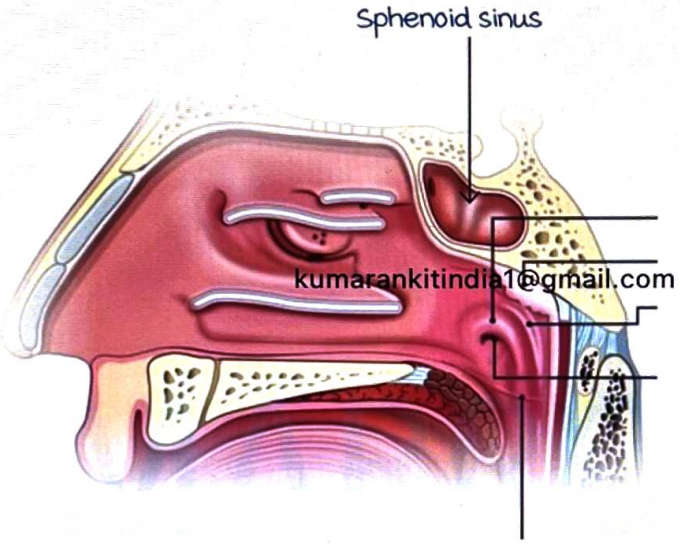

kumarankitindia1@gmail.com

The least common sinusitis is the sphenoid sinusitis as this sinus opens separately in the roof of the nose and not affected by other conditions of the nose.

Complete endoscopy of meatuses 01:30:54

It is in 3 passes .

Endoscopy of the left nostril.
Lateral wall & septum (sharp deviation of the septum at the junction of the body cartilage/septal spur).

Active space

Leave Feedba

The first pass is when the endoscope is passed inferiorly in between the inferior turbinate and the septum and go up to the nasopharynx to visualise the nasopharynx, then come back and view the inferior meatus.

Structures of nasopharynx

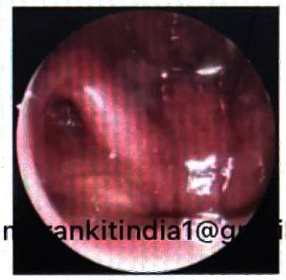

Right Eustachian tube

Left Eustachian tube

kun ankitindia1@g il.com

In the inferior meatus the nasolacrimal duct opening can be seen.

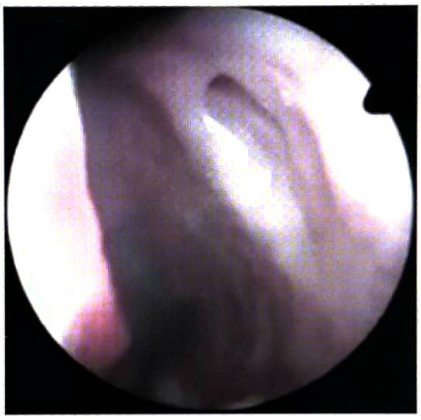

Nasolacrimal duct opening

The second pass :
Pass the endoscope inferiorly through the floor of the nose between the inferior turbinate and the septum till the choana (posterior nasal aperture) is reached.

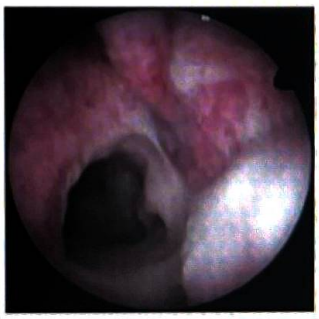

Choana

Once the tip of the endoscope is rotated superiorly, the sphenoid sinus opening, the recess area and superior turbinate can be seen.

Active space

Leave Feedba

Sphenoid sinus opening

Superior turbinate

Third pass : Passing endoscope through middle meatal area.
Here disease is found most commonly.
The middle turbinate can be seen.
The probe is touching the uncinate process.
Once the uncinate process is excised the infundibulum is accessed to view the maxillary sinus ostia.

60c6b3eeaa8ded0e4e7e5ea7

middle turbinate with the probe touching the uncinate process

Bulla ethmoidalis

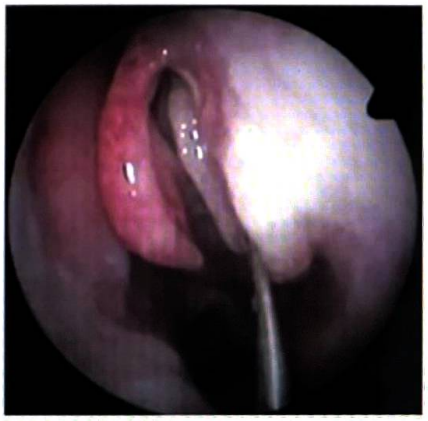

Hiatus semilunaris

Probe enteres infundibulum through hiatus semilunaris.

Active space

Leave Feedba

CLINICAL ANATOMY AND DISEASES OF SEPTUM

Parts of septum

00:01:10

- The septum is mainly bony.
- It is divided into three parts.
- The lower most part of the septum is formed by the medial crura of the lower alar cartilage (U-shaped cartilage).
- It has the lateral crura that forms part of the external nose.

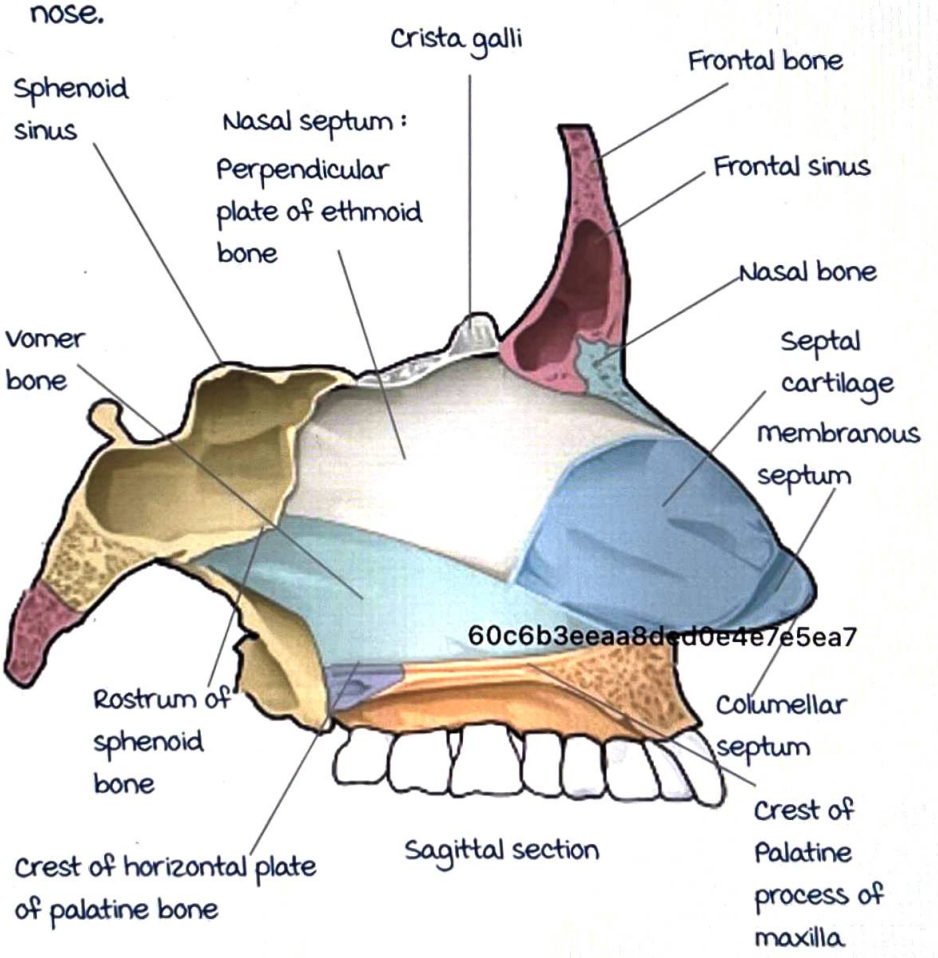

60c6b3eeaa8ded0e4e7e5ea7

- The medial crura of both the sides fuses to form the lower most part of the septum called the columellar septum.
- Just above the columellar area of the septum is an area where the skin of both the sides meet with the absence of cartilage called membranous septum.

Active space

Leave Feedba

- The remaining part of the septum above is called the septum proper (excluding the anteroinferior part) which is bony.
- The anteroinferior part of the septum proper which is cartilaginous is called the septal cartilage or the quadrangular cartilage (name given due to its shape).
- It gives support to the lower 2/3rd part of the external nose that is supported on the septum.

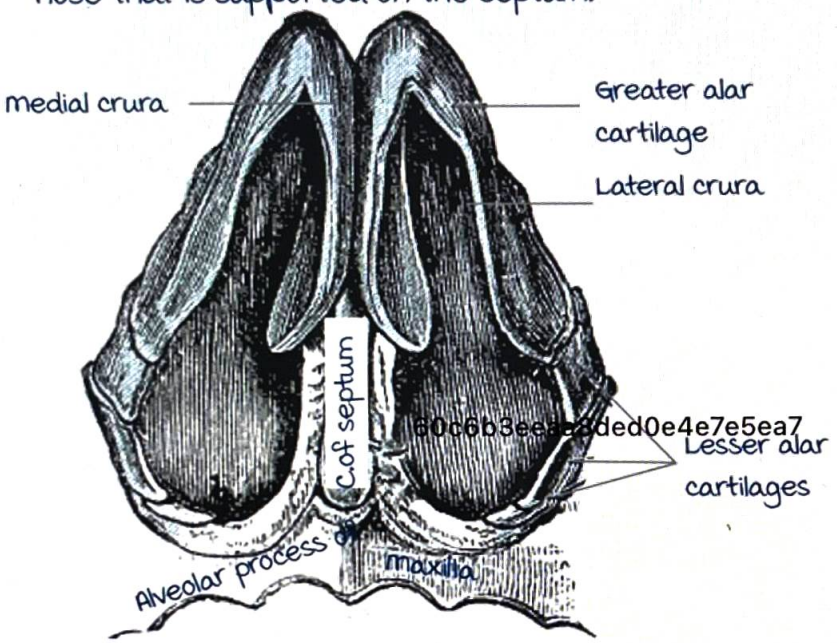

Extra caution should be taken when operating on the septal cartilage as excess removal will lead to the loss of the dorsum support. As a result, lowering of the dorsum/saddling of the dorsum occurs.

The part of the ethmoid coming down form the cribriform plate perpendicularly is called the perpendicular plate of ethmoid.

The vomer lies posterior to this.

Therefore the 3 main components of the septum proper include;

- Perpendicular plate of ethmoid.
- Vomer.
- The quadrangular cartilage.

Other parts include :

1. Nasal spine/process of frontal bone.
2. The rostrum of sphenoid : Small projection from the sphenoid.

Active space

Leave Feedba

3. Crest of palatine bone.
4. Crest of maxilla.

The inferior wall of the nose is formed by the palatine bone.
The palatine bone can be divided into 2 parts posteriorly :
The horizontal and the vertical part.
The horizontal part of the palatine bone forms the posterior aspect of the palate.
The palatine process of maxilla forms anterior aspect of the palate.
The palatine plate and maxilla give rise to projection to the septum called the palatine crest and maxillary crest respectively.

60c6b3eeaa8ded0e4e7e5ea7

Deviated nasal septum/DNS

00:08:43

The most common cause of DNS is birth trauma :

- In intrauterine life, compression forces on the foetus can create pressure on the septum which can cause microfractures.
- During delivery while passing through the birth canal a difficult labour, prolonged labour or compression on the nose can all cause microfractures.
- These become areas of weakness which will lead to deviation of the septum.

Active space

Leave Feedbac

- Developmental errors such as inequal development between the base of skull and palate leads to the compression of the septum between them causing microfractures and deviation.

Percentage of newborn with DNS is between 1 – 80%.
Even though a majority of newborns have DNS, not all are symptomatic.

Symptoms of DNS :

1. Nasal obstruction : most common symptom.
2. Recurrent sinusitis :
   Septal compression of the turbinate's obstruction of meatuses and impaired sinus drainage.
3. Recurrent acute otitis media :
   In children the discharge from the nose can easily go posteriorly into the Eustachian tubes (shorter in children) and enter the ear.
4. Headache :
   - Can be due to recurrent sinusitis.

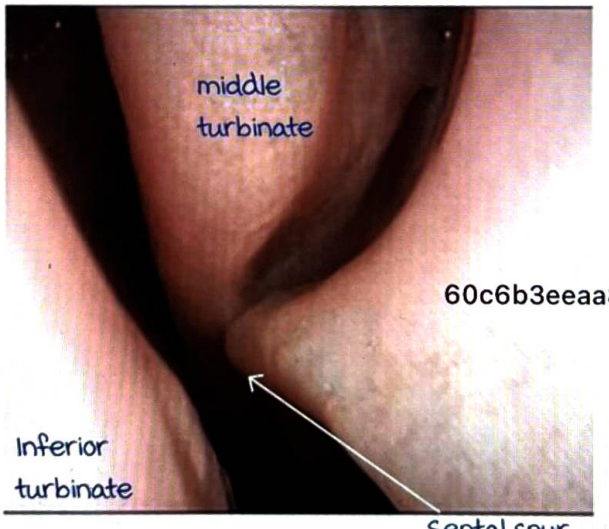

60c6b3eeaa8ded0e4e7e5ea7

   - Sluders neuralgia : A septal spur (a sharp deflection) usually occurs at the junction of bone and cartilage. When the spur compresses the lateral wall, it leads to the compression of the nerves in that area causing constant headache.
5. Hyposmia.

Active space

Leave Feedba

6. Repeated epistaxis :

Normally the air enters a nostril it reaches posterior aspect of the nose after passing through the middle region. Whereas in a patient with DNS the air directly hits the septum exposing it to the drying effects of the air causing crusting. Removal of the crust leaves raw areas prone to epistaxis.

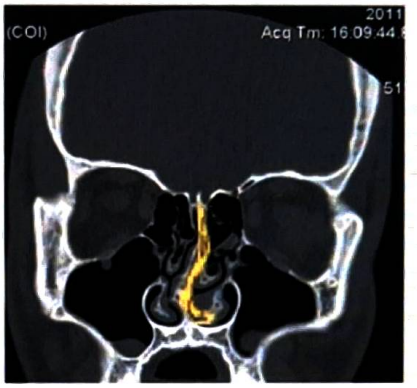

7. Hypertrophy of the turbinates (not atrophy) :

- Hypertrophy does not occur on the site of deviation instead it occurs on the opposite side (roomier side).
- The appearance of hypertrophic turbinate is uniform or mulberry like turbinate.
- Chronic change.
- The inferior turbinates get exposed first to the cold/ dry air entering the roomier side.
- Since the inferior turbinates plays the maximum role in temperature regulation and humidification it has extensive vascular supply and venous sinusoids.
- As a result of which the vessels remain constantly dilated for temperature regulation to occur, causing the hypertrophy of the turbinates with obstruction on the opposite side.
- This is called paradoxical nasal obstruction.
- The patient will also have hyposmia.

  Treatment : Correction of septum and reduction of the hypertrophic turbinates.

8. Cosmetic deformity : Dorsum and the tip is deviated to one side hence called deviated nose.

Treated by correcting the septum.

Active space

Leave Feedback

Cosmetic deformity

Examination of nose

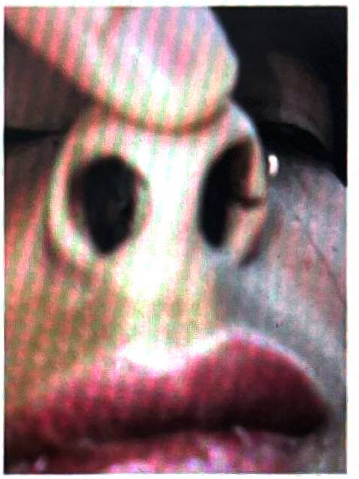

kumarankitindia1@gmail.com

Examination of the nose :

- Slight upward pull of the nose can reveal lower caudal deviation.
- Anterior rhinoscopy : Performed with Thudicum nasal speculum.
- Cold spatula test : Take a tongue depressor and ask the patient to breath out. When the patient breaths out, the misting in both the sides are compared.

Thudicum speculum

Cold spatula test

The drawback of this test is that both the nostrils do not function optimally and equally at all times. Always one nostril functions better than the other and this is called as nasal cycle. Nasal cycle varies from 2.5–4 hours.

In normal cases when the test is performed it can cause unequal misting. Hence to rule out DNS we need to look for a gross difference in the misting on both sides.

Active space

Leave Feedbac

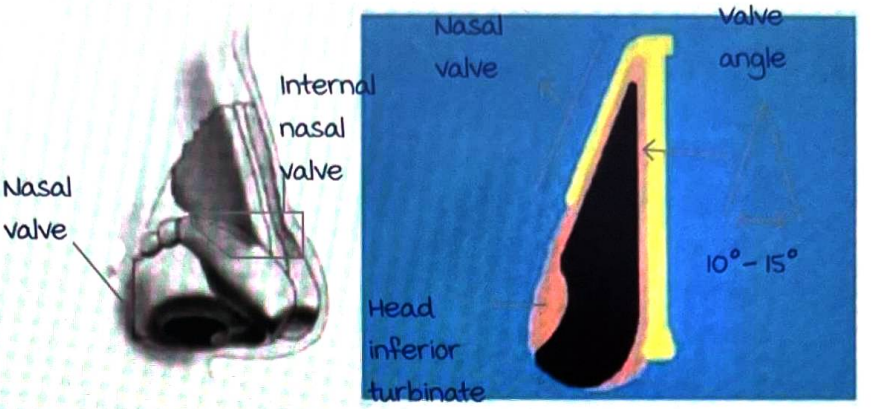

60c6b3eeaa8ded0e4e7e5ea7

The angle of the nasal valvular area is narrow and is normally 10–15 degrees. Therefore even a slight deviation in this part can cause severe obstruction. In such cases the patient is relieved after surgery.

The test used to diagnose the cause is Cottle's test.

In this test the patient is asked to pull the cheek laterally with the help of two fingers.

On doing so, the nasal valve area gets pulled laterally and the space gets opened up, relieving the obstruction.

- Endoscopy is the best test to find out the extent and site of deviation.

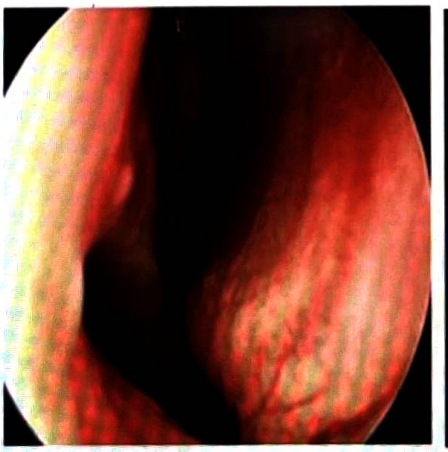

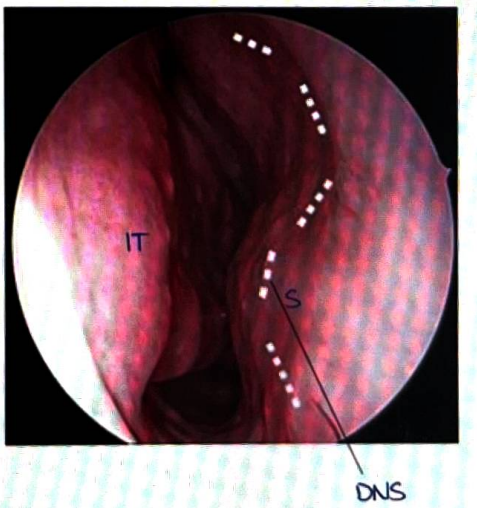

Active space

Leave Feedbac

CT : Not always required.

Septal surgery 00:26:03

It is of two types

1. SMR (Sub-Mucosal Resection of septum)
2. Septoplasty

Age :

The nasal areas contains the secondary centres of ossification which completely fuse by the age of 17 when the facial development occurs. If patient is operated upon before that, the deformity can recur or there can be additional deformity since the secondary centres of ossification are damaged.

Anaesthesia : Unless the patient has severe obstruction and the quality of life is been affected a conservative septal surgery is considered under LA.

Difference between SMR and septoplasty :

1. SMR :

On both the sides of the septum lie the mucoperichondrial flaps/lining.

In SMR, an incision is made (Killian's incision) at the lower border of the septum and mucoperichondrial flaps on both the sides of the septum is raised.

Now the septum is free of mucosa and perichondrium on either sides.

Active space

Leave Feedba

A 1 cm strip on the upper part of the dorsum of the external nose and a thin caudal strip is left (L shaped cartilage) with the removal of the remaining part of the septum.

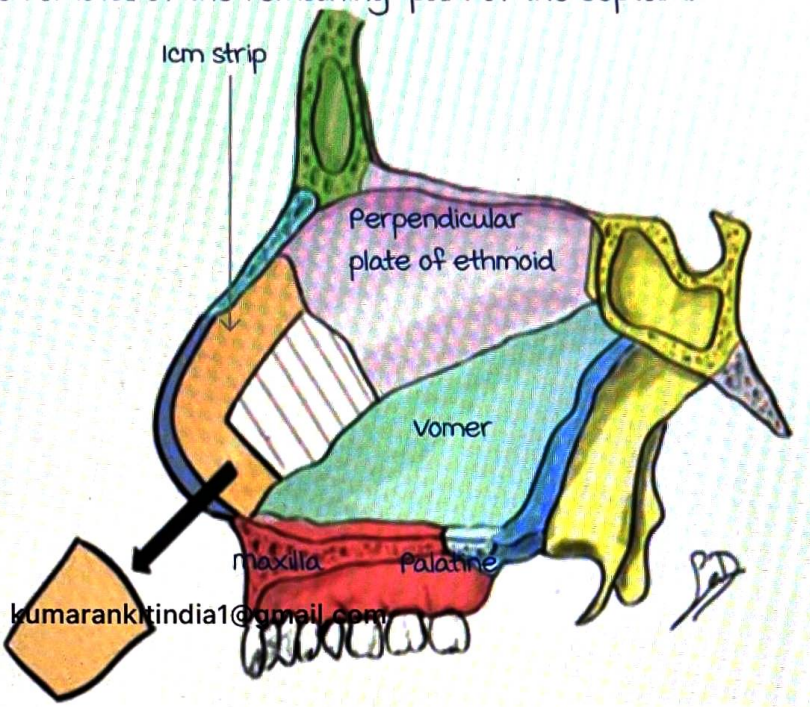

kumarankitindia1@gmail.com

- The dorsal part of the nose is supported by the septal cartilage below therefore removing the cartilage leads to saddling of the nose (not preferred).
- High risk of perforation.

Septoplasty

00:32:56

The incision is made (Hemitransfixion / Freer's incision) on the lower border of the septal cartilage and the mucoperichondrial flap is raised completely only on one side of the septum.

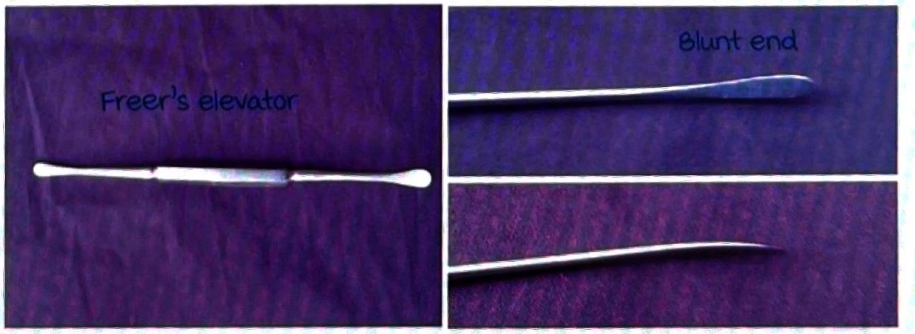

The flap and the mucosa is raised with the help of an instrument called Freer's elevator (blunt end).
Because of which the mucosa perichondrium and blood vessels are all persevered and chances of perforation is

Active space

minimal.

Only the part of the cartilage with deviation is removed.

more conservative and preferred over SMR.

LA is preferred.

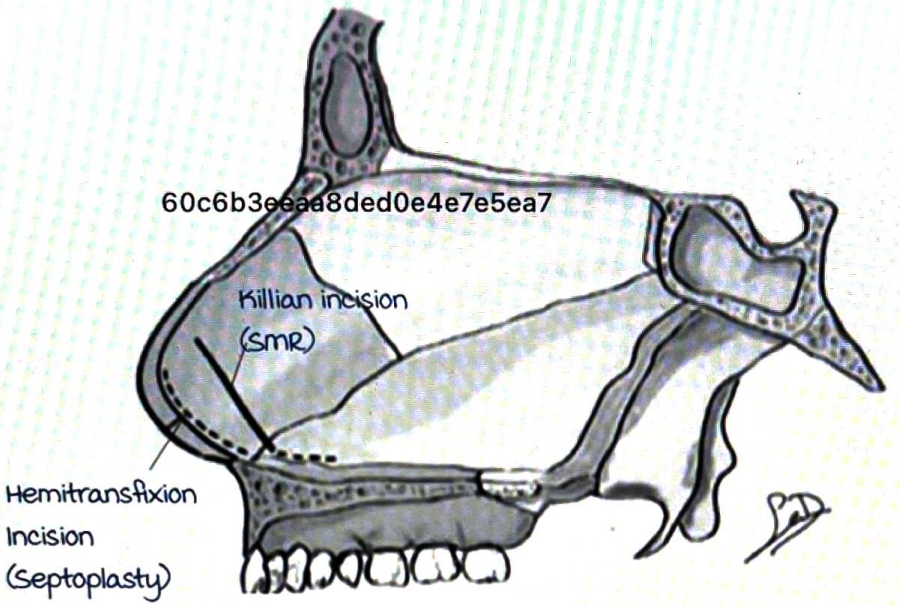

Endoscopic septoplasty 00:35:05

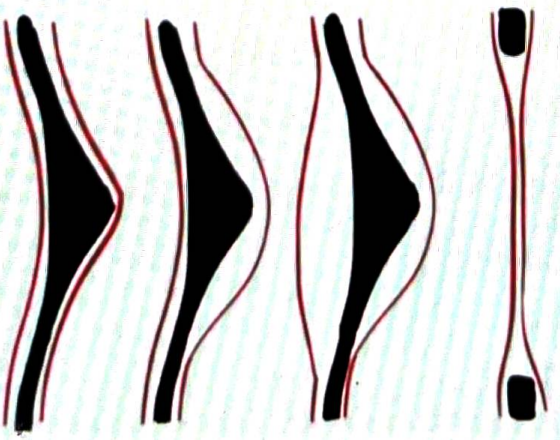

Active space

Leave Feedbac

Incision : An incision is made on the concave side (opposite side), in front of the deviation.

Raising the mucoperichondrial flap : The mucosa and the perichondrium overlying the septal cartilage are raised with the help of an instrument called Freer's elevator.

The flap is raised until the bony cartilaginous junction (the junction of quadrangular cartilage with the perpendicular plate of ethmoid).

Once the flap has been raised, the mucosa and perichondrium from the other side have to be raised cautiously to prevent the perforation of the septum.

The cartilage is then separated from mucosa and perichondrium on both sides and is held by Lux forceps and removed in pieces.

In endoscopic septoplasty, the incision is made in front of the deviation and the flap is raised partially.

Septal hematoma 00:43:08

Bilateral and most commonly occurs following trauma.

It is considered an emergency since the obstruction is always bilateral.

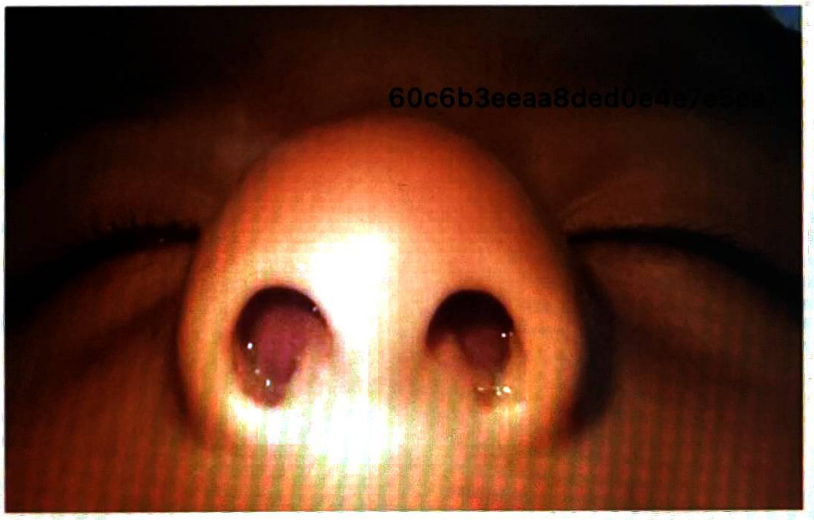

Whenever there is compression forces on the septum, it gets injured.

The perichondrium that is tightly adherent to the septum also gets damaged.

Active space

Leave Feedbac



As a result of which there is bleeding from both the sides occurs and the formation of hematoma takes place.
The septum in this case is separated from the perichondral lining which is responsible for the blood supply of the septum and the cartilage.
A delay in the drainage of hematoma can lead to the necrosis of the septum and cause saddling of the nose.

Case scenario :
Following surgery a patient falls off her bad and develops bilateral nasal obstruction. What should be the management of the patient?
Diagnosis : Septal hematoma.
Management : Immediate drainage within 48 hours.
Complications of septal hematoma :
1. Septal abscess :
Site of the abscess : Dangerous area of the face (Venous supply communicates with the pterygoid plexus which has direct communication with cavernous sinus).
2. Saddling of nose.

Septal abscess

Saddling of nose

Active space

Leave Feedbac

Perforation of the septum

00:48:43

- Most common cause is trauma following septoplasty.
- Cartilaginous perforation : Granulomatous conditions (TB, Granulomatosis with polyangiitis, lupus, leprosy).
- Bony perforation : Syphilis and granulomatosis polyangiitis.

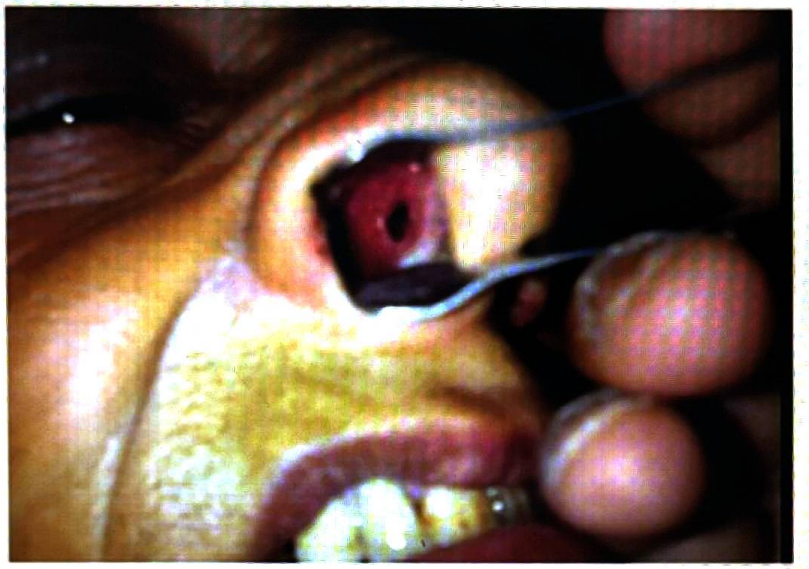

Other causes :

- Drugs : Prolonged use of nasal decongestants (otrivin), nasal steroid (the nozzle of the spray must be pointed laterally).
- Cocaine abusers (as cocaine causes vasoconstriction & ischemia of septal mucosa).
- Tumours.
- Nasal myiasis : Maggots seen in foul smelling patients with atrophic rhinitis (chrysomya fly).
  Management : Chloroform water and turpentine oil drops are initially used to kill the maggots and the they are removed by nasal douching (syringe is filled with saline solution and flushed into the nose).

kumarankitindia1@gmail.com

Active space

Leave Feedback

Nasal douching

kumarankitindia1@gmail.com

Rhinolith

Nasal myasis

- Foreign body : Batteries can lead to perforation. If the foreign body remains in the nose for a long time calcium deposition takes place around it called rhinolith.

Suspect foreign body when the child comes with unilateral foul smelling nasal discharge.

Generally the removal of foreign body is done with the help of an eustachian tube catheter and it does not require anaesthesia. Only in complicated cases general anaesthesia is used.

Eustachian tube catheter :

Uses : Removal of foreign body of the nose.



Septal perforation :

Any patient with septal perforation must be investigated to rule out granulomatous condition.

Active space

Leave Feedba

Symptoms :

- When a septal perforation is present, a whistling sound is heard during the passage of air through a narrow area.
- Crusting in the area.

60c6b3eeaa8ded0e4e7e5ea7

Management of septal perforation

01:02:32

- Non-surgical : Lubricants/ointments, nasal button.
- Surgical repair : Using flaps.
- Nasal button can cause obstruction.



Roof of the nose

01:05:48

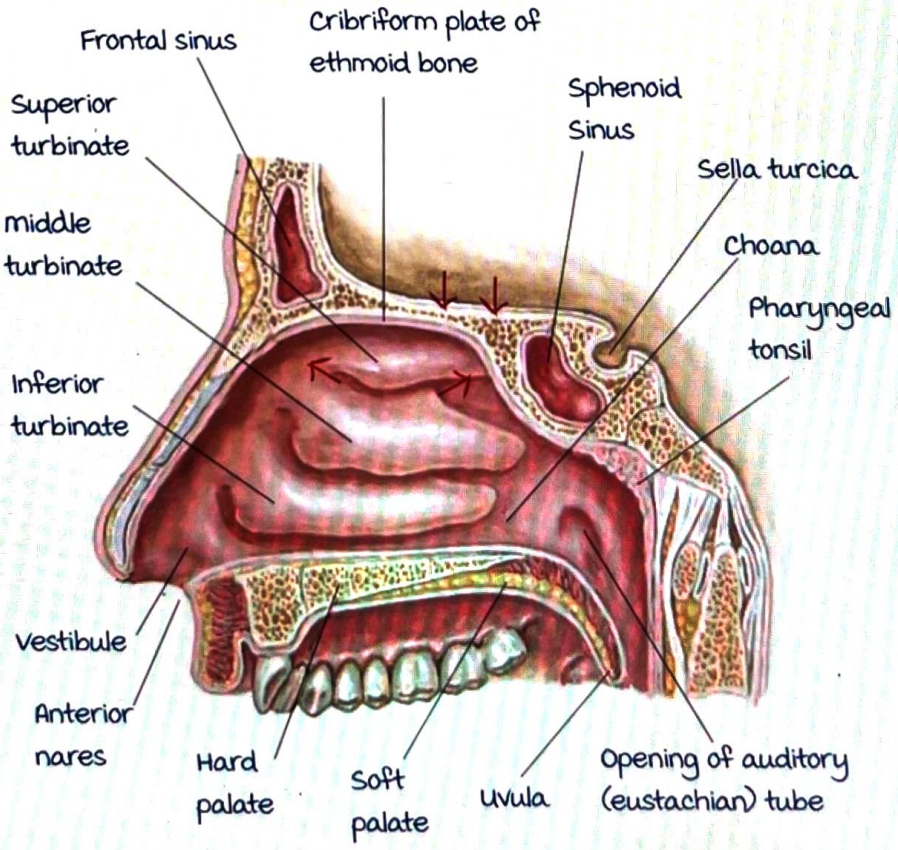

Active space

Leave Feedback

The roof of the nose is formed mainly by the cribriform plate of ethmoid which lies in the middle.
Anteriorly it is formed by the frontal bone and posteriorly by the sphenoid.

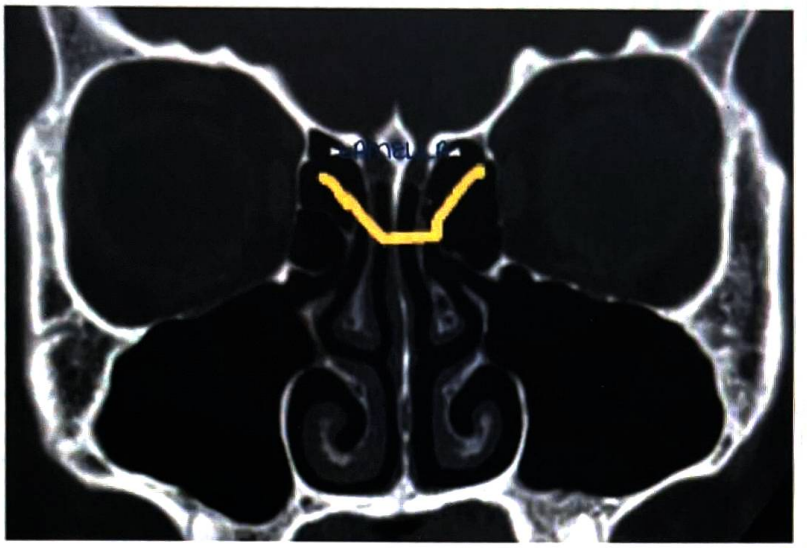

Anatomy of cribriform plate :
It looks like a fossa.
It has two parts : medial lamella and the lateral lamella.
The lateral lamella articulates with a thick bone which is the orbital plate of the frontal bone (fovea ethmoidalis). This junction is the weakest part of the cribriform plate.

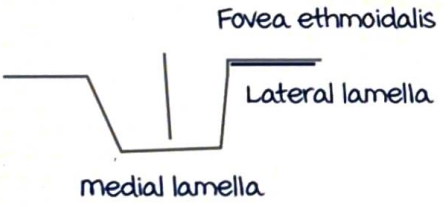

The most common site of CSF rhinorrhoea is fracture of cribriform plate (lateral lamella).
While operating the cribriform plate must be dealt with great caution because in certain individuals the olfactory fossa can be very deep.
Hence a CT is always advised before FESS.

kumarankitindia1@gmail.com

Keros classification of olfactory fossa :
Type I : Depth is 1–3 mm.
Type II : Depth is 4–7 mm.
Type III : Depth is 8–16 mm higher risk of injury to cribriform plate leading to CSF rhinorrhoea.

Active space

Leave Feedba

Olfactory fossae Keros

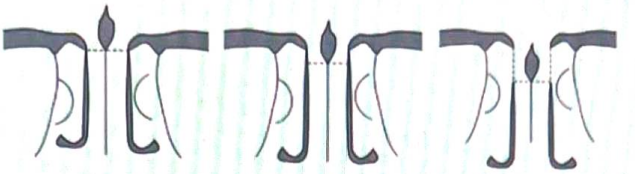

kumarankitindia1@gmail.com

The perforations for entry of olfactory nerves is called the danger area of nose as it act as a route for nasal infections intracranially.

Floor of the nose :

Posteriorly : Horizontal palatine bone.

Anteriorly : Palatine process of maxilla.

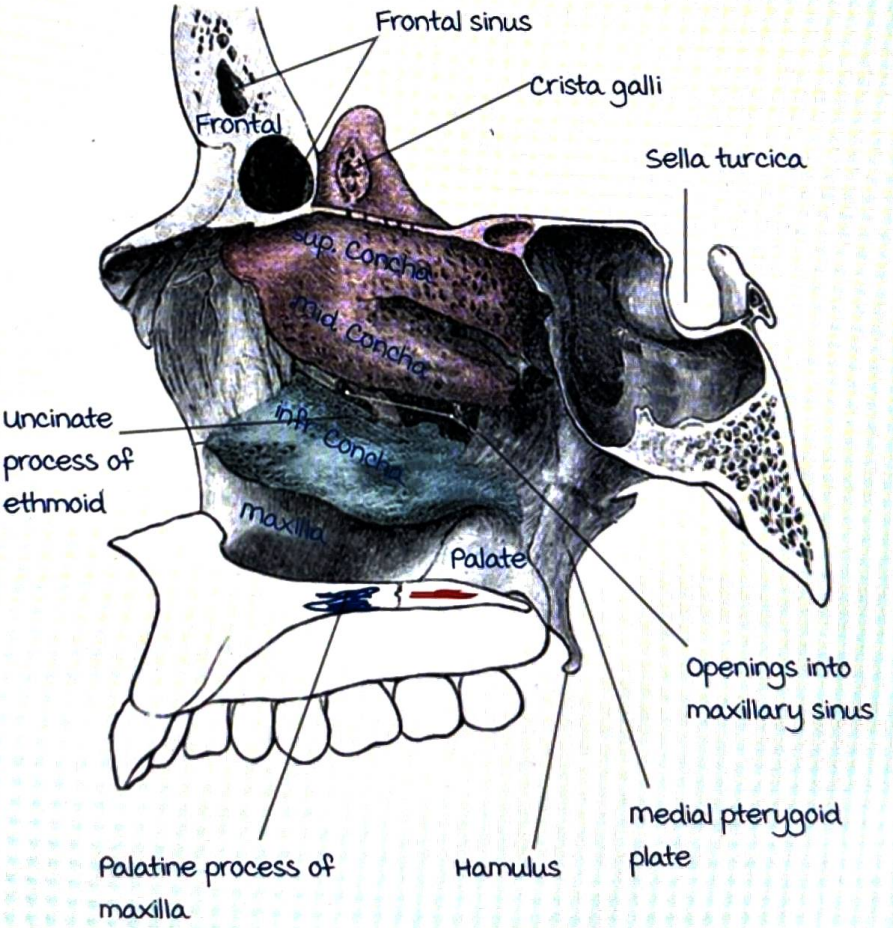

Active space

279
Leave Feedbac

NERVE SUPPLY OF NOSE AND ITS DISEASES : PART 1

Nerve (N) supply of nose :

- Olfactory nerve.
- Sensory nerve.
- Parasympathetic supply : For nasal secretions.

Olfactory nerve

00:01:46

Functions of olfaction :

- Needed for safety.
- Adds flavor to food : Air passes behind the palate and reaches olfactory mucoid and adds flavor to food.
- Responsible for adding emotions to memories.

Mechanism of olfaction :

Olfactory mucosa lines upper 1/3rd of the whole of nose.

On breathing, air passes through middle part of nose and 10–15% air reaches olfactory mucosa.

The odorant particles enter through 2 pathways :

- Nasal pathways.
- Retronasal pathway : While chewing.

Reaches olfactory mucosa and mixed with mucus. Sensory receptors are dendrites of bipolar cells.

69c6b3eeaa8ded0e4e7e5ea7

Their axons fuse to form olfactory nerves, which are 12 – 20 in number which pierce the cribrifom plate to enter into olfactory bulb.

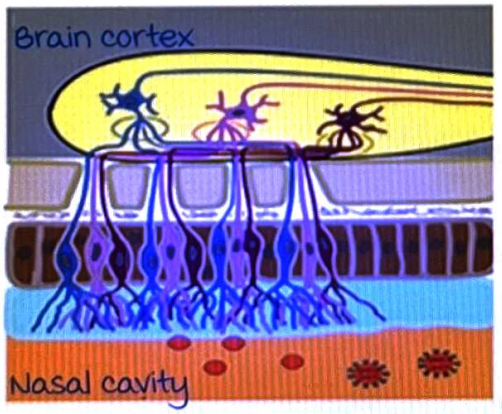

Active space

Leave Feedbac

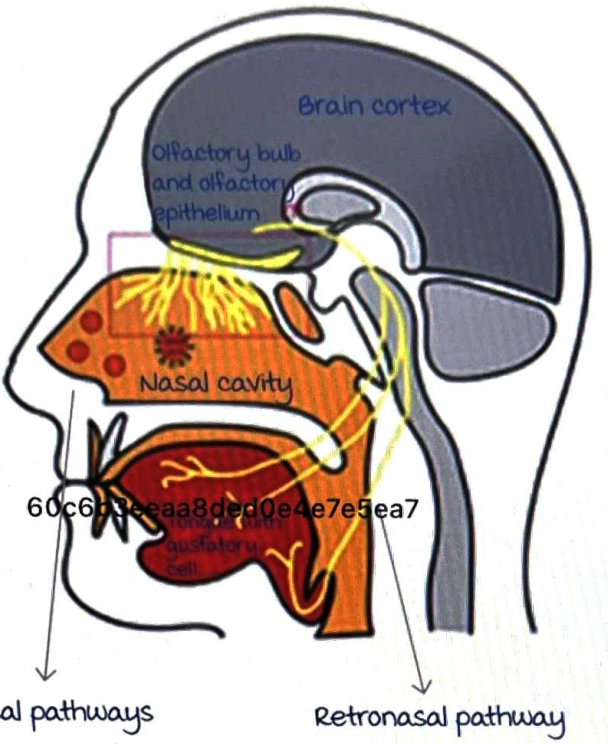

Dangerous area Nose

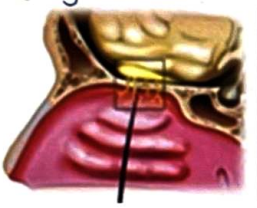

Dangerous area of nose : The above nerves traversing the cribriform plate are unmyelinated & act as pathway for transmission of infection from nose to brain.

Dangerous area of face : In the → triangular area deep facial vein → Communicates pterygoid plexus Communicates cavernous sinus.

Nerves on reaching olfactory bulb, synapse with the dendrites of mitral and tufted cells.

Their dendrites synapse with olfactory N and the axons fuse to form olfactory tract.

The olfactory tract will synapse with multiple areas in brain.

Olfactory cortex in temporal lobe : Primary olfactory cortex and association areas.

Primary olfactory cortex :

- Piriform cortex : Present at the junction of frontal and temporal lobe.

} For conscious perception of smell

Active space

- Entorhinal cortex : In temporal lobe.
- Hippocampus : Olfactory memory.
- Amygdala and hypothalamus : Emotional responses to smell.
- Reticular formation areas (RFA) : Visceral response.
  Reticular formation of midbrain (autonomic responses to smell, such as gastric secretion)
  Bad rotten material : Feel puckish by connection of nerves to reticular formation.

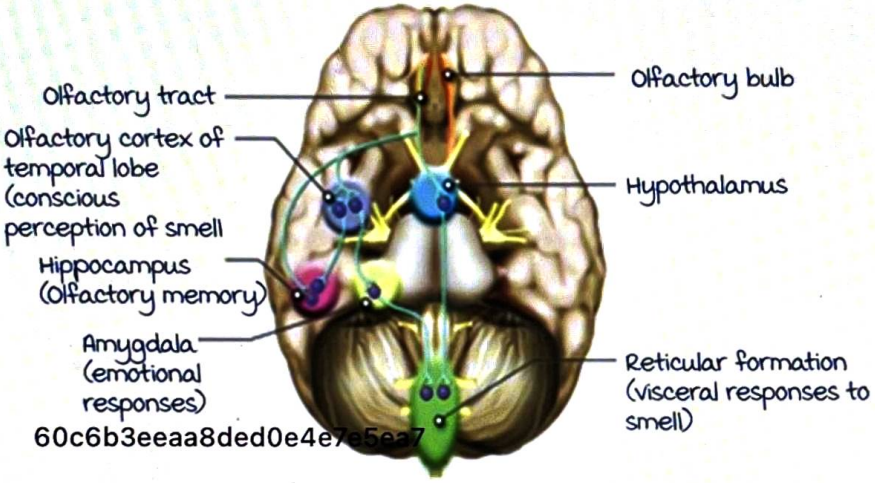

60c6b3eeaa8ded0e4e7e5ea7

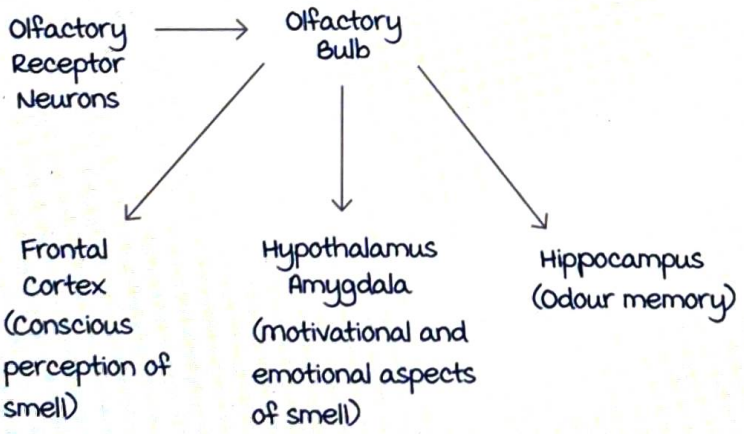

To test smell :
Eyes and one nostril are closed.
A non-irritant familiar substance is introduced in front of the opened nostril .
Ask if patient can smell anything and if so what is the familiar substance ?
Test other nostril with another non irritant familiar substance.

Leave Feedbac

If irritant substance used like ammonia : False positive as sensed by sensory nerves.

- Scratch and sniff cards :

The University of Pennsylvania Smell Identification Test (UPSIT)

60c6b3eeaa8ded0e4e7e5ea7

1. It smells like : 1
   a. gasoline (a)
   b. Pizza (b)
   c. Peanut (c)
   d. Flower (d)

Scratch & identify the smell.

Causes of smell abnormality 00:12:12

- Conduction block :
  Block/obstruction of conduction to olfactory mucosa :
  Like DNS, nasal polyp, nasal tumor, nasal mass, concha bullosa (pneumatized turbinate).
  Conduction block ⟶ Decreased smell ⟶ Hyposmia.
- Anosmia :
  Complete loss of smell.

Causes of anosmia :

- B/L complete block like in B/L polyps.
- Damage to olfactory mucosa (OM) :
  In viral infections like simple rhinitis, COVID or viral infections can cause temporary and permanent damage to OM.
- Atrophic rhinitis (nerves & mucosa atrophied).
- Transected nerves like in cribriform plate fractures.
- Damage to tracts :

Tumor in area of frontal lobe : Meningiomas.

- Parosmia / cacosmia / dysosmia :
  Perversion of smell.
  During recovering stage and temporary.

Active space

Leave Feedba

- Phantosmia : Perceiving smell in absence of smell .
  temporal lobe seizures
- Presbyosmia : Age related.
- Neuro degenerative diseases :
  Loss of smell is early sign,
  Like in : Alzheimer's.
  Parkinsonism.
  multiple sclerosis.
- Congenital anosmia :
  Kallmann syndrome (hypogonadotropic hypogonadism).

Sensory nerves

00:21:38

Functions :

- For pain mediating.
- Regulate air to body temperature.
  - Heat exchange : Vasodilation.
  - Humidification : Mucus secretion.
- Sensing Irritant exposure : Leads to nasal secretion.

Sneezing by contracting nasal & pharyngeal muscle.

- Protection of airways.

Sensory supply : Needed for anaesthesia.

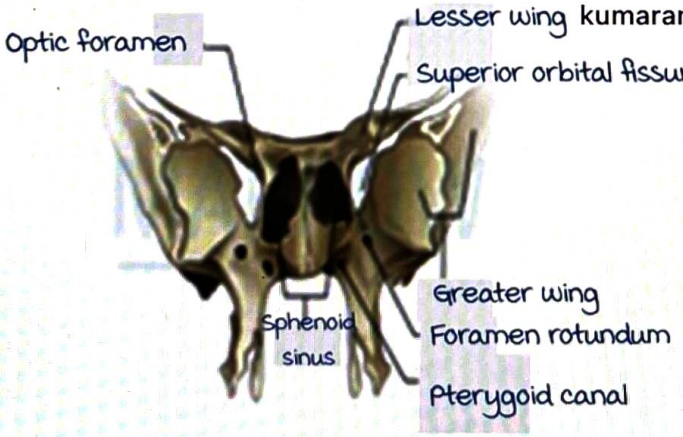

kumarankitindia1@gmail.com

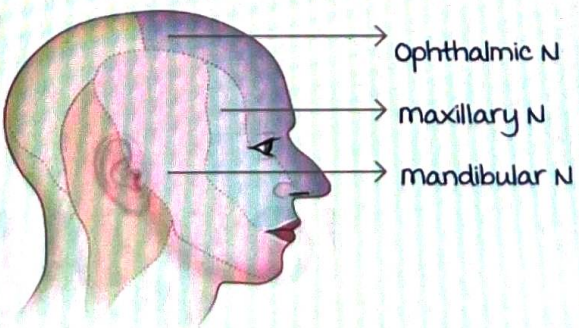

Active space

Leave Feedba

Ophthalmic nerve (ON)

00:26:48

Branch of trigeminal N (with its Gazivian Ganglion in meckel's Cave).

3 branches given ophthalmic, maxillary, mandibular.

Exit through superior orbital fissure as :

3 branches :

1. Lacrimal.
2. Frontal.
3. Nasocilliary.

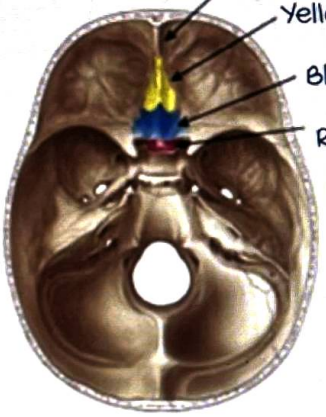

60c6b3eeaa8ded0e4e7e5ea7

Nasocilliary :

Optic foramen, posterior and anterior ethmoidal foramen.

Gives 3 branches :

1. Posterior ethmoidal N.
2. Anterior ethmoidal N (AEN) (branches : Internal & external nasal nerves).
3. Infra trochlear N.

After piercing cribriform plate, AEN give branch to lateral wall called internal nasal N. And traverse roof of nose upto septum and give branches. Pierces at junction of nasal bone and upper lateral cartilage and comes out.

Gives internal branch to lateral wall and supplies external part of nose (external nasal).

Active space

Leave Feedback

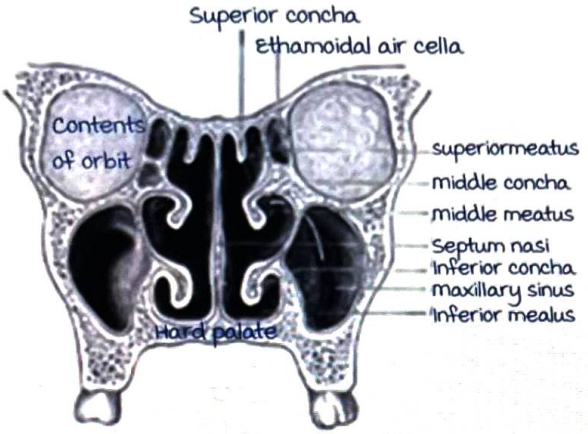

N anaesthesized : Infra trochlear.

N anaesthesized : External nasal

N anaesthesized : Anterior ethmoidal /nasocilliary.

Maxillary N (MN)

00:34:44

Main N giving sensory supply, ala of nose.

MN exits through foramen rotundum and enters the sphenopalatine fossa.

↓

Passes Sphenopalatine ganglion without relaying.

↓

Gives branches to :

Eye.

Maxillary sinus.

Active space

Leave Feedba

Palate :

Greater & Lesser Palatine N

(through Greater and Lesser Palatine Foramen).

↓

60c6b3eeaa8ded0e4e7e5ea7

Infraorbital N —

- The main trunk of MN continues and enters inferior orbital fissure.
- ↓
- Passes through floor of orbit through infra orbital canal.
- ↓
- Exits through infraorbital foramen.
- ↓
- Then supply orbit, cheek, lateral part of external nose, upper lip

Sphenopalatine / pterygopalatine fossa 00:37:00

Lateral wall of nose same as medial wall of maxilla.

Important : Blood vessels and N supplying nose are present.

It enters nose through sphenopalatine foramen (SP)

(1 cm behind middle turbinate).

Site of origin of angiofibroma.

At SP foramen, nose can be anaesthetized.

Boundaries :

Anterior : Posterior border of maxillary antrum.

Posterior : Anterior border of pterygoid plate.

Lateral : Opening called pterygomaxillary fissure communicating with infratemporal fossa

medial : Lateral wall of nasopharynx (contains sphenopalatine foramen).

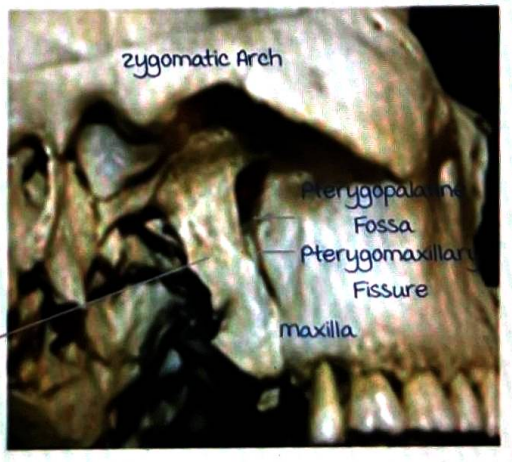

Active space

Leave Feedback

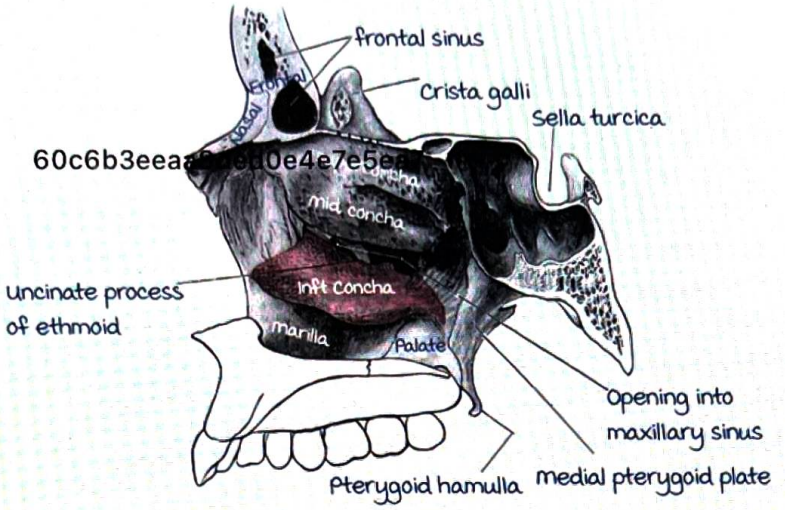

Contents of sphenopalatine fossa

00:44:38

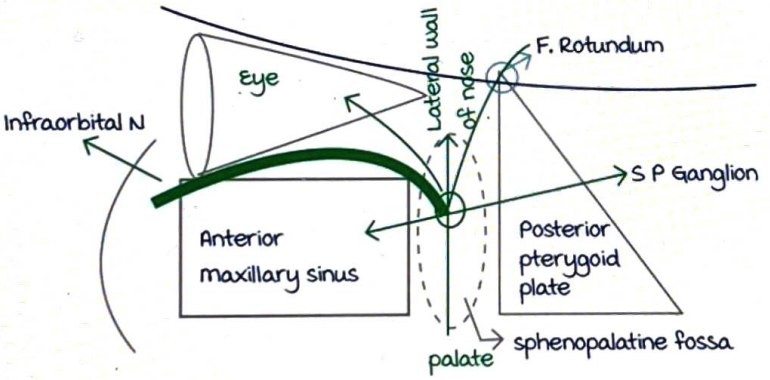

Lateral : Pterygomaxillary fissure communicates

↓

Infratemporal fossa.

Medial : Lateral wall of Nasopharynx.

Contents :

1. Maxillary Artery.
2. Maxillary N.
3. Sphenopalatine ganglion.

Supply :

Main branches to nose, paranasal sinuses.

Sensory supply to nose.

Main branch entering through SP foramen is called Nasopalatine N.

Active space

Leave Feedba

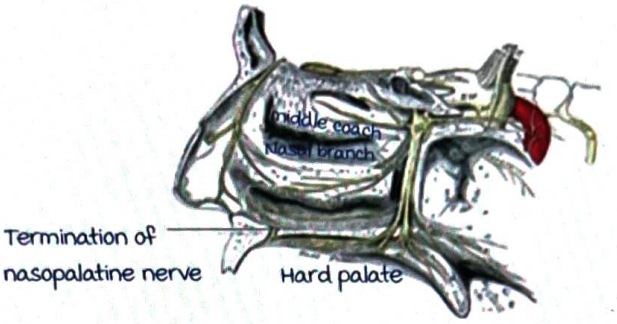

Causes of infraorbital N injury/ cheek anesthesia

00:53:18

- Zygomatic bone fractures.
- Floor of orbit fractures.
- Maxillary fractures.

N Anesthetized : Sphenopalatine ganglion block.

At SP foramen, using cotton swab / syringe, anesthetic can be injected in sphenopalatine ganglion.

Through the greater palatine foramen (medial to 3rd molar) sphenopalatine ganglion / greater palatine N.

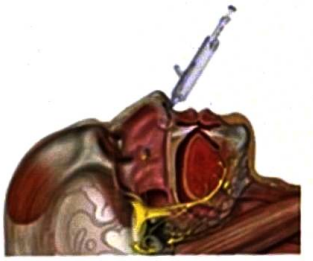

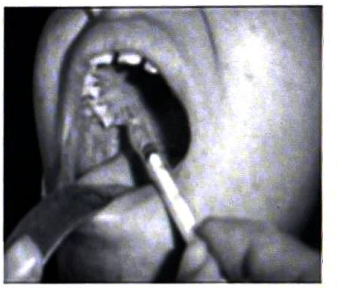

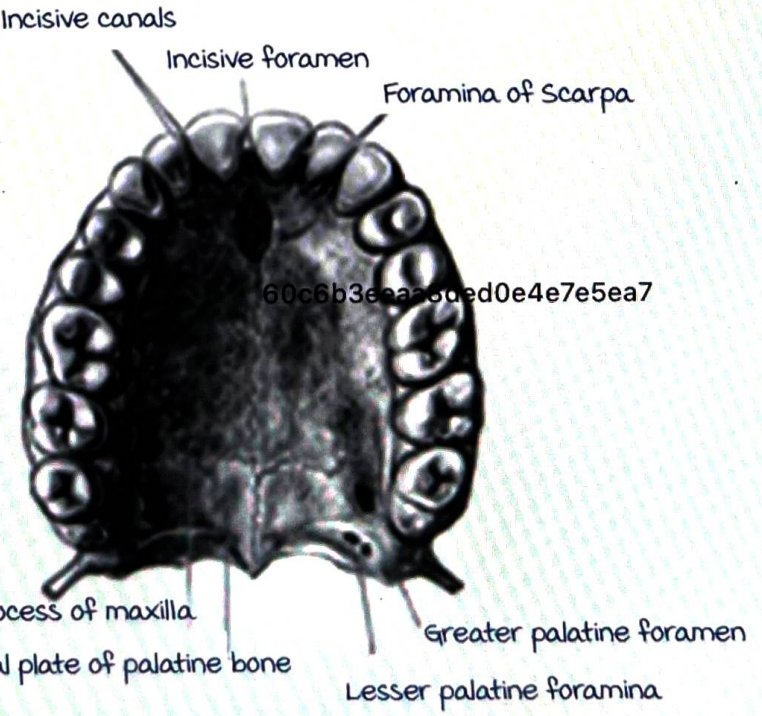

60c6b3eaa3ded0e4e7e5ea7

Active space

Leave Feedba

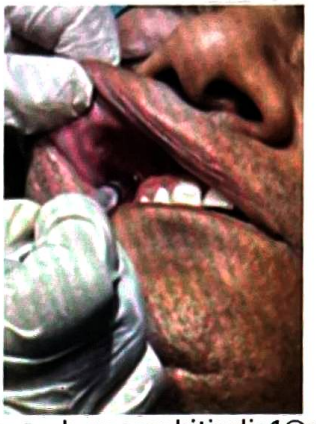

kumarankitindia1@gmail.com

N Anesthetized Infraorbital nerve

(cheek anaesthesia)

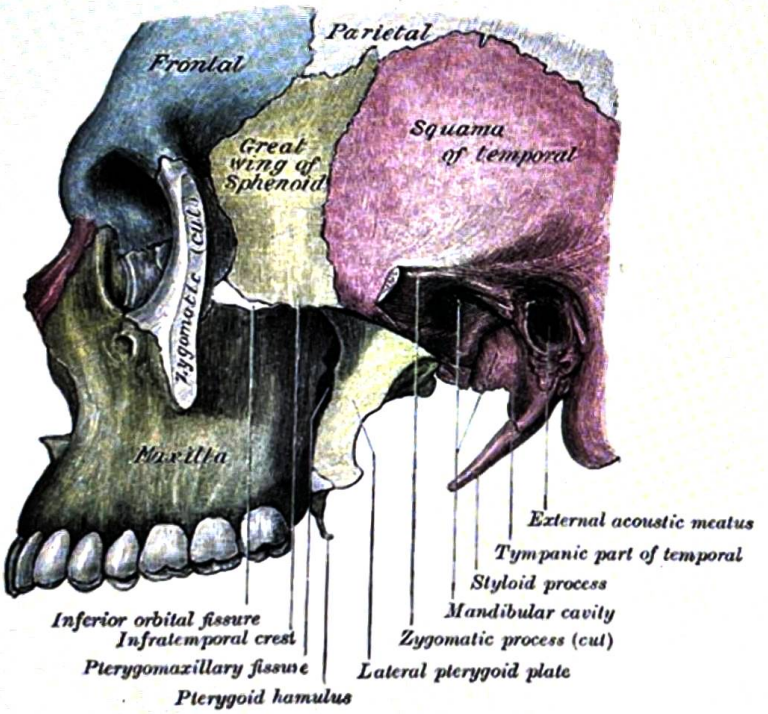

Active space

Leave Feedbac

NERVE SUPPLY OF NOSE AND ITS DISEASES : PART 2

Parasympathetic supply of nose 00:00:35

3rd nerve supply → Parasympathetic supply of nose : Nasal secretions and vasodilatation.

Sensory supply → Temperature and irritants are sensed → Reflex humidification by increasing secretions and vasodilation by parasympathetic system.

Always in conjugation with sympathetic system.

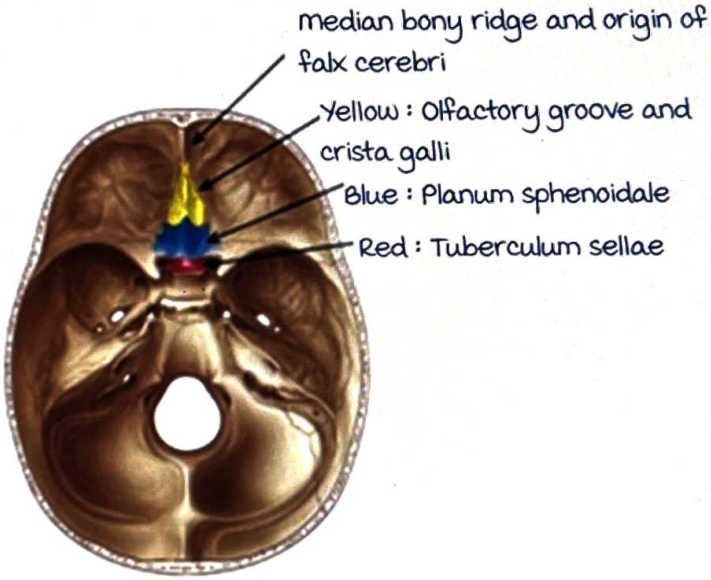

Parasympathetic supply is by Vidian nerve.

Vidian nerve formed by :

1. Greater superficial petrosal nerve (branch of facial nerve) (parasympathetic) → Vasodilatation + increased mucosal secretions.
2. Deep petrosal nerve (sympathetic plexus from superior cervical ganglion around internal carotid artery) → Vasoconstriction.

Greater superficial petrosal nerve → 1st genu → Enters cranium → Fuses with deep petrosal nerve → Fusion → Vidian nerve → Out through the root of sphenoid bone (pterygoid canal) → Sphenopalatine fossa.

Active space

Therefore, vidian nerve also known as nerve of pterygoid canal. Vidian canal is also called as pterygoid canal.

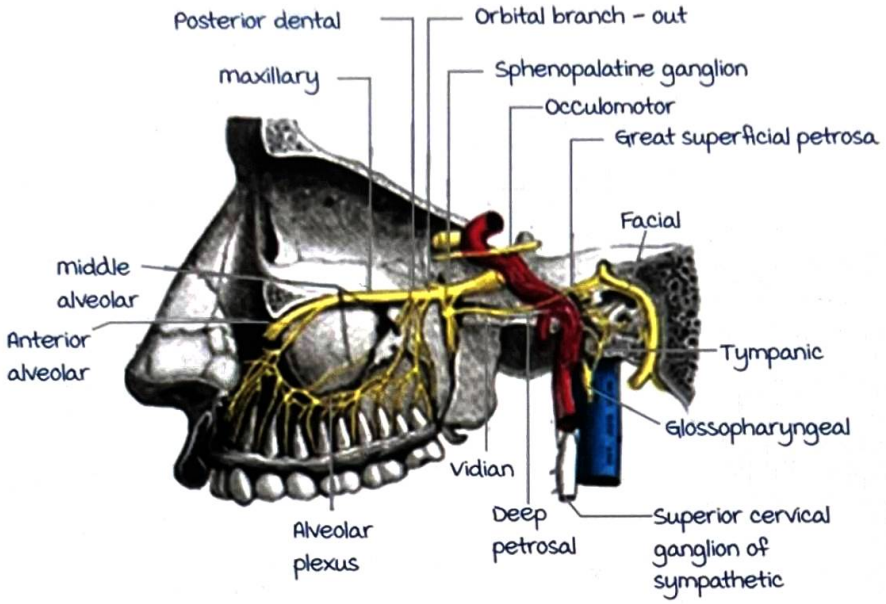

Vidian canal / pterygoid canal nerve of pterygoid canal

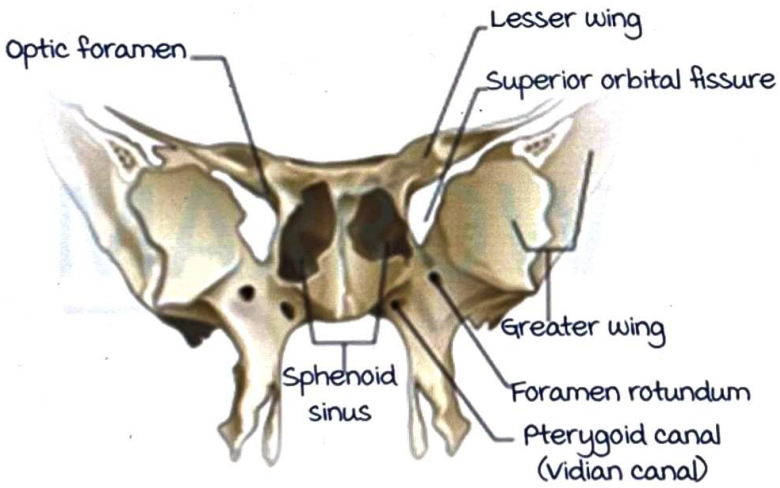

Sphenopalatine ganglion : Largest parasympathetic ganglion.

- Has both sympathetic and parasympathetic supply.
- Greater superficial petrosal nerve (parasympathetic) will relay and cause
  Vasodilation : On vessels.
  Increase secretions : On mucosal glands.
- Deep petrosal (sympathetic) will pass through the ganglion without relaying and cause vasoconstriction.
- Ganglionic branches of the maxillary nerve also pass through this ganglion → Supply lacrimation, nasal secretions, palatine secretions.

60c6b3eeaa8ded0e4e7e5ea7

Active space

Leave Feedba

Controlled by autonomous nervous system : Nasal cycle (Alternate congestion and decongestion every 2.5 to 4 hours).

Rhinitis

00:12:59

Any kind of irritant/stimulant → Sensory supply → Parasympathetic signal → Nasal obstruction (vasodilatation) + increase secretion + post nasal drip + itching/sneezing (sensory stimulation) → Rhinitis.

If symptoms last for > 1 hour/day for > 2 days → Rhinitis.

kumarankitindia1@gmail.com

1. Infectious rhinitis :
   Stimulant : Virus/bacteria.
   Virus > bacteria.
   Virus : mc is rhinovirus.
   Acute onset + systemic features like prostration, headache is s/o viral etiology, but bacterial is localised.
   Symptoms : Generalized features.
   Management : Symptomatic treatment (viral) or antibiotics (bacterial).

2. Non infectious rhinitis :
   Chemicals : Occupational rhinitis.
   Cold : Cold induced rhinitis/skier's rhinitis.
   Capsaicin.
   Drugs : Alpha blockers (vasodilation).
   Hormonal rhinitis : Estrogen (vasodilation).

3. Allergic rhinitis :
   When stimulus is something that the patient is allergic to → Allergic rhinitis.
   Stimulant : Allergen.

4. Idiopathic/vasomotor rhinitis :
   No cause found.
   NANIPER : Non Allergic, Non Infectious, PERrennial rhinitis.
   Increased parasympathetic activity (unknown cause)→ Rhinitis. Present throughout the year almost.

Active space

Leave Feedback

Allergic rhinitis vs vasomotor rhinitis

00:24:42

	Allergic rhinitis	Vasomotor rhinitis.
History	Allergy present.	No history.
Symptoms	Similar to rhinitis (nasal obstruction + discharge + post nasal drip + itching + sneezing etc).	Similar to rhinitis (nasal obstruction + discharge + post nasal drip + itching + sneezing etc).
Mucosa	Pale, boggy (edematous). Release of allergic mediators → Leakage of basement membrane → Exudation of fluid → Pale and boggy appearance.	Congested mucosa (parasympathetic → Vasodilation → Congestion)
External features	1. Dark circles around eye (venous congestion : Allergic shiners). 2. Folds appear prominent : Dennie Morgan lines. 3. Persistent rubbing of nose : Allergic salute.	No external features.
Test	Type I hypersensitivity reaction : Raised IgE levels (Radio-allergo-sorbent test (RAST) or skin prick test).	All tests : Negative.
Management	Avoid allergens.	
Medical management	Anti-allergics, leukotriene inhibitors (montelukast), decongestants, nasal steroid sprays. Immunotherapy.	Nasal decongestants, steroid nasal spray.
Surgical	No surgical management helps.	Vidian neurectomy (if no benefit from medical management).

60c6b3eeaa8ded0e4e7e5ea7

Pale mucosa

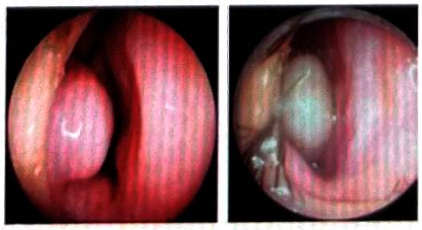

Congested mucosa

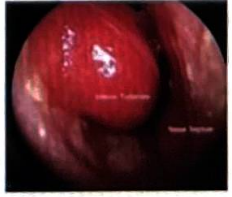

Active space

Leave Feedba

Allergic shiners and Dennie morgan lines

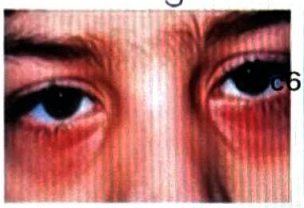

Dennie morgan lines

Allergic salute

Rhinitis medica mentosa

00:37:46

Due to prolonged use of nasal decongestants.
Nasal decongestants : Should be used only for a short period of time, not more than 3 -7 days at a stretch.
If used > 7 days → Vasoconstriction → Blood supply to nose decreases → Accumulation of toxins → When drug is stopped → Reflex vasodilatation → Uses decongestants again → habit.
Repeated use → Persistent vasoconstriction → Decreased blood supply → Ischemia → Rhinitis medica mentosa.

Rhinitis medica mentosa : Due to prolonged use of nasal decongestants.
Management :

- Nasal steroid spray, if no benefit short course of systemic steroid is used.
- Wean off nasal decongestants.

Prevention : Stop decongestants.

Hypertrophied inferior turbinate

00:44:38

Chronic irritation in the nose → Persistent parasympathetic supply → Chronic vasodilation → Venous sinusoids in inferior turbinates remains dilated → Inferior turbinate gets hypertrophied (maximally exposed) → Hypertrophied rhinitis.

Inferior turbinate : Erectile tissue (increased venous sinusoids). It dilates to regulate body temperature.
Not specific to any condition.

Active space

Leave Feedbac

Cause : Chronic infection, chronic sinusitis, allergic rhinitis & vasomotor rhinitis.

Appearance of hypertrophied turbinate : mulberry turbinate (irregular/uniform).

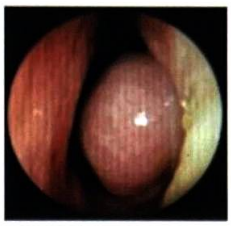

mulberry

management : Partial turbinectomy or reduce turbinates (cryotherapy/cautery/laser/knife etc.,).

Total resection not done as inferior turbinate plays a major role in thermal regulation.

Complete resection of turbinates → Post op false sense of nasal obstruction → Empty nose syndrome.

kumarankhindiali@gmail.com

Chronically exposed to dry or hot air → Anterior 1/3rd only affected (as turbinates regulate temperature) → Crusting limited to anterior 1/3rd part of the nose.

Normal tubinate

Congested HT

Deviated nasal septum

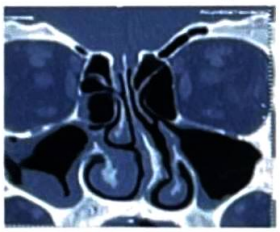

Before and after partial turbinectomy

Rhinitis sicca :

- C/o localised crusting at the anterior 1/3rd of nose.
- Occurs due to hot dry air.
- Rx : Avoid dry air, emollients/lubricants.

Rhinitis caseosa/nasal cholesteatoma/allergic fungal rhinitis :

Collection of cheesy material in the nose due to :

- Chronic sinusitis.
- Nasal polyps.
- Or any kind of chronic obstruction to the nose.
- Not related to otitis cholesteatoma.

Active space

Leave Feedbac

ARTERIAL SUPPLY OF NOSE AND EPISTAXIS

Arterial supply

00:01:12

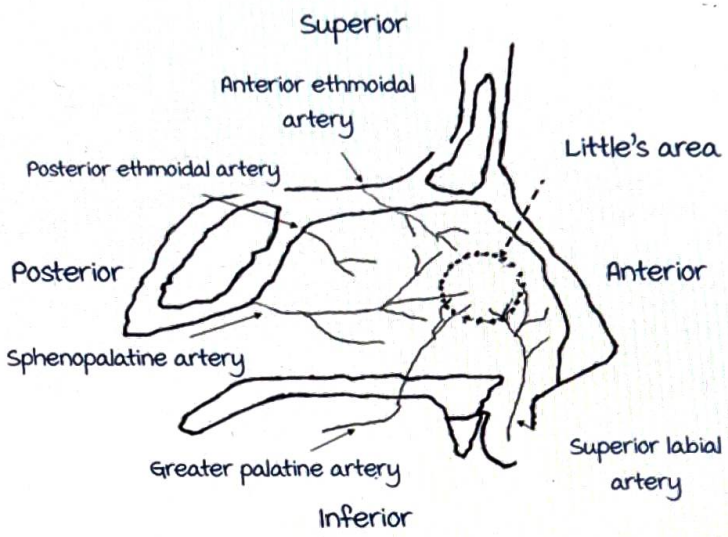

Branches from both internal carotid and external carotid arteries supply the nose (ECA > ICA).

From the internal carotid artery : Ophthalmic artery.
The ophthalmic artery enters orbit throught the optic canal to give two branches, the anterior and the posterior ethmoidal arteries.
These arteries pierce the lamina papyracea and pass through the same named foramen to enter the nose.

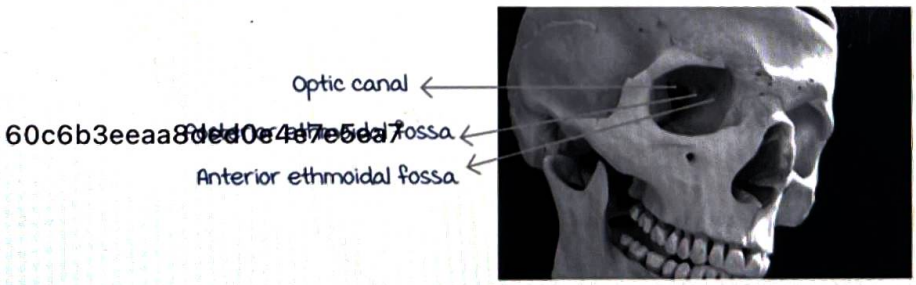

60c6b3eeaa8ded0e487e5da7

while entering the nose, the anterior ethmoidal artery produces a projection called the anterior ethmoidal notch, which is seen on a coronal CT scan as Nipple sign.
This sign is important to identify before performing a functional endoscopic sinus surgery (FESS).

Active space

Safe entry of anterior ethmoidal artery : If artery enters above the anterior ethmoidal air cells to reach the cribriform plate.
Unsafe entry : When the anterior ethmoidal artery passes through the ethmoidal air cell.

Therefore, artery can be injured during the removal of these air cells by FESS leading to an orbital hematoma.
Orbital hematoma, is a hematoma in a closed space which can lead to blindness.
Hence, it is an emergency and needs to be drained immediately with ligation of the artery through external approach or internal approach.

Internal approach is difficult since patient's sinuses are already infected.
For an easier external approach, a medial canthal incision (Lynch Howarth's incision) is given.
60c6b3eeaa8ded0e4e7e5ea7
Skin flap is removed upto the anterior ethmoidal foramen, which is 24 mm behind the anterior lacrimal crest.
The posterior lacrimal crest is 12mm behind the anterior ethmoidal formen.

The optical canal is around 6 mm behind the posterior ethmoidal foramen.

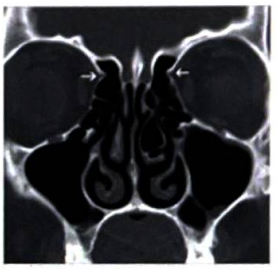
Nipple sign
Arrow shows anterior ethmoidal artery

Orbital hematoma

Lynch Howarth's incision

The anterior ethmoidal artery gives lateral branches to the nose in the eye and then passes through the cribriform plate to give branches to the septum.

Active space

Leave Feedbac

Anterior ethmoidal supplies anterior part of septum.

Posterior ethmoidal supplpies a small area postero-superiorly.

Branches of the internal carotid artery supplying the nose :

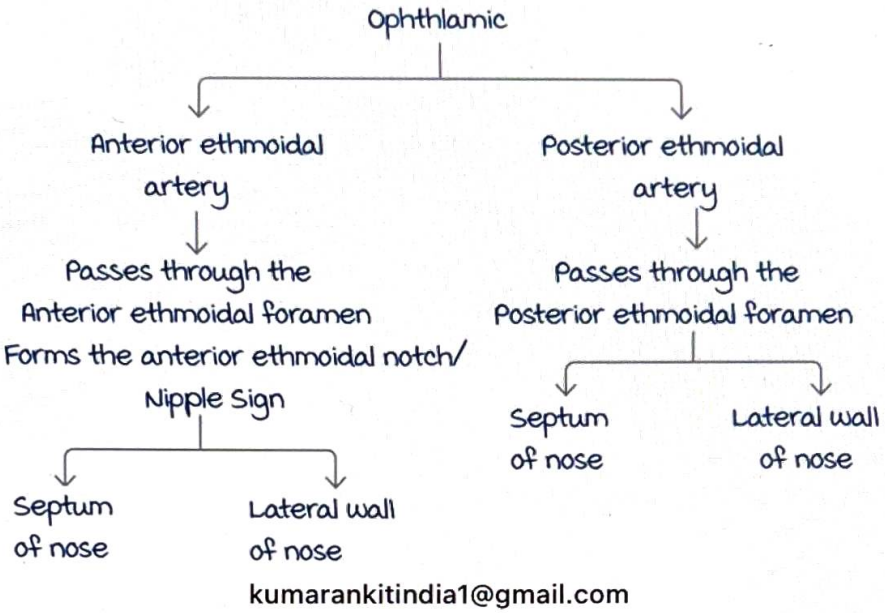

kumarankitindia1@gmail.com

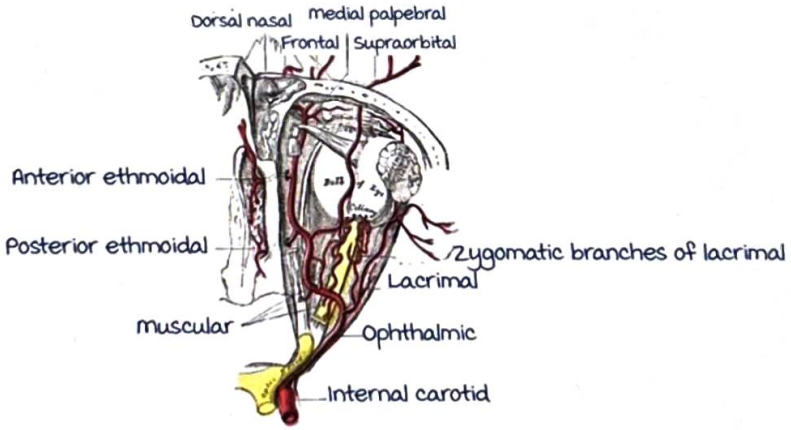

Injury to which artery during FESS leads to orbital hematoma : Anterior ethmoidal artery.

Incision to ligate anterior ethmoidal artery : Lynch Howarth incision.

Anterior ethmoidal notch on CT is known as : Nipple sign.

Active space

Leave Feedba

Branches of external carotid artery 00:12:06

External carotid artery has multiple branches in the neck, whereas internal carotid artery has no branches in the neck.
Arterial supply of the nose is mainly by external carotid artery.
Maxillary artery and facial artery supplies the nose.
60c6b3eeaa8dad0e4e7e5ea7

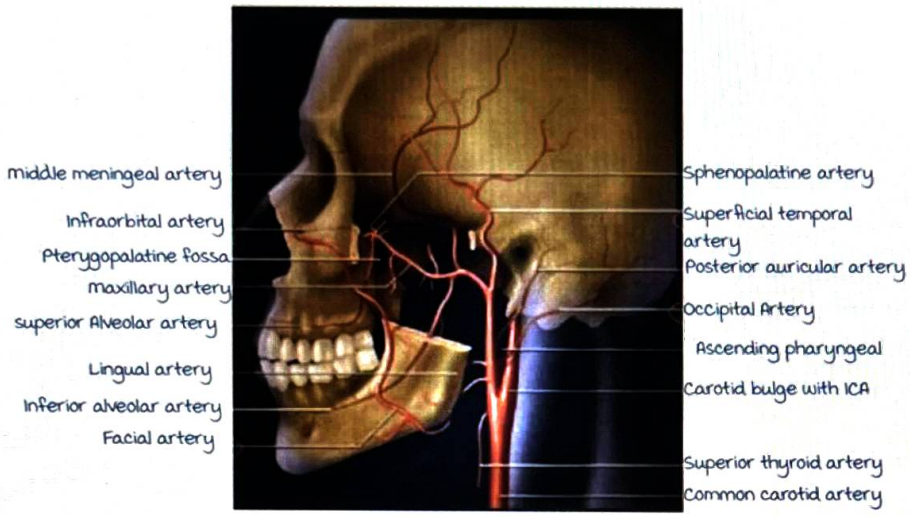

Maxillary artery enters the sphenopalatine fossa from the infratemporal fossa.

Boundaries of sphenopalatine fossa :

1. Anterior : Posterior part of maxillary antrum.
2. Posterior : Anterior part of pterygoid plate.
3. Laterally opens to infratemporal fossa through the pterygomaxillary fissure.
4. Medial : Lateral wall of nose with sphenopalatine foramen.

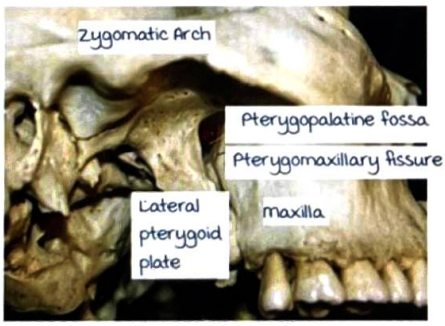

The maxillary artery gives two branches inside the sphenopalatine fossa.

1. Greater palatine artery : Runs through the Greater palatine foramen, to supply the palate and then runs upwards to supply the nose.

Active space

Leave Feedbac

2. Sphenopalatine artery : This artery enters the nose through the Sphenopalatine foramen.
The foramen is present 1 cm behind the posterior end of middle turbinate.

This artery supplies the lateral wall and then runs posteriorly up till the septum to supply it.

Superior labial artery is the branch of facial artery that supplies the septum through its septal branch.

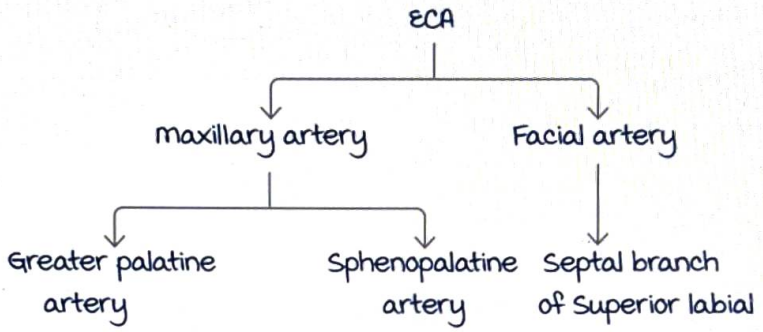

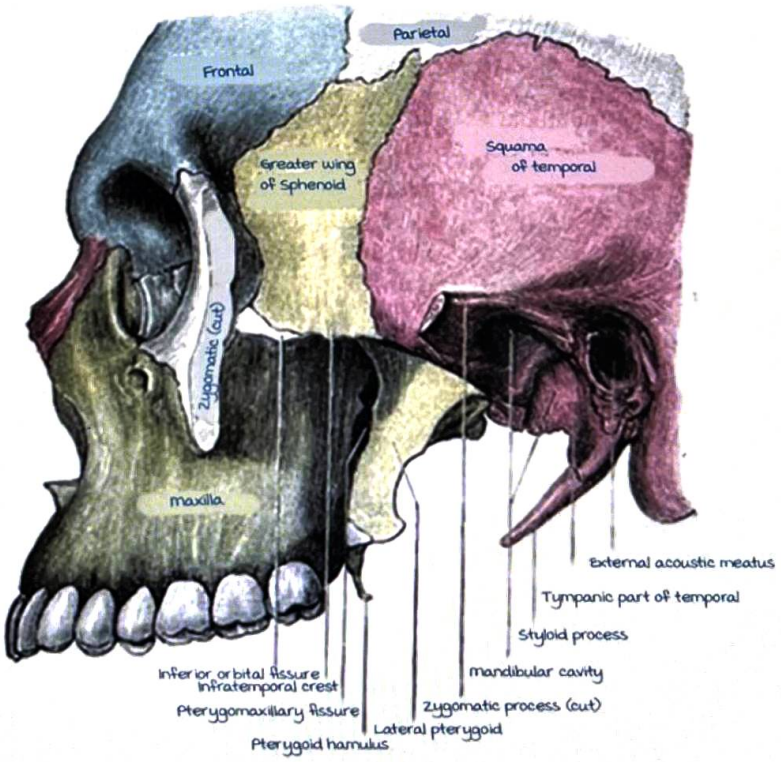

60c6b3eeaa8ded0e4e7e5ea7

Active space

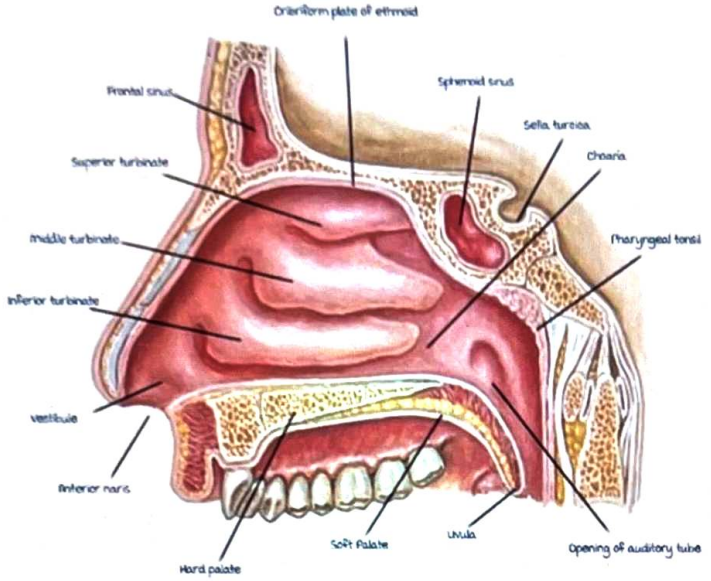

Little's area of the nose

00:21:30

All the arteries of the ECA and ICA anastomose on the antero-inferior part of the septum to form the Little's area. The plexus of arteries is called as Kiesselbach's plexus.

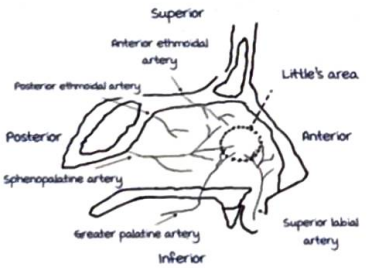

Keisselbach's plexus formative arteries :

1. Anterior Ethmoidal.
2. Superior labial.
60c6b3eeaa8ded0e4e7e5ea7
3. Sphenopalatine.
4. Greater Palatine.

Posterior ethmoidal artery is not a part of Keisselbach's plexus.

Sphenopalatine artery is the main artery of the plexus.

Active space

Leave Feedbac

Little's area is the most common site of anterior epistaxis as it is accessible to nose picking.
Hence, sphenopalatine artery is also known as artery of epistaxis.

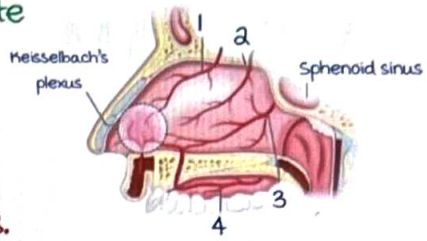

Kiessel bach's plexus

Most common cause of anterior and posterior epistaxis is Sphenopalatine artery.
The artery is ligated in the nose at the sphenopalatine foramen.

Little's area

Epistaxis is divided into anterior and posterior from the maxillary sinus ostium/ Pyriform aperture.
Pyriform aperture is the opening in the bony skull of the nose.
Anterior epistaxis is easily visualised.


Pyriform aperture

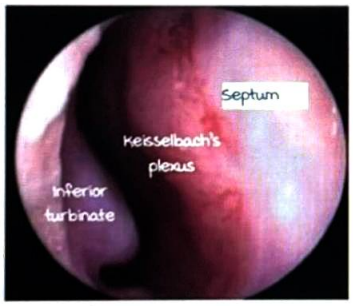

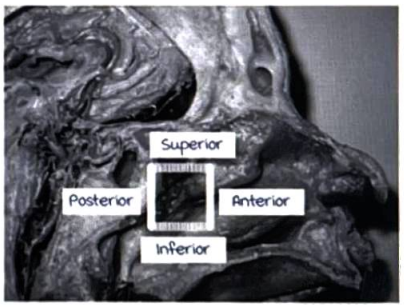

Epistaxis

00:30:08

60c6b3eeaa8ded0e4e7e5ea7

Mainly arterial bleeds.
Venous bleeds are from :
1. Anterior Retrocollumellar vein :
Bleeding from septum.
2. Woodruff's plexus : Bleeding from the lateral wall.
woodruff's plexus is present at the posterior end of inferior turbinate.
Columella : Lower most part of septum where medial crura of lower alar cartialges meet.
MC cause of both anterior and posterior epistaxis :
Sphenopalatine artery.

Active space

Leave Feedbac

Causes of epistaxis : Bimodal age presentation.

- Most common cause in children : Trauma by nose picking.
- Upper respiratory tract infections causes dryness in the area leading to epistaxis.
- Foreign body presentation in children can also come with epistaxis but more likely to come with unilateral foul smelling discharge.

Most common cause in adults/elderly : Idiopathic (previously considered to be hypertension. But epistaxis in hypertension was found to be due to vascular fragility).

Other local causes :

1. Surgical trauma (septoplasty, FESS).
2. Deviated nasal septum.
3. Infections (granulomatous infection, rhinosporidiosis).
4. Tumors : Young male with recurrent epistaxis could be an angiofibroma.
5. Drugs : Nasal Decongestants, steroid nasal spray.

Systemic causes :

Platelet disorders :

Disorders in Primary hemostasis :

Thrombocytopenia.

1. Decreased production of platelets :
   - Leukemia.
   - myelodysplastic syndrome.
2. Increased destruction of platelets :
   - Immune thrombocytopenic purpura (ITP).
   - Splenomegaly.
3. Inherited coagulopathies : Improper adhesion (Von Willebrand disease).
4. Drugs :
   - Antiplatelets (Aspirin, NSAIDS).
   - Anticoagulants (Heparin, Warfarin).
5. Infections :
   - Dengue viral hemorrhagic fever.

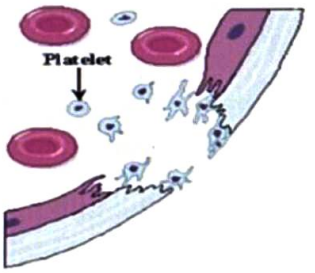

Primary Hemostasis: Platelets attach to the endothelium to for platelet plug

kumarankitindia1@gmail.com

Active space

Leave Feedba

6. Clotting factor abnormalities.

These patients can have bleeding from other muco cutaneous areas such as :
Petechaie (1-2 mm) and purpura (≥ 3 mm) and ecchymosis on skin, GI bleeding and gum bleeding, menorrhagia.

Primary hemostasis defect : The bleeding is always superficial.

Coagulation disorders leading to epistaxis 00:47:39

Coagulation casacde : Clotting factors are required.

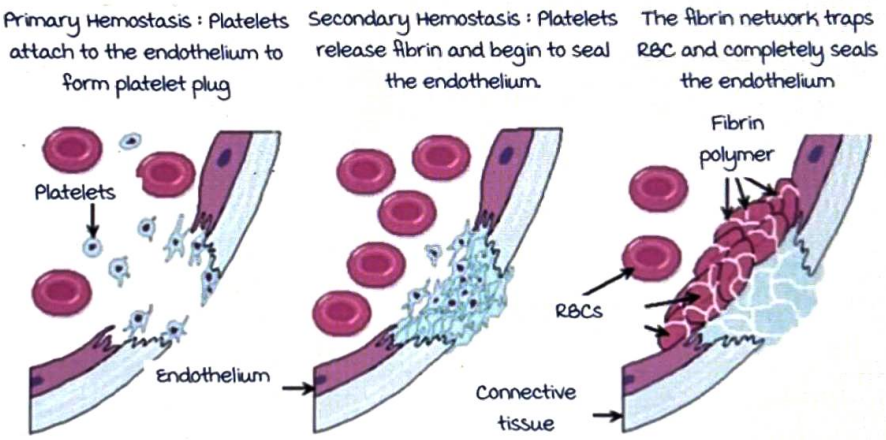

Clotting factor abnormalities :

Decreased production :

- Liver diseases.
- Vitamin K deficiency.
- Chronic alcoholics.
- Hemophilia A and B.
- Drugs : Heparin and Warfarin.

Secondary hemostasis disorders : Bleeding into muscles & joints.

Primary hemostasis disorders : Superficial (cutaneous/ mucocutaneous)

Active space
60c6b3eeaa8ded0e4e7e5ea7

Management of epistaxis 00:54:59

1st step : Hippocratic/ Trotter's method.
Pinch the nose tightly, bend forwards and breathe through the mouth.
If head is tilted up, blood flows into mouth and stopping of epistaxis acnnot be assessed.
Nasal decongesants can be given.
In severe bleeding we should establish IV access.
Next Step : If bleed is visible, cauterisation is done.

After Cauterization

Cauterization is done with :
1. Local silver nitrate.
2. Bipolar Cautery.

60c6b3eeaa8ded0e4e7e5ea7

Unipolar cautery should never be used.

Next Step : Anterior nasal pack (inconvenient for the patient).
Ribbon gauze is smeared with petroleum jelly.

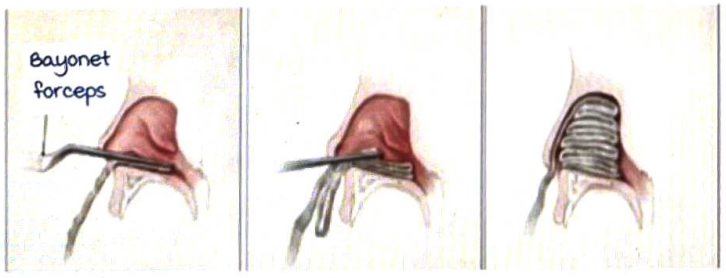

Anterior nasal pack is done in both the nostrils for pressure on septum.
Instrument used :
1. Tilley's nasal packing forceps :
It has serrated edges to hold on to the gauze.
2. Bayonet nasal forceps :
The bayonetting helps for visualisation during packing.

Active space

Leave Feedba

Tilley's forceps

Bayonet forceps

Instead of gauze merosel sponge (convenient) can be used.





merosel sponge

Next step : Posterior nasal packing.
Is done with Foley's catheter.
The catheter is inflated with air.

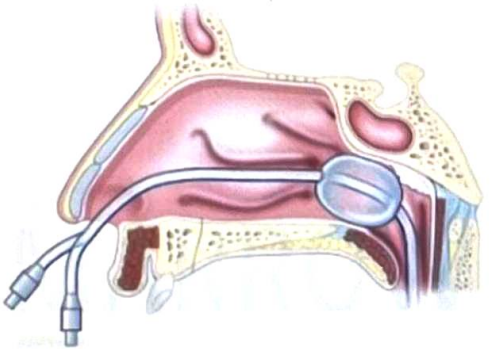

Whenever nasal packing is performed, patient must be admitted.
Pack is kept for 24 to 48 hours.
Antibiotic cover

Active space

Posterior nasal packing can also be done with help of an epistaxis balloon.

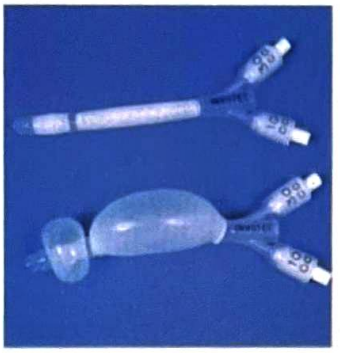

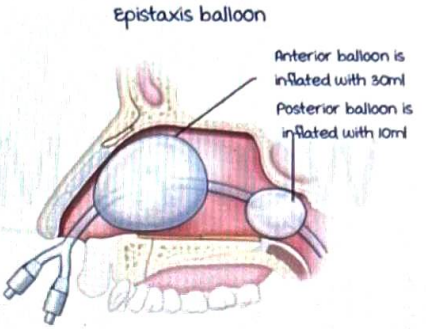

Final step : Ligation 01:04:12

Ligation done in the order of :

1. Sphenopalatine artery : At sphenopalatine foramen, 1 cm behind Inferior turbinate.

2. Maxillary artery :
   Caldwell-Luc's approach (sub-labial approach through maxillary antrum), ligated in the sphenopalatine fossa.

kumarankitindia1@gmail.com

3. External carotid artery :
   Ligated in the neck, above the superior thyroid branch to prevent retrograde systemic thrombosis.

4. Anterior and posterior ethmoidal :
   Only as an adjuvant to sphenopalatine artery.
   Lynch Howarth incision used.

Never ligate the internal carotid artery.

Hereditary hemorrhagic telangiectasia 01:11:28

Also Known as Osler Weber Rendu syndrome.

Active space

Leave Feedbac

Autosomal dominant condition.
Characteristic presence of multiple telangiectasias.
Present with approximately > 18 episodes of epistaxis/ month.
Involvement : Mucocutaneous/ visceral.

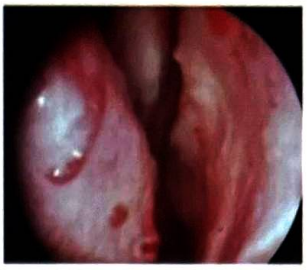

Telangiectasias

Management :
The management for epistaxis remains the same as given above.
Sometimes this may not suffice, so other treatments such as embolisation and septal dermoplasty can be done.
Septal dermoplasty : Nasal mucosa is replaced with skin flap.
Young's operation can be done. Also done for atrophic rhinitis.

60c6b3eeaa8ded0e4e7e5ea7

Active space

Leave Feedba

CLINICAL ANATOMY OF PNS AND RHINOSINUSISTIS

Anatomy of sinuses

00:00:42

Lateral outpouching from the lateral wall of nose.

Named according to the bone they grow into.

Enlarge and filled with air to lighten the skull.

Act as resonating chambers for voice.

Epithelial lining of sinuses is same as that of nasal cavity → Ciliated columnar pseudostratified.

4 paired sinuses are present.

Anterior group of sinuses : Frontal, anterior ethmoid and maxillary.

Posterior group of sinuses : Posterior ethmoid and sphenoid sinuses.

Maxillary sinus

00:03:40

Largest paranasal sinus.

Capacity : 15 ml.

Also called antrum of Highmore.

Earliest paranasal sinus to develop → Present at birth.

Shape is pyramidal.

Active space

Leave Feedba

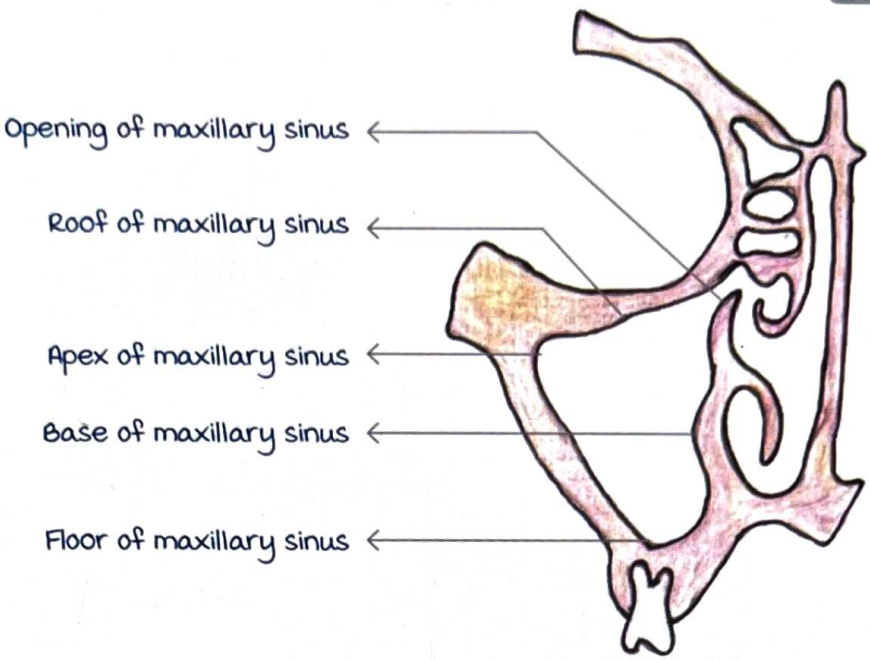

Apex : Towards the zygomatic bone.

Base : Lateral wall of nose.

Roof : Floor of orbit.

Floor is related to 2nd premolar and 1st molar teeth → oroantral fistula can occur if not extracted carefully.

Drainage is antigravity, hence predisposes to infection due to stagnation.

Meatus : Infundibulum (in between the uncinate process and lateral wall) of the middle meatus.

Maxillary sinusitis : Most common sinusitis in adults.

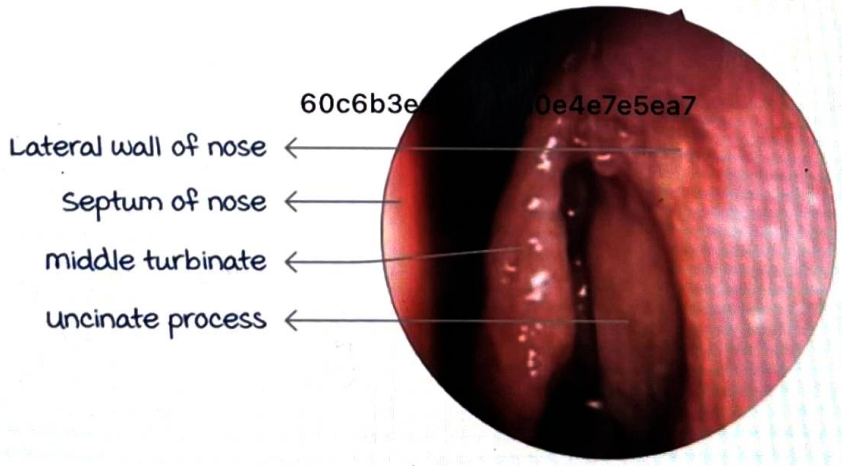

Removal of uncinate process (uncinectomy) : Maxiallary sinus can be approached.

Active space

Leave Feedback

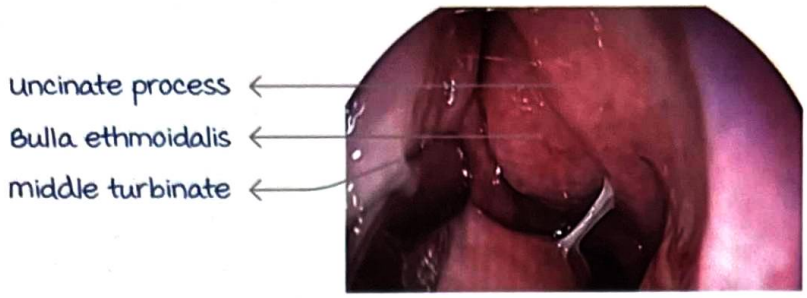

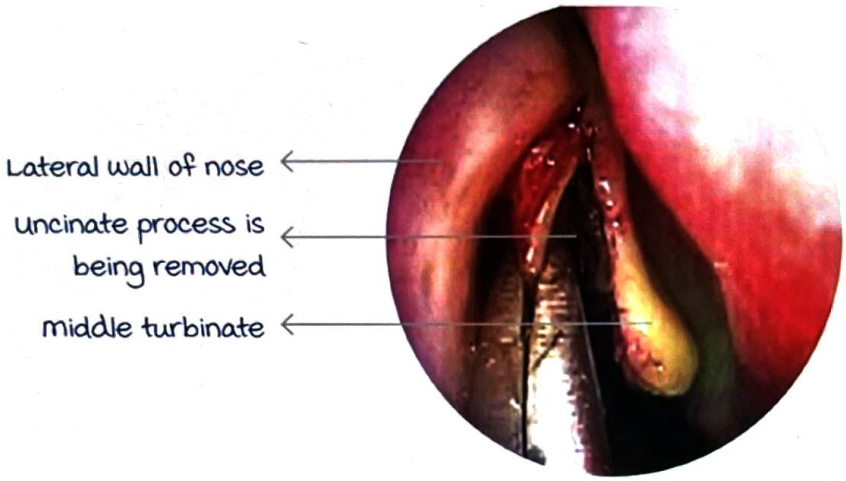

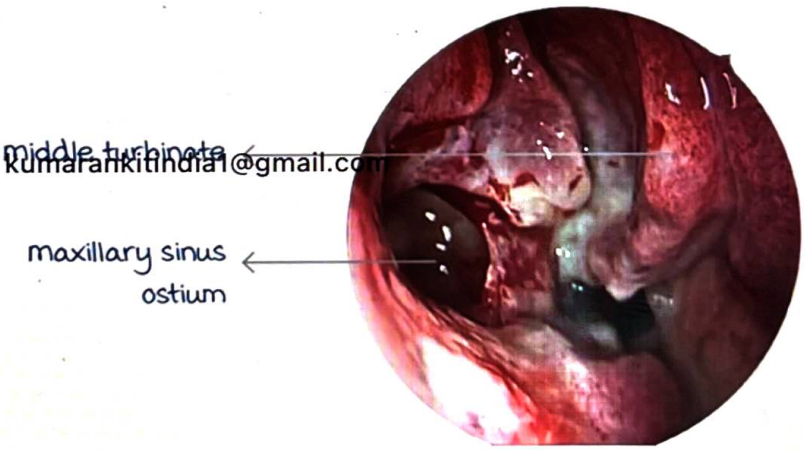

kumarankitindia1@gmail.com

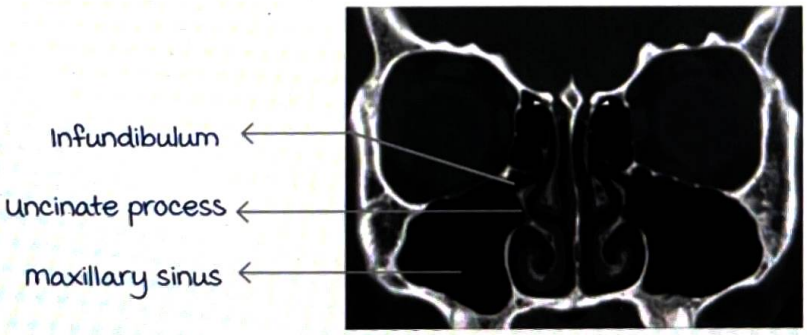

Active space

Leave Feedba

Ethmoid sinus

00:09:48

Outpouching to ethmoid bone.

Multiples groups of air cells.

Anterior ethmoid : Opens into middle meatal area.

Posterior ethmoid : Opens into superior meatus.

Present at birth.

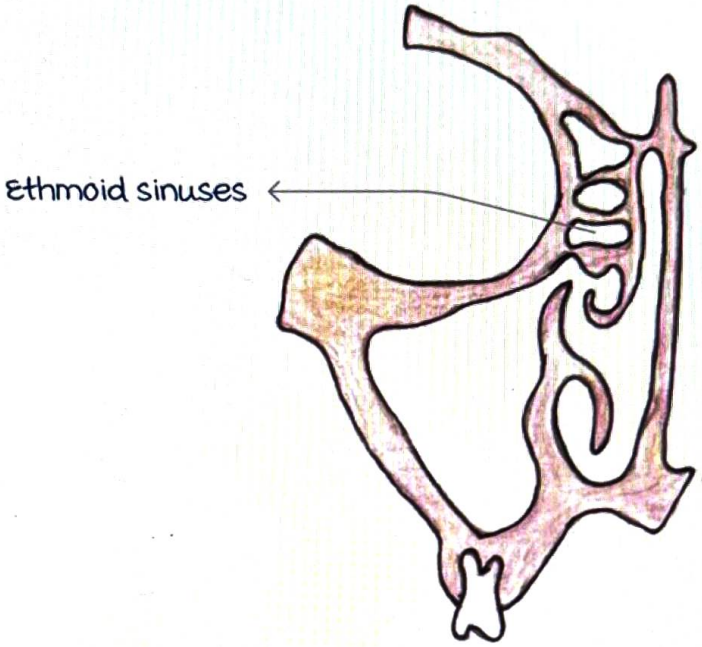

Develop after maxillary sinus development.

It is maximally pneumatized at birth as compared to maxillary sinus → Ethmoidal sinusitis is the most common sinusitis in children.

Lateral wall : medial wall of orbit (Lamina papyracea).

Pain of ethmoid sinusitis increases with eye movement.

Most common sinusitis causing orbital complications :

Ethmoid sinusitis. 60c6b3eeaa8ded0e4e7e5ea7

Most common complication caused by ethmoid sinusitis :

Orbital complications.

If the ethmoidal cells go beyond the boundaries of middle and superior meatus, they are named.

Anterior ethmoid cells can be present lateral or anterior to middle meatus.

Active space

Leave Feedback

- Bulla ethmoidalis : Largest.
- Agger nasi : Anterior most.
- Haller cell : In the floor of orbit/infraorbital/roof of maxillary sinus.

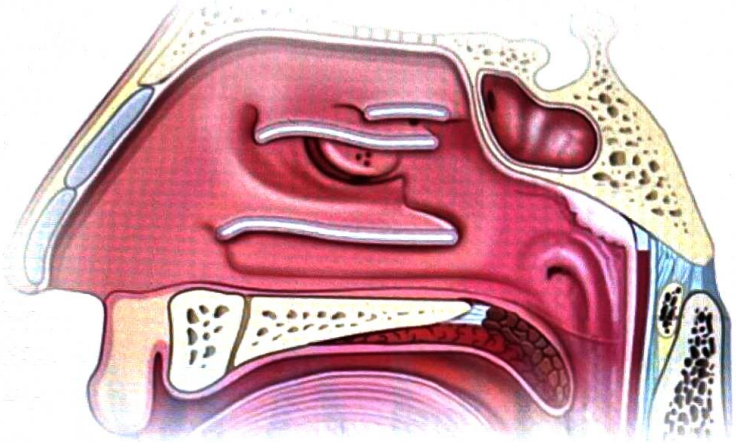

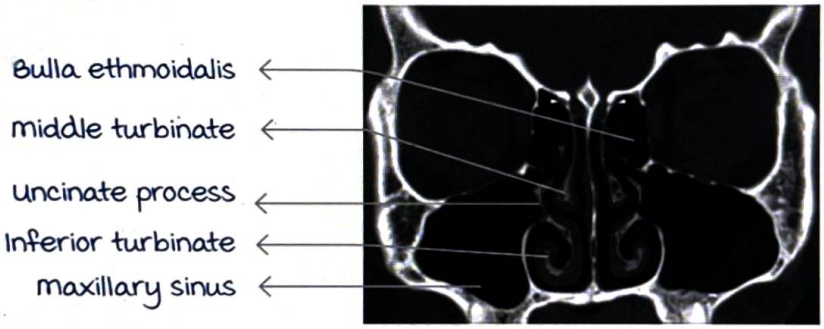

Haller cells :

Occupies the area of drainage of maxillary sinus.
Can cause the obstruction of drainage of maxillary sinus
→ can cause recurrent maxillary sinusitis.
More chance for injury to orbit in surgeries of the sinuses.

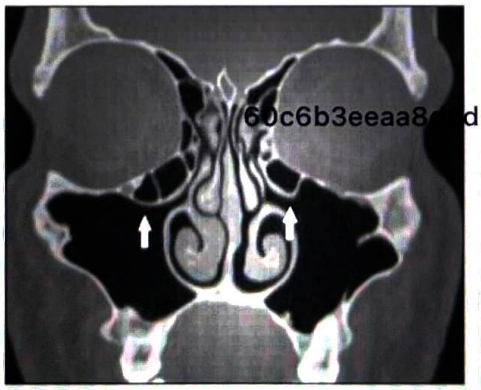

Infraorbital/Haller cells

Active space

Leave Feedbac

Agger nasi :

Anterior most anterior ethmoid cells.

Anterior to the anterior attachment of middle turbinate.

Frontal sinus drains into the anterior part of the middle meatus, via the frontal recess.

Presence of agger nasi blocks the frontal recess → recurrent frontal sinusitis.

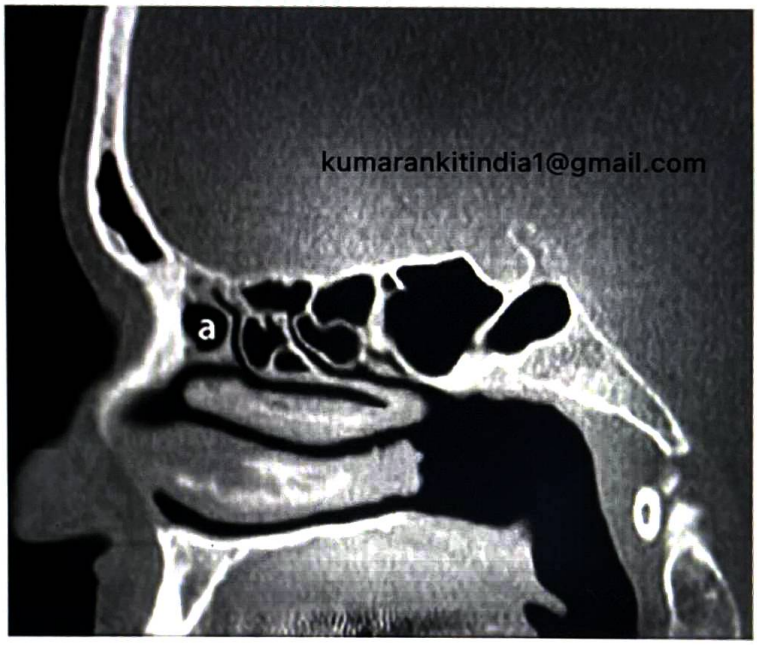

kumarankitindia1@gmail.com

Sagittal section : Agger nasi marked as 'a'

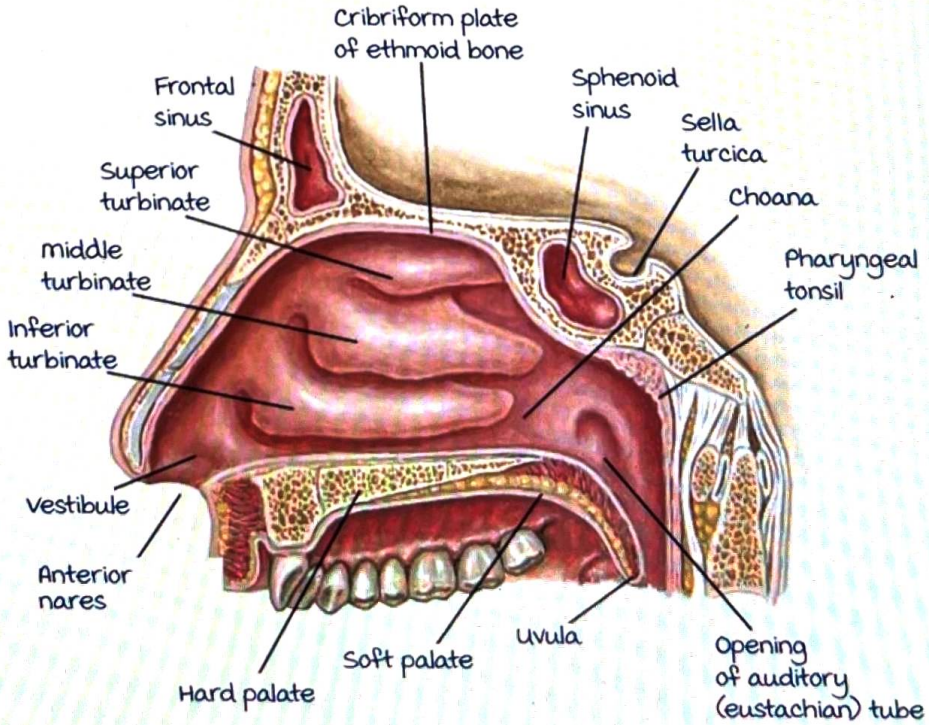

Active space

Leave Feedbac

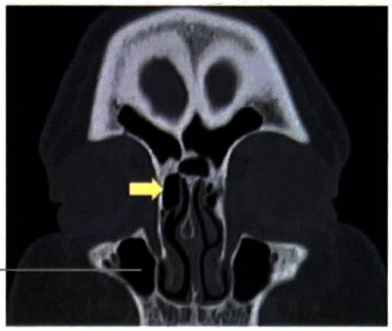

Coronal section : Agger nasi

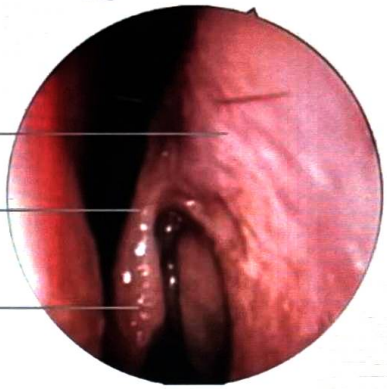

Posterior ethmoid cells

00:26:25

Open in the superior meatus.

Present at birth.

Can go around sphenoid sinus.

Part of posterior ethmoid sinus

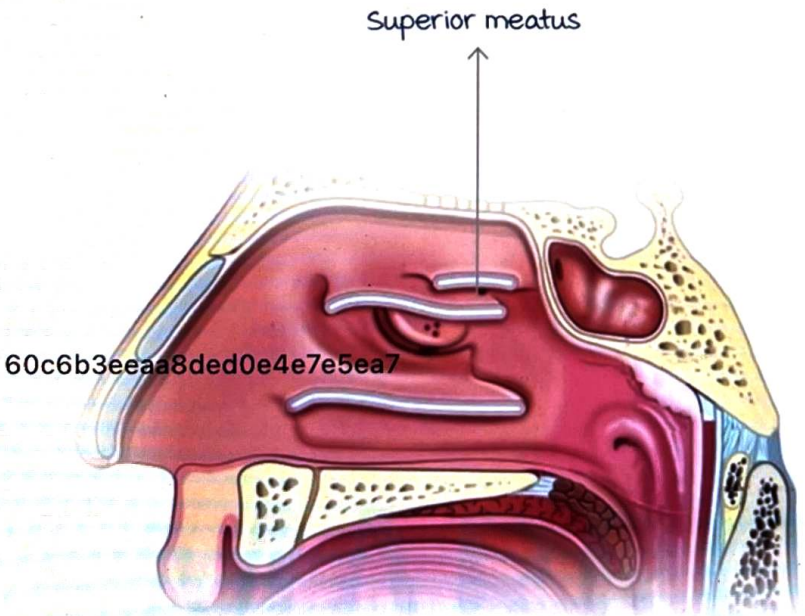

Relations of sphenoid sinus :

Located inside the body of sphenoid.

Active space

Leave Feedbac

Sella turcica is seen with pituitary gland superiorly.

Optic nerve passing through optic canal is seen in the roof of sphenoid sinus.

Cavernous sinuses seen laterally → contains the internal carotid artery.

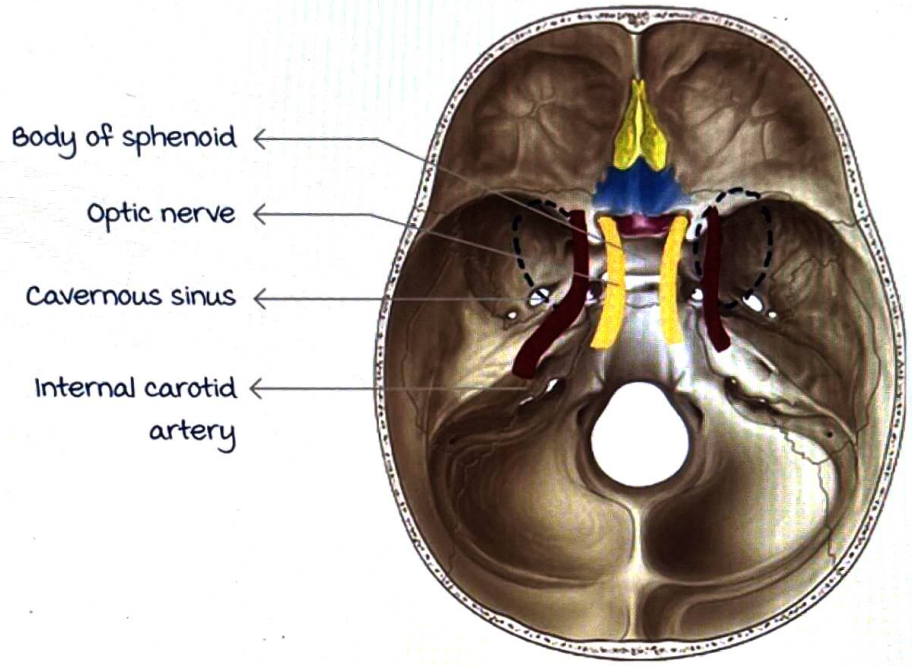

Relations of sphenoid sinus

Onodi cells : Enlarged posterior ethmoid air cells surrounding the sphenoid sinuses.

In relation to optic nerve, internal carotid artery.

During surgery, presence of onodi cells can cause injury to internal carotid artery.

Also known as spheno-ethmoid air cells.

60c6b3eeaa8ded0e4e7e5ea7

Active space

Leave Feedba

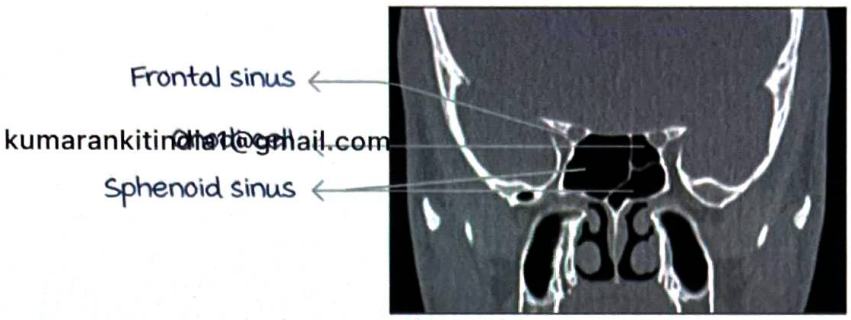

kumarankitindia1@gmail.com

Identification of sphenoid sinus in CT :

In sagittal view : Sella turcica seen behind sphenoid sinus.

In coronal view : Vertical septum separates the two sphenoid sinuses.

Horizontal septum in a sphenoid sinus demarcates the onodi cells.

Sphenoid sinus

00:39:53

Present in millimeter size at birth → not clinically significant.

Opens into spheno-ethmoidal recess → opens posterior to superior meatus.

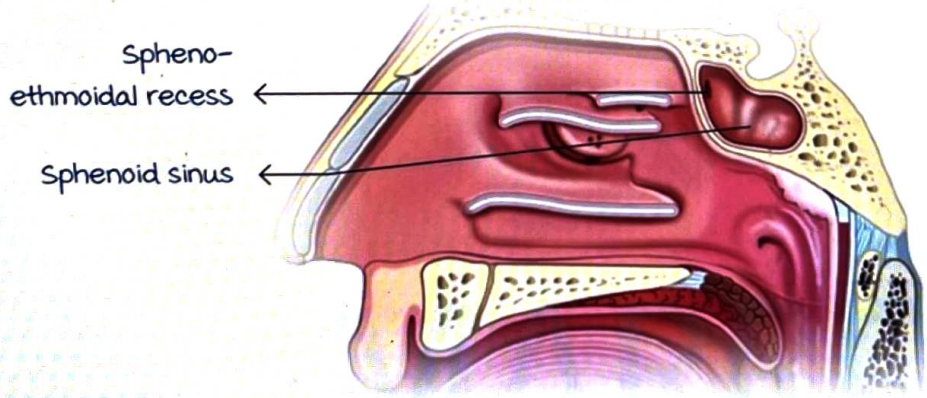

Present in body of sphenoid bone.

Least common sinusitis is sphenoid sinusitis.

Headache in sphenoid sinusitis is referred to occiput/vertex.

Relations :

Laterally → internal carotid artery.

Superiorly → Optic nerve and pituitary gland.

Active space

Leave Feedba

For hypophysectomy (surgical removal of pituitary gland) → Approached via the nose through the sphenoid sinus.

Pneumatization of sphenoid sinus should be adequate to approach the pituitary.

kumarankitindia1@gmail.com

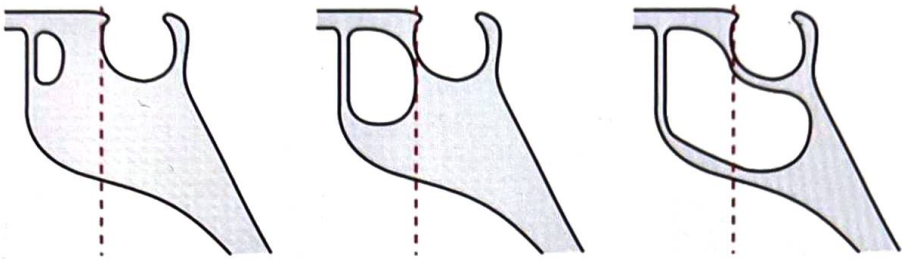

Types of sphenoid sinus : Conchal, Presellar and Sellar

According to pneumatization patterns, sphenoid sinus types are :

Conchal : Sphenoid is present like a small bowl.

Presellar : Ends before the sella turcica.

Sellar/post-sellar : Pneumatization extends beyond the sella turcica. Most common variety of pneumatization.

Thin wall separating the posterior wall of sphenoid and the brain.

Types of sphenoid sinus : Conchal, presellar and sellar.

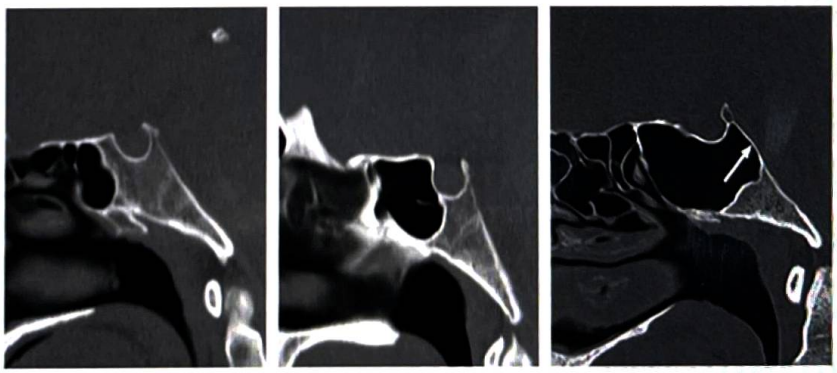

Conchal Presellar Sellar

Frontal sinus 00:46:43

Not present at birth.

Last to start and complete development.

Last to be viewed on X- ray → seen only by 6-8 years of

Active space

Leave Feedba

age.

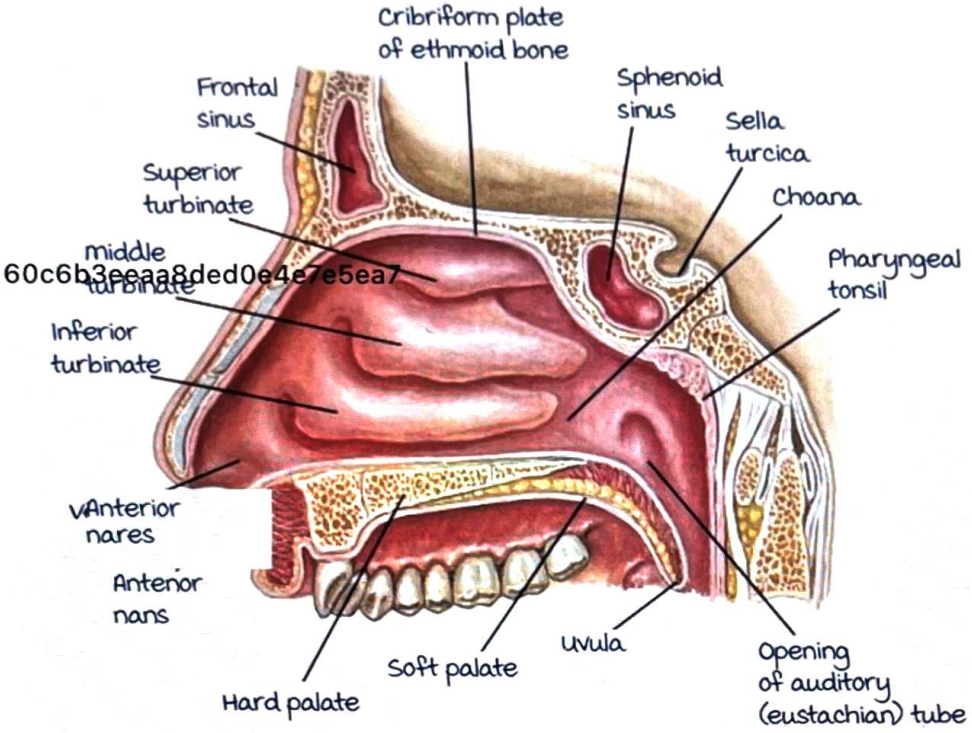

60c6b3eeaa8ded0e4e7e5ea7

Most anterior and superior sinus.

Drains into the middle meatus through frontal recess.

Drainage aided by gravity.

Headache caused by the frontal sinusitis → Office headache/early morning headache/periodic headache.

Headache decreases as the day progresses due to the emptying of the sinus because of gravity. Secretions collected while lying down.

Rhinosinusitis 00:52:58

Most common cause of sinusitis : Viral.

Most common bacterial cause : Streptococcus pneumoniae.

Clinical presentation :

- Nasal obstruction.
- Nasal discharge.
- Facial pain.
- Hyposmia.

Differentiation of affected sinus :

Pain with movement of eyes → Ethmoid sinusitis.

Active space

Leave Feedba

Pain radiating to occiput → Sphenoid sinusitis.

Early morning headache → Frontal sinusitis.

Diagnosis :

Anterior rhinoscopy shows :

Mucopurulent discharge in the middle meatus.

Congested nasal mucosa.

Anterior rhinoscopy

Bacterial infection :

Mucopurulent discharge and discolored discharge.

Unilateral discharge (localized).

Severe pain that is localized.

High fever.

Double sickening → Initial symptoms were mild which were resolving, then symptoms flare up, with increase in severity → Bacterial superinfection.

Management :

Antibiotics if the cause is bacterial.

Decongestants → Not for > 7 days.

> 12 weeks symptoms persist : Chronic sinusitis.

< 12 weeks symptoms : Acute sinusitis.

To assess the cause of chronic sinusitis → Endoscopic evaluation.

Nasal endoscopy : Definitive diagnosis of acute/chronic sinusitis.

Done under local anesthesia with anesthetic packs.

Rigid endoscopy usually done.

Active space

Leave Feedback

Rigid endoscopy

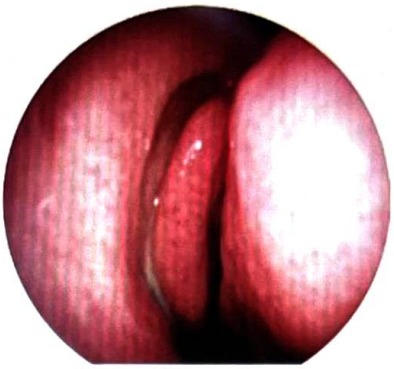

Mucopurulent discharge at middle meatus

kumarankitindia1@gmail.com

Best investigation for chronic sinusitis : NCCT.

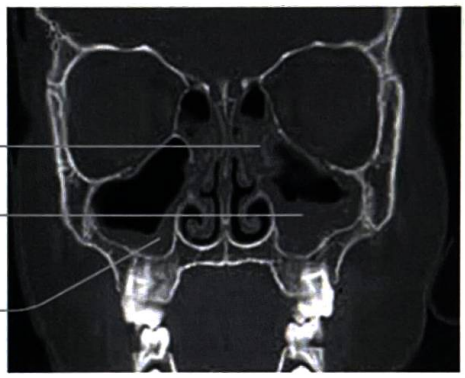

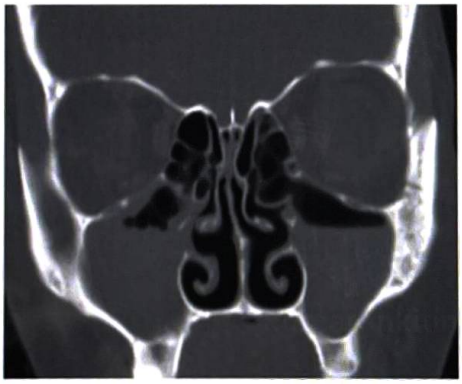

Maxillary sinus involvement

Management of chronic sinusitis 01:03:39

Medical management first.

Chronic sinusitis caused by mixed aerobic and anerobic organisms.

Most common aerobic microorganism : Staphylococcus.

Antibiotics against the microorganisms.

Active space

Leave Feedba

Decongestants.

Minimal infection and inflammation → Intranasal steroids to reduce the edema along with the antibiotic.

In case of no benefit (after 3 months)→ Osteomeatal complex must be opened by FESS.

FESS : Functional Endoscopic Sinus Surgery.

Restores the function of the sinus → Ventilation and drainage.

Mandatory NCCT to be taken before FESS.

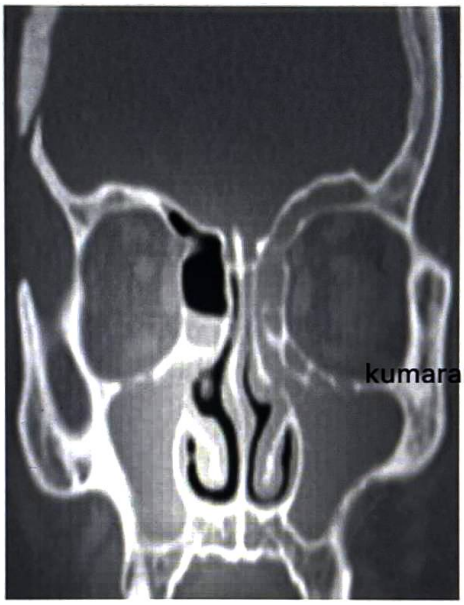

kumarankitindia1@gmail.com

Structures visualized during CT scan before FESS :

Mnemonic : CLOSE call before FESS.

Cribriform plate depth.

Lamina papyracea → Check for dehiscence or erosion.

Onodi cell.

Sphenoid sinuses.

Ethmoidal artery.

Keros classification of cribriform plates : (Type 1, 2, 3).

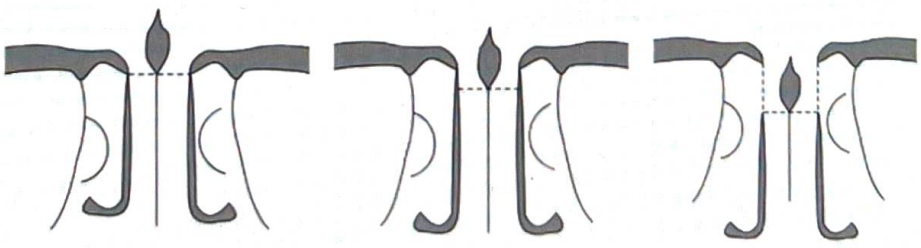

Olfactory fossa 1–3 mm

Olfactory fossa 4–7 mm

Olfactory fossa 8–16 mm

Active space

Leave Feedback

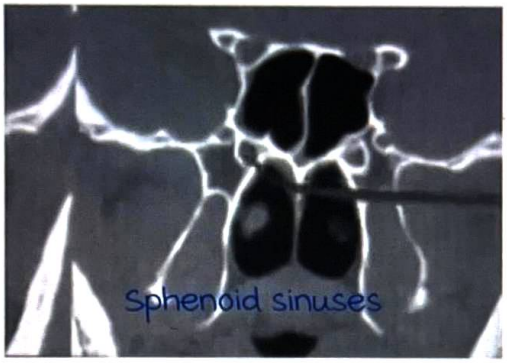

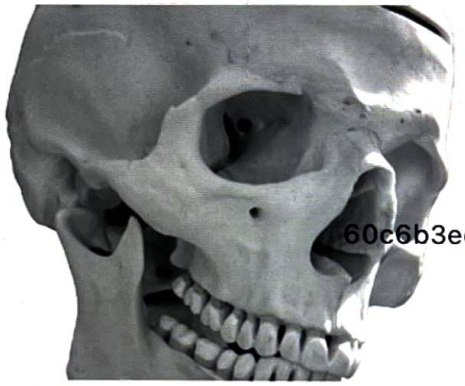

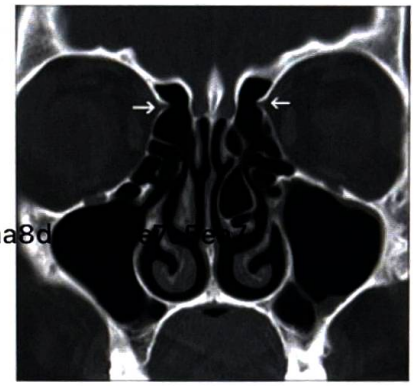

Nipple sign

Ethmoidal artery :

Branch of ophthalmic artery.

Ophthalmic artery gives anterior and posterior ethmoidal arteries in the eye, after entering the eye through the optic canal.

Anterior and posterior ethmoidal enter the nose via canals with the same names.

Anterior ethmoidal artery crosses to the nasal roof by passing through the ethmoid air cells.

From the roof, it comes down to the nasal septum to supply it.

Can be injured if the ethmoidal cells are diseased.

Anterior ethmoidal notch/nipple sign on CT : Notch produced by anterior ethmoidal artery while crossing to the nasal roof.

Injury to anterior ethmoidal artery causes orbital hematoma → emergency.

Blood around the orbit can cause optic nerve compression → blindness.

Active space

Leave Feedba

Orbital hematoma

FESS

01:15:04

First step of FESS/infundibulotomy : Uncinectomy with backbiting forceps.

Uncinectomy

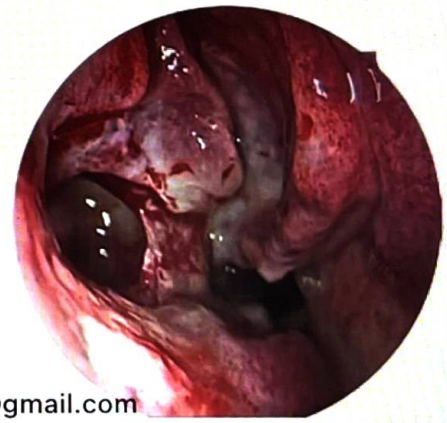

Maxillary sinus ostium widened

arankitindia1@gmail.com

Synechiae formation

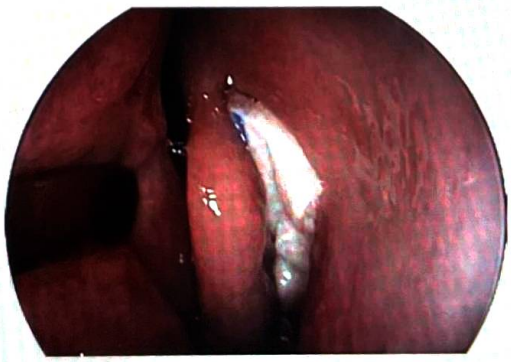

Mitomycin C packs

Active space

Leave Feedback

Complication of FESS : Synechiae formation.

Raw areas in lateral wall and middle turbinate.

Mitomycin C impregnated packs placed after FESS to reduce the incidence of synechiae.

Complications of FESS :

Most common is hemorrhage.

Injury to : (Mnemonic : CLOSE.)

Cribriform plate.

Lamina papyracea.

Onodi cell → optic nerve and internal carotid artery.

Sphenoid sinus → optic nerve and internal carotid artery.

Ethmoidal artery → orbital hematoma.

Most dreaded complication : Injury to internal carotid artery.

Endoscopic surgery of the nose : When it is endoscopic surgery other than for sinuses.

Nasal conditions	Non-nasal conditions
Septoplasty. Turbinate reduction. Ligating sphenopalatine artery. Choanal atresia. Tumors of the nose.	Lacrimal sac for endoscopic DCR. Orbit → Orbital hematoma, orbital abscess. CSF leak repair in cribriform plate fracture. Transnasal hypophysectomy via the sphenoid bone.

kumarankitindia1@gmail.com

Caldwell Luc approach to maxillary sinus :
Before the advent of endoscope, used for the treatment of chronic maxillary sinusitis.

Current indications :

Active space

Leave Feedba

To reduce maxillary fractures.

Floor of orbit fractures.

To approach the sphenopalatine fossa → maxillary artery ligation.

Caldwell Luc approach

Pack inserted following Caldwell Luc approach is removed endoscopically from a nasoantral window created in the inferior meatus to prevent collection post surgery.

Most common complication :

Extensive facial swelling (most common).

Inferior orbital nerve injury.

Injury to teeth.

Oroantral fistula.

Caldwell Luc approach

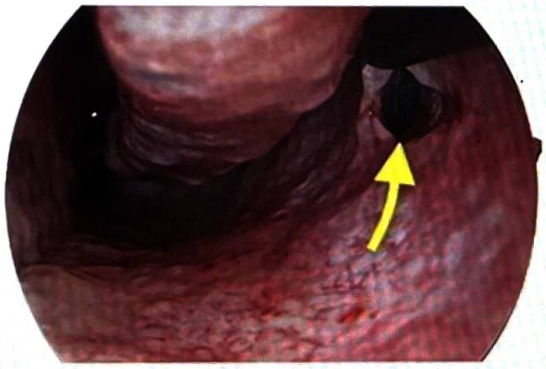

Nasoantral window in inferior meatus

Active space

60c6b3eeaa8ded0e4e7e5ea7

Leave Feedba

Antral puncture/proof puncture :

Surgery done in the past.

For chronic maxillary sinusitis.

Litzwitz antrum trocar and canula was used : very sharp canula.

Inserted through the inferior meatus.

Fluid passed through the cannula.

The collections in the maxillary sinus was flushed out → Could be sent for microscopic evaluation.

Both diagnostic and therapeutic.

Complication : Air embolism.

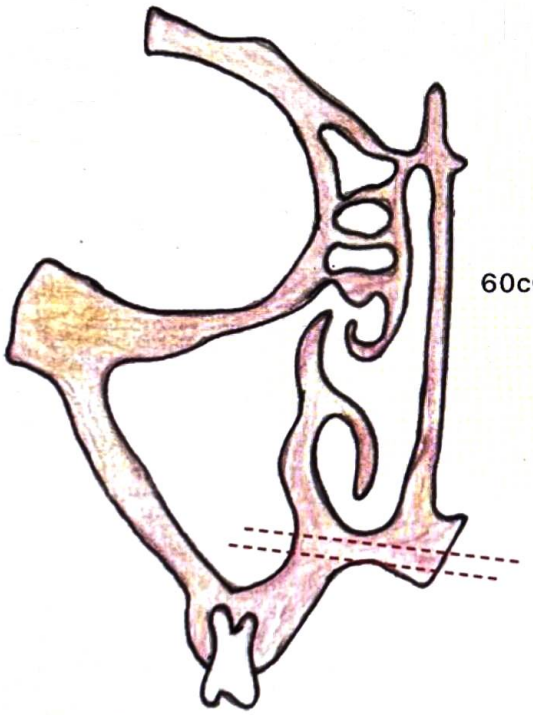

60c6b3eeaa8ded0e4e7e5ea7

Litzwitz trocar and canula

Active space

Leave Feedba

COMPLICATIONS OF SINUSITIS

Complications of sinusitis can be divided into acute and chronic complications.

Acute Complications

00:00:50

- Orbital complication.
- Osteomyelitis.
- Intracranial.

The most common acute complication : Orbital complication (most commonly due to ethmoid sinusitis).
Ethmoid sinusitis is more commonly seen in children.
Therefore acute complications are more commonly seen in children.

60c6b3eeaa8ded0e4e7e5ea7

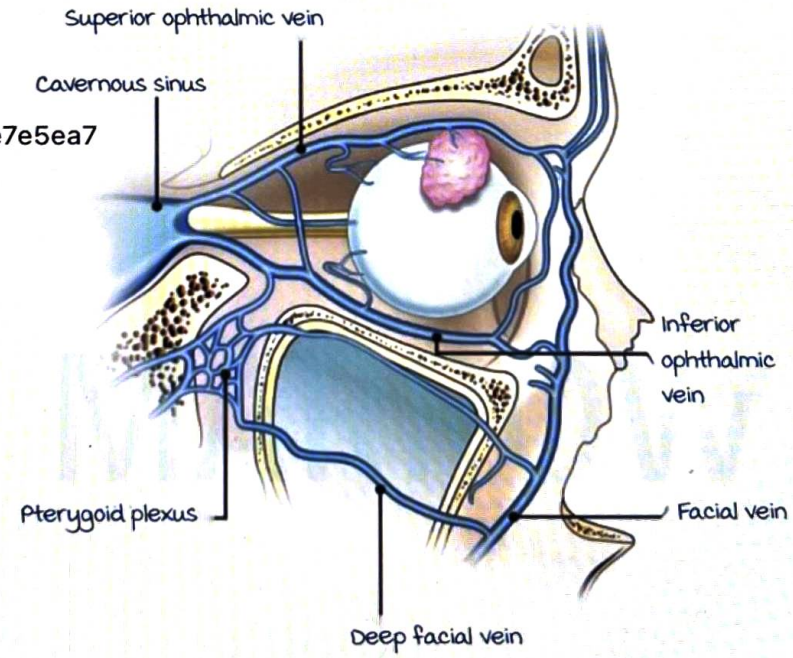

Active space

The infections spread from the sinus to the orbit via Lamina papyracea or via the venous drainage route.

The superior and inferior ophthalmic veins drain the ethmoid sinus and the orbit, these veins then drain into the cavernous sinus. This can result in cavernous sinus thrombosis.

Chandler Stages :

Based on the progression of infection from the ethmoid to the cavernous sinus via the orbit.

Stage 1 : Pre-septal cellulitis : Eyelid edema with normal appearing eye.

Stage 2 : Orbital cellulitis.

Stage 3 : Subperiosteal abscess.

Stage 4 : Orbital abscess.

Stage 5 : Cavernous sinus thrombosis.

Ethmoid sinusitis can directly cause cavernous sinus thrombosis without orbital cellulitis.

Danger area of face :

In this triangle the facial veins, through the deep facial vein, communicate with the pterygoid plexus which inturn communicates with the cavernous sinus.

The presentation of orbital cellulitis and cavernous sinus thrombosis is very similar. This is because the cranial nerves 3,4,6 are involved in both cavernous sinus thrombosis and orbital cellulitis.

60c6b3eeaa8ded0e4e7e5ea7

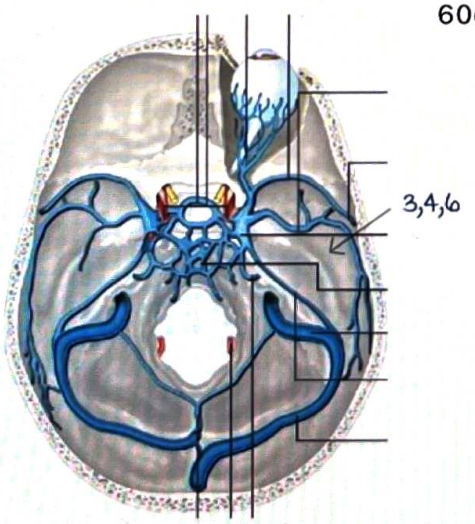

Danger area of face

Active space

Leave Feedba

Differentiating cavernous sinus thrombosis from orbital cellulitis :

	Orbital cellulitis	Cavernous Sinus Thrombosis
Onset	Slow onset.	Acute presentation, abrupt onset.
Nerve involvement	CN 3, 4 and 6 involved.	CN 3, 4 and 6 involved. The earliest nerve to be involved is the 6th nerve (6th nerve passes through the cavernous sinus).
Trigeminal paresthesia	Absent.	Present.
Unilateral or Bilateral	Always unilateral.	Starts unilateral and progresses to bilateral.

Unilateral orbital symptoms (chemosis, proptosis) with lateral rectus palsy of the other eye : Diagnosis is Cavernous sinus thrombosis.
(lateral rectus palsy is due to CN 6 involvement).

Cavernous Sinus Thrombosis

Orbital Cellulitis

kumarankitindia1@gmail.com

Superior orbital fissure syndrome :
When the complication involves the superior orbital fissure, then the ophthalmic branch of 5th CN along with CN 3, 4 & 6 are involved.

Orbital apex syndrome :
It is the same as superior orbital fissure syndrome but along with optic nerve involvement.

Active space

Osteomyelitis

00:12:00

Can involve frontal or maxillary sinus.
In children : maxillary osteomyelitis is more common than frontal because frontal sinus is the last to develop.
In adults : Frontal osteomyelitis is more common.

most common overall : Frontal osteomyelitis.

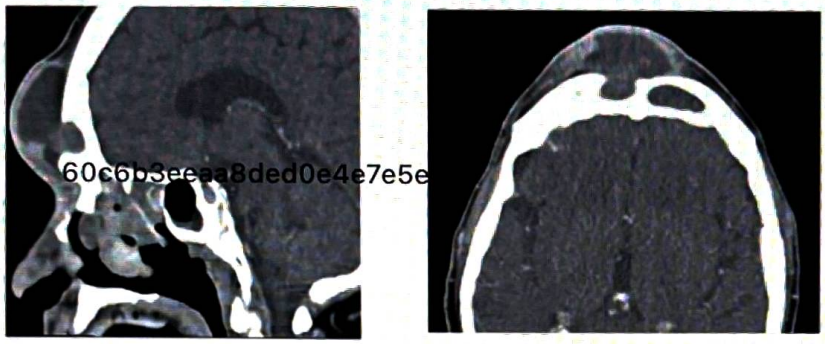

Sub periosteal abscess
in frontal osteomyelitis

Frontal osteomyelitis appears like a subperiosteal abscess which clincally appears like a soft doughy swelling on the forehead. This is known as Pott's Puffy Tumor.

The displacement of the eye signifies the pathology arising from the frontal sinus or the ethmoid sinus.
Frontal : Lateral and downward displacement.
Ethmoid : Lateral displacement.

Lynch Howarth incision

Pott's puffy tumor

Management :
Trephination of frontal sinus :
Draining of the frontal subperiosteal abscess via a Lynch Howarth incision.

Active space

Leave Feedbac

Intracranial complications 00:15:51

Most commonly occurring due to : Frontal sinusitis.
Extradural abscess → Subdural → Meningitis → Frontal lobe brain abscess → Cavernous sinus thrombosis.
It needn't be necessary for the infection to follow the above sequence in all cases.

Most common intracranial complication : Subdural abscess > Frontal lobe abscess.
Frontal lobe abscess presents with personality changes.

Chronic Complications :

- Mucocele.
- Pyocele.

Frontal sinus is more commonly involved resulting in downward and lateral displacement of the eye.

This is because the frontal sinus drains into the middle meatus via the frontal recess (fronto nasal duct). Due to the infection of the sinus, the frontal recess gets blocked due to edema.
This can cause collection of secretion in the frontal sinus even after antibiotic treatment and results in mucocele formation. The mucocele can get infected to form pyocele.

Management of Acute / Chronic sinusitis :
Radiological investigations like CECT and MRI are used to confirm the diagnosis.

The first approach is medical management.

Surgical management is done when :

- No response to medical management.
- Abscess is formed.
- Optic nerve compression.

Active space

X-Rays of nose and paranasal sinuses 00:23:48

60c6b3eeaa8ded0e4e7e5ea7

Water's view :
Occipito-mental view / Nose chin view :
Nose and the chin are close to the X-Ray plate with the mouth closed.

The maxillary sinus, anterior ethmoid sinus and frontal sinuses are seen in this view.

Best viewed sinus : maxillary sinus.

Pierre's view / Water's view with the mouth open :

This view helps visualize sphenoid sinus. Posterior ethmoid is not visible in this view.

Water's view

Pierre's view

Nose-chin position

Lateral view :

kumarankitindia1@gmail.com

Frontal sinus appears as the superior- most sinus.

All the sinuses are visible in the lateral view.

Caldwell view / Occipito-frontal view / Nose forehead position :

Occipito-Frontal view. The X-Rays are projected from the occiput to the frontal region. The nose and forehead is in touch with the Xray plate.

Best view for frontal sinus.

Lateral view

Active space

Leave Feedba

Frontal sinusitis presents with early morning headache / office headache.

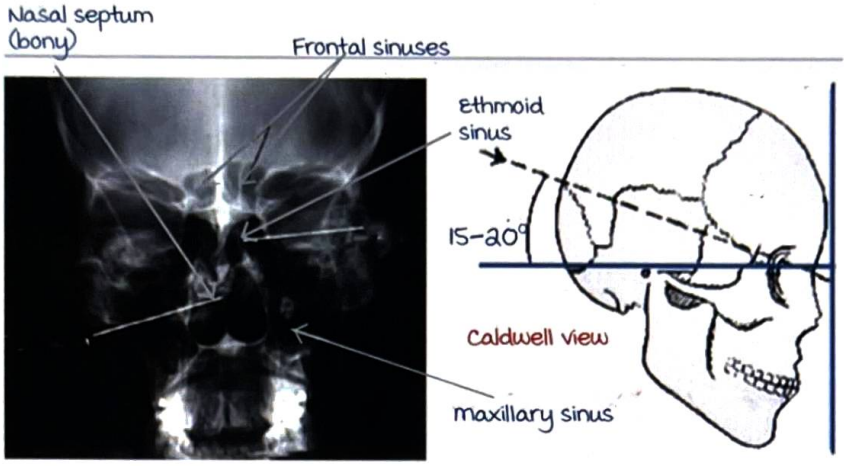

Caldwell view

The lower border of the mandibles :
Water's view : Inverted U shape.
Caldwell's view : Straight.

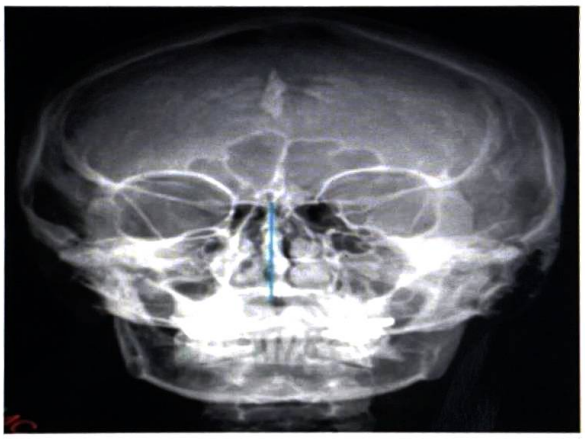

Caldwell's view

60c6b3ee

Water's view

Active space

NASAL POLYPS

Nasal polyp 00:00:48

They are polypoidal nasal mucosa which occurs because of edema of nasal mucosa.
Edematous nasal mucosa outpouches as polyps.
Usually formed from middle meatus.
can occur due to allergy or infection (due to underlying chronic conditions).

Infection or allergy.
↓
Edema in middle meatal area.
↓
Nasal narrrowing.
↓
Increased velocity.
↓
Negative pressure.
↓
Pulling of mucosa of sinuses into pathway of air.

Mechanism of polyp formation :

Occurs in accordance with Bernouli's theorem.
Odema of middle meatus.
60c6b3eeaa8ded0e4e7e5ea7
↓
osteomeatal complex block.
↓
Features of chronic sinusitis.
↓
On prolongd periods,lead to polyps.

Hence nasal polyps are now known as Chronic rhinosinusitis with nasal polyposis.

Active space

Leave Feedba

Types of polyps :

Bilateral nasal polyps in adults :

1. Allergic rhinitis :

   most common cause of B/L polyp, History of allergy present, IgE levels are raised.

Management :

- Anti allergens.
- Decongestants :

  For a maximum of 7 days.

  Long term therapy leads to Rhinitis medicamentosa.
- Steroid nasal spray.
- If medical management fails, FESS is done :

  In FESS, Patient is relieved of the symptoms :

  Nasal obstruction.

  Hyponasal voice : Rhinolalia clausa.
- Medical management to be continued even after surgery.
- Chance of recurrence of polyp is high.

Aspirin hypersensitivity

00:14:03

60c6b3eeaa8ded0e4e7e5ea7

2. Aspirin hypersensitivity :

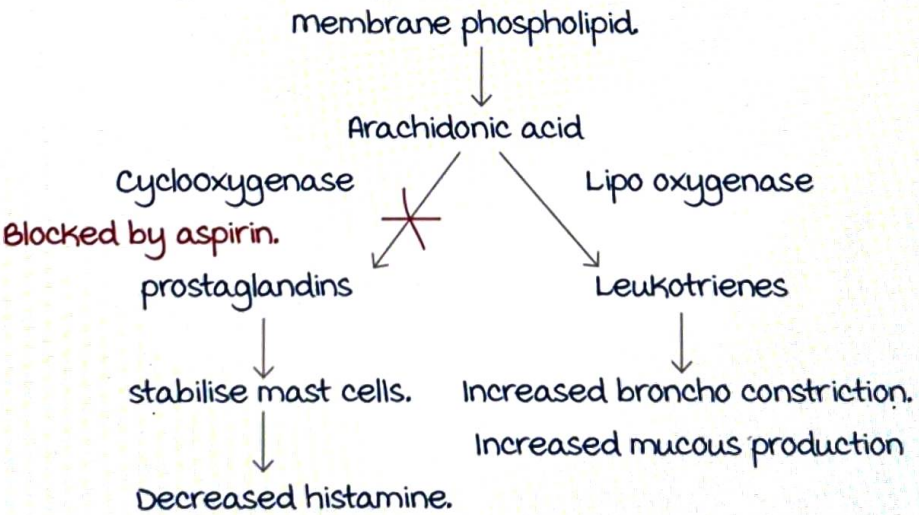

Aspirin blocks cyclo oxygenase pathway resulting in increased production of leukotrienes.

Decreased prostaglandins ⟶ mast cells unstable ⟶ Raised histamine ⟶ Increased vascular permeability ⟶ Edema in the middle meatal area ⟶ Polyp formation.

Increased leukotrienes ⟶ Bronchoconstriction ⟶ Increased mucosal secretions → Asthma.

Samter's triad : Aspirin hypersensitivity + nasal polyps +

Active space

Leave Feedba

asthma.

Management :

- Stop / avoid Aspirin.
- Desensitization.
- FESS.

3. Eosinophilic granulomatous with polyangitis :

Also known as Churg Strauss syndrome.

Auto immune condition.

Inflammation of small & medium blood vessels.

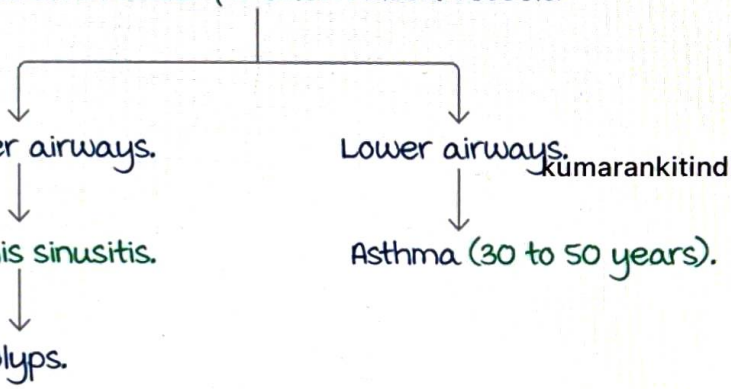

kumarankitindia1@gmail.com

Generalised systemic involvement.

- Peripheral neuropathy.
- Heart involvement (myocarditis).
- Renal & GI involvement.

Blood picture : >10% eosinophils.

Diagnosis :

- Biopsy : Eosinophilic granulomas.

Management :

- Steroids.
- Cyclophosphamide.

4. Young's syndrome :

Rare inherited condition.

Triad of :

- Chronic sinusitis (with/ without polyp).
- Bronchiectasis.
- Infertility (Azoospermia).

multiple pale grape like masses.

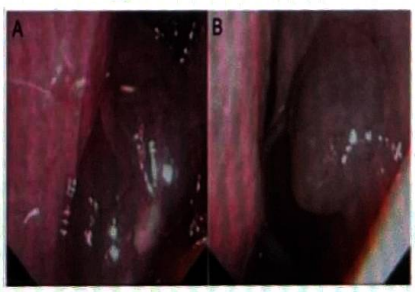

Active space

Leave Feedbac

Non contrast CT (NCCT) scan :

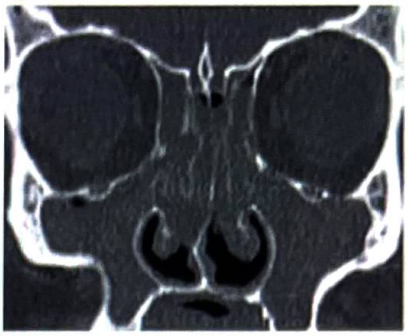

Bilateral nasal polyp with involvement of sinuses.

Bilateral nasal polyp in children

00:30:08

1. Cystic fibrosis :

It is an Autosomal Recessive condition. Mutation on the chromosome 7.

Leads to abnormal chloride conduction.

Also known as mucovicidosis.

Investigation :

Sweat chloride test :

- Sweat chloride level > 70 meq/l.

60c6b3eeaa8ded0e4e7e5ea7

Management:

- Functional Endoscopic Sinus Surgery (FESS).

2. Primary ciliary dyskinesia : Autosomal Recessive condition.

Kartagener's syndrome :

- Chronic sinusitis.
- Bronchiectasis.
- Dextrocardia (situs inversus).

Bilateral nasal polyp in children.

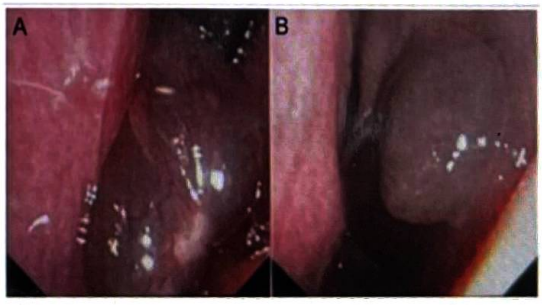

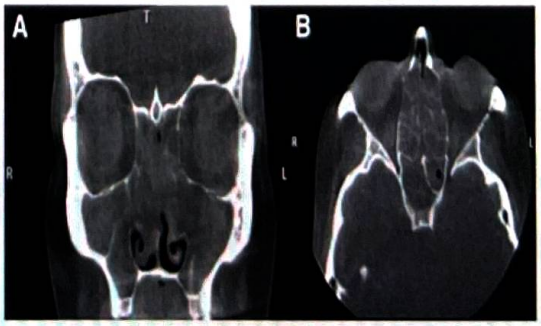

Active space

Leave Feedba

Unilateral nasal polyps in adults 00:37:34

Localised infections are the cause :

1. Bacterial infections :

Chronic bacterial sinusitis.

60c6b3eeaa8ded0e4e7e5ea7

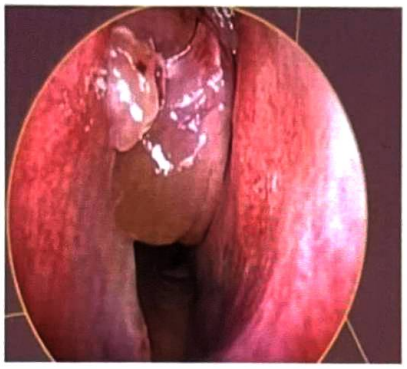

Management :

Medical :

- Antibiotics.
- Decongestants.
- Steroids.

If no benefit after 1 month of medical therapy, surgical management (FESS) is preferred.

2. Fungal infections :

Allergic fungal sinusitis :

Localised allergic reaction to the inhaled fungus.

History of atopy is present.

Raised IgE levels.

Secretions mucinous in nature.

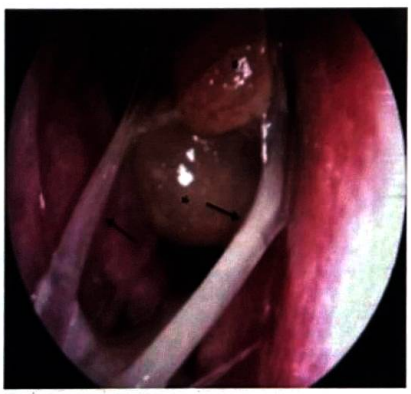

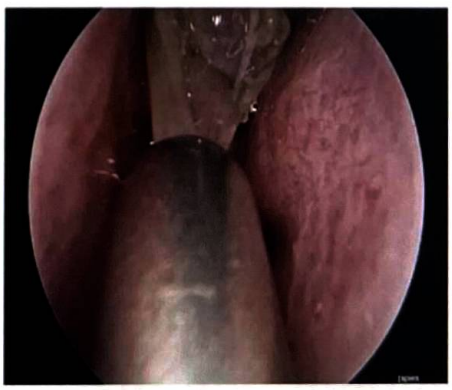

On pulling up : String like consistency.

Active space

Leave Feedba

Double density sign :
Also known as Rail track appearance.
Entraps metals like calcium, manganese and iron resulting in heterogenous appearance.

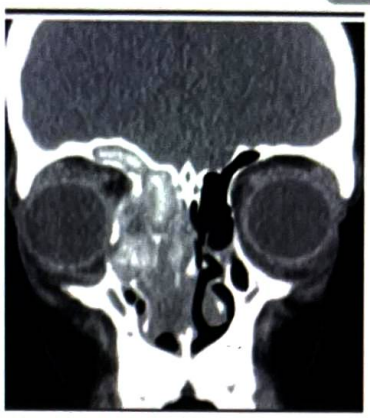

Bent and Kuhn diagnostic criteria of allergic fungal rhinosinusitis :

Major criteria :

1. Raised IgE level.
2. Nasal polyps.
3. Mucinous discharge (increased eosinophils).
4. CT finding : Double density/ heterogenous appearance.
5. Fungal smear positive.

kumarankitindia1@gmail.com

Management of allergic fungal sinusitis :

Definite management :

- FESS.
- Post operative nasal steroid spray (to reduce edema).
- No role of antifungals.
- Antifungals only preferred if response to FESS is not good.
- Itraconazole is the preferred drug.

Unilateral nasal polyp in young

00:53:46

1. Antrochoanal polyp :

localised infection obstructing the maxillary sinus ostia.
Leads to Polyp formation from maxillary antrum and moves to choana.

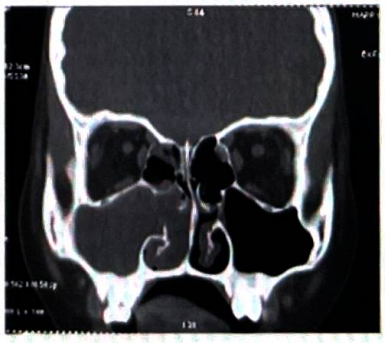

Active space

Leave Feedba

Hyponasal voice (Rhinolalia clausa).

Bilateral nasal obstruction.

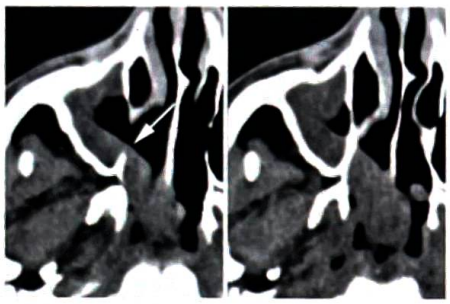

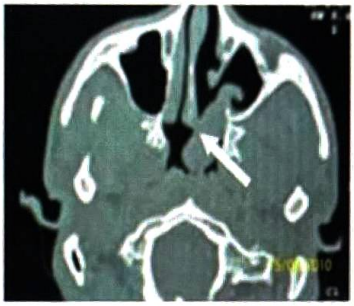

Management :

Medical management with antibiotics.

No role of steroids.

Definite management : FESS.

Summary

Q. A 35 year old male, with history of sneezing and raised IgE level

- Samter's triad?
  Ans : Asprin hypersensitivity.
- Adult onset asthma,
  > 10% eosinophils?
  Ans : Churg strauss syndrome.
- with infertility?
  Ans : Young's syndrome.

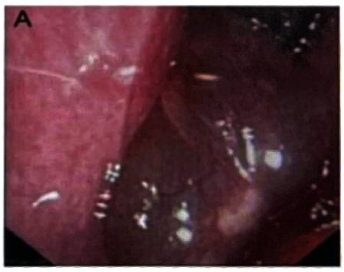

Unilateral multiple polyp in adult?

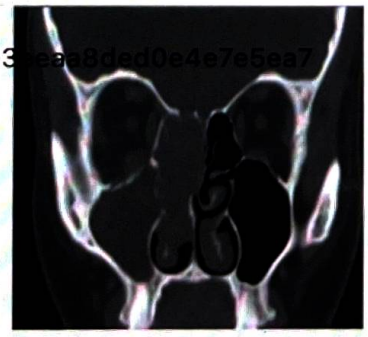

Chronic bacterial sinusitis.

Allergic fungal sinusitis

60c6b3[illegible]8ded0e4e7e5ea7

Active space

Leave Feedbac

Management of the situation :

FESS.

Post operative nasal steroids.

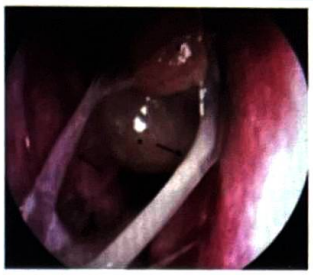

Antrochoanal polyp :

Earlier classification of polyps

00:59:58

Ethmoidal polyp :

- Bilateral.
- multiple.
- Associated with Allergy.

Antrochoanal polyp :

60c6b3eeaa8ded0e4e7e5ea7

- Unilateral.
- Infection.
- Arising from maxillary antrum.

Conditions mimicking polyps :

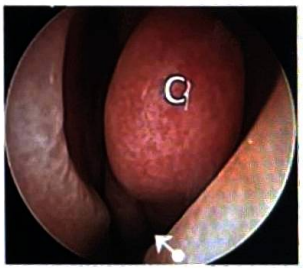

1. Concha Bullosa :

Pneumatised turbinate.

most commonly seen in middle turbinate.

Diagnosis confirmation by CT scan.

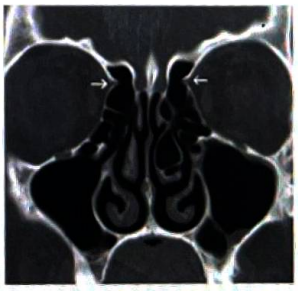

Probe test :

Used to differentiate polyp and turbinate.

Types	Polyps	Turbinates
Pass probe all around	Yes	No
Pain	No	Yes

Active space

Leave Feedba

Types	Polyps	Turbinates
Bleeds on touch	No	Yes

2. Meningocele or meningo encephalocele :

Always rule out in infants with polypoidal mass.

kumarankitindia1@gmail.com

Transillumination positive.

Furstenberg test positive : On increased intracranial pressure, the size of the lesion or polyp increases.

confirmation by MRI scan.

Biopsy is not done.

3. Malignancy :

Found in elderly.

Unilateral polypoidal mass in lateral wall of middle meatal area.

Rule out malignancy by biopsy.

meningoencephalocele

Active space

Leave Feedbac

FUNGAL SINUSITIS

Fungal sinusitis 00:02:55

Inhaled air contains fungus. It can come out in exhaled air or get entrapped in sinus. Response to the fungus depends on the immunity of the patient.

Immunocompetent/ non atopic patients : Fungal balls.

Atopic patients : Severe allergic response called allergic fungal sinusitis.

60c6b3eeaa8ded0e4e7e5ea7

Immunodeficient : Invasive fungal sinusitis.

Types :

Non invasive : Fungal balls, Allergic fungal sinusitis.

Invasive fungal sinusitis.

Fungal balls :

m/c organism : Aspergillus.

Seen in immunocompetent and non atopic patients.

C/F :

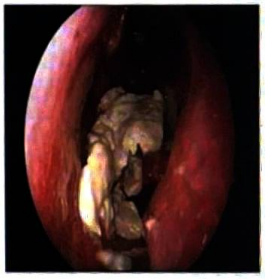

- Usually unilateral and rarely bilateral.
- Unilateral nasal obstruction.
- m/c sinus involved is maxillary.
- Fungus entraps metals like Iron,calcium, manganese.

O/E : Unilateral polyps.

Endoscopy : Cheesy clay like debris of fungal hyphae.

CT is diagnostic.

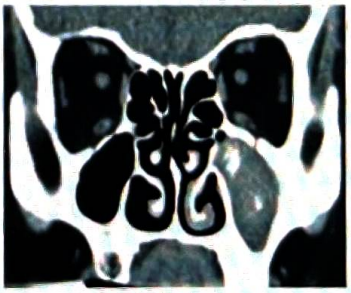

Heterogenous appearance in since the fungus traps metals like iron, calcium & manganese.

CT : Double density sign/ rail track appearance.

Management :

Functional endoscopic sinus surgery (FESS).

No need of antifungals.

Active space

Leave Feedba

Allergic fungal sinusitis

00:12:12

m/c organism : Dematacious - Curvalaris, bipolaris and alernaria.
Immunocompetent with atopic patients.

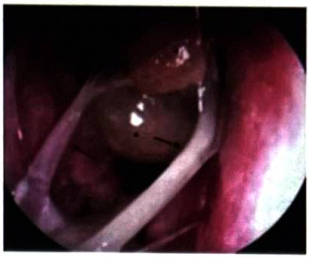

C/F :

- Unilateral.
- Nasal obstruction.
- Nasal discharge : mucinous (due to excess eosinophils in discharge).
- Facial pain.
- Hyposmia.
- Chronic sinusitis (block of ostemeatal complex).

60c6b3eeaa8ded0e4e7e5ea7

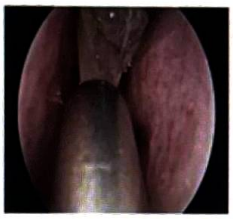

O/E : Nasal polyps (usually unilateral).
Peanut butter or axle grease appearance.

Endoscopy : Polyps with mucinous nasal discharge (thick and sticky).

On suction : Comes out like a string & is difficult to suction out.

CT : Heterogenous appearance i.e., double density sign (due to entrapment of metals). Aka Rail track or starry sky appearance.
m/c sinus involved : Ethmoid sinus.
Erosion (especially lamina papyracea) may be due to mucin (expansive in nature).

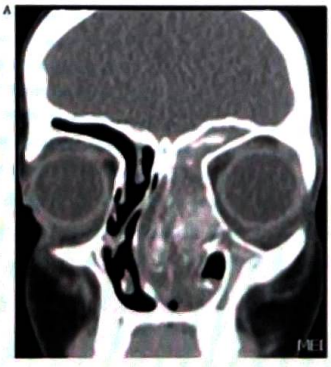

Active space

Leave Feedba

Bent and Kuhn diagnostic criteria :

Major criteria

- Ig E levels : raised.
- Nasal polyps.
- Eosinophilic mucin.
- On CT : Heterogenous appearance / double density sign.
- Positive fungal smear.

Minor criteria

- Asthma.
- Unilateral.
- Sr. Eosinophilia : Charcot leyden crystals present.
- On CT : Bone erosion.
- Positive fungal culture.

Management :

- Functional endoscopic sinus surgery (FESS).
- Post operatively : Steroids nasal spray (short course).
- Antifungals are not required.
- Required only if : Very severe disease and Not responding to surgery.
- Preferred antifungal : Iatroconazole.

kumarankitindia1@gmail.com

Invasive fungal sinusitis

00:23:44

Immunocompromised patients.

1. Invasive aspergillosis : By Aspergillus fumigatus.
2. Mucormycosis : By Rhizhopus & Mucor.

Pathogenesis :

Angioinvasive fungus
↓ (life threatening as rapidly spreading)
Thrombosis
↓
Ischemia
↓
Necrosis
↓
Black eschar.

Active space

High risk population :

- Poorly controlled diabetes : Ketone reductase, reduced chemotaxis & phagocytosis and iron dissociation.
- Steroid therapy : Unmasking of hyperglycemia.
- Elevated levels of free iron : Growth and multiplication.
- Treatment with desferoxamine : Iron uptake by fungus.
- Neutropenia or leukemia : Hematological malignancy (Bone marrow transplant or solid organ transplant).

On endoscopy :

Discoloured black necrotic areas : Black fungus.

Can invade : Intracranially, orbit, PNS, below to palate.

Spreads via intravascular route, perineural or direct spread.

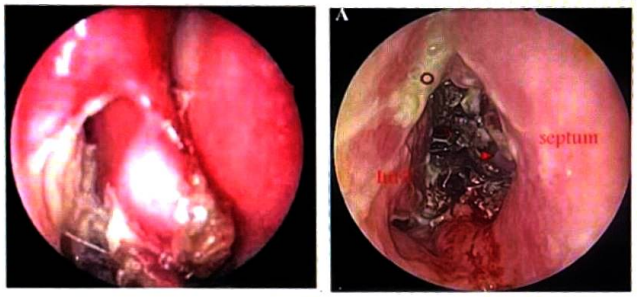

C/F :

60c6b3eeaa8ded0e4e7e5ea7

Orbit :

- Blurred vision.
- Proptosis.
- Chemosis.
- Ophthalmoplegia.

Intracranial symptoms :

- Head ache.
- Altered mental status.
- Cranial nerve palsies.
- Neurological deficits.

Active space

Leave Feedbac

- Seizures.
- Coma.
- Contralateral eye : Cavernous sinus thrombosis.

Palate :

- Loosening of teeth.
- Necrotic ulcers

CT : Features like sinusitis (i.e., mucosal thickenings, air fluid levels).

Confirmatory tests :

On microscopy : Ribbon like aseptate fungus branching at right angles.

HPE : Infarcts, angioinvasiveness and perineural invasion.

Treatment :

Medical management : Start immediate treatment without waiting on culture.

Liposomal Amphotericin B Intavenously 5 mg/kg/day.

In CNS involvement : IV liposomal Amphotericin B 7.5 mg/kg/day - 10mg/kg/day.

In invasive aspergillosis : Voriconazole.

60c6b3eeaa8ded0e4e7e5ea7

Step down/ salvage therapy : Isavuconazole & posaconazole.

Surgical debridement : Till clear bleeding margin (as all the necrotic areas act as nidus for fungal growth & also hampers immune cells & drugs to reach the site of infection).

Rapid reversal of underlying immunocompromised status.

Radiology : Serial CT.

Role :

- To know the extent of the disease.
- Response of the disease for treatment.

Prophylaxis : Not necessary in non contagious and in high risk patients.

Active space

Leave Feedbac

Myths associated with mucromycosis 00:39:51

No human to human transmission : Non contagious.
It is a opportunistic fungus (usually healthy are safe except for cutaneous type, can follow trauma).
Black fungus : Extensive angioinvasion – Vessel thrombosis and subsequent tissue necrosis.

Chronic invasive fungal sinusitis 00:41:35

Aka granulomatous fungal sinusitis.
Caused by Aspergillus fumigatus or Aspergillus flavus.
m/c seen in India, Pakistan, Saudi arabia.
Usually seen in immunocompetent people and sometimes in immunocompromised patients also.

C/F :
Slowly progressive over months.
Chronic sinusitis. which progresses to proptosis, mass in cheek.

Diagnosis : Biopsy.

Management :
- Surgical debridement.
- Antifungal : Voriconazole/ Iatroconazole.

kumarankitindia1@gmail.com

Active space

Leave Feedba

ATROPHIC RHINITIS AND GRANULOMATOUS CONDITIONS OF THE NOSE

Atrophic rhinitis/Ozena

00:01:30

Atrophy of the nasal tissues leading to bilateral wide, roomy nasal cavities.

Causes can be :

Secondary :

- Surgery : For example total turbinectomy leading to empty nose syndrome.
- Granulomatous conditions like TB, syphilis, leprosy etc.

Primary :

- Idiopathic.
- Atrophic rhinitis can be seen after an infection with Klebsiella ozaenae.
  Atrophic rhinitis is also called as ozaena.
- Hormonal imbalance can also cause atrophic rhinitis, this is seen in females during puberty.
  Atrophic rhinitis is most commonly seen in females.
- Estrogen deficiency.
- Nutritional deficiency.

Atrophic Rhinitis

Presentation :

- Bilateral nasal obstruction :
  This is due to dry air causing crusting of the nasal tissues.
- merciful anosmia : Secondary infection in the nasal cavities cause foul smelling discharge but due to crusting and destruction of the olfactory mucosa, the patient is unaware of the smell.

60c6b3eeaa8ded0e4e7e5ea7

Management :

- Removal of crust by nasal alkaline nasal douching.
  Alkaline solution : Distilled water with NaCl + $NaHCO_3$ + Na Biborate at 2 : 1 : 1.

Active space

Leave Feedba

- Kemicetine solution : To treat the local infection inside the nose.
- Kemicetine contains : Chloramphenicol, Oestradiol, Propylene glycol, Vit-D (COPD).
- 25% glucose in glycerin is also used for the proteolytic action of lactic acid derived from glucose.
- Closure of the nasal cavities to avoid large influx of air and crusting : Young's operation.

60c6b3eeaa8ded0e4e7e5ea7

Modified Young's surgery : A 3mm opening is left in the centre when bilateral nasal cavities are closed.

Granulomatous conditions should be suspected in patients of atrophic rhinitis.

Nasal douching

Rhinosporidiosis

00:18:24

Earlier was considered as a fungal infection.
Rhinosporidium seeberi, is considered as an aquatic protistan protozoa.
This organism is commonly found in the cattle dung and hence patient presents history of bathing in a water body shared by animals and endemic in south India.

The infection is not confined to the nose and nasopharynx. But the granulomas formed in the nasal cavity are very vascular, therefore cause excessive bleeding in the nasal cavity.

Infection can occur in all age groups, in immunocompetent patients and at any site on the body.

Active space

Leave Feedba

Presentation :

Patient complaints of recurrent epistaxis / blood tinged nasal discharge and on examination, red vascular mass with sporangia of the protozoa (white dots) on it appearing like a strawberry with white dots also called as mulberry mass.

Skin nodules can also be seen in these patients.

Hypertrophic turbinate is also known as mulberry turbinate.

Biopsy is not needed for diagnosis, sporangia can be detected on a nasal smear.

Sporangium filled with sporangiospores can be seen under micorscope.

kumarankitindia1@gmail.com

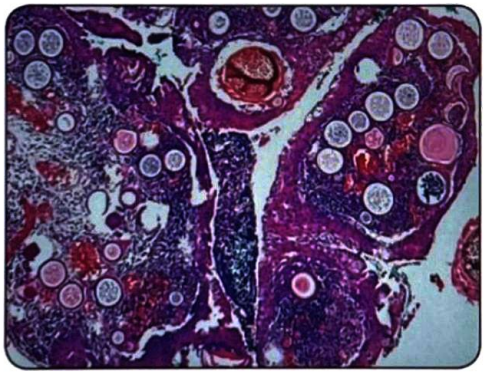

Skin nodules

Management :

Excision of mass : Wide excision with cauterization of base.

This is helps in preventing the sporangium from further invading the tissues during the surgery.

Dapsone is given post op to decrease the chance of recurrence.

Rhinoscleroma

00:30:28

This is a bacterial granuloma caused by :

Klebsiella rhinoscleromatis also known as Frisch Bacillus.

more common in North India.

Active space

Leave Feedbac

Presentation :

- Atrophic stage : Patient presents with crusts and atrophy of nasal cavity.
- Granuloma formation, the patient appears with hard nose/ woody nose/ Hebra nose.
- Cicatricial stage : Fibrosis has deformed the nose. (Tapir nose).

On biopsy : Mikulicz cells are seen (macrophages laden with phagocytosed bacteria are seen) and Russell bodies are seen (plasma cells with eosinophilic inclusion).

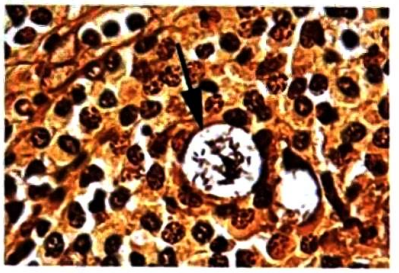

Mikulicz cells

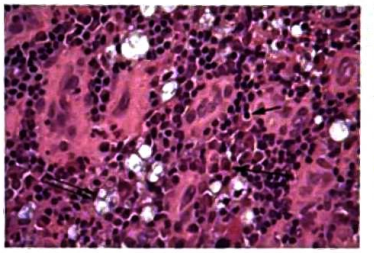

Mikulicz cells

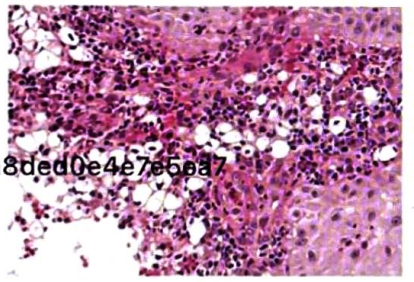

60c6b3eeaa8ded0e4e7e5ea7

Russell Bodies



Management :

- Streptomycin.
- Tetracycline.
- Rifampicin.
- Ciprofloxacin.
- Steroids : To reduce the fibrosis.

medication given for at least 6 weeks after which biopsy is taken.

medication is terminated when the culture is negative.

Active space

Leave Feedba

Granulomatosis with polyangiitis

00:39:28

Earlier known as Wegener's granulomatosis.

This disease involves :

- Upper respiratory system :
  Patient presents with blood tinged nasal discharge and nasal obstruction due to crusting.
  Around 80% of patients have nasal involvement.
  Nasal septal perforation can also be seen.
- Lower respiratory system : Hemoptysis, dyspnea; CT shows pulmonary infiltrates, pulmonary nodules.
- Renal system : RPGN, edema, hypertension, RBC casts.

All granulomatous conditions cause perforation of cartilaginous parts of the nasal cavity, but Wegener's granulomatosis and syphilis causes perforation of bony & cartilaginous parts of the nasal cavity. This can cause saddling of the nose.

60c6b3eeaa8ded0e4e7e5ea7

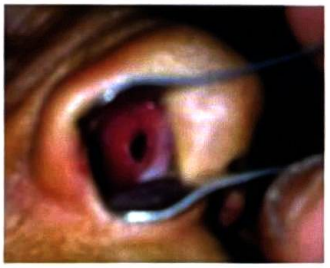

Diagnosis :

Done by c-ANCA. On biopsy, necrotizing granulomatous vasculitis is seen.

These patients rarely present with gingival hyperplasia.

Active space

Leave Feedbac

Strawberry gingival hyperplasia :

Strawberry gingival hyperplasia rare but pathognomic of granulomatosis with polyangitis.

kumarankitindia1@gmail.com

Management :

- Steroid.
- Cyclophosphamide.

Sarcoidosis

00:45:53

Nasal involvement is rare and seen in 1–4% of cases.

Patient complains of crusting, nasal obstruction, perforation of septum, blood tinged discharge, saddling of the nose and others.

Lupus Pernio : Violaceous affection of skin of nose and cheek is seen in patients of sarcoidosis.

Another finding is strawberry appearance of nasal mucosa.

Heerfordt Syndrome : Rare subacute variant of sarcoidosis.

- Bilateral parotid enlargement.
- Facial nerve palsy.
- Anterior uveitis.

Diagnosis of sarcoidosis :

Biopsy : Non-caseating granulomas are seen.

Active space

Leave Feedba

Management :

- Steroids.
- Hydroxychloroquine.

Tuberculosis 00:50:11

Lupus Vulgaris : Cutaneous lesions of TB which can be seen in nose as well.

60c6b3eeaa8ded0e4e7e5ea7

Apple jelly nodules are seen here : Brownish nodules that do not blanch on pressure.

Management : Anti tubercular drugs.

Congenital Syphilis :

Catarrhal rhinitis is seen in these patients which can present at 3 weeks to 3 months time.

Late congenital syphilis presents with : Gumma.

Primary Syphilis :

Chancre is seen in the nose, a painless indurated ulcer.

Secondary Syphilis :

Snail track ulcers are seen in the nose. The is least seen in the nose.

Active space

Leave Feedbac

Tertiary Syphilis :

Gumma seen in the nose. most common type of syphilis seen in the nose.

60c6b3eeaa8ded0e4e7e5ea7

All granulomatous disease can cause perforation of nasal septum at the anterior part.

The bony part of the septum is more commonly involved and saddling of the nose can be seen.

Active space

Leave Feedbac

FRACTURES OF FACE & CSF RHINORRHOEA

Fractures of face

00:00:36

Most common fracture of face : Nasal bone fracture.

Classification of fractures of nasal bone :

Class I	Class II	Class III
Chevallet fracture	Jarjaway fracture	Naso-orbito ethmoid fracture
Fracture of nasal bone + septum (septum not deviated)	Fracture of nasal bone + septum (septum deviated)	
Septum has vertical fracture	Septum has horizotal /C-shaped fracture	Pig nose deformity
Lateral blow	Lateral / Frontal blow	

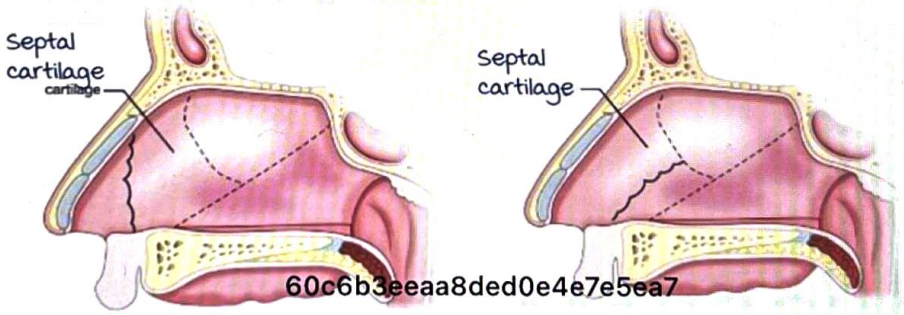

60c6b3eeaa8ded0e4e7e5ea7

Chevallet fracture

Jarjaway fracture

Management : Closed reduction (refracture and realign); after 1 week /after edema subsides, using Asch's forceps (for nasal septum) or Walsham forceps (for bone wall).

Asch nasal septum forceps

Walsham forceps

Active space

Management after 3 weeks – Rhinoplasty (for > 17 yrs ; Surgery performed after 6 months).

CSF rhinorrhoea

00:15:26

Cause :

Trauma (95%) : Most common.

Spontaneous (5%) : Infective erosion, tumor erosion, congenital dehiscence, empty sella syndrome.

Most common site : Lateral lamella of cribriform plate.

Diagnosis :

Clinical examination	Biochemical examination	Radiological examination
1. Sniff test. 2. Handkerchief test. 3. Halo/ Target/ Double ring sign 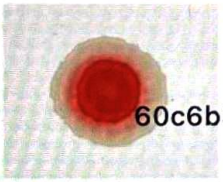 4. Reservoir sign (gush of fluid from nose).	1. β_2 transferrin. 2. β trace protein.	1. HRCT (best investigation). 2. CT cisternography (for active leak).

60c6b3eeaa8ded0e4e7e5ea7

Active space

Leave Feedba

Olfactory groove – Keros classificatic

Type I	1-3mm
Type II	4-7mm
Type III	8-16mm



©MARROW

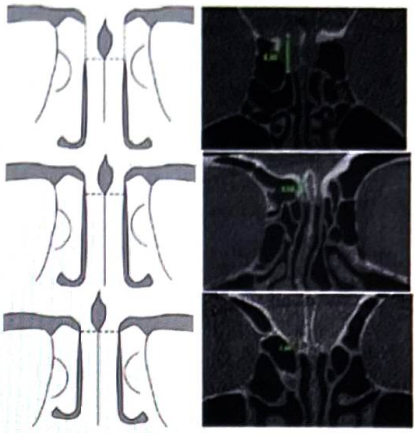

management :

1. Conservative for 2 weeks : Aims at lowering the CSF pressure (using mannitol, glycerol, diuretics ; propped up position).
2. Endoscopic repair (preferably, using fluorescein dye) or external repair : If no improvement is seen within 2 weeks.

Zygomatic bone fracture

00:37:15

Tripod fracture :

Infra orbital fracture

+

zygomatico temporal fracture

+

zygomaticofrontal fracture.

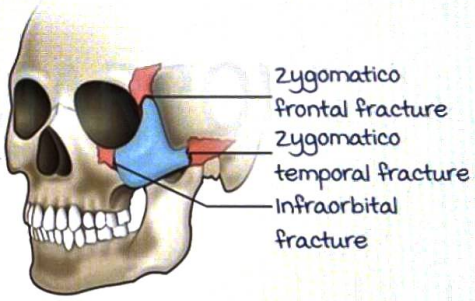

- Features of zygomaticomaxillary fracture :
  - Flattening of cheek.
  - Anaesthesia of cheek (due to infraorbital nerve injury).
  - Periorbital emphysema.
  - Step deformity.
  - Diplopia.
  - Enophthalmos.
- Feature of zygomaticotemporal fracture – trismus.
- Feature of zygomaticofrontal fracture – step deformity of lateral orbital rim.

management : Reduced by open reduction.

ActiveSpace
kumarankitindia1@gmail.com

Blowout fracture

00:42:56

It is the fracture of the floor of orbit.

most common site – inferior wall of orbit.

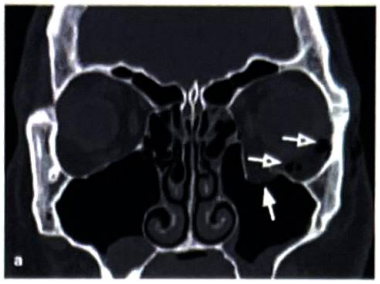

Tear drop sign

Features :

- Periorbital emphysema.
- Step deformity of infraorbital margin.
- Diplopia.
- Enophthalmos.

Maxillary bone fracture

00:45:29

Also known as Le Fort fracture.

Le Fort classification of fractures

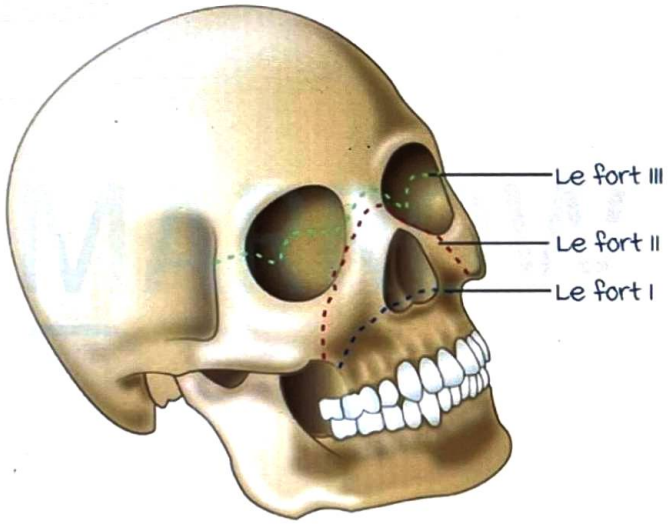

Types :

Le Fort – I fracture :

- a/k/a Guerin fracture.
- Fracture is parallel to the palate.
- Hanging teeth

60c6b3eeaa8ded0e4e7e5ea7

Le Fort-II fracture :

- Pyramidal fracture.
- Hanging maxilla.

Le Fort-III fracture : Craniofacial disjunction.

Active space

Leave Feedba

TUMORS OF THE NOSE AND PNS

Benign tumors

00:01:02

most common benign tumor of the external nose is : Rhinophyma.

Rhinophyma :

Hypertrophy of the sebaceous glands on the tip of the nose.

Usually seen in males of middle age or elderly.

Also known as elephantiasis of the nose or potato nose.

Rhinophyma

Long standing acne rosacea can be a cause for this tumor.

Usually excision of the tumor is not done unless the facial appearance is of concern or in cases of nasal obstruction.

CO_2 laser excision or knife excision with skin grafting can be done.

Inverted papilloma :

Also called as Schneiderian papilloma or Ringertz tumor.

most common benign tumor of the nasal cavity.

Caused by human papilloma virus and is considered the worst tumor.

Inverted papilloma

60c6b3eeaa8dec0e4e7e5ea7

It is :

- Benign but locally invasive.
- Premalignant.
- Recurrent.
- Arises from the lateral wall of the nose, therefore misdiagnosed as a polyp.

Presentation :

- Elderly male.
- Unilateral nasal obstruction.
- Blood-tinged nasal discharge.

Active space

Leave Feedba

On endoscopy, a unilateral polypoidal mass arising from the middle meatal area from the lateral wall is seen.

Papillary appearance seen on the outer surface of the mass and inverted, because on histopathology, the epitheliuminstead of growing outside, grows towards the stroma.

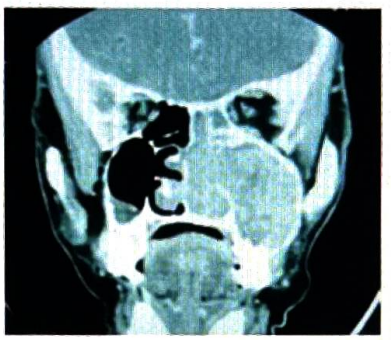

On CT the mass can be filling sinuses/expansion of sinuses.

Management is by wide excision as it is a locally invasive tumor.
No role of radiotherapy as it is a benign tumor.

Recurrence is common following excision and follow up is done via both CT scan and MRI.
MRI is preferred because it helps to differentiate the mass from secretions and normal tissues.

Benign tumor of the paranasal sinuses :
Most common benign tumor of the paranasal sinus is : Osteoma.
All benign tumors of paranasal sinuses are more common at superior aspect than inferior aspect of the head.
Except fibrous dysplasia, where the most common site is : maxillary sinus.
If a mass is seen in the frontal lobe : Suspect osteoma.
If mass is seen at the maxillary bone in a young patient : Suspect fibrous dysplasia.

Therefore, the most common site for osteoma will be : Frontal > Ethmoid > maxillary.

60c6b3eeaa8ded0e4e7e5ea7

Whereas in cases of malignant tumor, the most common site are : maxillary > Ethmoid > Frontal.

Active space

Leave Feedbac

Fibrous Dysplasia

Fibrous dysplasia :

In Fibrous dysplasia, the normal medullary bone is replaced by Fibro-osseous tissue. This tumor is usually seen in young individuals and appears an irregular asymmetric mass.

On CT : Ground glass appearance is seen Fibrous Dysplasia. The whole of the bone is involved, therefore complete excision is not possible and resculpturing of the bone for cosmetic reasons can be done but cannot cure the underlying cause.

kumarankitindia1@gmail.com

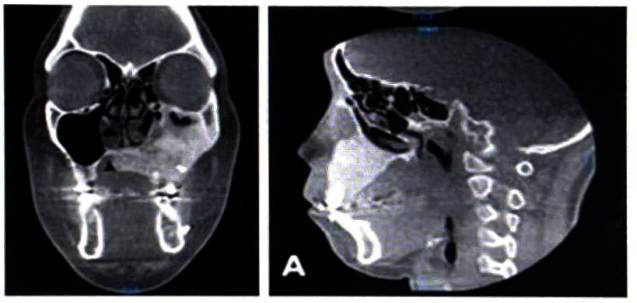

Ossifying fibroma :

Bone is replaced by fibrous tissue. The mass is well circumscribed and well defined.

Excision is easy.

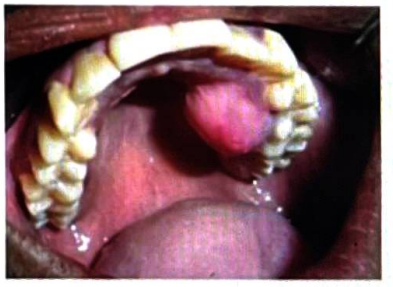

Ossifying Fibroma

Ossifying fibroma is most commonly seen in : mandible > maxilla.

Carcinoma of nose and paranasal sinuses 00:18:44

most common carcinoma in the nose and paranasal sinuses : Squamous Cell Carcinoma (SCC).

Active space

Leave Feedbac

Except, in the external nose, the most common carcinoma is : Basal Cell Carcinoma (usually seen in the sun exposed areas).
Basal Cell Carcinoma is also known as rodent ulcer.

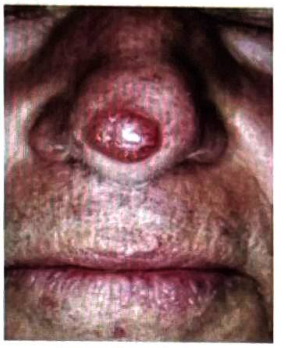
Basal Cell Ca

Rodent Ulcer is more commonly seen in elderly and males.
Most common carcinoma in paranasal cavity : SCC.
Most common carcinoma in nasal cavity : SCC.

Nosepickers carcinoma is another name for SCC in nasal cavity.
Most common location for paranasal sinus carcinoma : Maxillary Sinus.

But in cases of adenocarcinoma of the paranasal sinus, they are most commonly seen in the : Ethmoid sinus.

Maxillary sinus carcinoma is seen in : Carpenters or individuals with great wood exposure.
People working in hard wood industries : Adenocarcinoma
People working in soft wood industries : SCC (much more common variety).
Carcinoma of the paranasal sinuses are most commonly seen in : Bantu Tribe of South Africa because of mahogany wood burning.

Main lining epithelium in the nose : Ciliated columnar Pseudostratified Epithelium.
50c6b3eeaa8ded0e4e7e5ea7
Olfactory epithelium is seen in the upper 1/3rd of the nose.
5% of nasal tumors arise from the olfactory epithelium.

Olfactory neuroblastoma 00:24:32

Tumor arising from the olfactory epithelium.
This tumor is also called as esthesioneuroblastoma.
This tumor is more commonly seen in females in a bimodal

Active space

Leave Feedba

occurance, at 20 years and 50-60 years of age.
Very aggressive tumor and can cause metastasis early.
metastasis can be LN or distant metastsis.

Presentation :

- Blood tinged nasal discharge.
- Nasal Obstruction.

On endoscopy a cherry red vascular mass is seen. This is a neuroendocrine tumor, therefore it can secrete hormones. Therefore paraneoplastic syndromes should be investigated in suspected patients.

CT scan shows tumor attaching to the cribriform plate/ olfactory epithelium on the roof.

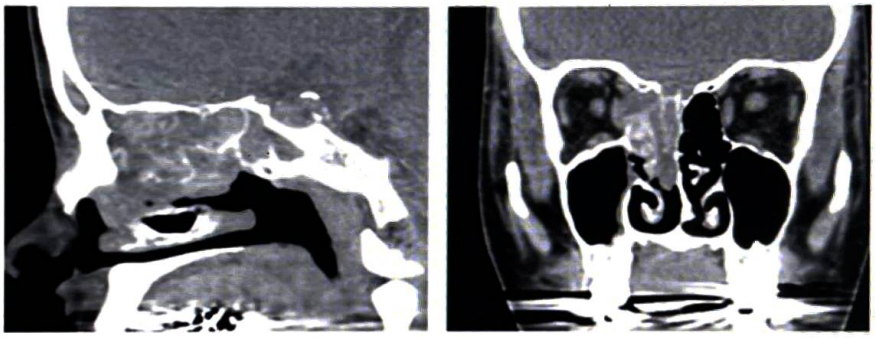

60c6b3eeaa8ded0e4e7e5ea7

Management :
In early stages : Excision.
In late stages : Excision + Radiotherapy.

Maxillary sinus Carcinoma Classification
Ohngren's Classification :
It is an imaginary line that is drawn from the root of nose to the angle of mandible, this line divides the maxillary sinus into two areas.
The area above the line is known as Suprastructure and below is known as Infrastructure.
It's a good prognostic indicator.

Active space

Leave Feedbac

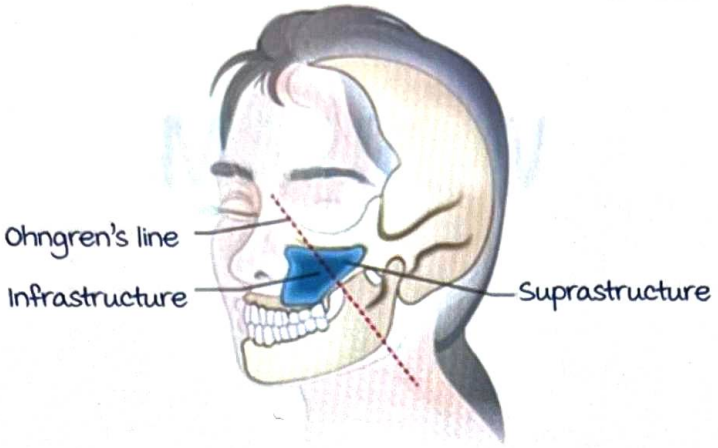

Ususally Infrastucture carcinoma is considered to be early stage and has better prognosis than Suprastructure.

kumarankitindia1@gmail.com

TNM Staging of maxillary sinus carcinoma :
CT scan is used for staging.

Stage	TNM Grade	Extent	management
1	T1 N0 M0	Only mucosa is involved and no bony erosion.	Surgical Exicision (maxillectomy)
2	T2 N0 M0	Tumor involves the lateral wall of nose and hard palate	Surgical Exicision (maxillectomy)
3	T3 N0 M0 T1/2/3 N1 M0	Suprastructures involved. The tumor has progressed superiorly (floor of the orbit and ethmoid sinuses) and posteriorly (posterior wall of maxillary sinus and sphenopalatine fossa or Pterygopalatine fossa).	Surgical Excision (Complete or Partial mxillectomy) + radiotherapy.
4	Everything else is Stage 4	Tumor has extended to the pterygoid plates or infratemporal fossa or skin of cheek or orbital contents or frontal/ sphenoid sinus or cribriform plate.	Surgical Excision (Complete or Partial mxillectomy) + radiotherapy.

Active space

Leave Feedbac

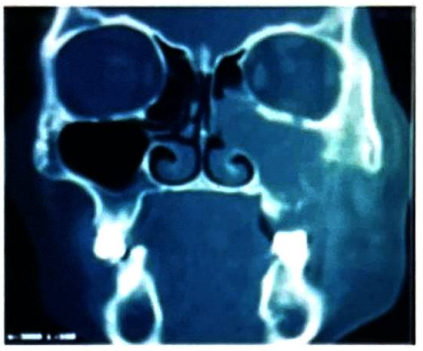

Stage 4

Endoscopic excision is done wherever possible.

In case of CA of Right Maxilla with Involvement of Right Upper Deep Cervical or Right Submandibular LN, It is Stage 3.

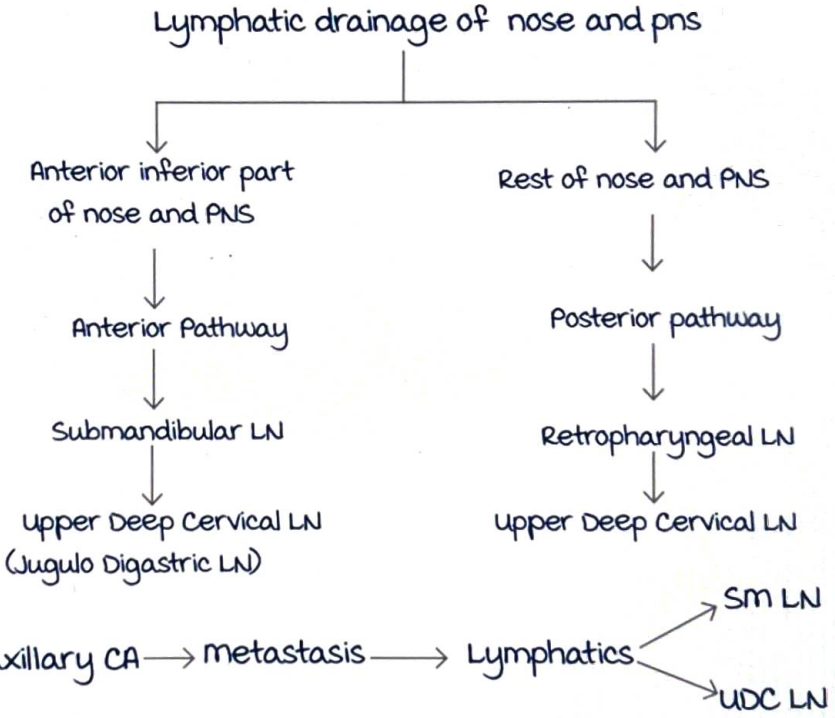

External incisions to excise maxilla :

Weber Fergussen incision : Incision made under the orbit and continues along the nasofacial crease and ends at the philtrum.

60c6b3eeaa8ded0e4e7e5ea7

Moure's incision : Incision made only at the nasofacial crease.

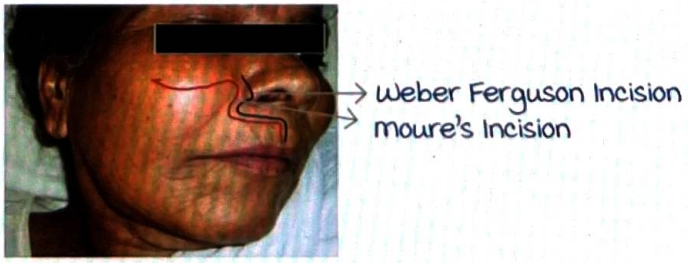

Active space

Leave Feedbac

Mid facial degloving approach : Incision is made from one molar to the other. Done to reduce external scar and preserve cosmetic features of the patient.

Mid facial degloving approach

Lederman's classification :

Not commonly used.

2 Horizontal lines of sebileau, one passing through the floor of the orbit and the other through the floor of the maxillary sinus.

These 2 lines divide the sinuses into 3 parts :

- Suprastructure : Ethmoid, sphenoid and frontal sinuses are present here.
- Mesostructure : Maxillary sinus and nasal cavity.
- Infrastructure : Has alveolar process.

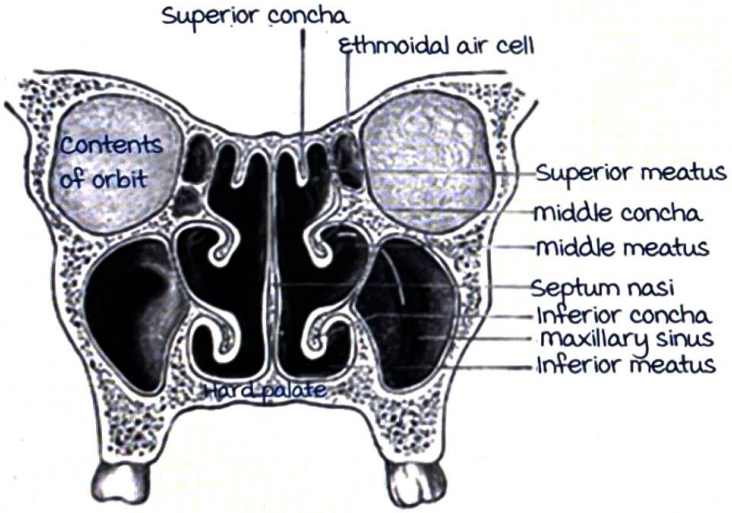

Lederman's classification

Midline lethal granuloma 00:45:24

Also known as stewart's granuloma or T-cell lymphoma or natural killer lymphoma.

- A non hodgkins lymphoma which expresses T-cell antigens.
- It involves the midline structures of the face.
- Aggressive tumor which is angioinvasive.
- Causes ischemia and necrosis of mid line structures.
- Very poor prognosis.

60c6b3eeaa8ded0e4e7e5e87

Active space

Leave Feedba

Management :

Radiotherapy is the preferred management.

In recurrent cases or disseminated cases : Chemotherapy.

Surgery has no curative role, can be perfomed for reconstruction of nose.

kumarankitindia1@gma

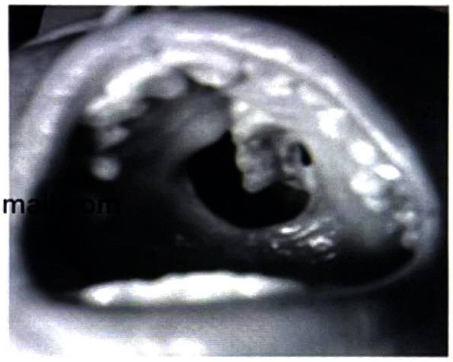

Midline Lethal Granuloma

Active space

371
Leave Feedba

CLINICAL ANATOMY OF PHARYNX : PART 1 (OVERVIEW)

Pharyngeal arches

00:01:46

1st arch : 2 lingual swellings + Tuberculum impar → Anterior 2/3 rd of tongue (supplied by Lingual branch of mandibular nerve for sensation & Chorda tymapani for taste).
Chorda Tympani is the pretrimatic nerve of the 1st arch arising from the 2nd arch.

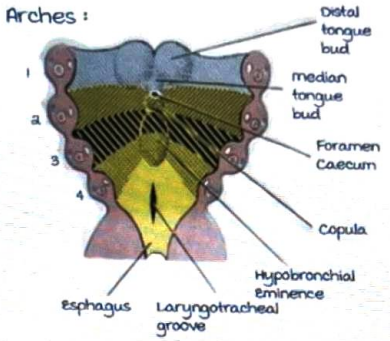

3rd arch : Cranial part of Hypobrachial eminence → Posterior 1/3 rd (anterior part)/ Base of tongue (supplied by glossopharyngeal nerve (9th) for taste & sensation).

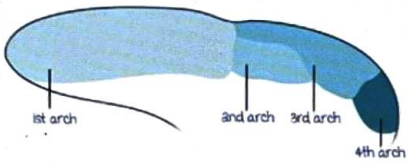

4th arch : Caudal part of Hypobrachial eminence → Posterior 1/3 rd (posterior part) & Epiglottis.
Posterior most part of tongue is supplied by Vagus nerve (10th) for taste & sensation.

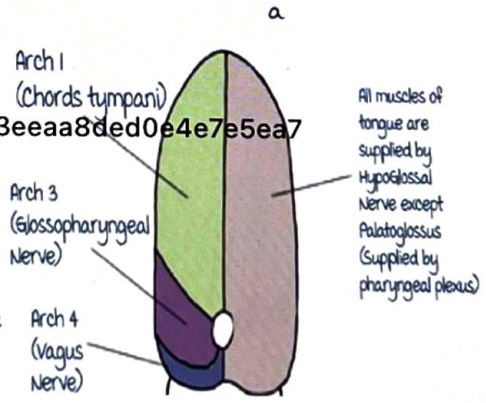

60c6b3eeaa8ded0e4e7e5ea7

Muscles of tongue are derived from occipital somites/ myotomes.
All the muscles are supplied by Hypoglossal nerve except palatoglossus muscle (supplied by pharyngeal plexus).

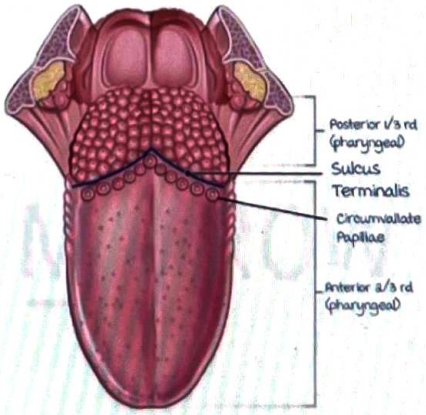

Active space

Leave Feedba

Circumvallate papillae are part of anterior 2/3 rd of tongue but are supplied by glossopharyngeal nerve.

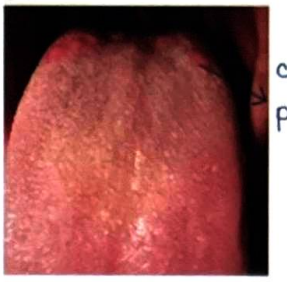

circumvallate papillae

Referred pain can travel to ear through glossopharyngeal nerve (Jakobson), vagus nerve (Arnold), mandibular (lingual) nerve. CN IX >>CN X.

muscles of tongue derived from occipital somites/myotomes. They are supplied by hypoglossal nerve except for palatoglossus supplied by pharyngeal plexus.

Left hypoglossal palsy deviates the tongue to the affected side [due to genioglossus (right) muscle protuding & deviating the tongue to left side].

Left Hypoglossal palsy

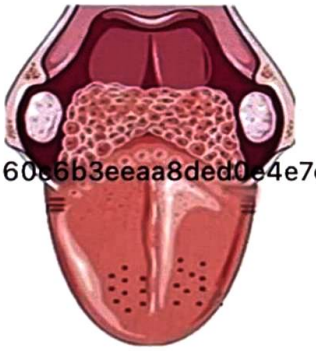

60e6b3eeaa8ded0e4e7e5ea7

Left Hypoglossal palsy

Anatomy of Pharynx 00:22:39

Pharynx : Musculofascial tube made of muscles & fascia & extends from base of skull above to the lower border of cricoid below.

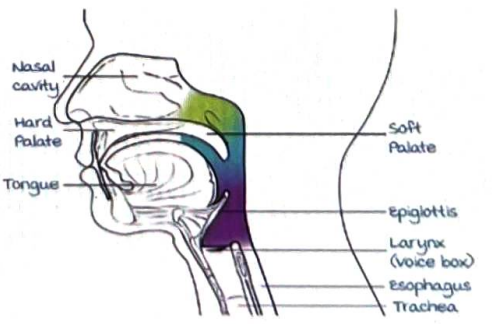

It is divided in 3 parts & named on the basis of the

Active space

parts it lies behind to :

- Nasopharynx/ Epipharynx (behind nose).
- Oropharynx (behind oral cavity).
- Laryngopharynx/ Hypopharynx (behind larynx).

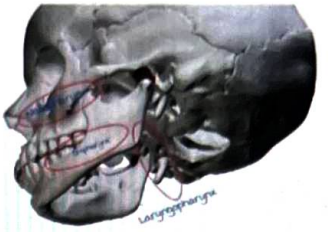

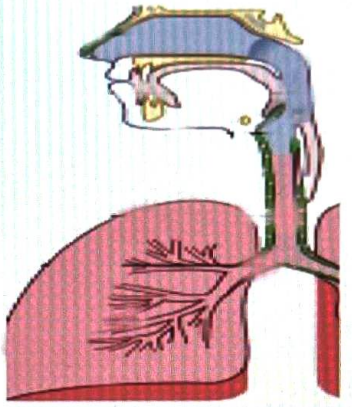

Pharynx acts as a connection between nose-through pharynx to larynx & oral cavity - esophagus.

Nasopharynx is bounded by :
Superiorly : Base of skull.
Inferiorly : Palate.
Nasopharynx : Opposite 1st cervical vertebrae.

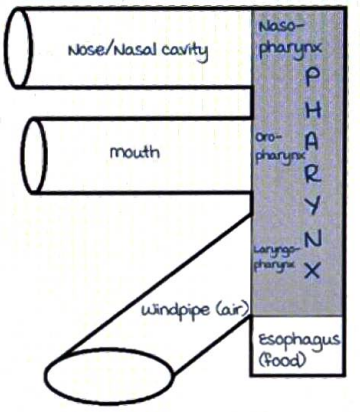

Oropharynx is present behind oral cavity & bounded by hard palate above and by hyoid below.
Oropharynx : Opposite to 2nd & upper part of 3rd cervical vertebrae.

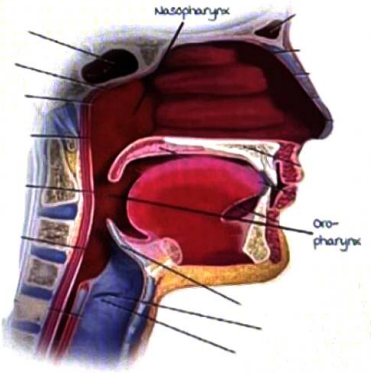

Hypopharynx extends from hyoid to lower border of cricoid & lies behind larynx.kumarankitindia1@gmail.com
Hypopharynx : Opposite lower border of C3, C4, C5 , C6 vertebrae.


Posterior rhinoscopy mirror

Oropharynx is the only part which is easily accessible for visualization.
For visualizing nasopharynx → Posterior rhinoscopy mirror. Held like pen.
The mirror has 2 tilts so that it doesn't touch the tongue & palate else gag reflex occurs.

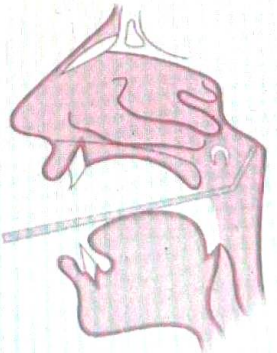

Active space

Leave Feedba

Depressing the tongue is preferred behind the uvula for better visualisation of nasopharynx.

Nowadays , nasal endoscopy is done.

For visualizing Hypopharynx & larynx → Indirect laryngoscope mirror is used.

Tongure is not depressed but pulled out instead to go behind for better viewing.

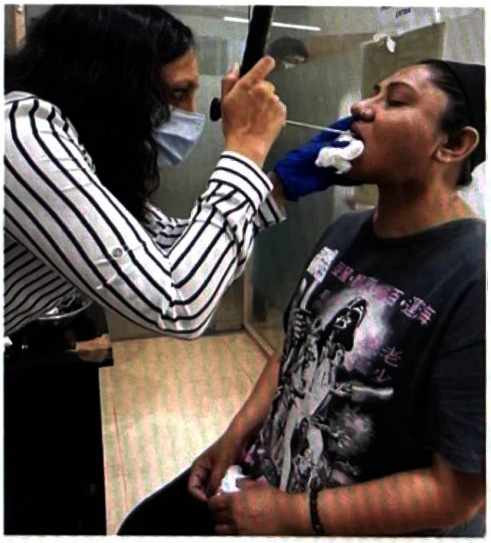

Active space

375
Leave Feedba

CLINICAL ANATOMY OF PHARYNX : PART 2 (PHARYNGEAL WALL)

Introduction :

Muscular tube bounded anteriorly & posteriorly by fascia.

Hence called musculofacial tube.

Connects the nose with larynx & oral cavity with oesophagus.

Inverted cone in shape :

Broadest : Nasopharynx.

Narrowest : Hypopharynx (laryngopharynx).

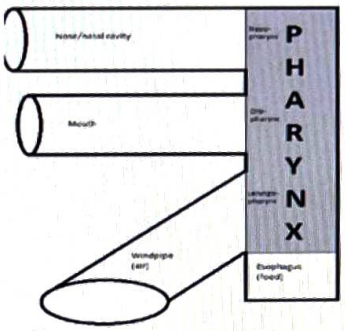

Nasopharynx :

Base of skull to hard palate.

Oropharynx :

Hard palate to hyoid bone.

Laryngopharynx :

Hyoid bone to lower border of cricoid.

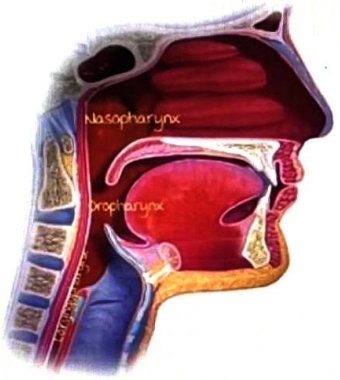

Anatomy of pharyngeal wall

00:02:22

Layers of pharyngeal wall

Epithelial lining.

Waldeyer's ring.

Pharyngobasilar fascia.

Longitudinal muscles.

Circular muscles.

Buccopharyngeal fascia.

Epithelial lining :

Lined by stratified squamous non keratinized epithelium except for nasopharynx.

Nasopharynx lined by ciliated columnar pseudostratified non keratinized epithelium.

Active space

Leave Feedba

Lining epithelium of :

Adenoids : Ciliated columnar epithelium.

Tonsils : Stratified squamous epithelium.

Soft palate : Has 2 surfaces.

Nasopharyngeal surface : Ciliated columnar epithelium.

60c6b3eeaa8ded0e4e7e5ea7

Oropharyngeal surface : Stratified squamous epithelium.

Waldeyer's ring

00:06:27

Collection of subepithelial lymphoid tissues in the form of ring, below the pharyngeal wall.

Component of MALT (Mucosa Associated Lymphoid Tissue).

Gets hypertrophied in case of allergy or infection.

Function :

Provides local/systemic immunity to children.

Gets atrophied in adults.

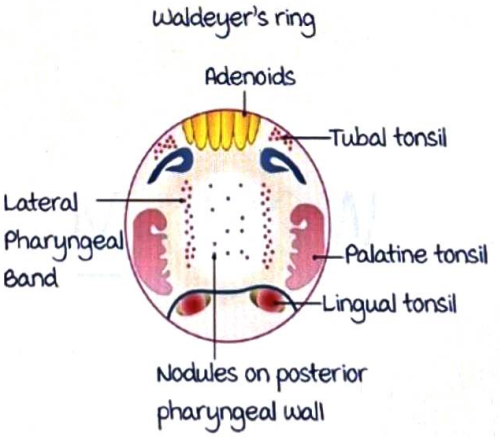

Components :

Adenoids :

Also known as Lushka's tonsil.

Nasopharyngeal tonsil.

Tubal tonsils :

Also known as Gerlach tonsil.

Present behind the nasopharyngeal opening of eustachian tube.

Palatine tonsils :

Also known as faucial tonsils.

Active space

Leave Feedba

Present in oropharynx between two pillars.

Lingual tonsil :

Present over the base of tongue.

Lateral bands & nodules :

Present in posterior pharyngeal wall.

Q. Identify the picture ?

kumarankitindia1@gmail.com

Ans : Adenoids.

Lining epithelium : Ciliated columnar.

Single mass with vertical ridges giving it a multiple appearance.

Q. Identify the picture ?

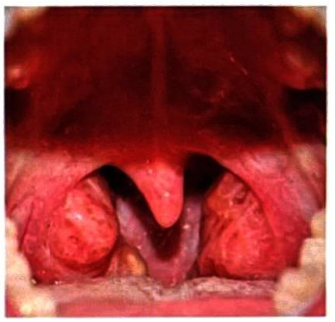

Ans : Palatine or faucial tonsil.

Lining epithelium : Stratified squamous.

Epithelium dips inside tonsillar tissue known as crypts.

Q. Identify the picture ?

Ans : Lingual tonsil.

Lining epithelium : Stratified squamous.

Q. Identify the picture ?

Ans : Nodules in posterior pharyngeal wall.

Lining epithelium : Stratified squamous.

Lining epithelium of soft palate :

Superior surface : Ciliated columnar.

Oropharyngeal surface : Stratified squamous.

Active space

Leave Feedbac

External waldeyer's ring

00:17:45

It's where internal waldeyer's ring drains.

Drains into retropharyngeal lymph nodes and neck nodes.

External waldeyer's ring are not a component of MALT.

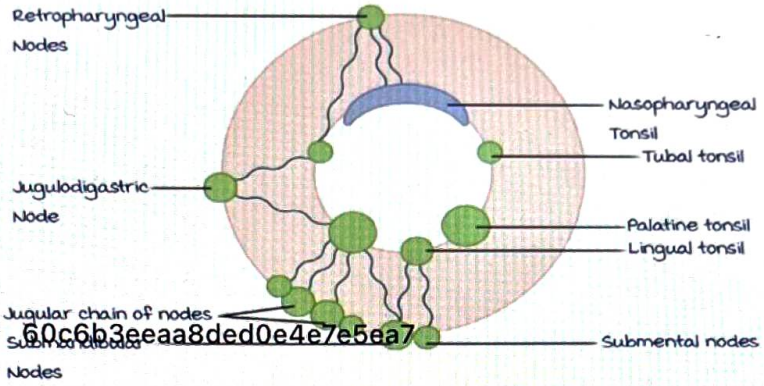

60c6b3eeaa8ded0e4e7e5ea7

Boundaries :

Pharynx	Epithelium	Waldeyer's ring
Nasopharynx/ Epipharynx	Ciliated columnar	Adenoids Tubal tonsils
Oropharynx	Stratified squamous non keratinised	Palatine tonsil Lingual tonsil
Laryngopharynx/ Hypopharynx	Stratified squamous non Keratinised	

Pharyngobasilar fascia :

Anterior fascia of pharynx.

Capsule of tonsil :

- Formed by thickening of pharyngobasilar fascia.
- Hemicapsule.
- Tightly adherent to tonsil.

Muscles of pharynx

00:25:15

2 layers of muscles :

1. Longitudinal muscles : 3
   Also known as dilators.

Active space

Leave Feedba

Salpingopharyngeus :

Originate from eustachian tube and gets attached to thyroid.

Palatopharyngeus :

Originate from palate and gets attached to thyroid.

Stylopharyngeous :

Originate from styloid process and gets attached to thyroid.

Posterior view of pharyngeal wall

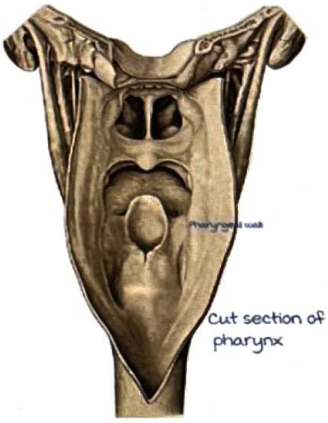

Cut section of pharynx

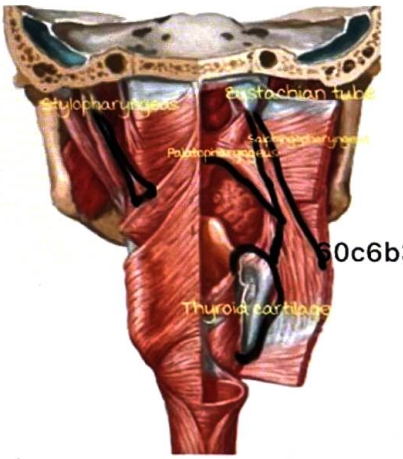

60c6b3eeaa8ded0e4e7e5ea7

2. Circular muscles :

Known as constrictors.

Present behind longitudinal muscles.

Posteriorly constrictors attached to the midline fibrous raphe.

Arranged as 3 types :

Superior constrictor muscle :

Arise from the pterygoid.

Has attachment to mandible by pterygomandibular raphe.

Upper border of the muscle is free & not attached to base of skull.

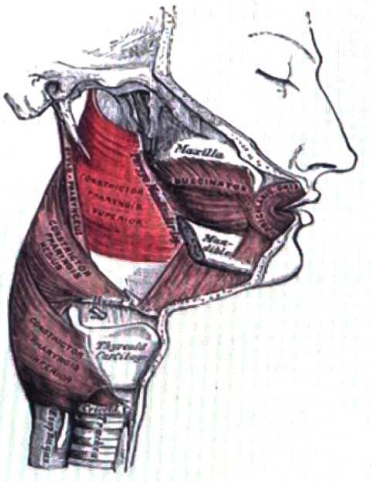

Middle constrictor muscle :

Originates from the hyoid.

Active space

Leave Feedba

Inferior constrictor muscle :

Originates from the thyroid.

Thyropharyngeus (oblique fibers).

Cricopharyngeus (horizontal fibers).

Gaps are present between constrictor muscles :

Between superior & middle constrictor laterally.

Between middle & inferior constrictor laterally.

Gaps are the entry sites for nerves and vessels supplying the pharynx.

Circular muscle at level of nasopharynx : Superior constrictor.

Circular muscle at level of oropharynx : Inferior constrictor.

Circular muscle in the bed of tonsil : Superior constrictor.

Sinus of Morgagni 00:38:58

Upper border of superior constrictor is free and creates a gap between muscle and base of skull.

Sinus of morgagni syndrome :

Advanced nasopharyngeal carcinoma extend into middle ear (base of skull) through sinus of morgagni producing symptoms.

Structures passing through sinus of morgagni :

Mnemonic : TAALA.

Tensor palatini.

Auditory tube.

Ascending palatine artery.

Levator palatini.

Palatine branch of Ascending pharyngeal artery.

Nerve supply of pharynx 00:44:58

Supplied by 9th and 10th nerves.

10th nerve :

1. Superior laryngeal branch :
   - Internal laryngeal nerve.
   - External laryngeal nerve.
2. Recurrent laryngeal branch :

kumarankitindia1@gmail.com

Active space

Leave Feedback

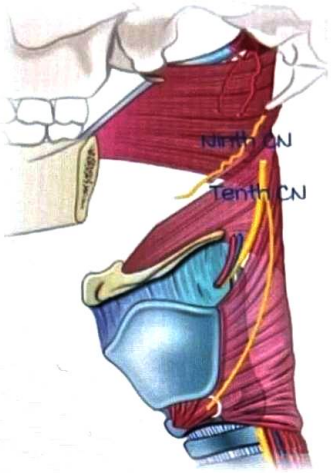

Part	Constrictors
Nasopharynx	Superior constrictor
Hypopharynx	Inferior constrictor
Oropharynx	Most of lateral wall by superior constrictor

Nerves passing :

Between superior & middle constrictor : 9th nerve.

Between middle & inferior constrictor : Internal laryngeal nerve, branch of superior laryngeal nerve.

Between inferior constrictor & esophagus : Recurrent laryngeal nerve.

Muscle passing :

Between superior & middle constrictor : Stylopharyngeus.

Killian's dehiscence

00:53:08

Posterior gap.

Gap between thyropharyngeus & cricopharyngeus fibers of Inferior constrictor muscle.

Also known as gateway of tears.

Most common site of pharyngeal pouch formation.

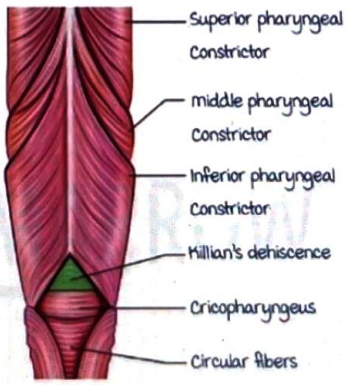

Active space

Leave Feedba

Zenker's diverticulum :

Occurs due to neuromuscular incoordination.

Seen in elderly.

Posterolateral diverticulum.

A Pulsion diverticulum.

A false diverticulum (muscle layer not involved).

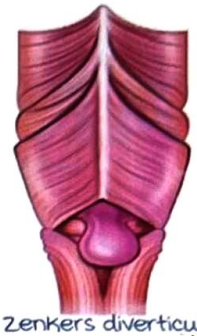

Zenkers diverticulum

Investigation :

Barium swallow (lateral view : Best).

Clinical presentation :

Dysphagia.

Halitosis.

Regurgitation of undigested food.

Laryngitis.

Lung complications.

Cough.

60c6b3eeaa8ded0e4e7e5ea7

Neck swelling :

most common on left side.

On palpation: Gurgling sounds heard (Boyce sign).

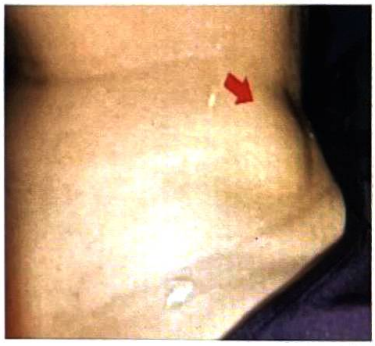

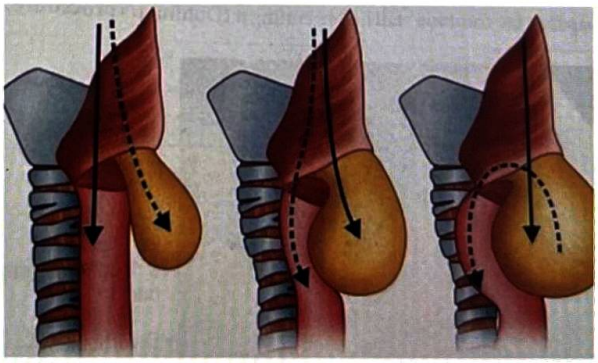

Endoscopy :

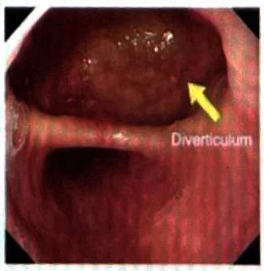

Active space

Leave Feedbac

Treatment of killian's dehiscence

01:06:47

Cricopharyngeal myotomy (cutting of the common wall).

Laser technique :

Dohlman's procedure :

- Pouches < 2 cm.
- Uses diathermy or CO_2 laser.

Endoscopic stapling :

- Pouches > 2 cm.
- Recommended procedure.
- Cuts the walls & staples the edges simultaneously.

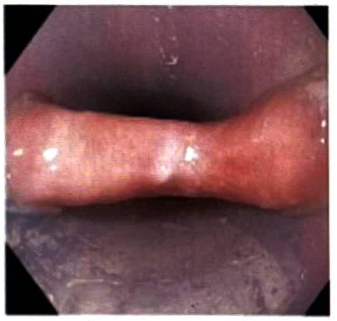

Dohlmans procedure

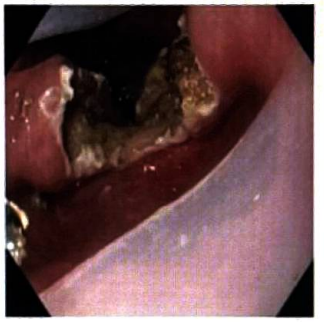

CO_2 laser

kumarankitindia1@gmail.com

Open neck surgery :

- External approach.
- If the pouch is very large (>4 cm).

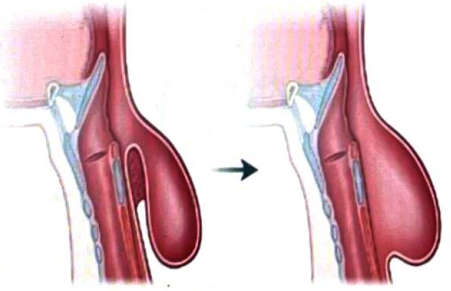

Buccopharyngeal fascia : Present behind the muscles.

Active space

Leave Feedba

CLINICAL ANATOMY OF PHARYNX : PART 3 (SPACES AND ITS ABSCESS)

Layers of pharyngeal wall

00:03:47

- Muscle layer.
- Buccopharyngeal fascia.
- Alar fascia.
- Pre vertebral fascia.
- Vertebrae.

In between buccopharyngeal fascia and alar fascia → Retropharyngeal space.
In between alar fascia and prevertebral space → Danger space.
(Called dangerous since Infection here is dangerous.)
Upper limit of all 3 spaces is base of skull.
Lower limit of all 3 spaces varies.

Lower limit →
Retropharyngeal space → T4.
Danger space goes down till diaphragm (can go to mediastinum easily).

In between pre-vertebral space and vertebrae → Prevertebral fascia.

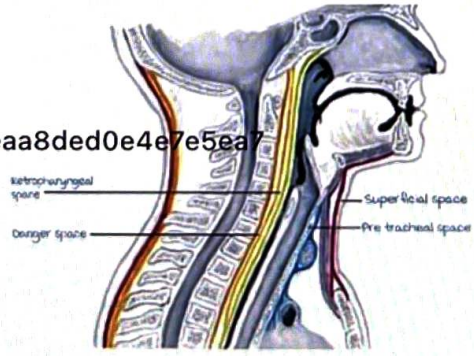

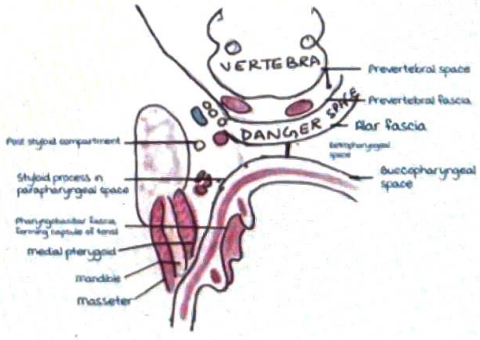

60c6b3eeaa8ded0e4e7e5ea7
Active space

Transverse cut section at the level of tonsil and oropharynx.

- Transparent epithelial lining :
  At the level of tonsil → Stratified squamous epithelium.
60c6b3eeaa8ded0e4e7e5ea7
- Behind that, pharyngobasillar fascia (forms capsule of tonsil).
- 2 muscle layers.
- Buccopharyngeal fascia.
- Alar and prevertebral fascia.

Retropharyngeal spcae has lymph nodes →Nodes of rouviere.
This space is also known as space of Gillette.

Spaces	Upper	Lower	Anterior	Posterior
Retro pharyngeal space of gillette	Base of skull	T4	Bucco pharyngeal fascia	Alar fascia
Danger space	Base of skull	Diaphragm	Alar fascia	Prevertebral fascia
Prevertebral space	Base of skull	T4	Prevertebral fascia	Vertebrae

Differentiate between retropharyngeal or prevertebral abscesses :
Retropharyngeal space is divided in the midline by fibrous raphae into 2 spaces.

Retropharyngeal space bulge is never a midline diffuse bulge.
Always be a para median bulge (unilateral).
Whereas prevertebral bulge midline diffuse bulge of posterior pharyngeal wall.

Retropharyngeal space has 2 compartments.

Prevertebral shadow is increased.
Prevertebral thickness → C2 normal : 7 mm.
At C6, it varies in adults and children.

Active space

Leave Feedba

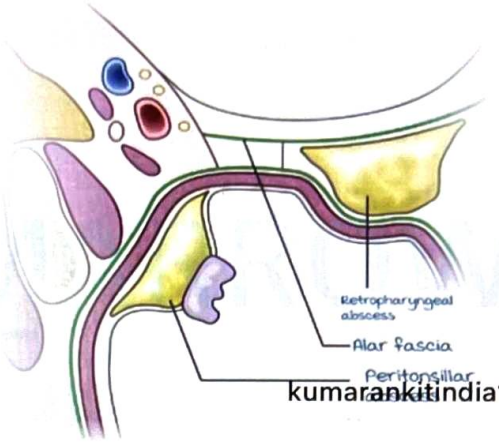

kumarankitindia1@gmail.com

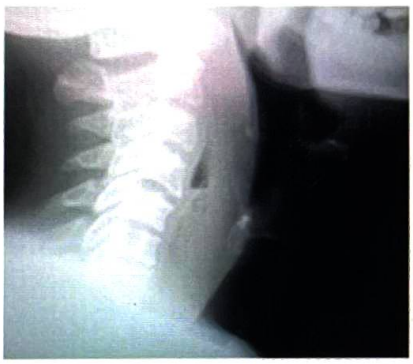

In Children → 14 mm.

In adults → 21 mm.

In both there will be lumbar lordosis.

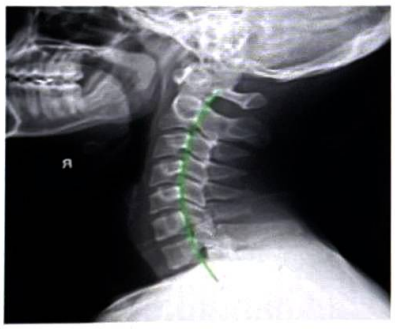

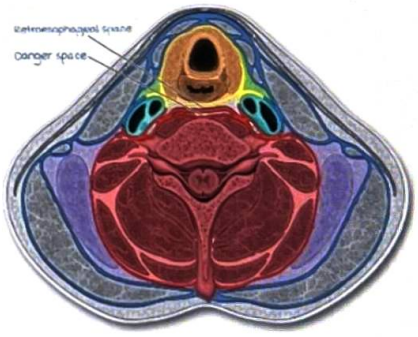

Abscess can be differentiated with the help of CT :

Prevertebral abscess

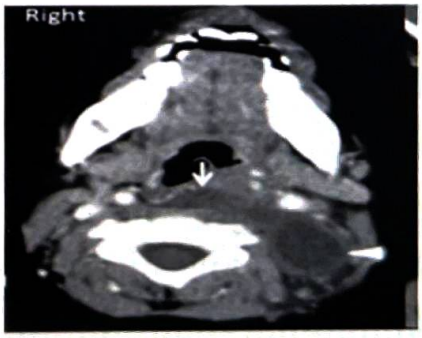

Retropharyngeal abscess

Active space

Leave Feedba

Retropharyngeal abscess

00:18:12

Can be both acute or chronic.

Acute :

Causes :

Children → Acute infections of nasopharynx.

Adults → m/c cause is penetrating injury like fish bone,chicken bone, etc.,.

More common in children.

Chronic :

More common in adults.

Due to TB spine (caries spine/Pott's spine).

C/F :

- Fever
- Dysphagia.
- Odynophagia.
- Stridor.
- Torticollis.

O/E : Unilateral paramedian bulge of posterior pharyngeal wall, i.e., on one side of midline.

Difference from peritonsillar abscess → Midline diffuse bulge of posterior pharyngeal wall.

Diagnosis → CT.

Management :

Medical management → IV antibiotics.

Look for response.

If worsens till 24-48 hrs : Drainage of abscess.

No medical management first and immediate drainage when,

- Respiratory distress.
- Nerve compression features.

Intra oral incision for I & D is preferred.

Huge abscess, extended down till T4 → External incision can also be given.

Chronic :

TB abscesses are not drained by I & D as it might lead to sinus formation.

Mx → ATT.

Active space

Leave Feedba

Parapharyngeal space

00:28:32

Lateral to lateral wall of pharynx.
This space is also known as pharyngomaxillary space (parapharyngeal space).

This space is medially to lateral wall of pharynx and laterally to mandible.
Vessels and nerves passing through this space :

- CN IX, X, XI and XII comes down from base of skull.
- Internal jugular vein.
- Internal carotid artery.

This space is divided into 2 compartments :
Styloid process and muscles attached to it divides this space into 2 compartments.
Anterior compartment → Fat.
A.K.A Pre-styloid compartment.

Posterior compartment → Vessels and nerves.
A.K.A Post-styloid compartment.
Abscess of parapharyngeal space is most common in anterior compartment due to presence of increased amount of fat.

Vascular tumors and aneurysms are most common in posterior compartment.

Parapharyngeal space appears like inverted pyramid.
Starts from base of skull above to hyoid below as lower limit.

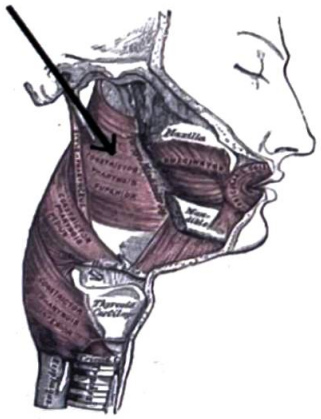

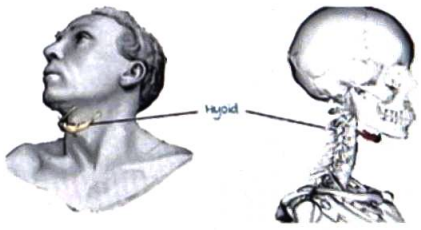

60c6b3eeaa8ded0e4e7e5ea7

Styloid attachments :
1. Styloglossus.
2. Stylomandibular ligament.
3. Stylopharyngeus.

Active space

Leave Feedbac

This divides para pharyngeal space into anterior and posterior compartments.

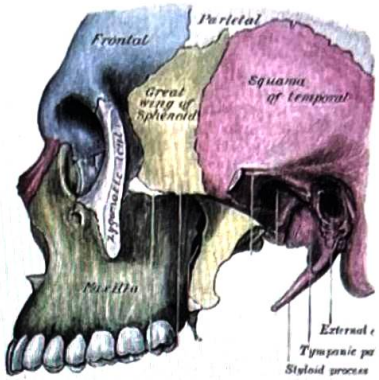

All the great vessels passes through
posterior compartment.

Trismus is seen in anterior compartment abscess.
In posterior compartment abscess, Trismus is not seen.

kumarankitindia1@gmail.com

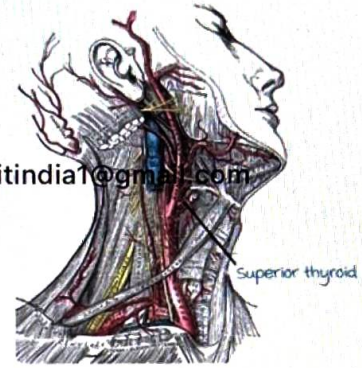

Neurogenic tumors, torticollis are most commonly seen in posterior compartment.

The space behind retropharyngeal space, prevertebral space.
Lateral to retropharyngeal space posterior compartment of parapharyngeal space.

Spaces	Upper	Lower	Medial (wall/ Fascia)	Lateral
Para pharyngeal space/ Pharyngo maxillary/ Lateral pharyngeal space	Base of skull	Hyoid	Lateral pharyngeal wall/ bucco pharyngeal fascia	mandible, medial pterygoid, masseter and parotid gland
Shape	Inverted pyramid			

Active space

Leave Feedbac

Contents :

Anterior/pre styloid compartment → mainly fat, branches of maxillary artery, branches of mandibular nerve i.e., auriculotemporal nerve, inferior alveolar nerve and lingual nerve.

60c6b3eeaa8ded0e4e7e5ea7

Posterior/post styloid compartment → CN IX, X, Xi and XII, Cervical sympathetic chain, internal carotid artery and internal jugular vein.

Abscess more common in anterior compartment.
Neurogenic tumours more common in posterior compartment.
Horner's syndrome seen in posterior compartment.
Abscess :
C/F →
Lateral pharyngeal wall pushed medially.
Tonsil is also pushed medially.

In between capsule of tonsil and superior constrictor, the space is called as peritonsillar space.
Infections of pharynx can spread here easily.
Which may lead to peritonsillar abscess.

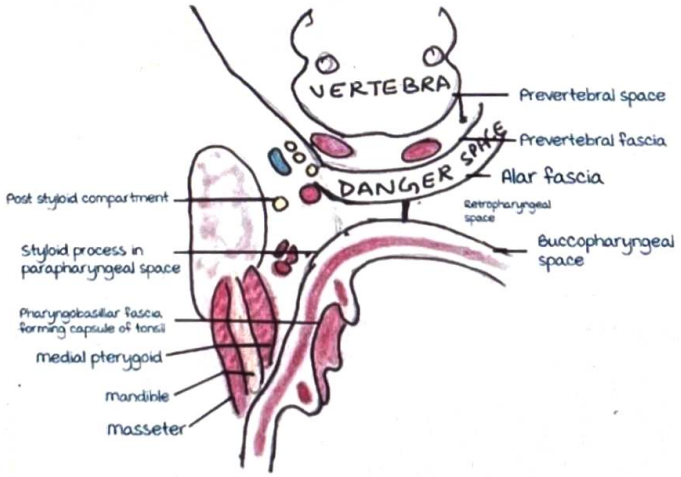

Incision given intra orally lateral to tonsil.

Peritonsillar abscess is differentiated from parapharyngeal abscess by bulge at the upper border of sternocleidomastoid, angle of jaw is parapharyngeal space abscess.

Active space

C/F of parapharyngeal abscess :

- Fever.
- Dysphagia.
- Odynophagia.
- Pain in the ear.
- Trismus present in anterior compartment.

O/E : Tonsil pushed medially.
External bulge at the angle of jaw, upper border of sternocleidomastoid.

60c6b3eeaa8ded0e4e7e5ea7

Posterior compartment :
Features → IX, X, XI and XII CN and Horner's syndrome.
No trismus.
Torticollis +.
Bulge internally : Behind posterior pillar.

Mx :
Medical management with IV antibiotics first.
If no response after 24–48 hrs : I & D.
External incision below the lower border of mandible.
Incision should be 2–3 cms below the lower border of the mandible, to prevent injury to marginal mandibular nerve.

Marginal mandibular injury : Angle of lip cannot be moved.
This nerve is a branch of facial nerve.

Peritonsillar space

01:04:01

Capsule of tonsil →
Pharyngobasillar fascia.
Loose areolar tissue.
Superior constrictor muscle.
Space between superior constrictor
laterally and capsule of tonsil medially → Peritonsillar space.

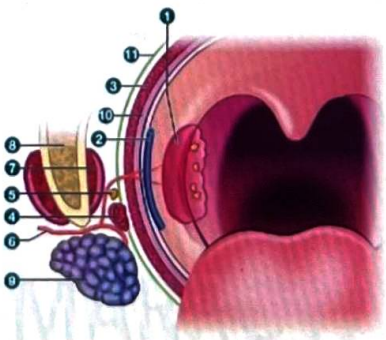

Active space

Leave Feedba

It consists of loose areolar tissue, external palatine vein.

Spaces	medial	Lateral	Anterior	Posterior
Peritonsillar space	Capsule of tonsil, i.e., pharyngo basillar fascia	Superior constrictor muscle	Anterior faucial pillar formed by palatoglossus	Posterior faucial pillar formed by palato pharyngeus
Content	Loose areolar tissue, fat, external jugular vein.			

kumarankitindia1@gmail.com

Peritonsillar abscess/quinsy :

Route → Infection of oropharynx, spread to crypts of tonsil and enters peritonsillar space.

m/c in adults.

Adult tonsil is atrophied.

Through crypta magna.

Organism : Group A β hemolytic streptococcus, anaerobes

C/F :

- Fever.
- Odynophagia.
- Dysphagia.
- Pain in the ear.
- Typical voice : Hot potato voice.

O/E : Tonsil pushed medially.

Trismus + (Superior constrictor is close to pterygoids).

Complete mx :

medical management with I.V antibiotics.

Aspiration.

If both fail, I & D.

D/D : Carotid aneurysm. Therefore, always aspirate first to confirm.

Incision is given at the site of maximum bulge, lateral to junction of anterior pillar and base of uvula.

Chance of difficulty in opening the mouth following healing is very little.

Not under GA.

Active space

Leave Feedback

Interval tonsillectomy is done after 6 weeks of last episode.
Of 1 episode in children and 2 episodes in adults.
Hot tonsillectomy/ abscess tonsillectomy :
Tonsillectomy done immediately.
Not done now a days.

	Peritonsillar	Parapharyngeal
Tonsil pushed medially	+	+
Trismus	+	+
Bulge at jaw angle	Absent	+
Ear pain	+	+
Incision	Intra oral	External incision
Communicates with other space		Peritonsillar, submandibular and retropharyngeal space

kumarankitindia1@gmail.com

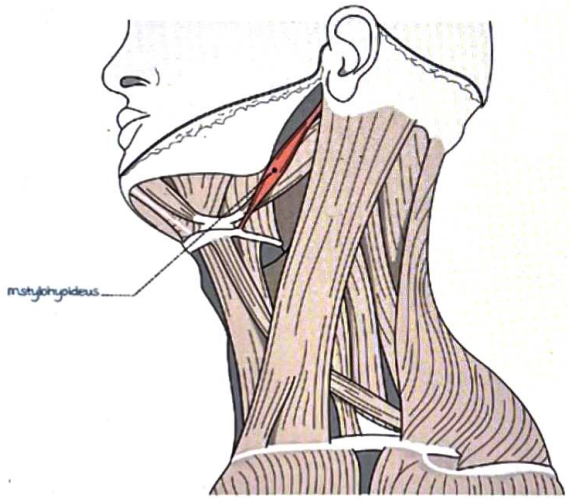

Submandibular space 01:25:10

Space in the floor of mouth.
Below the tongue and external limit is deep cervical fascia.
Divided into 2 compartments by mylohyoid.

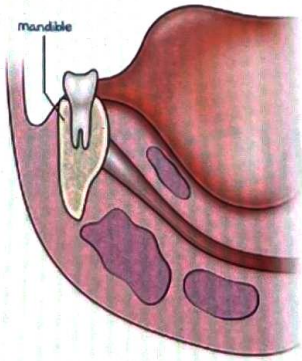

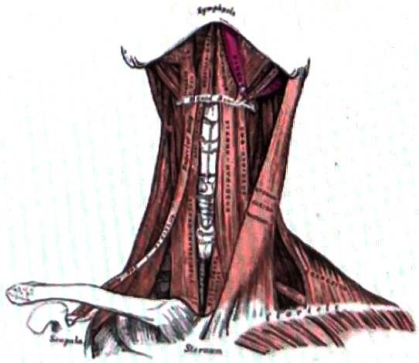

Active space

Leave Feedbac

Mylohyoid divides submandibular space into 2 compartments.

- Sub lingual compartment.
- Sub mandibular/sub maxillary compartment.

Sub lingual compartment → Salivary glands.
Submandibular/sub maxillary compartment → Some part invaginates sub lingual compartment also.

Pre molars project into sublingual space.
Molars projects into submandibular space.

Spaces	Upper	Lower	Antero inferior	Postero inferior
Sub mandibular space	Floor of mouth	Deep cervical fascia between mandible and hyoid	Anterior belly of digastric	Posterior belly of digastric
Source	Dental caries : Strep viridans, anaerobes.			
Cellulitis Known as	Ludwig's angina			

O/E : Hard woody feel, brawny appearance.

In case of sublingual infection :

- Raised floor of mouth.
- Tongue pushed up.
- Difficulty in speaking.
- Difficulty in eating.
- Trismus +.

60c6b3eeaa8ded0e4e7e5ea7

Active space

Goldring's criteria :

- Cellulitis of submandibular space.
- Always bilateral.
- Sublingual and submandibular salivary glands are not involved.
- Spreads through tissue spaces.

Management :

Airway management → Crucial.

Medical management with IV antibiotics.

No improvement → I & D.

Incision given from one angle of mandible to another in the midline.

2-3 cms below the lower border of mandible.

Parotid abscess

01:38:33

Parotid is bounded by 2 layers of deep cervical fascia.

Route → Via stenson's duct.

60b6b3eeaa8ded0e4e7e5ea7

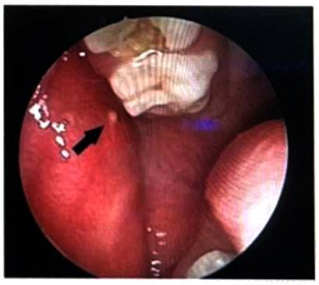

Predisposing factors → Dehydration (oral), poor oro dental hygiene, dental infections, diabetes, immunocompromised and HIV patients.

No age predisposition, bimodal age.

m/c organism → Staphylococcus, streptococcus and anaerobes.

C/F :

- Pain.
- Fever.
- Difficulty in opening mouth.

Age → Bimodal : 3-6 years, elderly.

O/E → Redness, tender and firm.

Fluctuation is a late sign.

Internally → Pus from stenson's duct.

Active space

Leave Feedba

Mx :

Medical management with IV antibiotics.

If failed : I & D.

Incision → Just in front of pinna → Vertical incision.

Dissection plane is parallel to facial nerve → Hilton's method.

kumarankitindia@gmail.com

Overall M/C cause of deep neck space infection :

Odontogenic infections.

Sex → M : F = Males > females, 1.6 : 1.

Predisposing factors → Immunosuppression, poor oral hygiene

Best imaging modality → CECT.

Management :

- Secure airway.
- IV antibiotics → No response → I & D.

Active space

Leave Feedbac

CLINICAL ANATOMY OF PHARYNX : PART 4 (CAVITY)

60c6b3eeaa8ded0e4e7e5ea7

Anatomy of the cavity of pharynx

00:00:38

Pharynx is a musculofascial tube which is like an inverted cone (broad superiorly).
Upper most part of the pharynx lies just posterior to the nasal cavity (nasopharynx).

Boundaries of the nasopharynx/epipharynx :
Superiorly→ Base of skull.
Inferiorly → Palate.
Posteriorly → Lies opposite to C I vertebrae.
Laterally → Extension of the lateral wall of the nasal cavity.
Lining epithelium → Ciliated columnar pseudostratified.

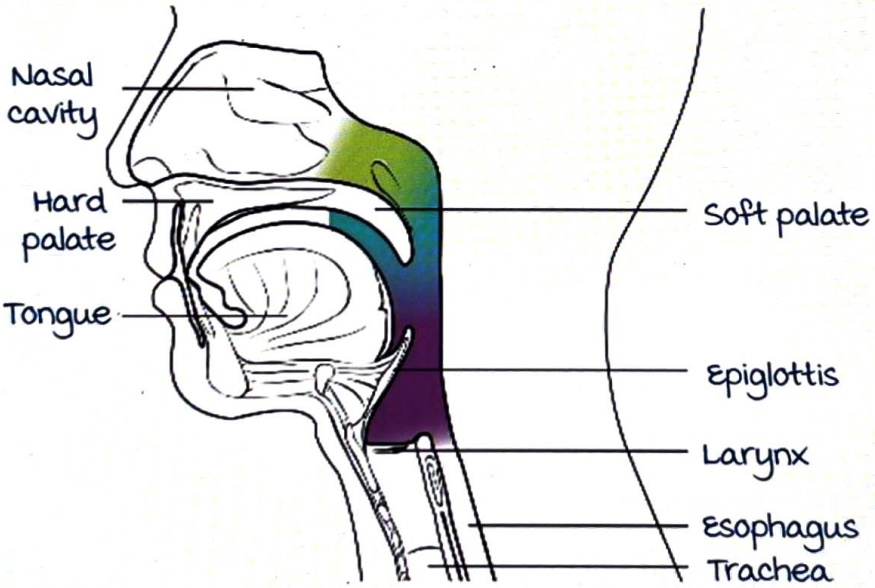

Structures :
Posterior wall of nasopharynx at the junction of roof and the posterior wall → Adenoid (collection of the lymphoid tissue).

Lateral wall of the nasopharynx :

- Opening of the Eustachian tube → 1.25 cm behind the posterior border of the inferior turbinate.
- Torus tubarius → It is the bulge which is produced by the cartilage of the eustachian tube posteriorly.

Active space

Leave Feedba

- Fossa of Rosenmuller/lateral pharyngeal recess → The fossa present behind Torus tubarius (MC site of origin of nasopharyngeal carcinoma).
- Sphenopalatine foramen :
  1. 1 cm behind the posterior end of the middle turbinate.
  2. This is the site of communication between the nose and the nasopharynx to the sphenopalatine fossa.
  3. Contents :
     a. Maxillary artery.
     b. Maxillary nerve.
     c. Sphenopalatine ganglion.
  4. It is the MC site of origin of angiofibroma.

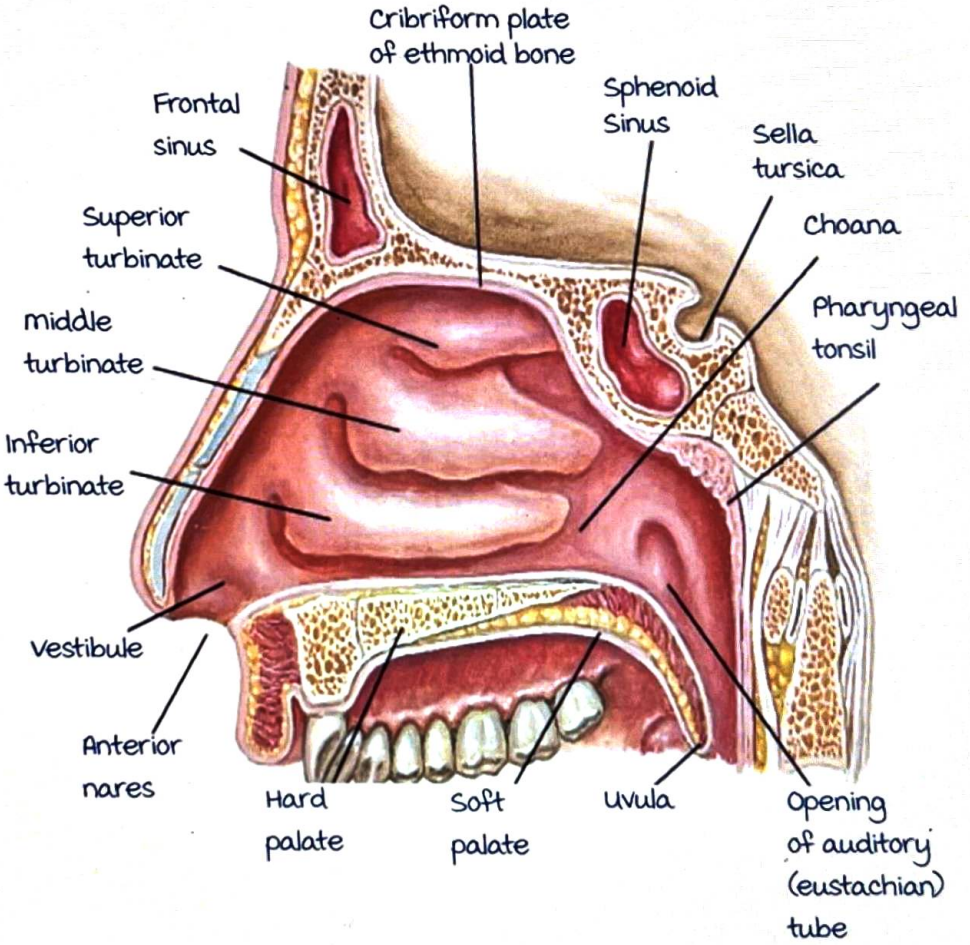

Adenoid hypertrophy (midline structure) → B/L obstruction of the Eustachian tubes causing B/L CSOM.

Nasopharyngeal carcinoma → U/L obstruction of eustachian tube causing U/L CSOM as carcinoma arises from lateral wall.

Adenoids start to atrophy by puberty and disappear by 20 years of age.

Infection from the nasopharynx can spread to the middle ear (AOM) through the opening of the ET.

Active space
60c6b3eeaa8ded0e4e7e5ea7

Leave Feedbac

Endoscopic pictures of the nasopharynx :

k.marankitindia1@gmail.com

Bilateral view

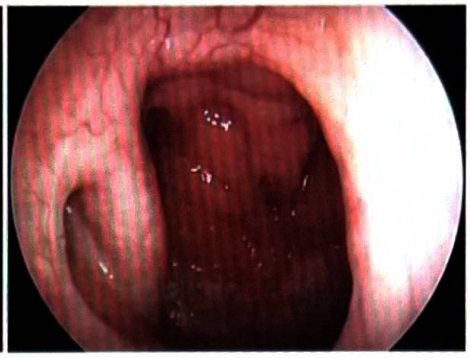

Right nasopharynx

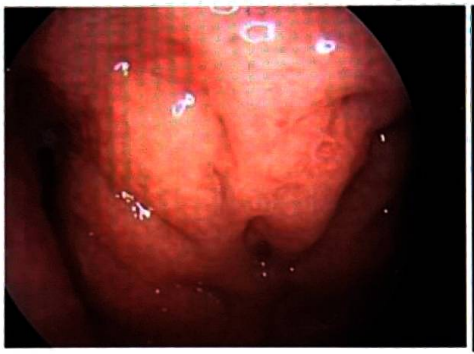

Fossa of Rossenmuller

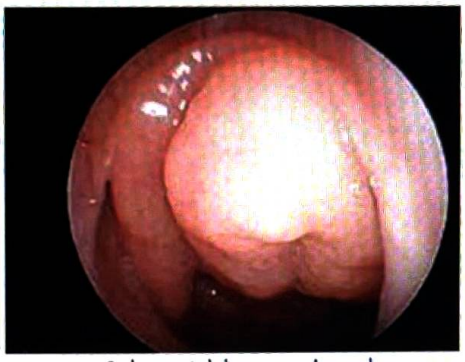

Adenoid hypertrophy

Eustachian tube

00:13:53

Openings :
Nasopharynx → 1.25 cm behind the inferior turbinate.
Middle ear (ME) → Anterior wall.
Cartilagenous → Medial 2/3rd part of (towards the nasopharynx).
Bony → Lateral 1/3 rd part of the (towards the ME).

Complete obstruction of the ET by adenoid

Function → Ventilation & drainage of secretions from the ME.
Isthmus → Narrowest part of the ET at the junction of the cartilagenous and the bony part.
Angle with horizontal = 45° (achieved by 6-7 years of age).
ET → Short and horizontal in children due to which AOM is MC in them.

Active space

Leave Feedbac

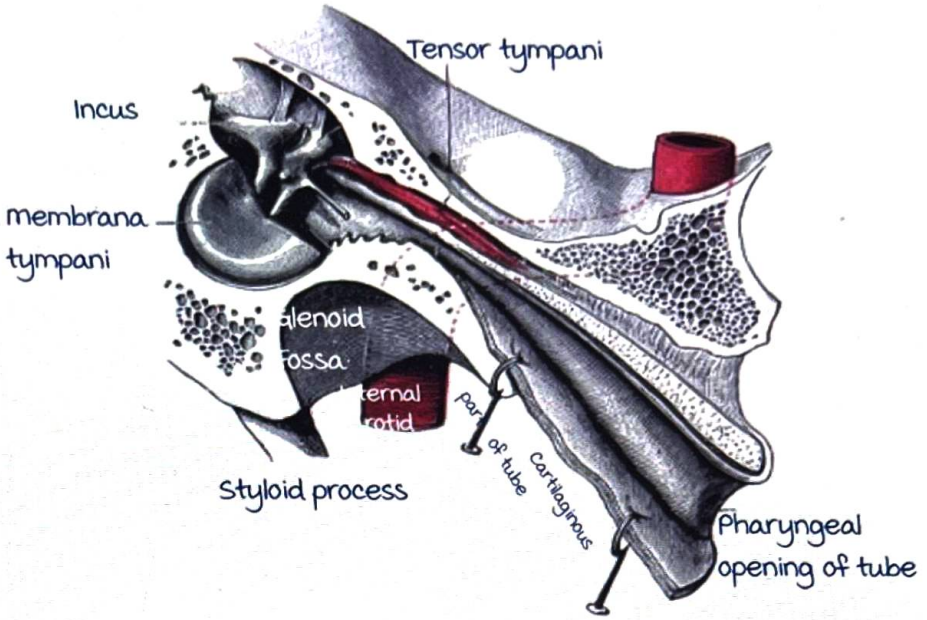

Sphenopalatine foramen and fossa

00:19:18

60c6b3eeaa8ded0e4e7e5ea7

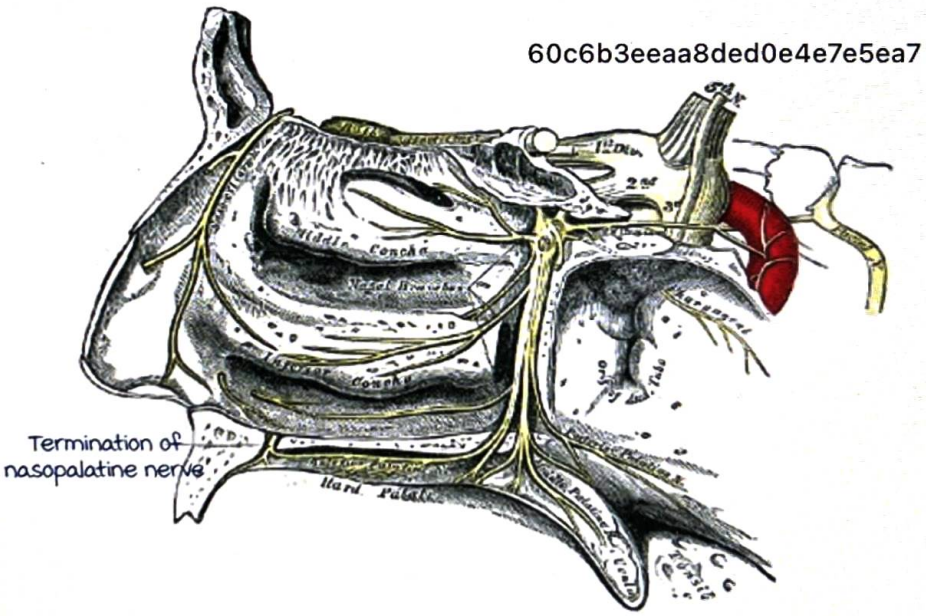

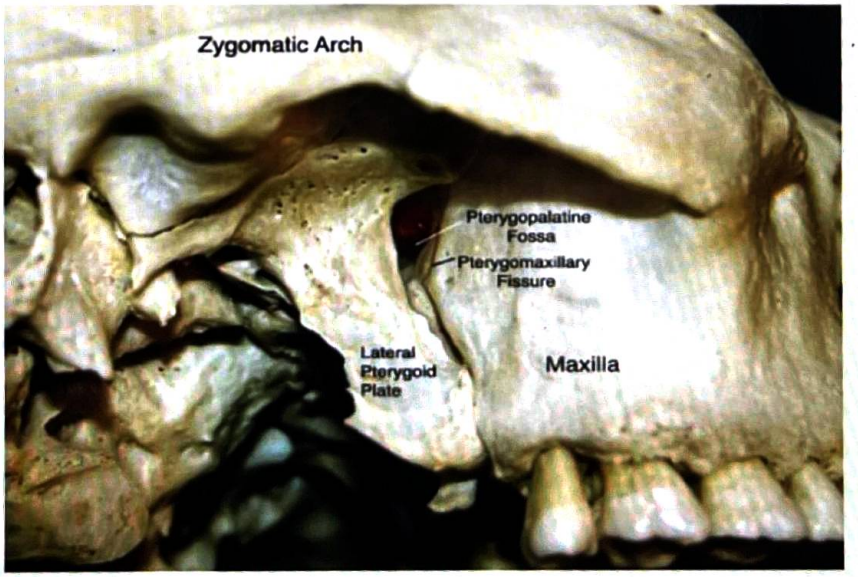

Active space

Posterior to the posterior wall of the maxillary sinus, from the base of skull, pterygoid plates are present which arise from the sphenoid bone above.

Boundaries of the sphenopalatine fossa :

- Anteriorly : Posterior border of the maxillary antrum.
- Posteriorly : Anterior border of pterygoid plate.
- Medially : Lateral wall of the nasopharynx.
- Laterally : Pterygomaxillary fissure through which it communicates with the infratemporal fossa.
- Superiorly : Base of skull.

Angiofibroma arises from the sphenopalatine fossa which can extend into :

- Anteriorly : Nasal cavity.
- Posteriorly : Nasopharynx.
- Laterally : Sphenopalatine fossa and infratemporal fossa.
- Superiorly : Orbit.

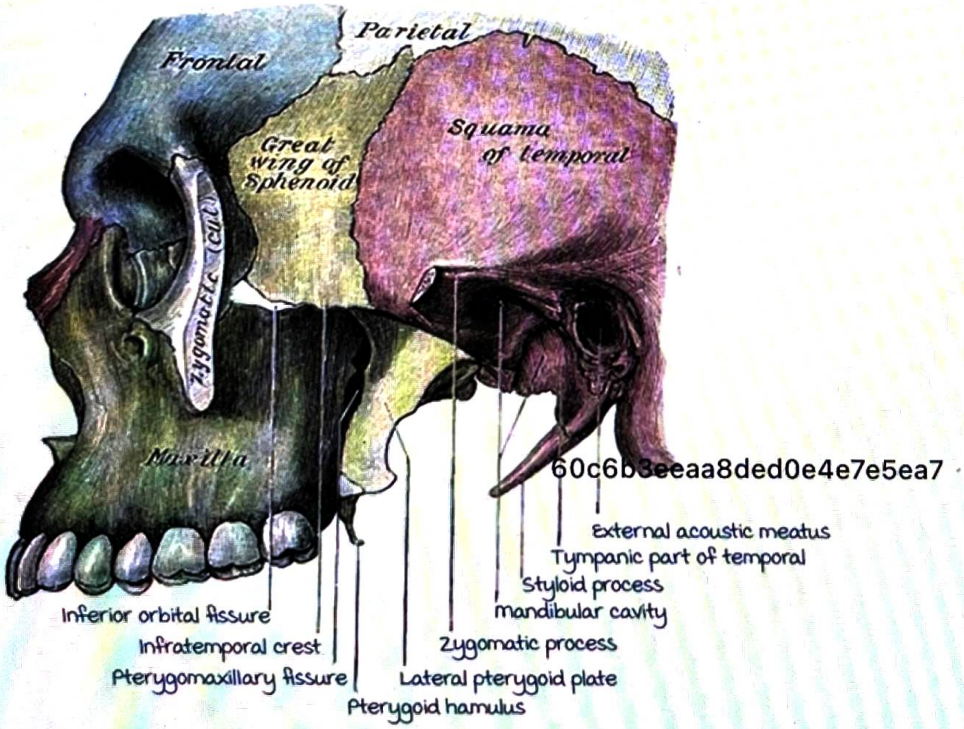

60c6b3eeaa8ded0e4e7e5ea7

Active space

Leave Feedbac

Axial CT cut-section at the level of the maxillary sinus :

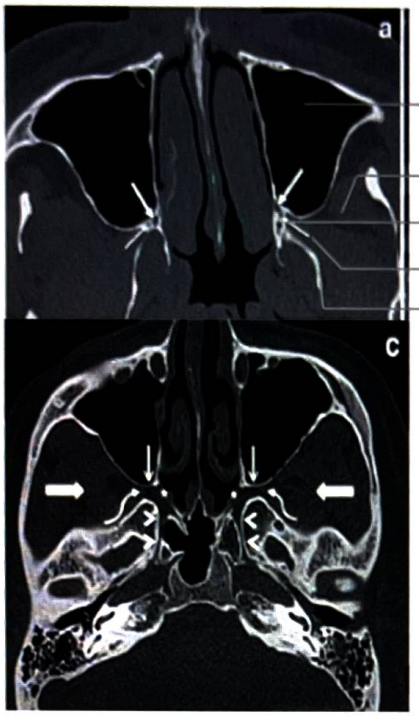

- Maxillary sinus
- Infratemporal fossa
- Sphenopalatine fossa
- Pterygopalatine fissure
- Pterygoid plates

Posterior rhinoscopy

00:27:46

By St. Clair Thompson post-nasal/ posterior rhinoscopy mirror.

Used to visualize the nasopharynx.

It is held like a pen and passed from over the tongue to back of the uvula.

kumarankitindia1@gmail.com

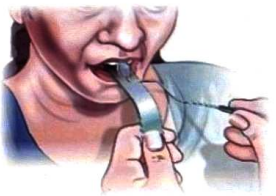

It has two bends to prevent touching the tongue and the uvula.

It is used along with tongue depressor.

Structures seen on posterior rhinoscopy :

- Posterior end of the turbinates.
- Adenoids.
- Eustachian tube openings.
- Torus tubarius.
- Fossa of Rosenmuller.

Posterior rhinoscopy

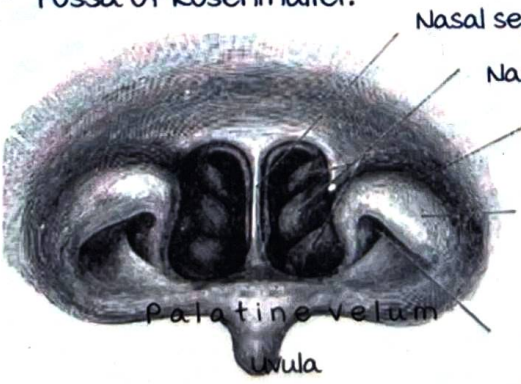

- Nasal septum
- Nasal conchae
- Pharyngeal recess
- Torus of auditory tube
- Pharyngeal ostium of auditory tube

Active space

Leave Feedba

Endoscopic appearance of the nasopharynx 00:30:05

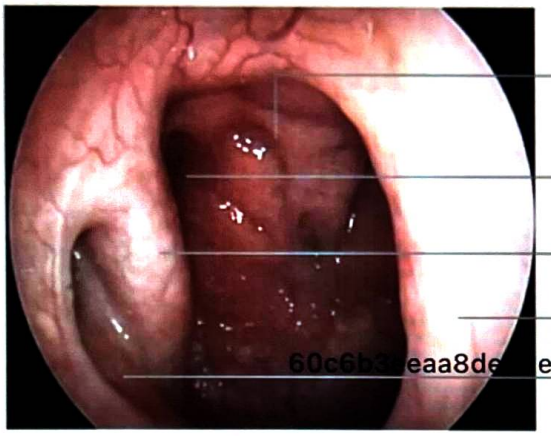

Right nostril

The muscles of Eustachian tube, tensor palati and levator palati also supply the palate. So, the ET orifice moves along with the movement of the palate.

The palate meets the posterior pharyngeal wall on swallowing to prevent the entry of food particles into the nasopharynx.

Oropharynx 00:31:33

Boundaries :

- Superiorly → Hard Palate.
- Posteriorly → C2 and upper part of C3.
- Inferiorly → Till hyoid bone.

Structures :

Active space

Leave Feedba

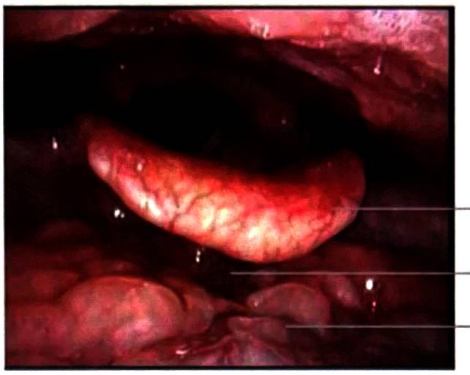

Anterior pillar and the posterior pillars of the oropharynx extend from the palate to the tongue.

Anterior pillar is formed by the Palatoglossus muscle (only muscle of the tongue which is supplied by the pharyngeal plexus).

Posterior pillar is formed by the palatopharyngeus muscle (longitudinal muscle of the pharynx).

Longitudinal muscle of the pharynx :

- Stylopharyngeus.
- Salpingopharyngeus.
- Palatopharyngeus.

Passavant's ridge

00:34:38

Formed by the fusion of the circular fibres of Palatopharyngeus muscle and the Superior constricter muscle (circular muscle at the level of tonsils).

Clinical significance → Soft palate meets the Passavant's ridge and closes the nasopharyngeal isthmus to prevent the entry of food into the nasopharynx.

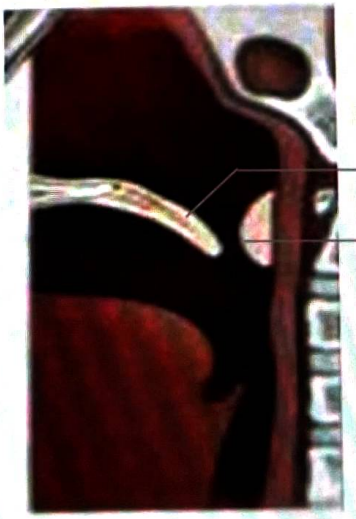

Active space

Leave Feedback

Velopharyngeal insufficiency :

- Inability of the soft palate to meet the Passavant's ridge.
- Presents with nasal regurgitation of food and water.
- Nasal words (ma, na, ga) pass through the nose for nasal resonance.
- Rest of the words which do not need to pass through the nose are prevented from passing the nose due to the closure of nasopharyngeal isthmus by approximation of the soft palate and the Passavant's ridge.
- Presents with hypernasal voice/rhinolalia aperta.

Causes :

- Palatal palsy (palsy of vagus nerve).
- Cleft palate.
- Submucous cleft (Cleft in the palate which felt only on palpation).

Obstruction of nose leads to loss of nasal resonance of the nasal words and presents with hyponasal voice/rhinolalia clausa.

Causes :

- Adenoid hypertrophy.
- Nasopharyngeal carcinoma.
- Angiofibroma.
- B/L nasal polyps.

Hypopharynx/laryngopharynx

60c6b3eeaa8ded0e4e7e5ea7 00:44:36

It is located behind the oropharynx and behind the larynx.

Boundaries :

- Superiorly : Hyoid bone.
- Inferiorly : Lower border of cricoid cartilage.
- Posteriorly : C3, C4, C5, C6 vertebrae.

Components (mnemonic : 3 P's) :

- Post cricoid.
- Pyriform fossa .
- Posterior pharyngeal wall.

Active space

Leave Feedbac

Epiglottis → Arises from the midline of thyroid cartilage.
Aryepiglottic folds → mucosal folds which extend from the sides of the epiglottis to the arytenoids.
Arytenoids are located on top of the cricoid cartilage.
Posterior to the cricoid is the hypopharynx.

Pyriform fossa → The fossa formed by the mucosal folds which separate the larynx and the hypopharynx laterally on both the sides of the larynx.

During swallowing, epiglottis closes the inlet of the larynx and prevents the aspiration of food particles into the larynx.

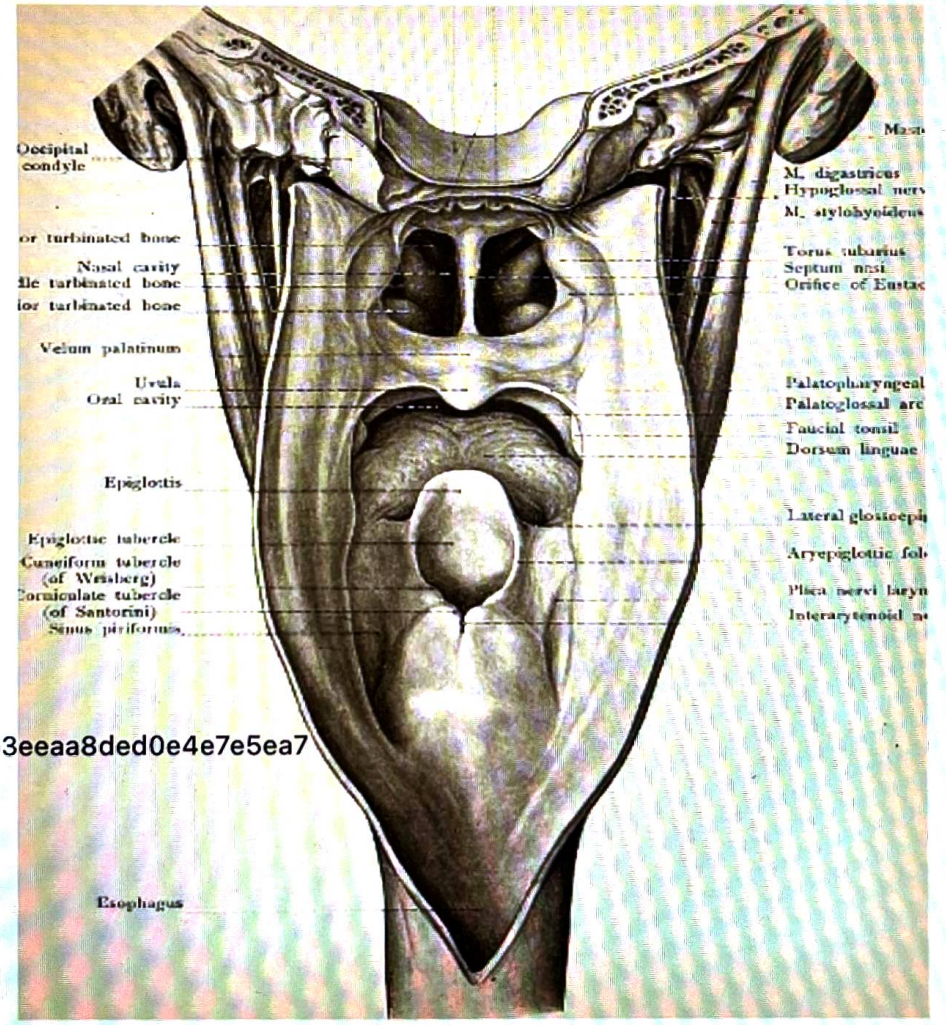

60c6b3eeaa8ded0e4e7e5ea7

Active space

Leave Feedbac

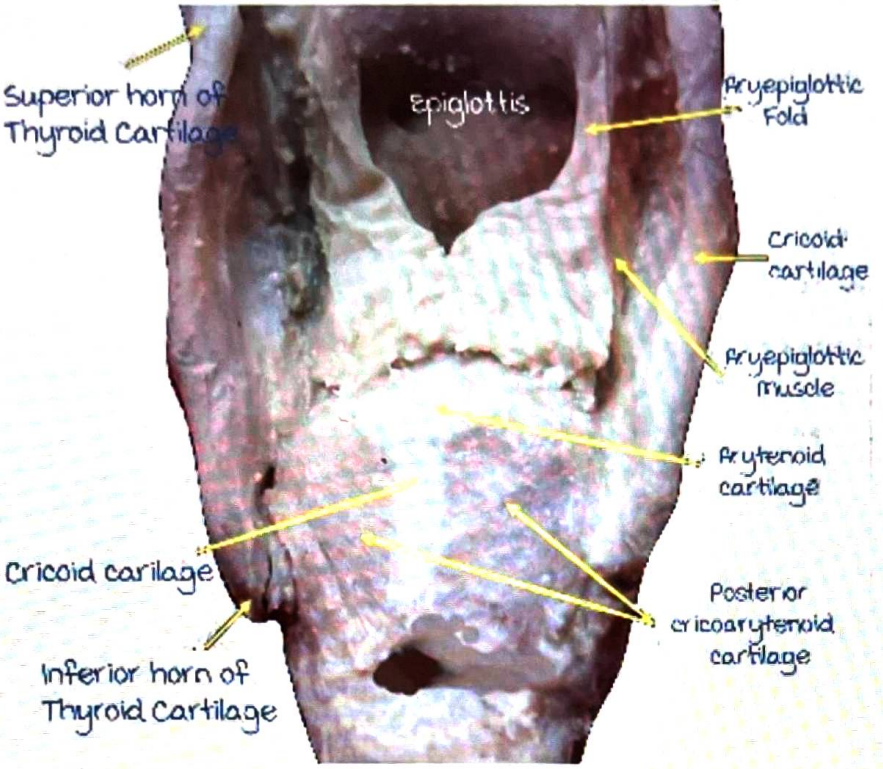

Endoscopic appearance of hypopharynx :

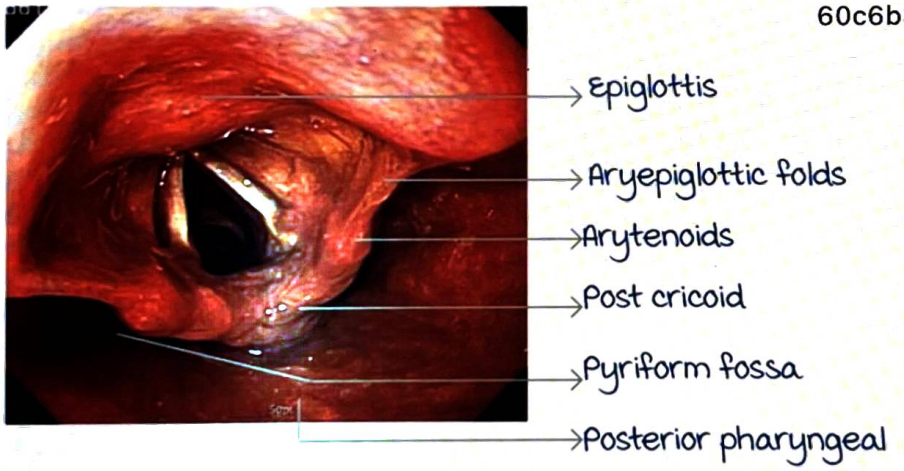

60c6b3eeaa8ded0e4e7e5ea7

Pyriform fossa is AKA smuggler's fossa.

- Lateral channel for the passage of food.
- It is the mc site of lodgment of foreign body in the hypopharynx.

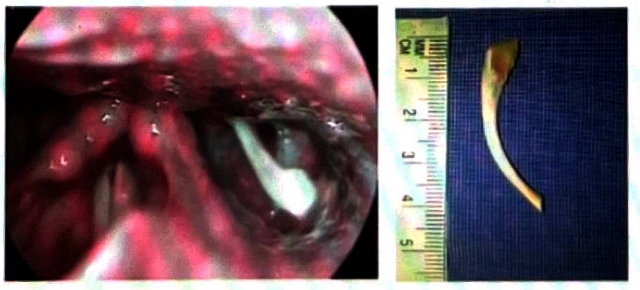

Foreign body in pyriform fossa

Active space

Leave Feedba

Overall m/c site of lodgment of foreign body → Tonsillar fossa.

2nd mc site overall → Vallecula.

3rd mc site overall → Pyriform fossa.

Chevalier Jackson's sign :

Pooling of saliva in the pyriform fossa/postcricoid area.

It is an indication for hypopharyngeal carcinoma.

Postcricoid is the mc site affected in females suffering from Plummer Vinson syndrome.

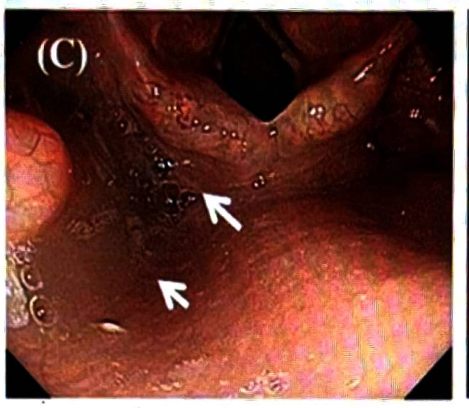

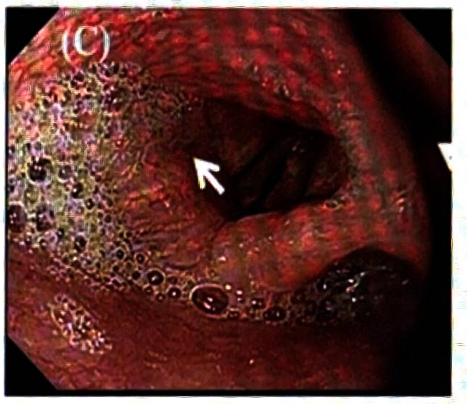

Internal laryngeal nerve (branch of the superior laryngeal nerve) → Sensory supply of the upper part of the larynx and the hypopharynx.

It passes in between the middle constrictor and the inferior constrictor muscles and lies superficially in the pyriform fossa.

Clinical significance → Local anaesthesia can be given either externally/internally (at the pyriform fossa) to take the biopsy for diagnosing carcinomas.

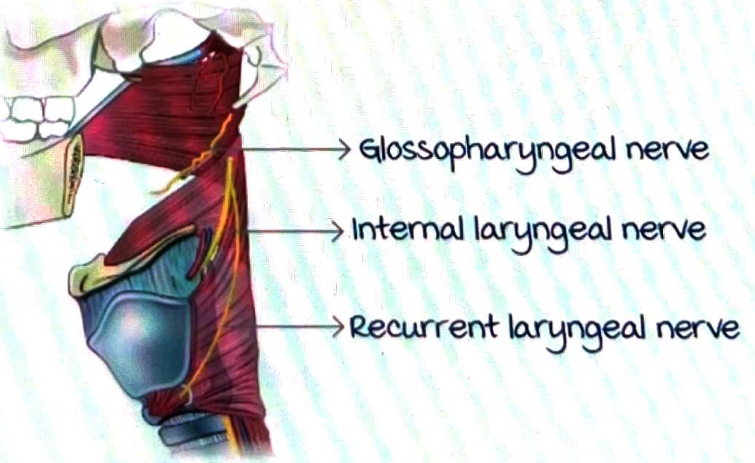

Active space

Leave Feedbac

Indirect laryngoscopy mirror 01:01:41

To visualise the larynx and hypopharynx.

Procedure :

Tongue is pulled anteriorly and IL mirror is pressed against the uvula to visualize the larynx and hypopharynx.

It is held like a pen.

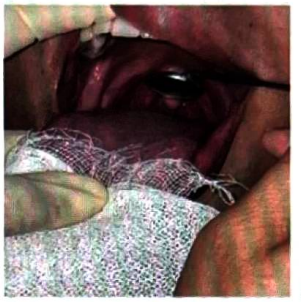

Instruments in ENT which are held like a pen :

- Posterior rhinoscopy mirror.
- Indirect laryngoscopy mirror.
- Otoscope.
- Mastoid drill.

Nerve supply of the pharynx 01:05:51

Sensory supply :

Nasopharynx → Branches of maxillary nerve (from the sphenopalatine ganglion).

Oropharynx :

- Glossopharyngeal nerve (enters the pharynx by passing in between the superior constrictor and the middle constrictor muscles).
- Soft palate : Lesser palatine nerve.

Hypopharynx :

kumarankitindia1@gmail.com

- Upper part → Internal laryngeal nerve (between the middle constrictor and the inferior constrictor).
- Lower part → Recurrent laryngeal nerve (between inferior constrictor and esophagus).

Motor supply :

All pharyngeal and palatal muscles → Pharyngeal plexus (formed by the 9th, 10th cranial nerves and the superior cervical ganglion). Motor supply by 10th.

Active space

Leave Feedbac

Except in :

- Pharynx → Stylopharyngeus muscle is supplied by glossopharyngeal nerve.
- Soft palate → Tensor palati muscle is supplied by the mandibular nerve.
- Additional nerve supply of inferior constrictor (Thyropharyngeus + Cricopharyngeus) → Recurrent laryngeal nerve.

Lymphatic drainage of the pharynx 01:12:34

- Nasopharynx → Retropharyngeal lymph nodes of Rouviere which drain into to the upper deep cervical lymph nodes.
- Oropharynx → Upper/tonsillar node, middle, lower deep cervical lymph nodes.

MC infectious cause of the enlargement of the upper deep cervical lymph nodes → Tonsillitis.

- Hypopharynx → Upper, middle and lower deep cervical.

Pyriform fossa has richest lymphatic supply.
Pyriform fossa carcinomas usually present with neck nodes.

Active space

kumarankitindia1@gmail.com

411
Leave Feedba

ADENOID HYPERTROPHY

Adenoids

00:00:46

Group of Mucosa Associated Lymphoid Tissue (MALT).
Collection of subepithelial lymphoid tissue present in nasopharynx (at site of entry of antigens).
Component of Waldeyer's ring.
Present at birth.
Grows up till 7 years of age, after which growth plateaus.
At puberty (12 years) starts to atrophy and disappears by 20 years of age.
Produce immunity & immunological memory.
Provides local as well as systemic immunity to child.

60c6b3eeaa8ded0e4b7e5ea7

Number : Single adenoid but multiple like appearance because of presence of vertical ridges.

Epithelial lining : Ciliated columnar pseudostratified epithelium.
No capsule.
Crypts are absent.
Lymphatic drainage : Retropharyngeal lymph nodes ⟶ Upper deep cervical nodes.
Blood supply :

- Maxillary artery.
- Ascending pharyngeal artery.
- Facial artery.

Adenoid hypertrophy

00:09:38

Gets hypertrophied in response to allergens or infection.
Ultimately obstructing the whole nasopharynx.
Hence main symptoms are obstructive.

Active space

Leave Feedba

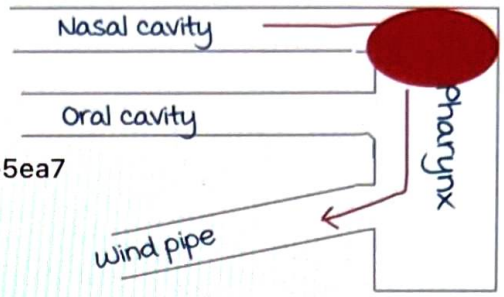

60c6b3eeaa8ded0e4e7e5ea7

1. Nasal obstruction :

Leads to adenoid facies.

Nose :

- Undergoes disuse atrophy.
- Absence of nasolabial crease.
- Pinched up appearance.

Mouth :

- Mouth breathing.
- High arched palate.
- Anterior crowding of teeth.

Dull look on face :

- Obstructive mass also blocks eustachian tube resulting in serous otitis media and cause hearing impairment.

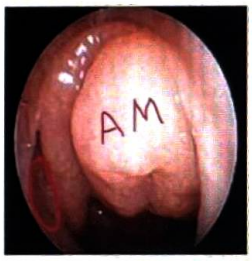

2. Sleep apnoea : Cessation of breathing for atleast 10 s ; > 30 apnoeic episodes/7 hours of sleep or > 5 episodes/hour.

Parents complain of daytime dozing.

Sleep apnoea (hypoxemia) ⟶ Decreased oxygen ⟶ Leads to pulmonary vasoconstriction ⟶ Pulmonary hypertension ⟶ Right sided heart failure (cor pulmonale).

3. Rhinolalia clausa: Hyponasal voice due to nasal obstruction

Normal nasopharynx

Blocked nasopharynx

Active space

Hypertrophied adenoids act as a reservoir of infection due to collection of undrained nasal secretions.

4. Recurrent sinusitis.
5. Recurrent acute otitis media.

Failure to thrive : Growth of child will not be according to optimum standards.

Acute adenoid hypertrophy 00:22:22

Only clinical diagnosis is necessary.

Treatment :

- Anti allergics.
- Nasal/oral decongestants.
- Nasal steroid spray.

Chronic adenoid hypertrophy is when adenoid do not regress. It can lead to cardiovascular complications. Hence, to prevent chronicity, proper assessment of adenoid size & nasopharynx is required.

Diagnosis :

1. Endoscopy : Best investigation.

Grading:

- Grade I : 1/3rd of choana is obstructed.
- Grade II : 1/3-2/3rd obstruction.
- Grade III : 2/3rd to nearly complete obstruction.
- Grade IV : Complete obstruction.

2. X-ray :

kumarankitindia1@gmail.com

Usually done in uncooperative child.
Lateral view of nasopharynx done.
grade can also be assessed by x ray.

Antrochoanal polyp v/s adenoids :

Crescent sign :

- Positive in antrochoanal polyp.
- Crescent of air present between pharyngeal wall and antrochonal polyp.
- Negative in adenoids.

Active space

Leave Feedba

Management of chronic adenoid hypertrophy :

Medical management :

- Anti allergics.
- asal decongestants.
- Nasal steroid spray.

Crescent sign

Surgical management :

If medical management fails even 2-3 months of medical management.

Adenoidectomy ± tonsillectomy ± grommet insertion (most will have serous otitis media).

60c6b3eeaa8ded0e4e7e5ea7

Adenoidectomy

00:33:44

Indication :

- Sleep apnoea.
- Chronic serous otitis media.
- Recurrent sinusitis.
- Recurrent acute otitis media.
- Dental malocclusion.

Surgery :

Done under general anesthesia.

Position of patient :

Rose position : Extension at the cervico throracic joint & atlanto-occipital joint.

Larynx positioned at a higher level, while the site of surgery at lower level.

Rose position used in surgeries like :

- Adenoidectomy,
- Tonsillectomy.
- Tracheostomy.

To get better access for surgery, oral cavity approach is used.

Site of surgery is reached through oral cavity from behind the soft palate.

Mouth kept open for surgery using :

Active space

- Boyle's tongue blade.
- Davis mouth gag.



Tongue blade is articulated with davis mouth gag.

Tongue blade : Depress tongue.

60d6b3eeaa8ded0e4e7e5ea7

Mouth gag : Keep the teeth (upper jaw) up.

Draffin bipod stand with plates :

Used to keep mouth gag in position.

Draffin bipod with stand

Draffin bipod

Boyle tongue blade

Davis mouth gag

After positioning, palpate adenoid to :

- Medialise the adenoids.
- Look for aberrant vasculature (aberrant ICA present medially & gone to retropharyngeal space).

Curettage of adenoids :

Curette is passed behind the palate into the nasopharynx, then adenoid is engaged and by sweeping movements, adenoid is curetted out.

St. Clair Thomson adenoid curette :

- Held like a dagger.
- Blind curettage is performed.

Active space

Leave Feedba

St Claire Thomson adenoid curette

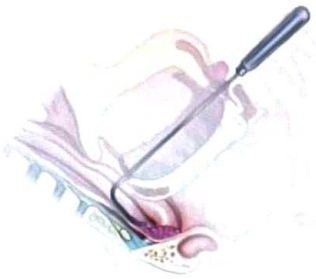

Endoscopy guided curettage :
Used nowadays.

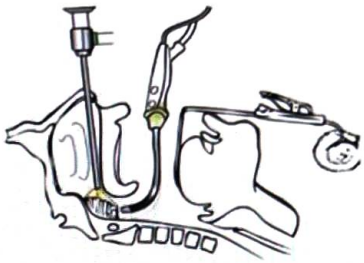

Microdebridement of adenoids :
Done using microdebrider.

Microdebrider

Methods of adenoidectomy 00:45:43

1. Cold method :
   Heat is not produced.
   Curettage, microdebrider.
2. Hot method : Cutting & coagulation done at the same time.
   Heat produced.
   Monopolar cautery/diathermy.
   coblation (cold ablation : heat produced is less than cautery.

Coblation wand

Post adenoidectomy :

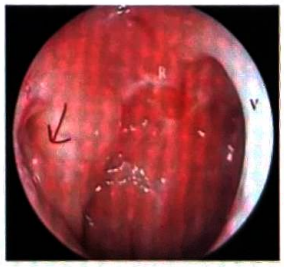

Edematous ET, child take some time to symptomatically recover.
Grommet is inserted

Active space
kumarankitindia1@gmail.com

Contraindications of adenoidectomy :

- Acute infections.
- Bleeding diasthesis.
- Velopharyngeal insufficiency (cleft palate) :
  Failure of soft palate to close against the posterior pharyngeal wall.

Results in :

Hypernasal voice.

Nasal regurgitation of food.

In children with hypertrophied adenoids, it blocks cleft and there won't be any symptoms of velopharyngeal insufficiency.

Post adenoidectomy, child manifests symptoms.

Inspect & palpate to rule out cleft palate.

In the presence of cleft palate, repair the cleft first and then perform adenoidectomy.

Complications following adenoidectomy 00:52:55

1. Hemorrhage :
   Adenoidectomy done before tonsillectomy since it's a blind space surgery.
   Doing adenoidectomy first, will ensure enough time to achieve and confirm hemostasis.

Coroner's clot :

Occult blood clot in the nasopharynx formed after surgery.

Has the potential to cause laryngeal obstruction following extubation.

Prevention : Proper suction done after removing packing

60c6b3eeaa8ded0e4e7e5ea7

2. Unmasking of features of velopharyngeal insufficiency.
3. Eustachian tube injury (excess curetting laterally).
4. Grisel syndrome :
   Atlanto axial dislocation.
   Non traumatic.
   Occurs because of _____
   _____
   Lead to painful neck movements.
   Torticollis (head tilted to one side).

Active space

Leave Feedbac

Management of Grisel syndrome :

- Anti inflammatory drugs.
- Neck immobilisation.
- Rarely neurosurgical intervention.

Thornwaldt's bursa

01:01:16

Also known as pharyngeal bursa.

Remnant of the connection between primitive pharynx & notochord.

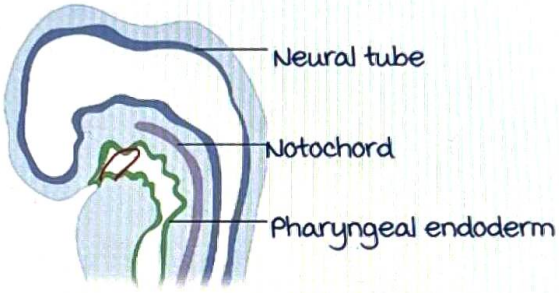

Persists as a pouch.

Present at the same site of adenoids.

60c8b3eeaa8ded0e4e7e5ea7

Pouch gets infected due to secretions collected in the pouch.

Can lead to :

Persistent post nasal drip.

Occipital headache.

Cyst formation due to block
(Visualised under MRI or CT scan).

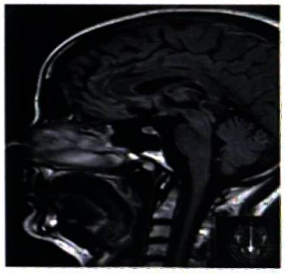

Management :

Antibiotics.

Excision of cyst if formed.

Marsupialisation :

Cyst is opened and edges sutured, forming a continuous surface (open pocket).

Active space

419
Leave Feedba

ANGIOFIBROMA

Juvenile nasopharyngeal angiofibroma.

Most common benign tumour of the nasopharynx.

60c6b3eeaa8ded0e4e7e5ea7

It is locally invasive tumour.

Starts at puberty.

Exclusively in males.

The tumour does not have a true capsule, although the epithelium lining thickens to form a psuedocapsule.

It arises from the sphenopalatine foramen. (1 cm posterior of the middle turbinate).

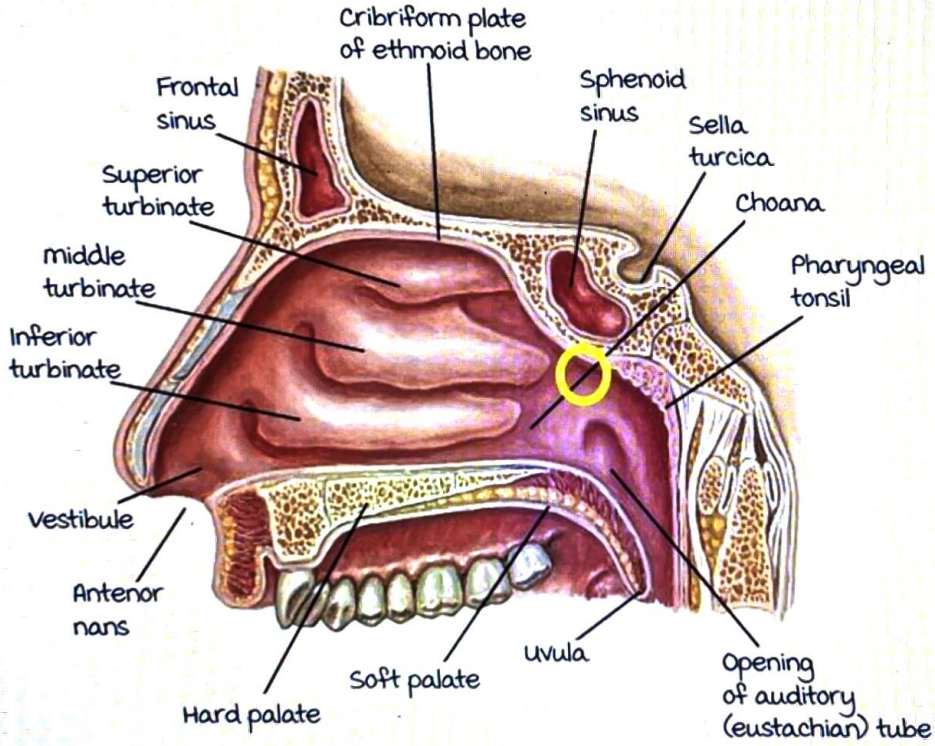

Etiology :

Angiofibroma is a vascular malformation that develops in people with :

- Incomplete regression of first arch artery remanent (primitive form of maxillary artery and the branches pass through the sphenopalatine fossa).
- Hormonal : Androgenic stimulation.

The vessels that form the tumour is also malformed (have

Active space

Leave Feedbac

a very thin endothelial lining, the muscular component is missing). Therefore, prone to rupture and bleeding.

Sphenopalatine foramen & sphenopalatine fossa 00:06:57

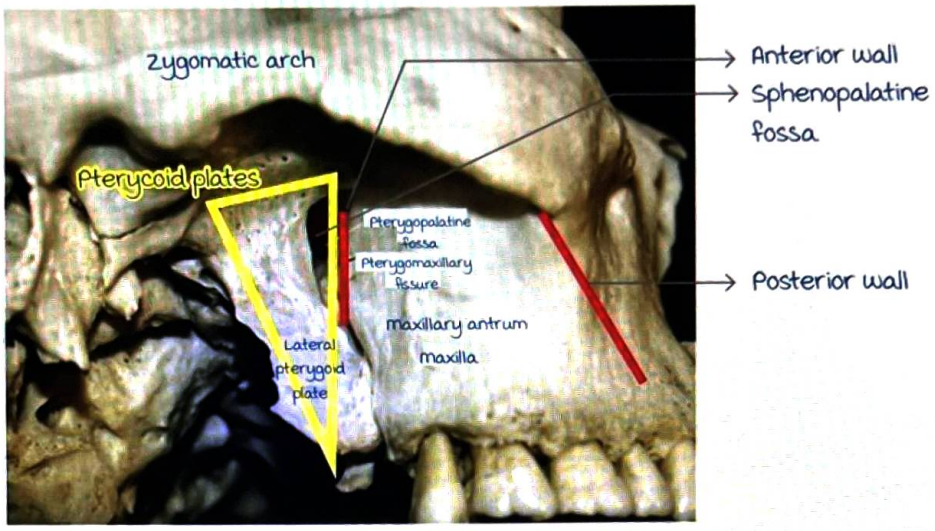

Anteriorly : Maxillay sinus

Posteriorly : Pteregoid plates.

Lateral boundaries : Infratemporal fossa through Pterygomaxillary fissure.

60c6b3eeae8ded0e4e7e5ea7

Medial boundaries : Lateral wall of nasopharynx.

Vessels in the fossa : maxillary artery, maxillary nerve, sphenopalatine ganglion (they also supply the nasopharynx after entering the foramen).

Sphenopalatine foramen is 1 cm behind the posterior end of middle turbinate in the nasopharynx.

The foramen is also the most common site of origin of angiofibroma.

Once the angiofibroma arises from the foramen,

If it grows medially it can invade the nasopharynx and nasal cavity.

If it grows laterally it can invade the sphenopalatine fossa and from there it goes superiorly & it invades the the orbit.

Posteriorly through the pterygoid plates, it can go intracranially.

Laterally, it can go through the pterygomaxillary fissure into the infratemporal fossa.

Active space

Leave Feedback

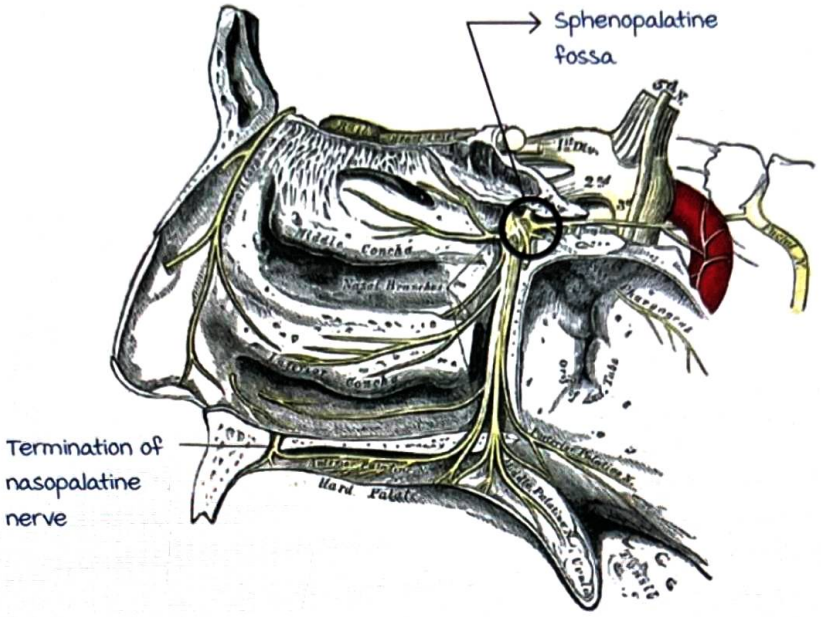

Initially the tumour will be in the nasopharynx.

Although the tumour is small, the vasculature is prone to rupture on the smalless triggers (forceful respiration).

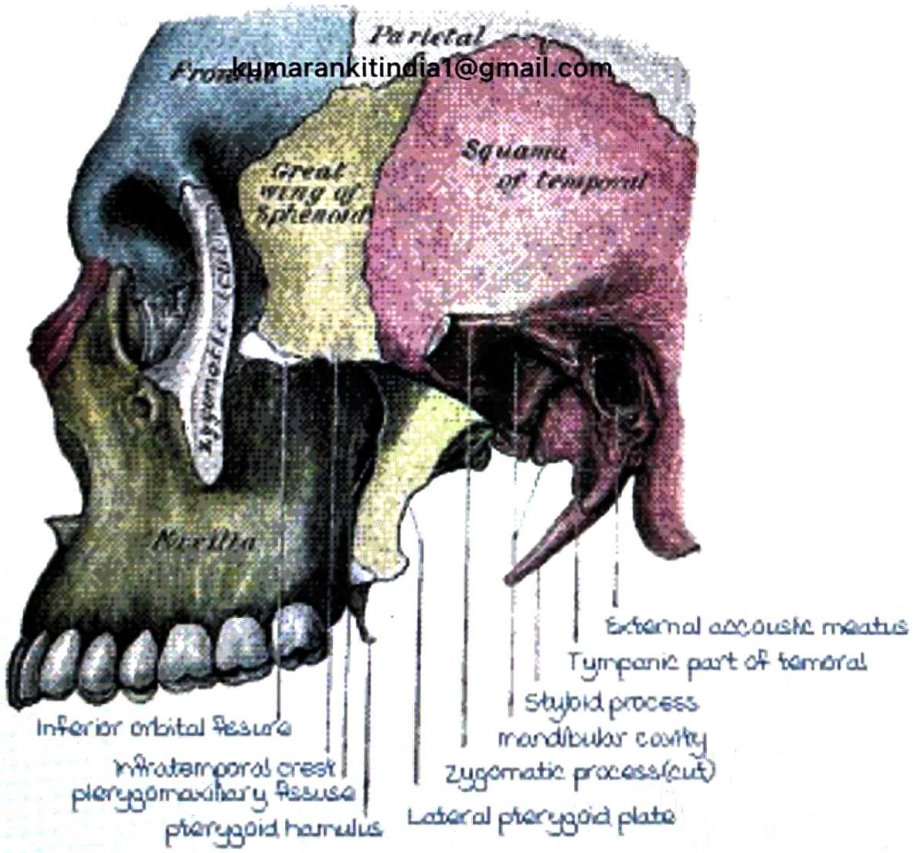

kumarankitindia1@gmail.com

Presenting complaint is recurrent epistaxis (because the vessels do not have muscular contractile component)

When angiofibroma is suspected, digital palpation and biopsy should not be done .

Active space

Leave Feedbac

When it grows further, it enters the nasal cavity leading the nasal obstruction (unilateral).

When the mass grows in the nasopharynx it can compress the Eustachian tube leading to serous otitis media.

Obstruction of the nasopharynx, the patient will have hyponasal voice (clausa).

When the tumour grows laterally in the sphenopalatine fossa it pushes the posterior wall of maxillary antrum anteriorly and pterygoid plate posteriorly. Hence the fossa will widen. Then it will grow into infratemporal fossa causing swelling of cheek.

When the tumour grows antero-superiorly, it enters the orbit to cause proptosis.

All these features give the appearance of frog facies (proptosis, cheek swelling, broadening of nose).

Superiorly it grows into the intracranial cavity through the natural openings/foramen such as :

- Foramen rotundum, which is the opening through which the maxillary nerve comes from the brain into the sphenopalatine fossa.
- Vidian canal.
- Superior orbital fissure.
- Sphenoid sinus.
- Roof of the middle cranial fossa.

60c6b3eeaa8ded0e4e7e5ea7

Invasion into the fissures can lead to multiple cranial nerve palsies.

Active space

Leave Feedba

Routes of intracranial spread

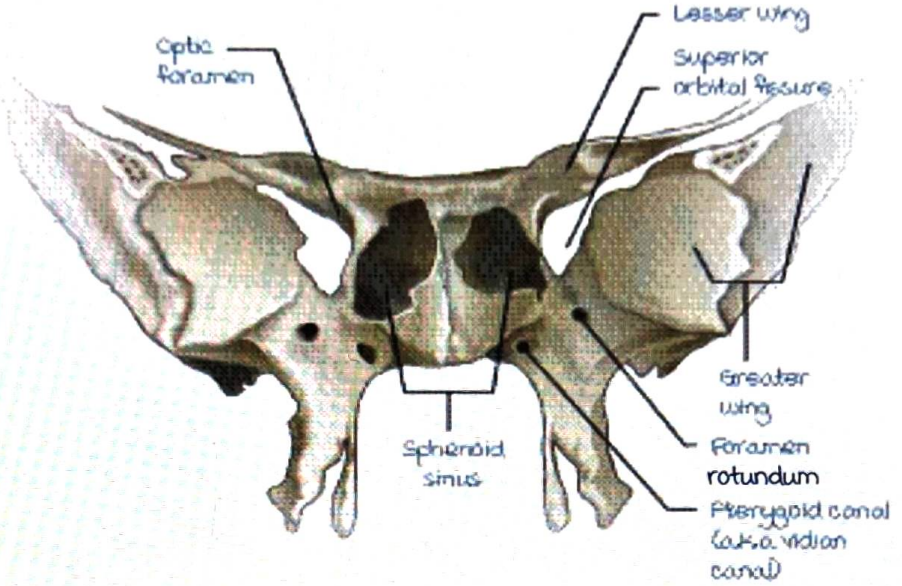

Nasal endoscopy :

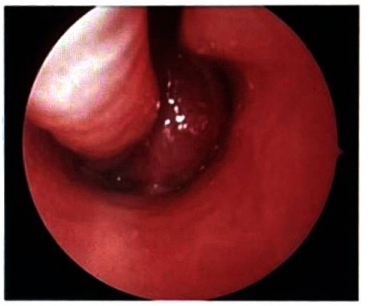

If the mass cannot be seen, and suspicion is high endoscopic visualisation is preferred.

A red vascular fleshy mass can be seen.

Biopsy is contraindicated due to the risk of bleeding.

The angiofibroma has a rich vascular supply mainly from the maxillary artey.

Confirmation can be done by Contrast enhanced CT/CECT (to see if the tumour is vascular)

60c6b3eeaa8ded0e4e7e5ea7

Normal Sphenopalatine foramen and fossa

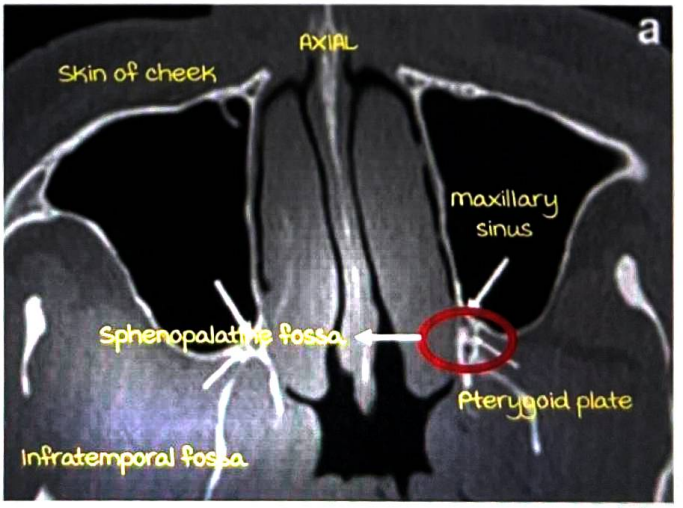

Pterygo- palatine/ sphenopalatine fossa

Active space

Leave Feedba

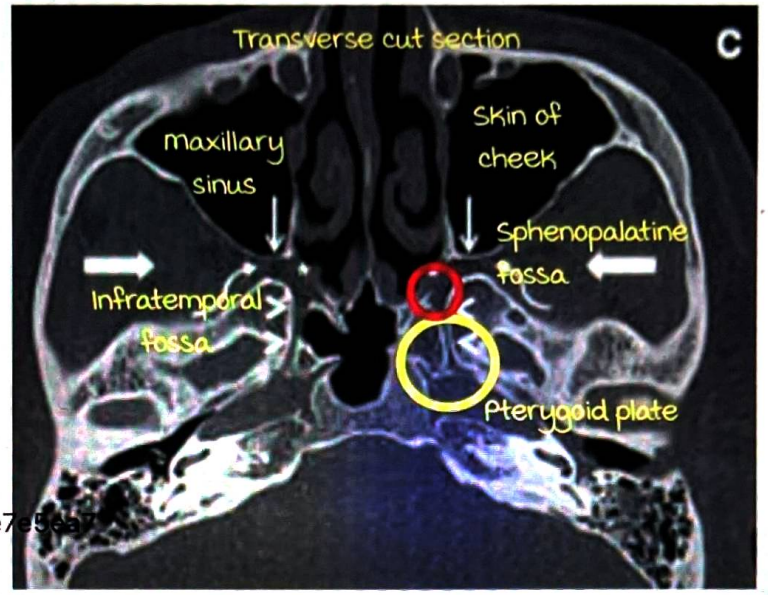

60c6b3eeaa8ded0e4e7e5e6

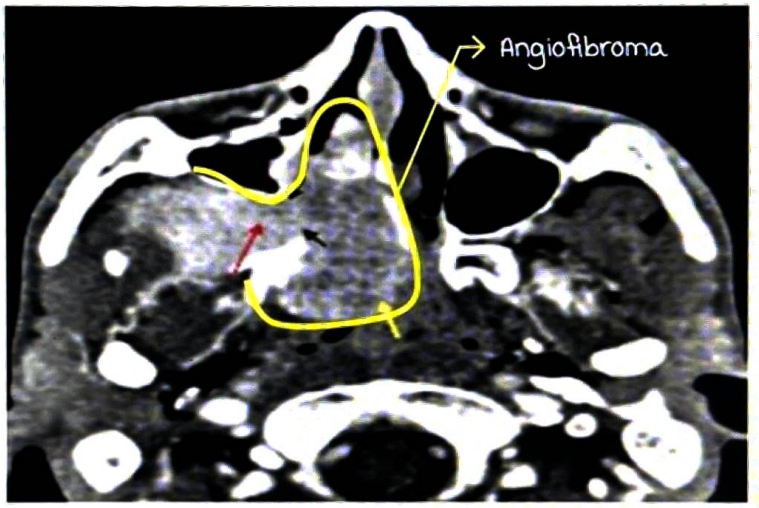

Here an enhancing mass in the nasal cavity going back into the nasopharynx, arising from the sphenopalatine foramen area. It has pushed the posterior wall of maxillary sinus anteriorly and the pterygoid plate posteriorly. It has then gone laterally to invade the infratemporal fossa.

The hallmark sign seen on CT is the Holman miller sign/ Antral sign.

The CT will also help to stage the disease.

Radkowski classification

00:24:10

Stage	Description
I	medial spread

Active space

Leave Feedba

IA	Involvement limited to the nose and/ or nasopharynx
IB	Extension into one or more sinuses
II	Lateral spread
IIA	Minimal extension into the sphenopalatine fossa
IIB	Occupation of the entire sphenopalatine fossa with or without erosion of the orbital apex
IIC	Involvement of the infratemporal fossa with or without extension to the cheek or posterior to the pterygoid plates
III	Intracranial spread
IIIA	Erosion of the skull base (the middle cranial fossa/base of the pterygoids); limited intracranial extension
IIIB	Erosion of the skull base; extensive intracranial extension with or without cavernous sinus invasion.

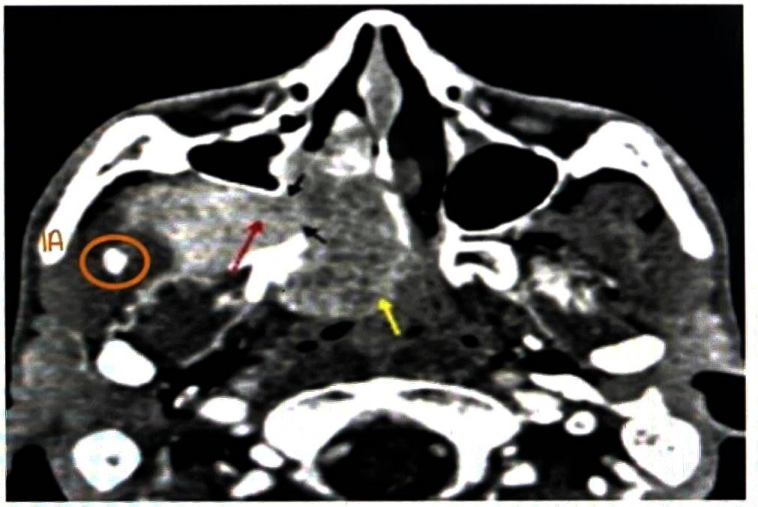

Active space

Leave Feedba

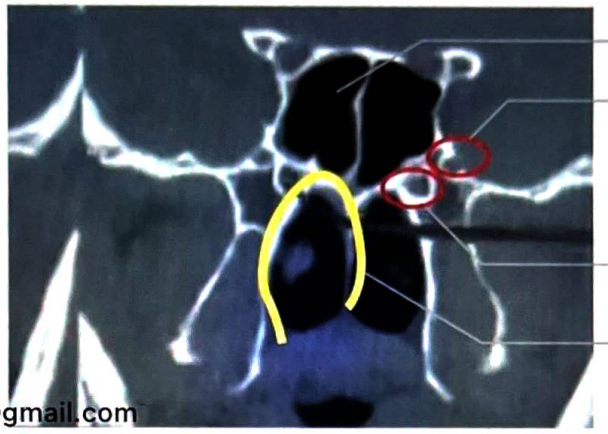

kumarankitindia1@gmail.com

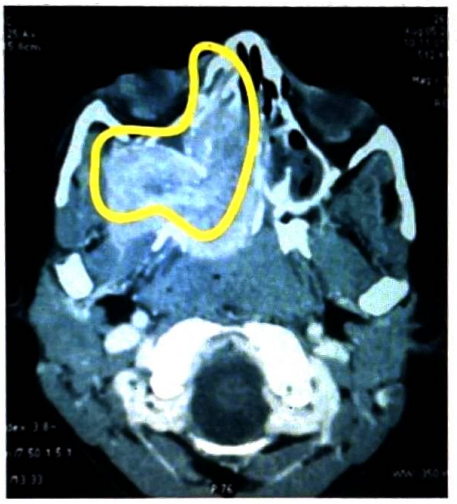

Tumour has gone into nasal cavity, sinus and laterally.
Stage : 2C

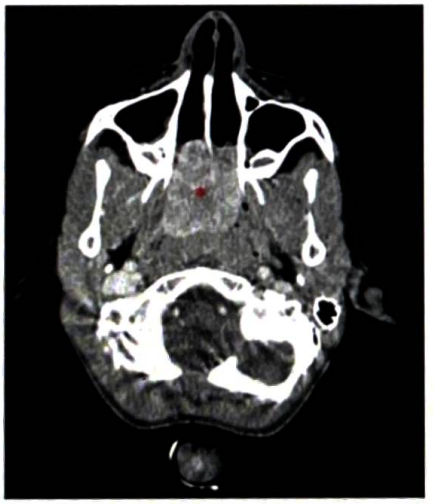

Tumour is in nasal cavity & nasopharynx
Stage : 1A

Modalities of treatment :

Hormonal therapy with anti-androgen to reduce the size of the tumour.

Radiotherapy :

It is never the first choice in the management as it can induce secondary tumours).

Active space

Only used in the management of IIIB.
Surgical excision is the main management.
Before excision embolization must be done (angiography must be done prior to identify main artery).
Unresectable tumour : When the tumour has invaded intracranially (IIIB), radiotherapy is done.

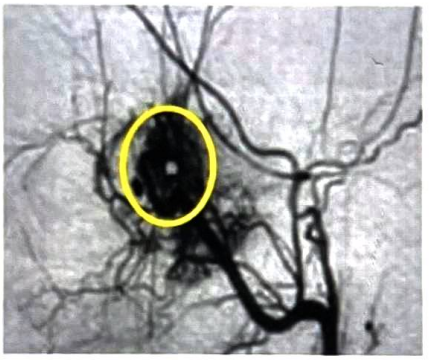

Tumour

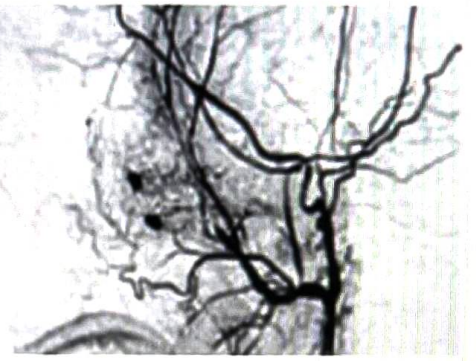

After embolization

Surgical approach

00:31:14

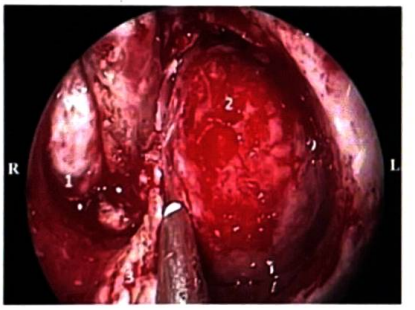

1. Endoscopic trans nasal approach only if skilled (as recurrence rate is very high because endoscopy gives limited access, whole tumour may not be removed).
2. Trans palatal approach : Here an incision is made between the hard and the soft palate and retracted. Once retracted the nasopharynx can be visualised.

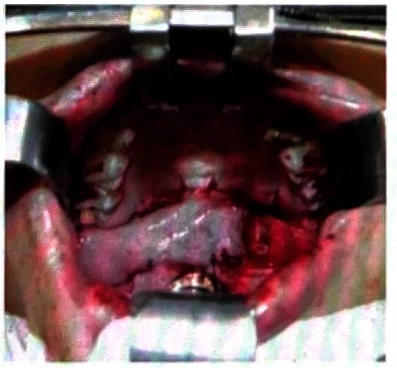

ENT • v4.0 • Marrow 6.0 • 2022

Leave Feedba

3. Weber Fergusson incision.
4. Lateral rhinotomy.

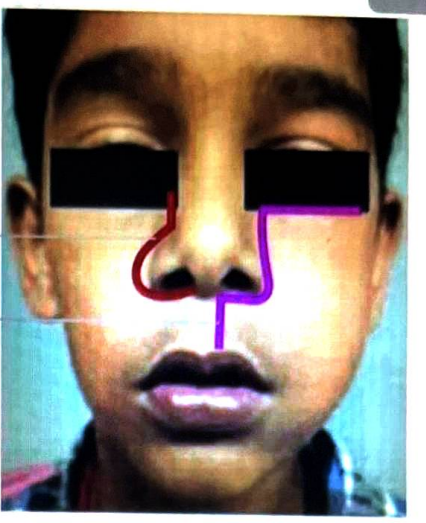

5. Infratemporal fossa approach.
6. Mid facial degloving approach :
   From one angle of mandible to other and skin flap is raised.
   Scar marks can be avoided.
   High risk of recurrence.

Locally invasive benign tumour :

Ear

- Glomus.
- Acoustic neuroma.

Nose:

- Inverted papilloma
- Angiofibroma in the nasopharynx.

These tumours can only spread through natural openings .

Active space

429
Leave Feedbac

NASOPHARYNGEAL CARCINOMA

Nasopharyngeal carcinoma

00:01:40

m/c carcinoma of nasopharynx.
Squamous cell carcinoma.
Site of origin : Fossa of rosenmuller/ lateral pharyngeal recess.

Etiology : Multinodal.

- Genetic : South east Asian countries.
  m/c : Southern China (Guandong carcinoma).
  m/c seen in Mongoloids.
- Nitrosamines used in food preservatives (Salted fish food), wood burning or incense burning.
- Virus : Epstein barr virus-IgA VCA/ EA.

Fossa of rosenmuller

Viral capsular antigen (VCA) : more sensitive.
Early antigen (EA) : more specific.

- Age : Bimodal age (15-25 years, 55-65 years).

C/F : 75% cases presents with upper deep cervical lymph nodes. Nasopharynx drains into retropharyngeal lymph nodes which further goes to deep cervical nodes.
2nd m/c lymph node to be involved : Posterior group of lymph nodes (Group v lymph nodes). Ex : FNAC of upper cervical LN is done & suggesting SCC with possible metastasis from pharynx because of rich lymphatics.
Base of tongue.
Tonsils.
Pyriform fossa.
Hence we should rule out above by endoscopy.

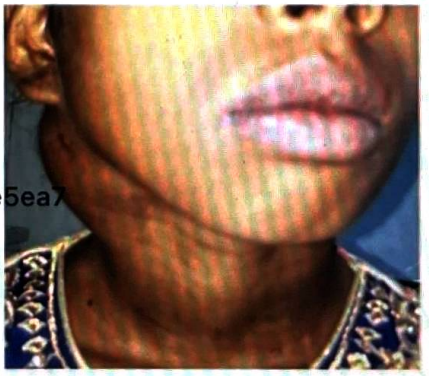

60c6b3eeaa8ded0e4e7e5ea7

Active space

Leave Feedba

Symptoms :

- Serous otitis media.
- Nasal obstruction.
- Hyponasal/ Rhinolalia clausa.

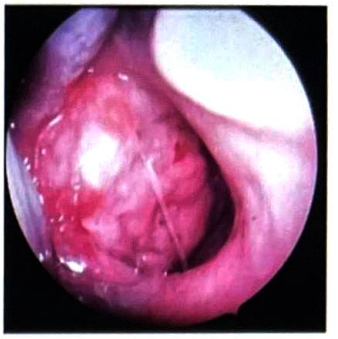

Can grow superiorly or laterally.

If grows superiorly : Sinus of morgagni syndrome (Trotter's triad).

Features :

Neuralgia of mandibular nerve.

Palatal palsy.

Conductive hearing loss (due to unilateral SOM).

Structures involved : TAALA.

Tensor palati.

Auditory tube.

Ascending palatine artery.

Levator palati.

Ascending pharyngeal artery (palatine branch).

If it grows laterally :

Grows to parapharyngeal space.

IX, X, XI, XII nerve involvement.

m/C : CN V (V_a > V_3) > CN VI.

Horner's syndrome is due to involvement of cervical sympathetical chain.

Mass in nasopharynx

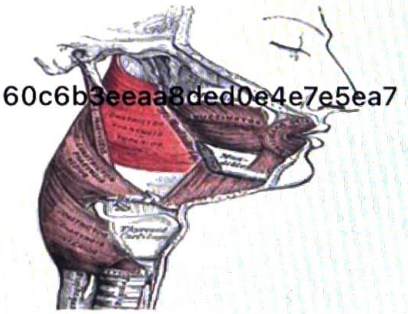

60c6b3eeaa8ded0e4e7e5ea7

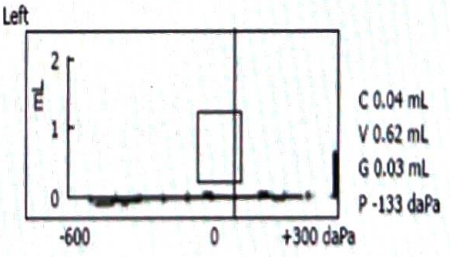

Tympanogram

Active space

Leave Feedba

Investigations :

B type or flat tympanogram.

On endoscopy :

Mass in nasopharynx.

Blood tinged discharge.

Confirm by Biopsy.

For spread : CT/MRI.

WHO Classfication :

Type I : Keratinizing squamous cell carcinoma.

kumarankitindia1@gmail.com

Type II : Non Keratinizing squamous cell carcinoma.

Type IIa : Non Keratinizing differentiated.

Type II b : Non Keratinizing undifferentiated (very radiosensitive but poor prognosis, as in 70-75% patients presents late).

m/C variant in endemic areas : Type IIb.

Management :

Early stage : Radiotherapy.

Late stage : Concurrent chemoradiation.

No role of surgical management.

Active space

Leave Feedbac

CONDITIONS OF TONSILS AND TONSILECTOMY : PART 1

Tonsils

00:01:12

Mucosa associated lymphoid tissue in oropharynx.
Palatine tonsils/faucial tonsils develop immunity.
They are present at birth.
Grow till 12 years.
Atrophy at puberty.
Develops from 2nd pharyngeal pouch.

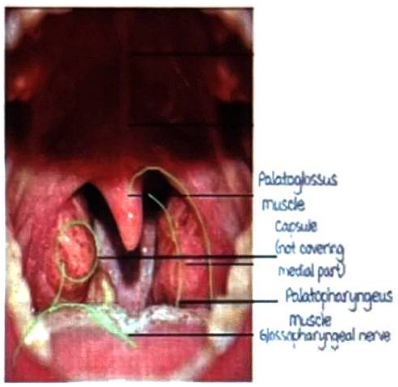

Epithelium : Stratified squamous non Keratinised epithelium.
Except in nasopharynx : Ciliated columnar epithelium.
Crypta magna (remnant of 2nd pharyngeal pouch) : Largest crypt.
Capsule : Pharyngo-basillar fascia only at the level of palatine tonsils thickens to form the capsule.
It is a hemicapsule (not covering the medial part).

Longitudnal muscle : Palatopharyngeus muscle (stylopharyngeus and glosspharyngeus muscles are longitudnal as well).
Circular muscle : Superior constrictor muscle.
Parapharyngeal space : Divided into 2 compartments by styloid process.

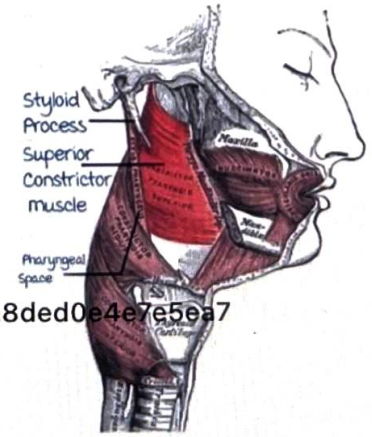

60c6b3eeaa8ded0e4e7e5ea7

Active space

Structures in the bed of tonsils (lateral to tonsils) :

- Loose areolar tissue : m/c site of haemorrhage following tonsilectomy.
- Superior constrictor muscle.
- Buccopharyngeal fascia.
- Parapharyngeal space (Anterior compartment : Styloid process and the muscles attach to it).

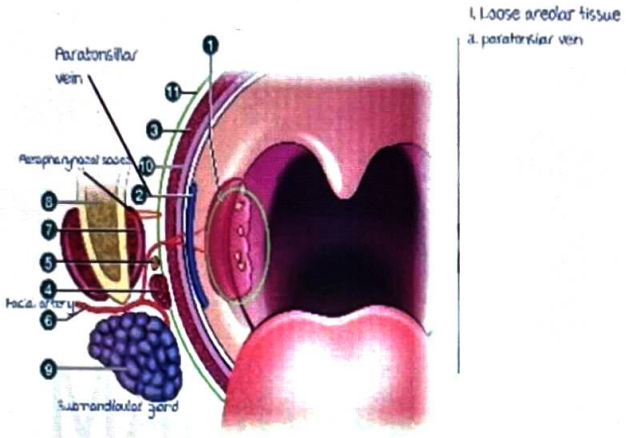

- Medial pterygoid muscle.
- Mandible.
- Masseter.
- Parotid gland.
- Submandibular gland.
- Glossopharyngeal nerve.
- Facial artery.

Any calcification/projection from styloid process can be accessed or removed from tonsilar bed.

Glossopharyngeal nerve enters the pharynx between superior and middle constrictor muscle.

Travels through the lower border of superior constrictor muscle.

Ascends up to oropharynx and gives sensory supply.

60c6b3eeaa8ded0e4e7e5ea7

It supplies posterior 1/3rd of tongue.

Glossopharyngeal neuralgia : Sharp severe pain arising in the distribution of the nerve.

Arterial supply :

- External carotid artery : Facial artery, maxillary artery (gives descending palatine), ascending pharyngeal artery & lingual artery.

Active space

Leave Feedba

- Facial artery : Tonsillar branch (main) and ascending palatine branch.

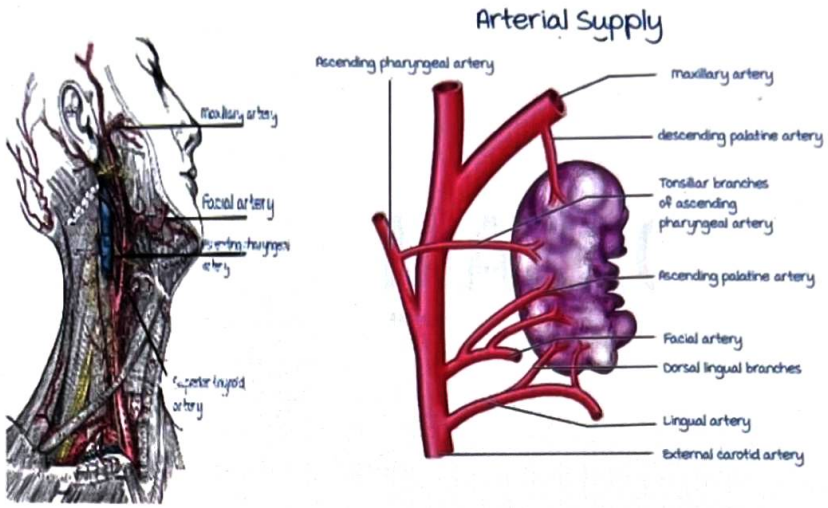

All the branches from facial artery supply the lower pole of tonsil usually so we have to be careful during surgery.

Structures entering through foramen of Moragagni :

1. Auditory tube.
2. Levator palati muscle.
3. Ascending palatine artery (branch of facial artery).
4. Ascending pharangeal artery.

kumarankitindia1@gmail.com

Venous drainage : Paratonsillar/extra palatine vein (present in bed of tonsil).
Nerve supply : Glossopharyngeal nerve (CN IX), some branches from lesser palatine nerve.
Lymphatic drainage : Upper deep cervical lymph node / tonsillar node/ jugulodigastric lymph node.

ENT surgeons graveyard/coffin : Area between the lower pole of tonsil and the base of tongue is known as tonsillo-lingulo sulcus.
Tumour or trauma may be hidden here.

In oropharynx, tonsil is the MC site of carcinoma.
Risk factor : HPV infections (HPV 16).

Active space

Acute tonsilitis

00:35:00

m/c organism : Group A β hemolytic streptococcus (also responsible for peritonsillar abscess).

Presentation :

- Pain in ear and throat.
- Fever.
- Odynophagia.
- Lymphadenopathy (upper deep cervical lymph node enlarged and painful).

60c6b3eeaa8ded0e4e7e5ea7

Types of appearance for tonsillitis :

- Acute catarrhal : Due to viral infection (congestive inflammation everywhere).
- Follicular : Pus points seen on the opening of the crypts.
- Membranous : Pseudomembrane formed due to coalescing of exudates.
- Parenchymatous tonsilitis : Involves the parenchyma as well.

Important causes of sleep apnea (> 30 episodes in 7 hrs of sleep).

Management :

Analgesics.

Antibiotics against Group A β hemolytic streptococcus.

Cataharal tonsilitis

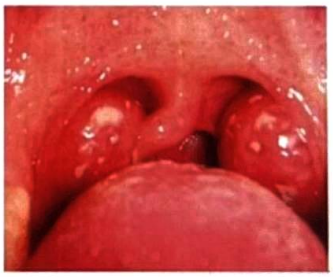

Follicular type

Membranous tonsilitis

Parenchymatous tonsilitis

Active space

Leave Feedba

D/D for membrane on tonsil : AL-VITAMIN D.

Agranulocytosis

Leukaemia.

Vincent angina.

Infectious mononucleosis.

Trauma.

Aphthous ulcers.

Moniliasis (candidiasis)

Infections of the throat (membranous tonsilitis).

Neoplasia.

Diphtheria.

60c6b3eeaa8ded0e4e7e5ea7

Vincent angina :

Infection of gingiva (interdental papillae) due to poor dental hygiene.

Causative organism : Borellia vincenti, F. fusiform.

A.K.a Acute necrotising ulcerative gingivitis/trench mouth.

Dirty grey membrane with necrotic gingiva seen.

Management : Penicillin + metronidazole.

Vincent's angina

Infectious mononucleosis :

AKa Glandular fever.

Causative organism : Epstein barr virus.

H/O sore throat, difficulty in swallowing, malaise.

O/E : multiple lymph nodes (posterior triangle) are involved.

Infectious mononucleosis

Seen in young people (12-25 yrs) :

Spread through saliva.

Known as kissing disease.

O/E : Petichae over palate.

P/A : Splenomegaly, hepatomegaly.

Active space

Diagnosis :

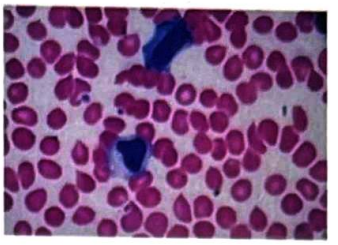

Blood tests : Atypical lymphocytosis

Paul bunnel monospot test.

Management :

No need for antibiotics.

Avoid penicillin (patient will develop rash).

Conservative management .

Candidiasis :

A.K.a oral thrush.

Causative organism : Candida.

Predisposing factor :

Immunocompromised patient.

Patient with steroid inhaler.

Diphtheria :

Causative organism : Corynebacterium diphtheriae.

Symptoms due to :

Exotoxin → Ulcers, necrosis → Pseudomembrane (RBC + WBC + bacteria + dead cells) → Membrane over necrotic base → Respiratory obstruction.

Exotoxin gets access to bloodstream through ulcers leading to systemic complications.

Heart : Myocarditis, conduction block, arrythmias.

Nerves : Neuritis, soft palate paralysis → Regurgitation of food and fluid through nose.

kumarankitindia1@gmail.com

Pseudomembrane present in larynx → Respiratory obstruction.

Pseudomembrane characteristics :

Dirty grey colour.

Extends beyond tonsil.

Tightly adherent & bleeds on removal.

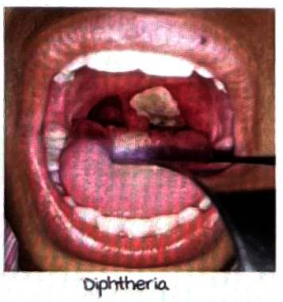

Diphtheria

Soft tissue edema - bull neck

Active space

Leave Feedba

Immunisation history will be missing.

Throat swab : Club shaped, gram positive rods.

management :

Anti toxin to be given (waiting for the report not required however sensitivity testing needs to be done).

β lactam antibiotics, macrolides, penicillin.

60c6b3eeaa8ded0e4e7e5ea7

Active space

439
Leave Feedba

CONDITIONS OF TONSILS AND TONSILECTOMY : PART 2

Complications of tonsillitis

00:01:12

Infections :

Recurrent acute otitis media.

Deep neck space abscess like :

- Peritonsillar abscess.
- Parapharyngeal abscess.
- Retropharyngeal abscess.
- Submandibular abscess.

Lemierre's syndrome :

Following oropharyngeal infection, septic thrombophlebitis of IJV.

Patient presents with :

- Neck pain.
- Tenderness.
- Features of septicemia.

60c6b3eeaa8ded0e4e7e5ea7

Non infective complications :

- Rheumatic fever (molecular mimicry).
- Type III hypersensitivity leading to post streptococcal glomerulonephritis.
- Sub acute bacterial endocarditis.

Sleep apnoea :

Decreased oxygen (> 10 secs) : Apnoea.

> 30 episodes in 7 hours approximately > 5 episodes / hour : Sleep apnoea.

Decreased oxygen → Pulmonary vasoconstriction → Pulmonary hypertension → Cor pulmonale (right heart failure).

Due to repeated infections → Blockade of crypts → Deposition of calcium crystals → Stone formation →

Active space

Leave Feedba

Tonsillolith.

Tonsillolith

60c6b3eeaa8ded0e4e7e5ea7

Tonsillar cyst

Obstruction of crypts → Secretions → Tonsillar cysts.

Chronic tonsillitis :

Tonsils infected for more than 3 months.

Features :

- Hyperemic or flushing of anterior pillars.
- On compression : Oozing of cheesy material : Irwin Moore sign.
- Enlarged jugulodigastric or upper deep cervical lymph nodes.

Tonsillectomy 00:11:58

Indications :

1. Infectious causes : Recurrent episodes of tonsillitis.

According to Paradise criteria :

> 3 episodes of tonsillitis / year for 3 consecutive years.

> 5 episodes of tonsillitis / year for 2 consecutive years.

> 7 episodes of tonsillitis / year for 1 year.

2. Peritonsillar abscess :

Single episode in a child

or 2 episodes in adult.

Active space

Leave Feedba

3. Chronic tonsillitis : if features present.

4. Non infective causes :

Obstructive sleep apnoea.

According to Friedman score :

0 : No tonsils (Surgery done).

1 : Within pillars.

2 : Outside the pillars.

3 : Reached 3/4th to midline.

4 : Touching in midline.

kumarankitindia1@gmail.com

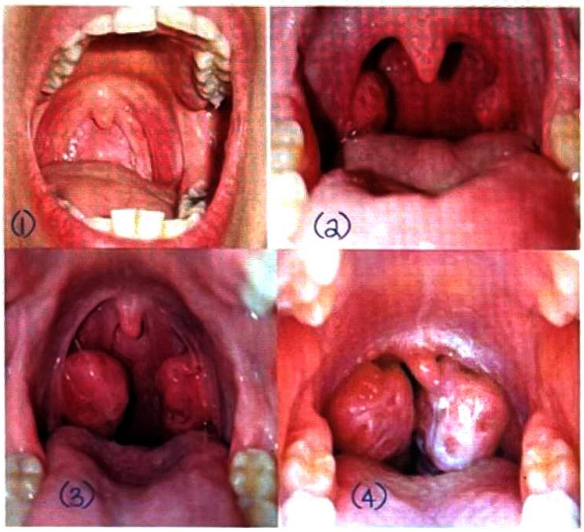

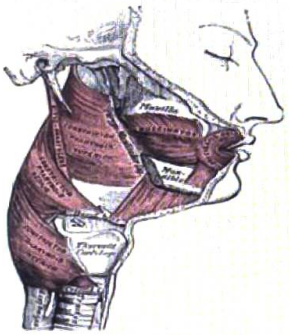

5. Relative indications :

Carriers of streptococcus and diphtheria.

As an approach to :

Styloid process enlarged : Eagle's syndrome.

Average length : 2-3 cm.

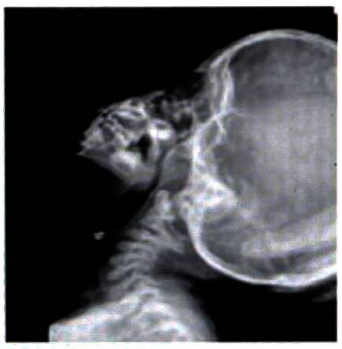

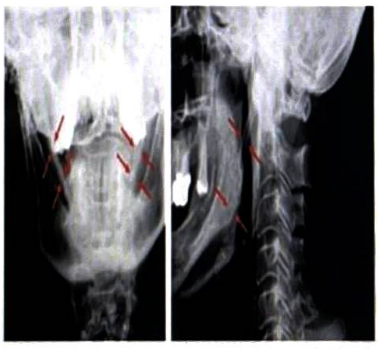

6. Glossopharyngeal neuralgia : Pain in the distribution of glossopharyngeal nerve.

Rx :

Medical management with carbemazepine.

Glossopharyngeal neurectomy via tonsillar bed.

Active space

Leave Feedb

7. Assymetric enlargement of tonsil : R/O lymphoma.

8. Uvulo palato pharyngoplasty done in case of bulky oropharynx.

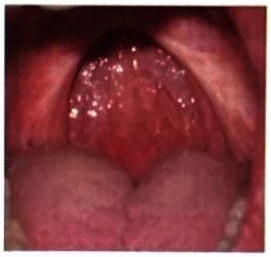

Contraindications :

- Acute infection.
- R/O bleeding diasthesis.
- Hb < 10mg/dl.
- Polio epidemic.

Position : Rose's position.

Pillow placed below shoulders.

Extension :

- Cervicothoracic joint.
- Atlanto occipital joint.

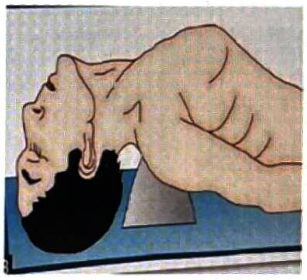

Rose's Position

Mouth is opened with Boyle's Davis mouth gag.



Draffin's Bipod stand

Active space

Draffin's bipod stand :

Holds Boyle's Davis mouth gag.

Other techniques :

60c6b3eeaa8ded0e4e7e5ea7

Hot methods : Heat used.

Cold methods : Heat not used.

Cold Knife

Microdebrider

Harmonic scalpel

Coblation wand

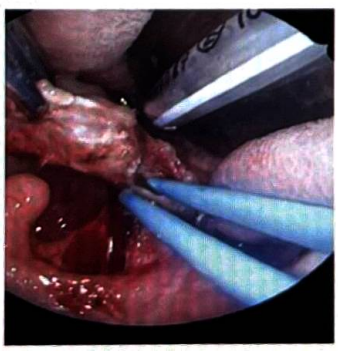

Monopolar cautery

Active space

Leave Feedba

Cold methods :

- Cold knife.
- Microdebrider.
- Harmonic scalpel.
- Cryosurgery.

Hot methods :

- Cautery.
- Coblation.
- Laser.

Dennis Brown forceps :

Pull the tonsils medially.

Jaws are blunt.

One jaw is bigger than the other.

kumarankitindia1@gmail.com

Dissection and snare method :

Mollison tonsil dissector and anterior pillar retractor.

Eve's tonsillar snare : Crush and cut to reduce the bleeding.



Active space

Types of tonsillectomy :

Extracapsular tonsillectomy : Tonsil + capsule (whole of tonsil removed)

Intracapsular tonsillotomy : Part of tonsillar tissue + capsule left behind.

60c6b3eeaa8ded0e4e7e5ea7

Complications of tonsillectomy :

Hemorrhage.

m/c of hemorrhage : External palatine vein / paratonsillar vein.

- Primary hemorrhage : During surgery.
- Reactionary hemorrhage : After surgery within 24 hours.
- Secondary hemorrhage : Secondary to infection after 24 hours upto 10 days.

m/c at 5-6 days.

Placed in recovery / coma position : Best protection from airway occlusion or aspiration of fluids into the lungs.

Watch for swallowing movements (happens in case of bleeding) and spitting of blood.

Monitor vitals (increased HR).

Management of hemorrhage :

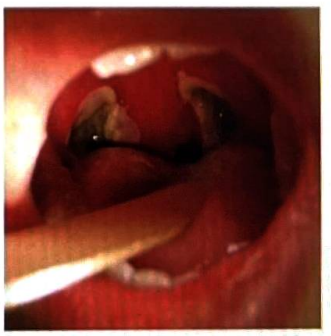

Under GA.

Steps :

1. Removal of clot.
2. Pressure with vasoconstrictor pack.
3. Ligation / Cautery.

On the 2nd or 3rd day : Raw areas starts sloughing.

Around 3 weeks following surgery : Tonsillar fossa. have normal appearance and normalized.

Active space

Leave Feedbac

CLINICAL ANATOMY OF LARYNX : PART 1

60c6b3eeaa8ded0e4e7e5ea7

In the earliest forms of life, larynx was present just as a muscular sphincter present in the lung fish.
The function was to protect lungs from the entry of water.

Even now, the function of larynx is considered as airway protection.
As life came from water to air, larynx in Amphibians (salamander) developed cartilages resulting in a patent open tube leading to an additional function → Respiration.

In humans larynx further developed to provide the function of phonation, along with respiration and protection of airways.

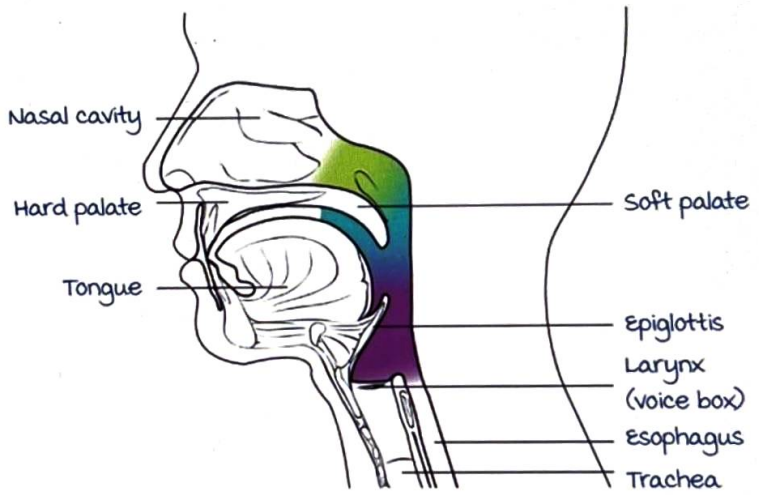

In the chronological order, phonation was late to develop. Phonation is due to the vocal cords in the larynx. The vocal cords adduct in midline, increasing the subglottic air pressure and then release of this pressure and vibration of vocal cord, results in speech by the articulators of the oral cavity, pharynx and larynx.

The adduction of the vocal cords also increase in the intrathoracic pressure, this helped in coughing out unwanted contents in the larynx and to lift heavy weights (by helping in fixing the chest).

Active space

Leave Feedbac

Therefore in people without larynx (post laryngectomy patients), heavy lifting would not be possible.

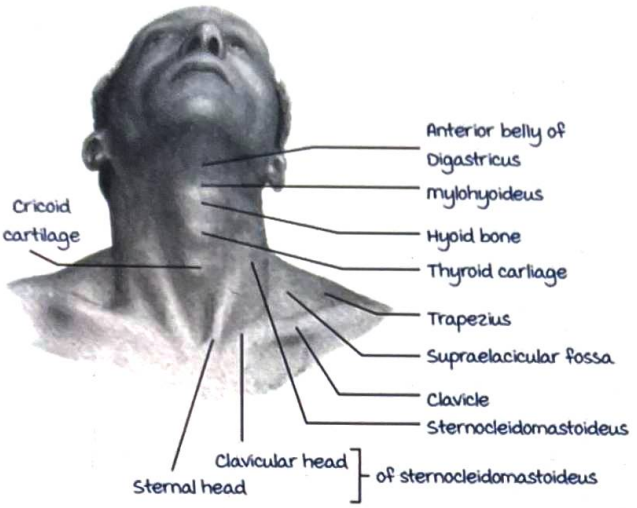

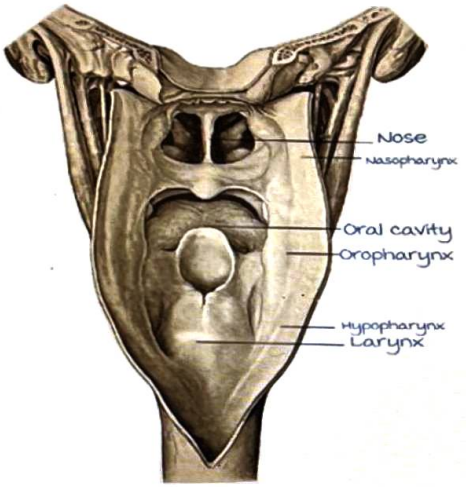

Larynx lies just in front of the hypopharynx and it extends

- Upper limit → From the epiglottis.
- Lower limit → The lower border of cricoid.
- At the location of vertebrae C3, C4, C5, C6.

The larynx developes from the 4th to the 6th pharyngeal arches.

- 4th arch → Upper part of larynx develops.
- 6th arch → Lower part of larynx develops.
- From the 3rd and the 4th arch, in the midline, a thickening develops called the hypobrachial eminence.
  This divides into cranial and caudal part.

The cranial part form the 3rd arch and caudal part from the 4th arch.

Active space

Leave Feedba

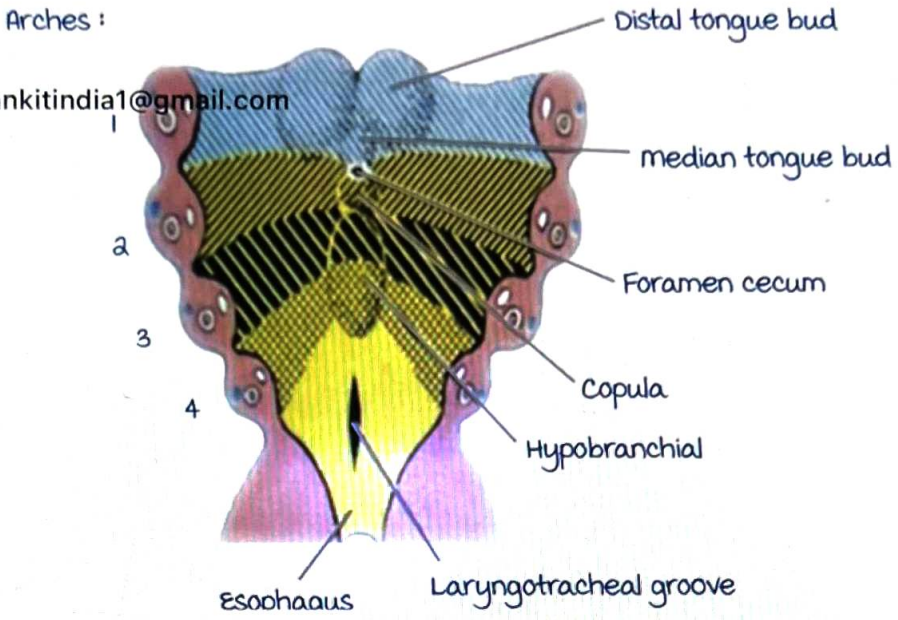

kumarankitindia1@gmail.com

- The hypobrachial eminence forms the base of the tongue (posterior 1/3 of tongue) and the anterior part formed by the 3rd arch.
- The hypobrachial eminence also leads to the formation of the epiglottis.

Development of larynx :

- Epiglottis : Hypobrachial eminence.
- Thyroid cartilage : 4th arch.
- Cricoid cartilage : 6th arch.
- Nerve supply :
  The parts derived from the 4th arch is supplied by : SLN (superior laryngeal nerve).
  6th arch parts are supplied by : RLN (recurrent laryngeal nerve).

Anatomy of the larynx 00:09:46

The larynx consists of 3 paired and unpaired cartilages. The unpaired cartilages are the :

- Epiglottis.
- Thyroid cartilage.
- Cricoid cartilage.

Active space

Leave Feedba

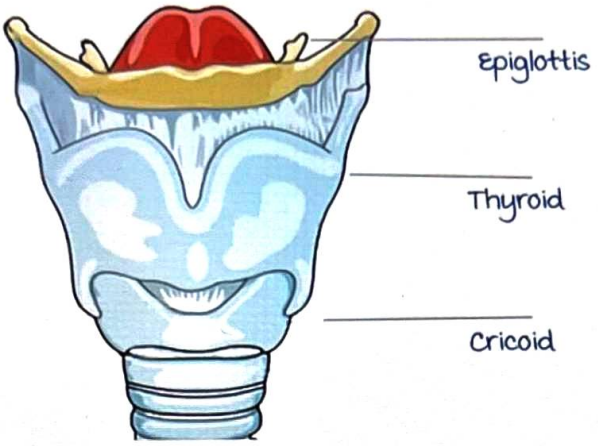

The paired cartilages are :

- Arytenoid/Pyramidal cartilage (1).
- Corniculate/Santorini cartilage (2).
  Small cone shaped cartilage found above the arytenoid cartilage.
- Cuneiform cartilage (3).
  Found above the corniculate Cartilage and also known as cartilage of Wrisberg.

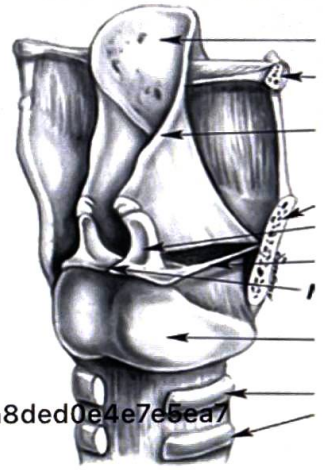
60c6b3eeaa8ded0e4e7e5ea7

The sensory part of facial nerve is also known as Nerve of Wrisberg.

Thyroid Cartilage :

Largest cartilage of the larynx.
Thyroid cartilage has 2 ala or lamina which meet in the midline at an angle.
The angle is different in both males and females.

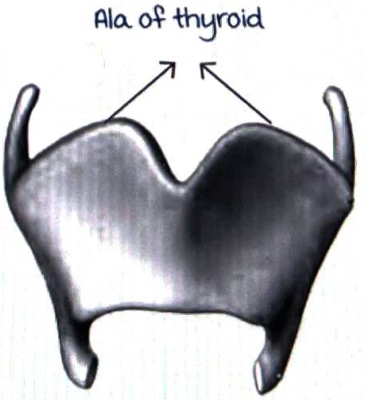

Active space

Leave Feedba

In males the angle is : 90°C.
Because of this, the males have laryngeal prominence called the Adam's apple.
In females the angle is : 120°C.

The notch in the midline of the thyroid cartilage is known as thyroid notch.
The upper and lower border of the lamina project superiorly and inferiorly to form the superior and inferior cornu respectively.

On the external surface of the thyroid, an oblique line of Thyroid is present which extends from the inferior part of the superior cornu till the lower border.
This oblique line of thyroid presents as a prominence for muscle attachment. The muscle attached are :

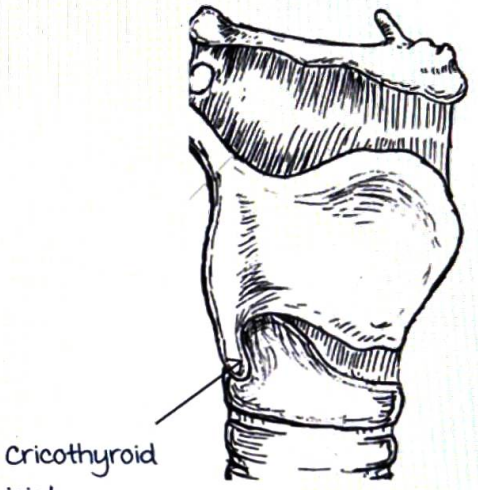

- Sternothyroid muscle.
- Thyrohyoid.
- Thyropharyngeus part of inferior constrictor.

The inferior cornu of the thyroid has an articular facet to articulate with the cricoid below at the cricothyroid joint (cricothyroid joint).
This enables the thyroid to move like a visor of the helmet.

60c6b3eeaa8ded0e4e7e5ea7

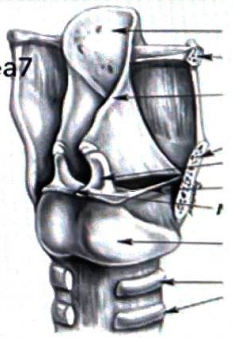

- On the mid point of the thyroid cartilage, an unpaired cartilage is attached called the epiglottis.
  Epiglottis is in the form of a leaf and is an elastic fibrocartilage. Superiorly, the epiglottis is attached to the hyoid by the hyoepiglottic ligament.

Active space

Leave Feedba

This ligament divides the epiglottis into 2 parts :

- Suprahyoid epiglottis.
- Infrahyoid epiglottis.

Cricoid :

It is the only complete ring cartilage of the larynx and is also known as signet ring cartilage.

Anteriorly, the ring is narrow (called as arch) and posteriorly, it broadens (called as lamina).

Because of cricoid forming a ring around the larynx, any injury leading to fibrosis can cause laryngeal stenosis.

MC site for laryngeal stenosis : Cricoid.

This is the reason, for tracheostomy, the incision is given at the 2nd or 3rd or 4th ring.

When dealing with a stenosed larynx, it is mandatory to use drugs (mitomycin C) to reduce synechia formation.

Mitocycin is also used for :

- Nasal packs following FESS.
- Choanal atresia.

kumarankitindia1@gmail.com

Arytenoid :

Posteriorly on the upper surface of the cricoid → The arytenoid is found.

The cricoarytenoid joint is a saddle joint and provides extended movement to the arytenoid.

It has 2 processes :

- Vocal process : Found anteriorly and the vocal cords attach here.
- Muscular process : Muscles attach on the arytenoid, these muscles attach only on the muscular process. These muscles actually move the vocal cords.

On the apex of the arytenoid is a paired cartilage called the corniculate cartilage.

Active space

Leave Feedbac

The membranes and muscles which connect towards the exterior of larynx is called as extrinsic membranes and

60c6b3eeaa8ded0e4e7e5ea7

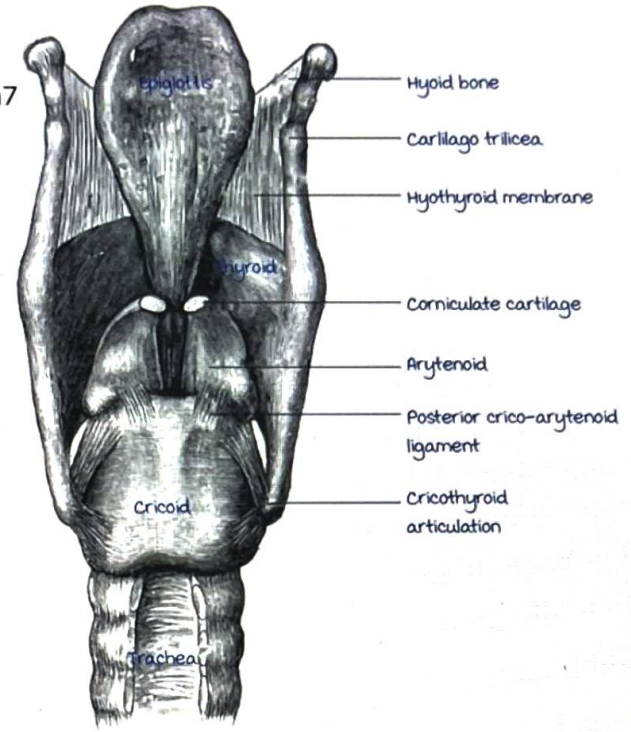

muscles.

Intrinsic membranes and muscles are those membranes and muscles that connect with each other.

Upper cartilage of larynx → Thyroid.
Lower cartilage of larynx → Cricoid.

Extrinsic Membrane : Hyoepiglottic membrane, Thyrohyoid membrane Cricotracheal membranes

Thyrohyoid membrane →

The membrane that connects the thyroid with the hyoid. The vessels and the nerves supplying the upper part of larynx (superior laryngeal vessels and nerves) enter through this membrane.

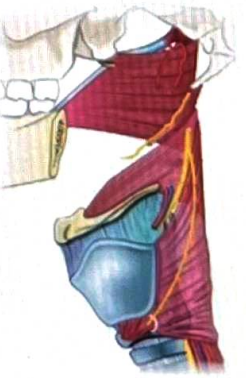

Active space

Leave Feedba

The internal laryngeal nerve division of the superior laryngeal nerve enters the thyrohyoid membrane.

Cricotracheal membrane :

Membrane that connects the cricoid to the trachea.

Hyoepiglottic ligament :

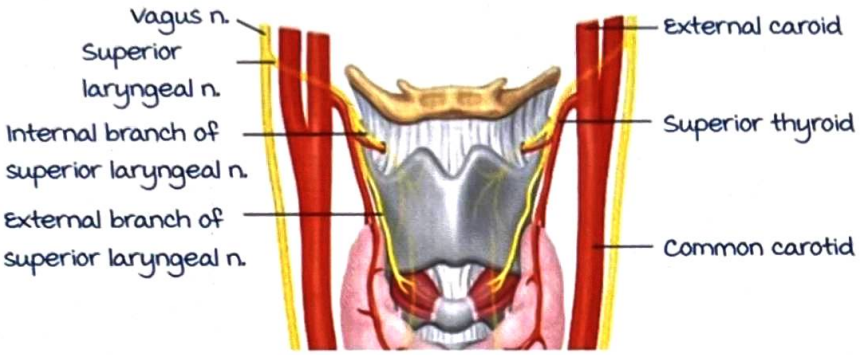

Connects the hyoid to epiglottis.

Circothyroid membrane is not an extrinsic membrane.

The internal laryngeal nerve enters the pharynx between the thyropharyngeus and middle constrictor muscle at the upper extrinsic membrane of the larynx.

During biopsy of the upper part of larynx, the internal laryngeal nerve is anesthetized at the point where it enter the thyrohyoid membrane.

The greater cornu of the thyroid is palpated and the anesthetic agent is injected just below it.

60d6b3eeaa8ded0e4e7e5ea7

Intrinsic membranes 00:33:55

2 membranes come under this category and they are named according to their shape.

- Quadrangular membrane.
- Conus elasticus. Also known as cricovocal membrane.

Active space

Leave Feedba

Quadrangular membrane :

These are the membranes attached to both sides of the epiglottis.

The upper border of the quadrangular membrane is called as aryepiglottic folds (connects epiglottis to arytenoid) and the lower border is called as false vocal cord.

Epilarynx :

This is the inlet of the larynx with the borders as :

- Epiglottis.
- Aryepiglottic fold.
- Arytenoid.

Vestibule of larynx :

Cavity between the 2 quadrangular membrane.

Rima vestibuli :

The space between the 2 false vocal cords.

kumarankitindia1@gmail.com

During ingestion of food, the epiglottis folds down closing the epilarynx passes over epiglottis into Hypolarynx.

In cases of acute epiglottitis or laryngomalacia, the epiglottis becomes enlarged, inflammed and edematous.

When the patient lies supine, the bulky epiglottis falls down and closes the inlet of larynx leading to respiratory distress.

Conus elasticus :

membrane in the form of cone, found at the upper end of the cricoid and also known as cricovocal membrane.

The upper border of the conus elasticus forms the true vocal cord.

At the level of true vocal cords, the larynx is known as glottis.

Above this level is supraglottis and below it is subglottis.

Ventricle :

Gap in between the false and true vocal cords.

Active space

Leave Feedbac

Components of the supraglottis :

- Epiglottis.
- Aryepiglottic fold.
- False vocal cord.
- Ventricle.
- Quandrangular membrane.

Cavities in the larynx from superior to inferior , starting from the epiglottic inlet :

- Vestibule.
- Rima vestibuli.
- Ventricle.
- Rima glottidis (cavity in between the 2 true vocal cords) below which the subglottis is found.

kumarankitindia1@gmail.com

Anterior to cricoid is the larynx and posterior to it is hypopharynx and cricoid acts as a common wall.

Pyriform fossa :
On the sides at the hypopharynx, mucosal folds created due to the projection of larynx into the hypopharynx.
This fold of mucosa separate the larynx from the hypopharynx.

Paraglottic space :
Space lateral to the larynx, in between the thyroid ala, quadrangular membrane (medially), ventricle, conus elasticus, pyriform fossa (posteriorly) extending the whole lenght of the larynx.
Pre epiglottic space :
Space between the thyroid and the epiglottis.

Supraglottis :
epiglottis
aryepiglottic fold
false vocal cord
quadrangular membrane.

Active space

Leave Feedbac

Cricothyroid membrane :

Is an anterior thickening of cricovocal membrane and is part of intrinsic membrane.

Piercing this membrane allows access to the laryngeal airway without having to incise a cartilage.

Whenever an obstruction is above the level of vocal cord, an emergency tracheostomy is done.

But if this cannot be done, emergency respiration can be given to the patient by piercing the cricothyroid membrane.

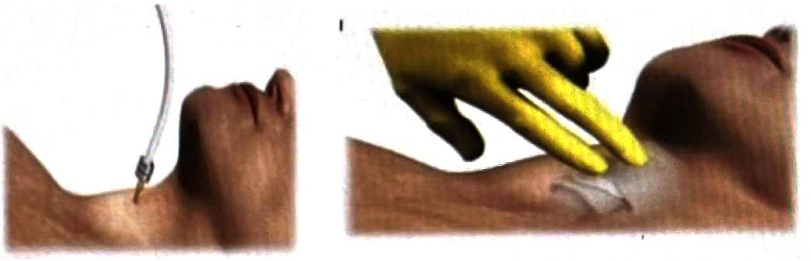

This is called as cricothyrotomy/coniotomy (opening on the conus elasticus)/ inferior laryngotomy (opening on the inferior membrane) done during CICO state (can't intubate can't oxygenate).

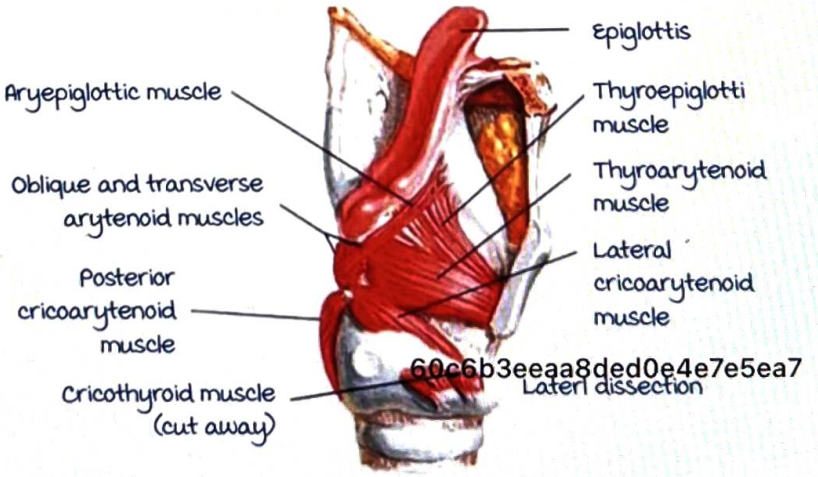

60c6b3eeaa8ded0e4e7e5ea7

Active space

Leave Feedba

Laryngeal muscles

00:49:53

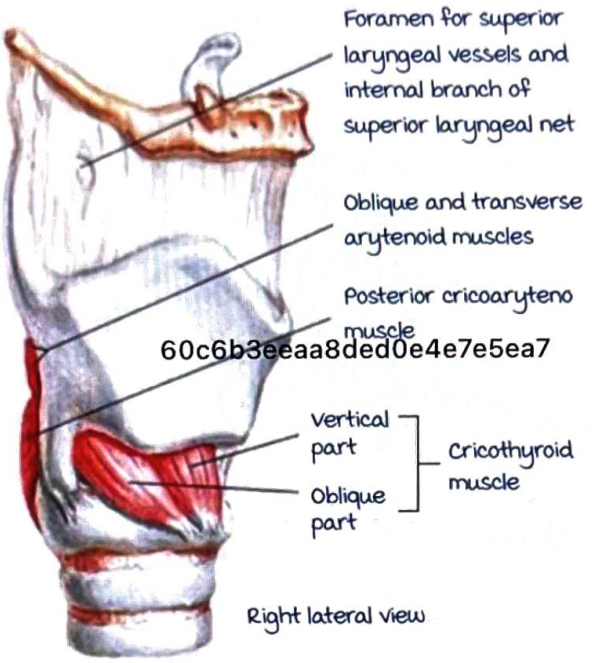

60c6b3eeaa8ded0e4e7e5ea7

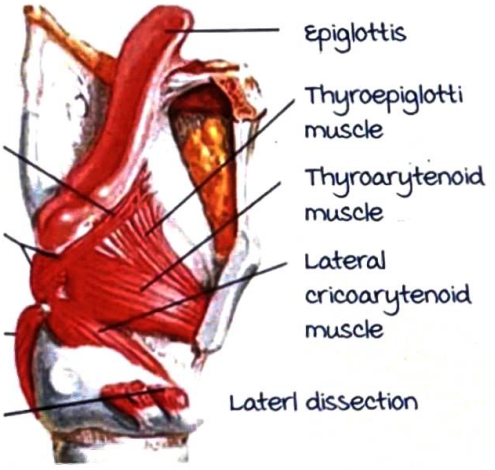

Categorised into 2 :

- Extrinsic muscles : Connects the laryngeal framework to the outside structures.

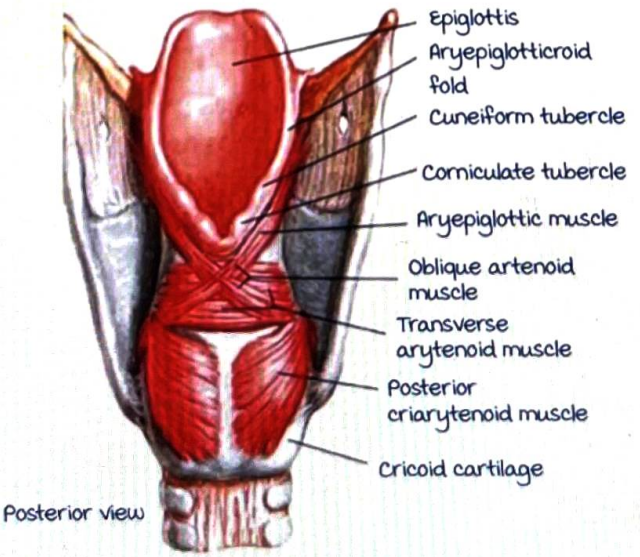

Active space

Leave Feedba

- Intrinsic muscles : Connects the laryngeal cartilages with each other.

Intrinsic muscles :

Thyroepiglottic muscle → Thyroid to the epiglottis.

Thyroarytenoid : Thyroid to the arytenoid.

kumarankitindia1@gmail.com

Cricothyroid muscle :

Cricoid to thyroid. This is the only intrinsic muscle lying outside.

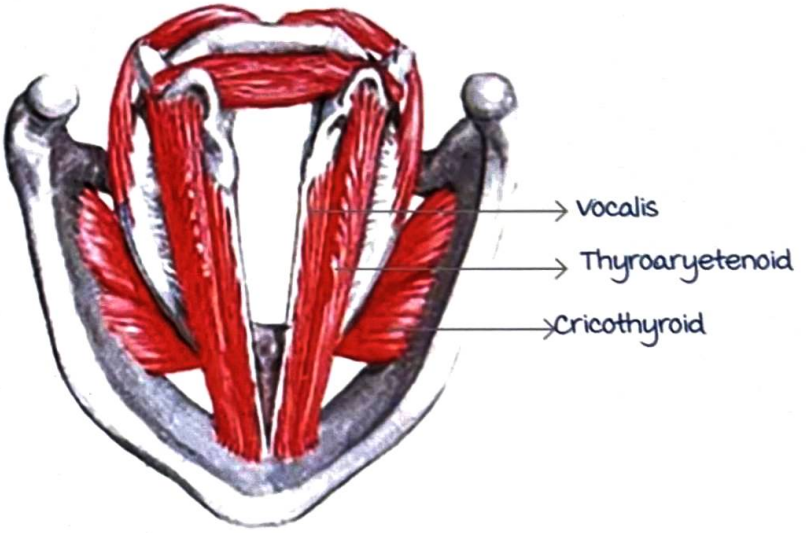

Cricoarytenoid :

Consists of lateral cricoarytenoid & posterior cricoarytenoid.

Interarytenoid :

Present in between the 2 arytenoids. Only unpaired muscle.

Oblique arytenoid :

muscles that travels obliquely from in between the arytenoid and reaches the aryepiglottic fold and forms the aryepiglottic muscle.

Thyroarytenoid is a broad muscle and is divided into lateral and medial parts :

- Lateral part → Thyroarytenoid.
- Medial part → Vocalis.

When the vocalis contracts, it reduces the tension on the vocal cords.

Classification based on function of the muscles :

Active space

Leave Feedba

muscles that attach to the inlet :

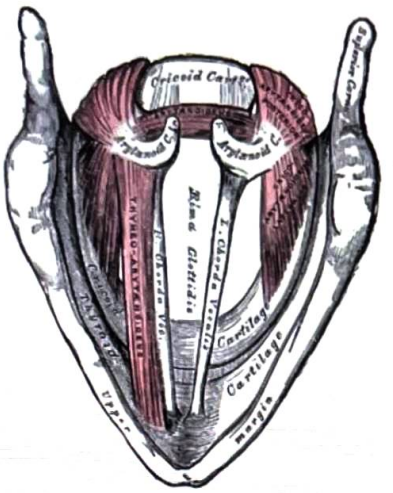

kumarankitindia1@gmail.com

- Thyroepiglottic → Epiglottis moves closer to the thyroid/ inlet opens.
- Aryepiglottic → Epiglottis moves closer to arytenoid/ inlet\ closes.

  This muscle is a part of oblique arytenoid.

muscles that attach to the true vocal cord/glottis :

- Adduction of true vocal cord : All muscles adduct except posterior cricoarytenoid (also known as safety muscle).
- Abduction : Only abductor is the posterior cricoarytenoid.
- Tensors of the vocal cord :
  1. Cricothyroid increases the tension of the vocal cords. This muscle when it contracts, it pulls the thyroid cartilage down and increases the tension of the true vocal cord.
  2. Vocalis muscle (inner part of Thyroarytenoid muscle) decreases the tension of the vocal cords.

In males, the vocal cords are relaxed compared to females and hence the high pitched voice in females due to tense cords.

To increase the pitch → Cricothyroid should contract.

To decrease the pitch → Vocalis should contract.

Only muscle with dual nerve supply : Interarytenoid or transverse arytenoid (supplied by RL of both the sides).

Extrinsic muscles :

These muscles help the larynx move along with the other

Active space

Leave Feedba

structures during swallowing.

Muscles which depress the larynx :

- Sternothyroid.
- Sternohyoid.
- Omohyoid.

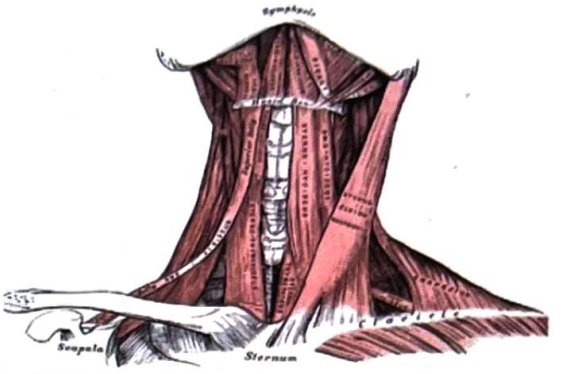

Muscles which elevate the larynx :

- Longitudinal muscles of the larynx.
  These muscles have different originating levels.
  Palatopharyngeus.
  Salpingopharyngeus.
  Stylopharyngeus.
  All three attach to the thyroid.

Other muscles that elevate by attaching to the hyoid include :

- Stylohyoid.
- Geniohyoid.
- Mylohyoid.
- Digastric.
- Thyrohyoid.

Possible movements of larynx :

- Up and down.
- Anterio posterior.
- Side to side → Done using physical force.
  used to detect cricoid caricinoma (laryngeal crepitus is absent).

Epithelial lining of larynx 01:13:16

Ciliated columnar pseudostratified epithelium lines the whole of the larynx except at the true vocal cords and upper part of epiglottis & aryepiglottic fold, where the lining is stratified squamous non Keratinized epithelium.

Active space

461
Leave Feedbac

CLINICAL ANATOMY OF LARYNX : PART 2

Sites of larynx

00:00:22

At the level of true vocal cords :

- Supraglottis (above).
- Glottis (at the level of true vocal cords).
- Subglottis (below).

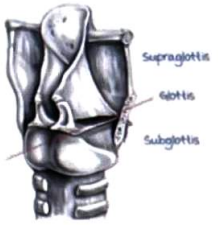

Subsites of supraglottis :

- Arytenoids.
- Aryepiglottic folds.
- False vocal cords.
- ventricles.
- Epiglottis.

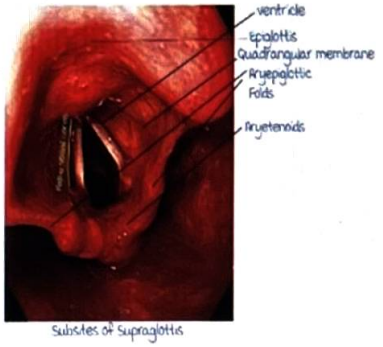

Subsites of Supraglottis

Epilarynx : Inlet (formed by epiglottis + aryepiglottic folds + arytenoids).

Glottis : At the level of true vocal cords.

Components of glottis :

- Anterior commissure.
- Posterior commissure.
- True vocal cords :

1. Anterior 2/3rd : membranous (vibrates during talking).
2. Posterior 1/3rd : Cartilaginous (has abduction and adduction movements).

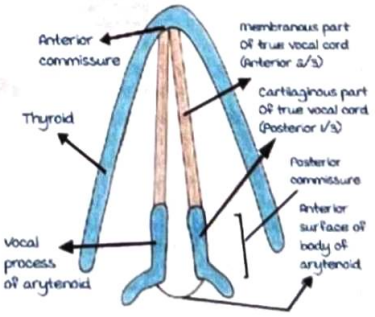

Glottis

Mid part of membranous part : Maximal point of vibration of true vocal chords → Maximum point of [illegible] abuse.

Boundaries of glottis :

Upper boundary → Lower border of ventricle.

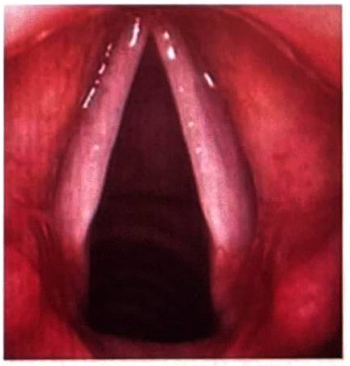

Glottis

Active space

Leave Feedba

Lower boundary → 1 cm below the edge of TVC.

MC site of vocal nodule / polyp formation : mid part of membraneous part or junction of anterior 1/3rd and posterior 2/3rd

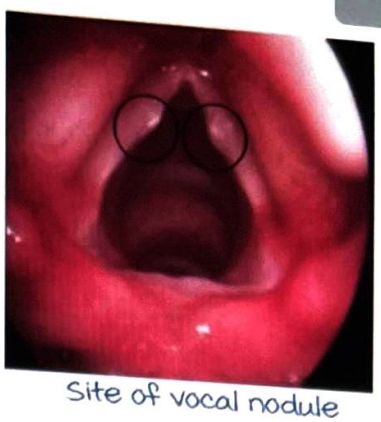

Site of vocal nodule

True vocal chords are attached to thyroid via Broyle's ligament/ anterior commissure tendon. They hamper the spread of tumours.

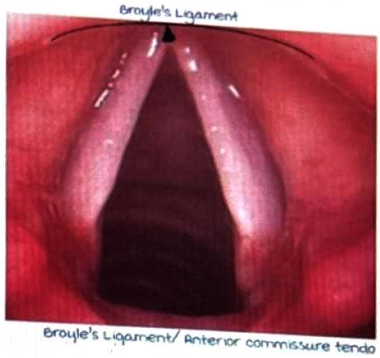

Broyle's Ligament/ Anterior commissure tendo

Subglottis :
It is present below the glottis.

Subglottis

60c6b3eeaa8ded0e4e7e5ea7

Cavities of larynx

00:10:48

Cavity of larynx :

- Inlet.
- Vestibule (between 2 quadrangular membrane).
- Rima vestibuli (between 2 false vocal cords/ AKa vestibular folds/ventricular folds).
- Ventricles (between false & true vocal cords).
- Rima glottidis (space between 2 true vocal cords).
- Subglottis.

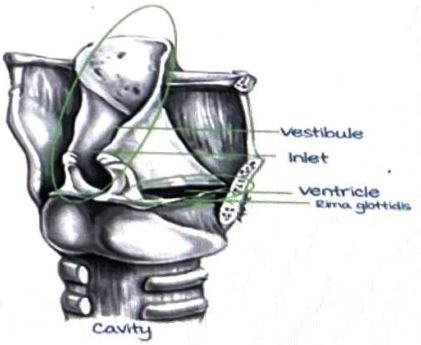

Cavity

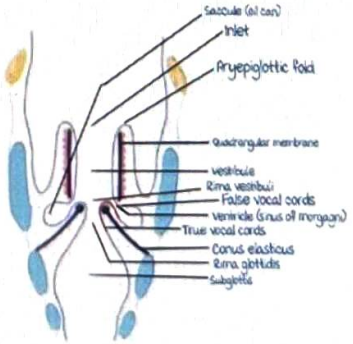

Active space

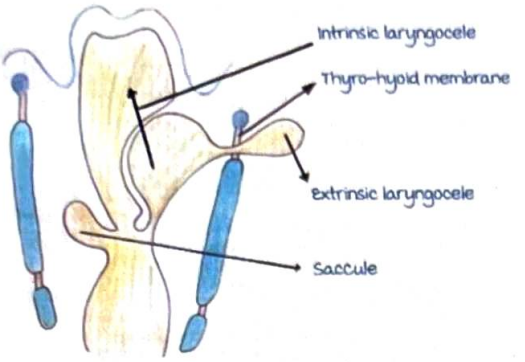

kumarankitindia1@gmail.com

- Epithelium from false vocal cord goes laterally to form saccules before lining the true vocal cord.
- TVC gets lubricated by the saccule as it is lined by stratified squamous epithelium with no mucous glands. AKA oil can of Larynx.
- Sinus of morgagni of larynx is ventricles.
- Enlargement of saccule occurs when the TVC are in mid line (blowing down /blowing against closed glottis) air entry is not possible downwards and the air gets diverted into the saccule→Enlargement →Laryngocele.

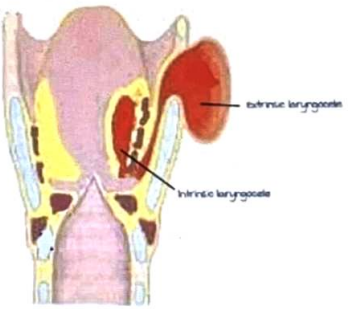

It can be seen in :
weight lifters.
Trumpet blowers .
Glassblowers.
Tumors of ventricles.

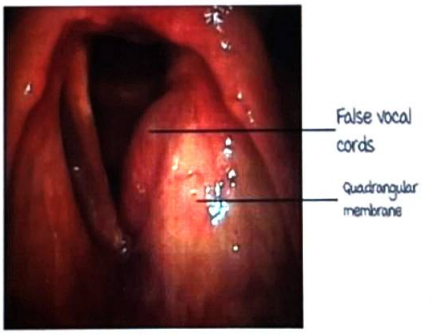

Extrinsic laryngocoele

Types :
- Intrinsic.
- Extrinsic : Piercing the thyrohyoid membrane.

It can cause difficulty breathing.
Can be congenital.

Compression of external neck swelling (Laryngocele) :
Increases on Valsalva.
On compression : Sudden gush of sound producing a hissing sound : Bryce sign.
Can lead to laryngopyocele following infection.

Active space

Leave Feedba

Before & after valsalva

Boyce sign : Gurgling sound on palpation.

Management : Excision (endoscopic / through external approach).

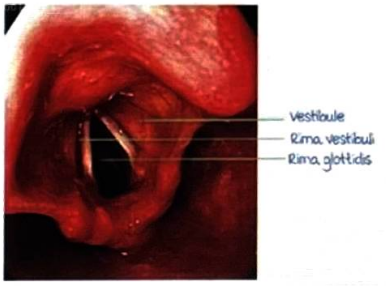

Larynx as protective sphincter of airway :

- Inlet : most effective sphincter.
- False vocal cords : Prevent aspiration.
- True vocal cords.

Spaces around larynx

00:22:42

Pre-epiglottic space :
Also known as space of Boyer.
Boundaries :
Anteriorly : Hyoid, Thyro-hyoid membrane, thyroid.
Posteriorly : Epiglottis (Infra hyoid).
Superiorly : Hyoepiglottic ligament.
Contains fat .
Lymphatics & vessels pass through it.
Pre-epiglottic space is an important route of spread of carcinoma larynx.

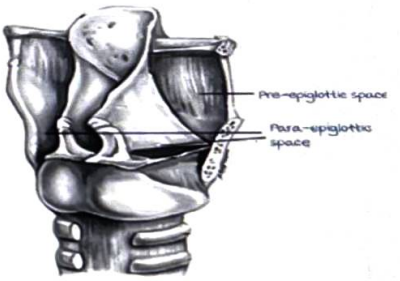

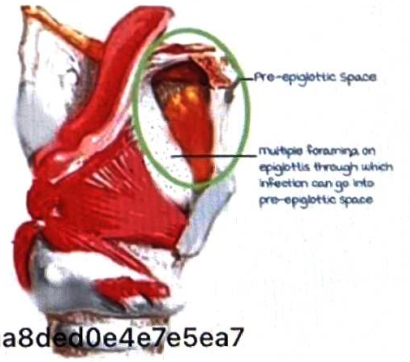

60c6b3eeaa8ded0e4e7e5ea7

Para-epiglottic space :
Also known as space of Tucker.
Boundaries :
Laterally : Ala Of thyroid.

Active space

Leave Feedback

Medially : Quadrangular membrane, Ventricles, conus Elasticus(crico-vocal membrane).
Posteriorly : Pyriform fossa.
Anteriorly : Communicates with pre-epiglottic space.
Contains : Fats , lymphatics & vessels.
Significance : Spread of tumor.

Reinke's space :
The space in between vocal ligament & epithelium of true vocal cords.
Boundaries :
Laterally : Vocal ligament
Medially : Epithelium of vocal cord.
Anteriorly : Anterior commissure.
Posteriorly : Posterior commissure.
Contains loose areolar tissue.
Significance : enables movement/vibration of vocal cord.

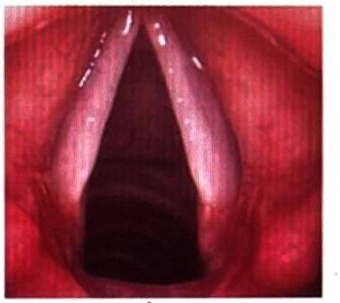
Reinke's space

Reinke's edema

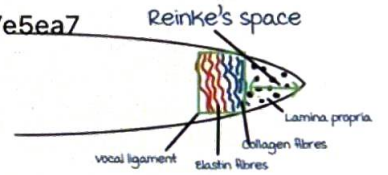

Cut section of true vocal cords

Lymphatic drainage 00:31:55

True vocal cords have no lymphatics :
1) No spread of glottic carcinoma through lymphatics.
2) Reinke's edema is seen in true vocal cords because lack of lymphatics.

Maximum lymphatic drainage : Supraglottis.
No lymphatics in glottis.

Supraglottis drains into upper deep cervical & middle deep cervical (level 2 & 3) lymph nodes.
Subglottis drains into lower deep cervical (level 4) & anterior group of lymph nodes (level 6).
Larynx drains into lateral group of lymph nodes (level 2,3 & 4).

Active space

Leave Feedba

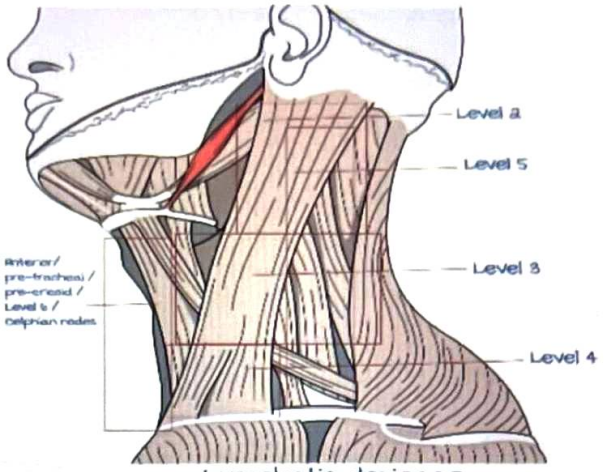

Lymphatic drainage

Adult larynx vs Infant larynx

00:36:18

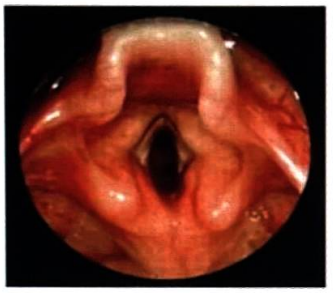

Infant larynx

Adult larynx

kumarankitindia1@gmail.com

	Infant larynx	Adult larynx
Shape (larynx)	Funnel	Cylindrical
Shape (epiglottis)	Omega	Leaf
Narrowest part	Subglottis	Glottis
Level (opposite vertebrae)	At level of C2, C3. (High placed)	At level of C3,C4,C5 & C6.
Significance	Can breathe & suckle at same time due to high placed larynx.	

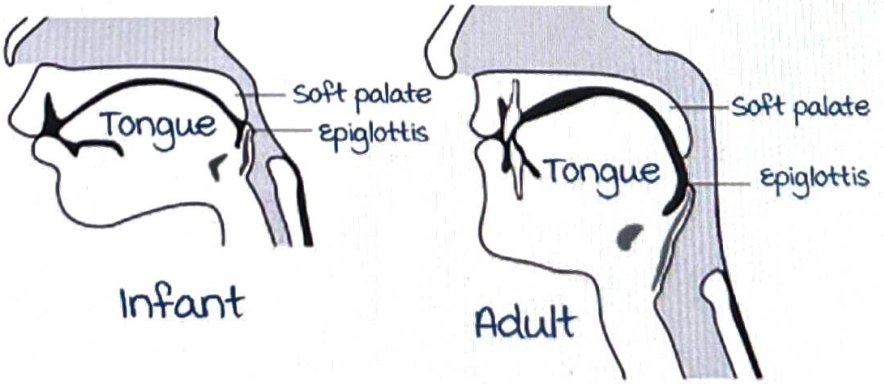

When inf

Active space

Leave Feedba

ant swallows, epiglottis meets uvula and closes the laryngeal inlet. Milk will then go sideways into pyriform fossas.

Simultaneous passage of air can occur behind the uvula & epiglottis into larynx.

Hence children can breathe and swallow at the same time.

60c6b3eeaa8ded0e4e7e5ea7

AP diameter in males : 36mm.

AP diameter in females : 26mm.

Cartilages of larynx start calcification at the age of 25 yrs → Prone for fractures.

Epiglottis is elastic cartilage.

Hyaline cartilages : Thyroid , cricoid & aryetenoids.

Calcifications can occur in all these cartilages & can be viewed on X-Ray.

Visualising larynx

00:50:55

We can visualise larynx by :

- Flexible endoscope .
- Rigid endoscope - with tips of different angles (70°, 90°).
- Stroboscope.
- Indirect laryngoscope.

Flexible Endoscope

Stroboscope :
Lights appear in flashes, enable visualisation of vocal cords.

Rigid endoscope

Active space

Leave Feedbac

Indirect laryngoscopy :

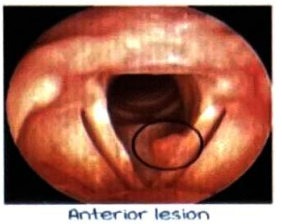

Anterior lesion

Anterior lesion

Anterior part is where the 2 commisures meet.
Anterior lesions are vocal nodules or polyps whereas granulomas are posterior lesions. This can help in narrowing down differentials.

Direct laryngoscope

When patient is sitting in front of examiner :

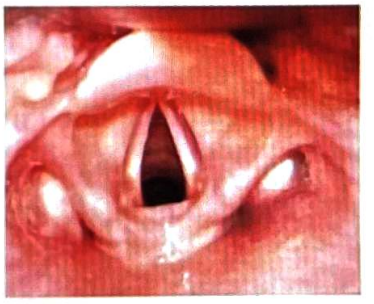

60c6b3eeaa8ded0e4e7e5ea7

Active space

Leave Feedbac

In direct laryngoscopy : Boyle's position is maintained (extension at Atlanto-occipital joint & flexion at cervico-thoracic joint).



Boyle's position

Laryngoscope is held in the non-dominant hand (left).
Dominant hand is used for intubating/suctioning etc.

Anterior lesion

Posterior lesion

arankitindia1@gmail.com

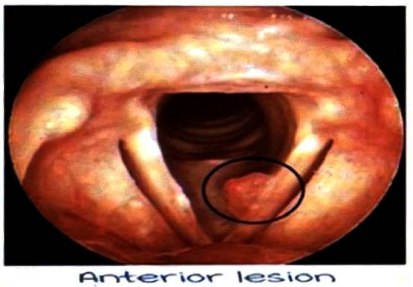

Anterior lesion

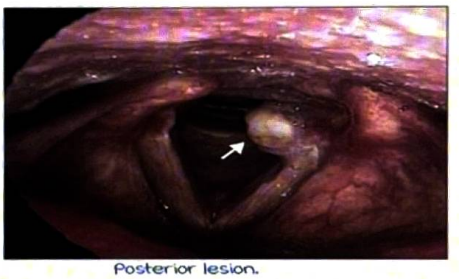

Posterior lesion.

Indirect laryngoscopy : Visualise the larynx through a mirror.
Mirror has straight handle.
We go behind the base of tongue in the oropharynx to view structures below in larynx.
The tongue is pulled out/ depressed and lip is raised with index finger to properly visualise through the mirror.
The indirect laryngoscope is pressed against uvula.

Indirect Laryngoscope

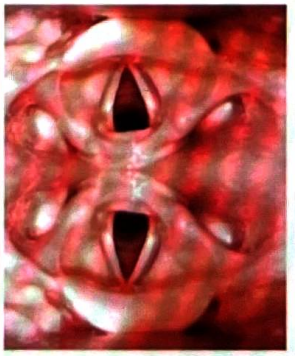

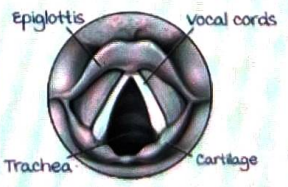

Active space

Leave Feedba

INFECTIONS OF THE LARYNX

Functions of larynx :

- Protection of lower airway.
- Helps in respiration.
- Helps in swallowing.
- Phonation.

Stridor

00:02:50

High pitched noise.

Produced due to the obstruction in the larynx, up to secondary bronchi.

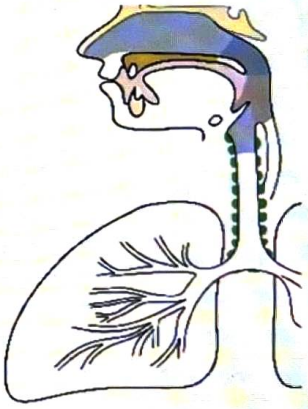

Types :

1. Inspiratory :
   - Supraglottic.
   - Glottic.

2. Biphasic :
   - Subglottis.
   - Cervical trachea.
   - Sometimes heard in glottic obstruction as well.

3. Expiratory :
   - Obstruction of Intrathoracic trachea till secondary bronchi.

Stertor :

Obstruction above the level of larynx (nose, nasopharynx, oropharynx).

60a6b3eeaa8ded0e4e7e5ea7

Wheeze :

Obstruction beyond secondary bronchi.

Active space

Leave Feedback

Supraglottic v/s glottic v/s subglottis

00:14:54

	Supraglottic	Glottic	Subglottic
Speech	Normal/ muffled speech.	Hoarseness/ Dysphonia/ Aphonia.	Normal.
Stridor	Inspiratory.	Inspiratory/ biphasic.	Biphasic.
Increase in supine.	+	-	-
Decrease in prone.	+	-	-
Preferred posture.	Prone/ bending forward.		
Dysphagia/ odynophagia/ drooling	+	-	-

60c6b3eeaa8ded0e4e7e5ea7

Acute epiglottitis

00:19:33

Also known as supraglottic laryngitis.
Earlier caused mainly by H. influenza.
Nowadays, most common cause : Streptococcus.

Presentation :
Age : 2-8 years.
Onset : Acute onset.
Symptoms : Dysphagia / odynophagia / drooling.
Stridor :

- Inspiratory.
- Increase in supine position.
- Decrease in prone position.
- Preferred posture :
  Bending forward/ Tripod position.

Speech : Normal or muffled.

Tripod position

Active space

Leave Feedba

Overall appearance : Toxic appearance/ Sick child.

Diagnosis :

Pharyngeal examination is contraindicated, as it can lead to laryngospasm.

X-ray :

Thumb sign.

Endoscopy :

- Done under intubation in OT setting.
- Finding : Congested edematous epiglottis.
- Seen in adults with endoscopy/IL examination because the submucous tissue is tight leading to lower edema compared with the children.

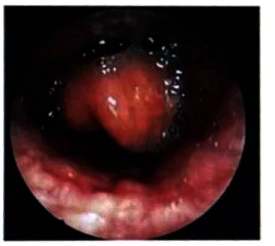

kumarankitindia1@gmail.com

Management :

1. Secure airway :
   - Preferably by intubation (best option).
   - If intubation not possible, do tracheostomy.
2. Start IV antibiotics.
3. Steroids :
   - Local/ systemic.
   - To reduce edema.
4. Adrenaline nebulisation :
   - Results in vasoconstriction and bronchodilatation.
   - Improves breathing.
5. Hydration.

Croup

00:30:09

Also known as laryngo tracheo bronchitis.

Most common cause of respiratory distress in a child/infant.

Most common cause of acute airway obstruction in children.

Caused by parainfluenza virus.

Presentation :

Age : 6 months to 3 years.

Active space

Sex : male/ Boys.

Onset : Gradual onset.

Speech : Hoarseness.

Cough : Barking voice / seal like cough.

Stridor :

- Initially inspiratory, later becoming biphasic in nature.
- No change in posture.

No dysphagia, odynophagia or drooling.

Diagnosis :

X-ray : Steeple sign /pencil tip sign.

Management :

1. Steroids : Local /systemic.
2. Adrenaline nebulisation.
3. Humidification.
4. Hydration.
5. Heliox : Helium + oxygen in ratio of 70:30.

60c6b3eeaa8ded0e4e7e5ea7

Q. 2 year old fully immunised child presents with acute onset fever, stridor and dysphagia. Within 2 hours, child becomes floppy. In another 2 hour child dies. What is the diagnosis?

A. Diphtheria.

B. Foreign body aspiration.

C. Acute epiglottitis.

D. Croup.

Chronic infections of larynx

00:41:09

Tuberculosis (TB) of larynx :

most common granulomatous condition of larynx.

Occurs secondary to Pulmonary TB.

most common part of larynx affected in TB : Posterior part.

most common part of larynx affected in all other infections except TB : Anterior part.

Presenting features :

- Low grade fever.

Active space

Leave Feedba

- malaise.
- cough.
- very painful in nature (TB is usually a painless condition except in TB larynx).

TB larynx findings :

- mammillated arytenoids : First part affected.
- mouse nibbled vocal cords.
- Turban epiglottis or pseudo edema.

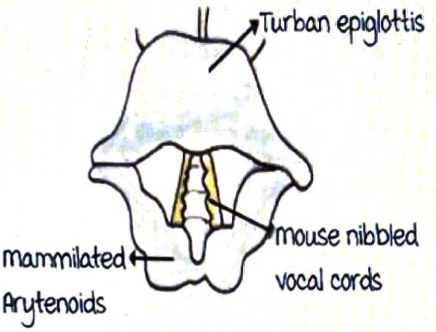

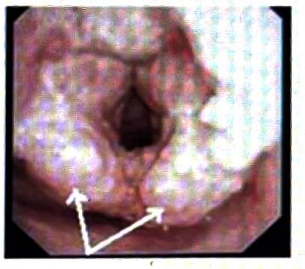

Diagnosis : Biopsy.

Management : Anti tubercular therapy (ATT).

60c6b3eeaa8ded0e4e7e5ea7

Active space

475
Leave Feedba

CONGENITAL CONDITIONS OF LARYNX

MC congenital anomaly : Laryngomalacia.
2nd MC congenital anomaly : Vocal cord palsy.
3rd MC congenital anomaly : Subglottic stenosis.

60c6b3eeaa8ded0e4e7e5ea7
00:01:40

Laryngomalacia

m/c congenital anomaly in children.
Also known as congenital laryngeal stridor.

Presents either at birth or little later.

Stridor → Inspiratory type.

- Worsens on lying supine, playing and crying.
- Decreases while sleeping.
- Disappears on prone position.
- Odynophagia is absent.
- Signs of respiratory distress and cyanosis are absent.

Diagnosis on endoscopy :

- Epiglottis → Enlarged, curled up, omega shaped.
- Aryepiglottic fold → Short and floppy.
- Arytenoids → Enlarged.
- Excessive lax tissue in the supraglottis.

Active space

Leave Feedba

Management :

- Conservative.
- Disappears by 2 years of age.
- If persistent, it is due to excessive lax tissue and if required → Supraglottoplasty.

Subglottic stenosis 00:12:00

3rd m/c congenital anomaly of larynx.
Sub-glottic diameter in full term → ≤ 4mm.
In pre term → < 3mm.
This is termed as congenital subglottic stenosis.

It can also be acquired.
MC cause of acquired subglottic stenosis is prolonged intubation.
This can be prevented by shift to tracheostomy after 2-3 weeks.
History of prolonged intubation should be noted.

Presents with biphasic stridor.
Best investigation → Rigid endoscopy.
Graded by Meyer-cotton grading.

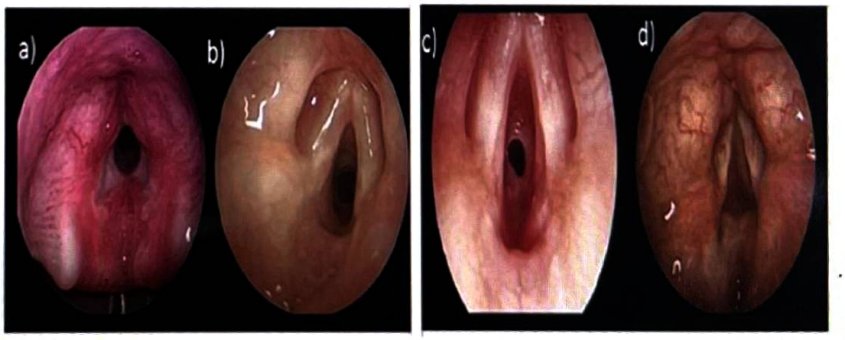

60c6b3eeaa8ded0e4e7e5ea7

Classification	From	To	Endoscopic appearance
I	No obstruction	50% Grade I stenosis	
II	51%	70%	
III	71%	99%	
IV	No detectable lumen		

Active space

Leave Feedback

management depends on grading :
Grade I → No management required.
Grade II & early Grade III → Graft is placed posteriorly (MC coastal cartilage graft).
Grade III (late) & Grade IV → Graft placed both anteriorly and posteriorly.
If symptoms does not subsided, cricotracheal resection.
In early and immature → Balloon dilatation.

To prevent restenosis → Mitomycin C.
Stent is placed called as Montgomery tube.
Gives support.
Prevents restenosis following surgery.
Also used for respiration.

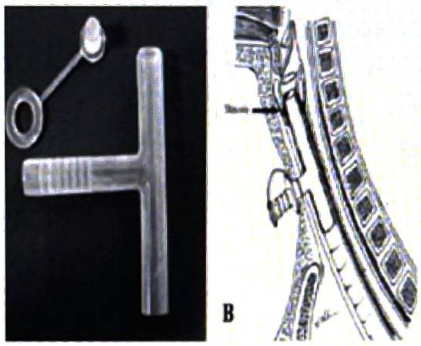

Laryngeal web

00:23:33

Cause : Due to incomplete recanalization of larynx during development.
MC site : Anterior part of glottis.
Voice/ cry : Weak cry.
Stridor : Inspiratory/biphasic.
Diagnosed by endoscopy.
Management :
Excision with Knife or laser (Co_2).
Laryngeal keel → Prevents adhesions after surgery (for 2 weeks).

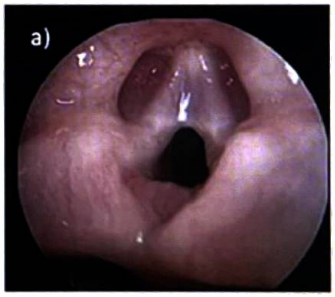

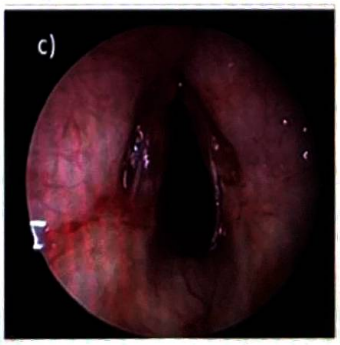

kumarankitindia1@gmail.com

Active space

Leave Feedba

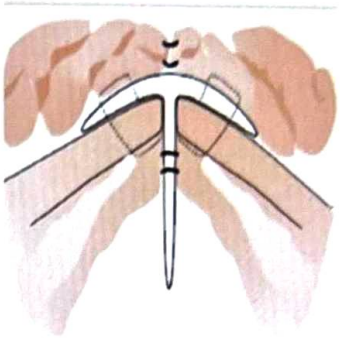

Child with biphasic stridor & lesions on the face → Suspect and rule out subglottic hemangioma.

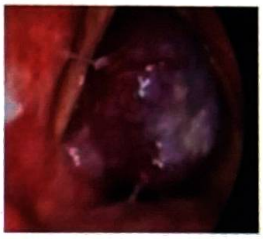

may be localized to one part or may be a large hemangioma.

Management :
First line : Propranolol.
Steroids injections.
Sub mucous resection : Laryngofissure.
CO_2 laser.
They may involute and disappear by 5 years.
If not, management remains same.

Laryngeal papillomatosis 00:31:12

AKA Recurrent respiratory papillomatosis.
Acquired condition ; Bimodal age occurrence.
Caused by Human papilloma virus.
Strains → 6 and 11 (more virulent).
Adult → Single.
Premalignant more in adult (due to smoking, post radiation).

Juvenile laryngeal papillomatosis in infants → H/O vaginal delivery.

Multiple papilloma in true vocal cord.

Active space

Predilection to grow in squamociliary junction.
Other sites → Nasopharynx, oropharynx.

H/O Prolonged 2nd stage of labour.
Hoarseness.
Stridor.

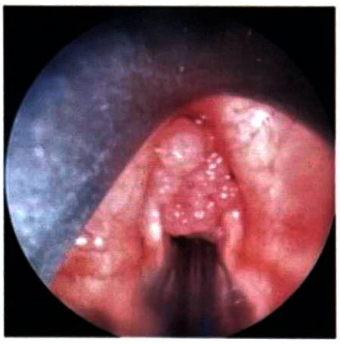

Diagnosis → Endoscopy.
Biopsy.

Management :
Excision by microdebrider.
Tracheostomy not done.
Laser CO_2 used very rarely.
Recurrence → Present.

Post operative : A, B, C.
A : α interferon immunomodulator.
B : Bevacizumab (reduces angiogenesis).
C : Cedofovir (intralesional).
Prevented by vaccination for mothers → Cervarix, gardasil-9.

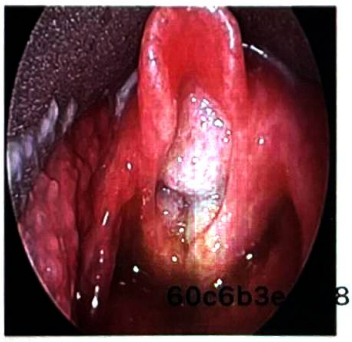

60c6b3e 8ded0e4e7e5ea7
Active space

Leave Feedbac

VOICE DISORDERS

Vocal cords/glottis

00:00:58

Part of the larynx responsible for phonation : Vocal cords/ glottis.

Presentation of vocal cord disorders :

- Hoarseness of voice.
- Change of voice.
- Dysphonia.
- Aphonia.

Involvement of the vocal cords can be due to :

- Infection.
- Neuromuscular involvement (nerve palsies).
- Structural lesions.
- Psychogenic/functional disorders.

60c6b3eeaa8ded0e4e7e5ea7

Structural abnormalities of the vocal cords :
Due to changes in the structure of the vocal cords like swelling/nodule/edema of the vocal cords.
Presentation : Hoarseness of voice.
Main etiological factors :

- Voice abuse.
- Laryngopharyngeal reflux.
- Smoking.

Diagnosis by laryngeal endoscopy.

Vocal nodules

00:05:53

Appearance and size : B/L, symmetrical, small (3 mm), sessile nodules.
Site : Junction of anterior 1/3rd and posterior 2/3rd of the vocal cords (site of maximum vibration of the vocal cords).

- Anterior 2/3rd of the vocal cords is membranous.

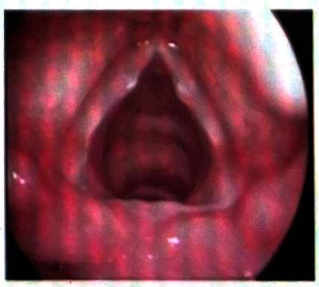

Active space

Leave Feedba

- Posterior 1/3rd of the cords is cartilagenous.

Maximum vibration occurs at :

- The midpoint of the membranous part.
- Junction of anterior 1/3rd and posterior 2/3rd.
- Junction of anterior 1/3rd and middle 1/3rd.

Main etiological factor : Chronic voice abuse against background noise.

Seen in : Teachers, vendors, singers.

AKA : Teacher's nodule/singer's nodule/screamer's nodule.

Diagnosis : Laryngeal endoscopy.

Management :

Voice rest and speech therapy is sufficient.

Management of the reflux.

If the nodule does not regress : Excision.

Vocal polyps

00:10:39

Appearance : U/L, pedunculated, polypoidal mass.

Size : > 3 mm.

60c6b3eeaa8ded0e4e7e5ea7

Site : Junction of anterior 1/3rd and posterior 2/3rd.

Main etiological factor : Voice abuse (sudden episode of voice abuse in an unprepared larynx causing sudden hemorrhage in the submucosal tissue of the true vocal cords).

Seen in : Protest, fight.

Diagnosis : Laryngeal endoscopy.

Management : Excision by MLS.

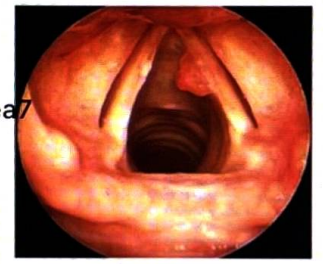

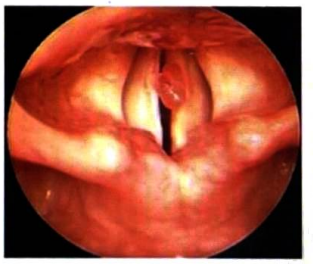

microlaryngeal surgery

Active space

Leave Feedbac

Position of the patient : The axis of the larynx should be brought along the axis of the mouth by :

- Extension of the atlanto-occipital joint.
- Flexion at the cervico-thoracic joint cervical joint/neck joint.

This is known as boyce position/ chevalier jackson position/ barking dog position/sniffing the morning air position.

Rose's position : Extension at both atlanto-occipital and the cervico-thoracic joint.

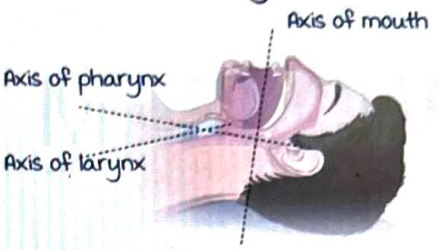

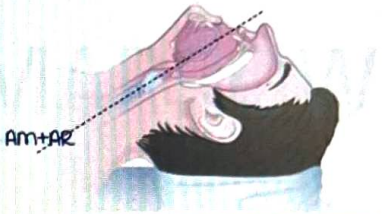

magnified view of the polyp

Vocal cord cysts

00:16:36

Cause : Voice/phonotrauma.
Site : Free edge of the vocal cords.
Diagnosis by stroboscopy which is attached to the flexible or the rigid endoscope.

kumarankitindia1@gmail.com

Flashes of light are given on the vocal cords which results in the appearance of individual waves of vocal cords separately. This helps to differentiate between nodule/polyp/cyst distinctly.
Management : Excision by MLS.

Arytenoid granuloma

00:21:19

Site : Posterior 1/3rd of the vocal cords/vocal processes of the arytenoids/cartilagenous part of the vocal cords.
It can be unilateral /bilateral.
Etiology :

- Voice abuse.
- Laryngopharyngeal reflux.
- Smoking.
- Trauma (intubation).

Active space

Leave Feedback

AKA :

- If due to voice abuse : Contact ulcer (misnomer)/contact pachydermia (heaping up of the epithelium on one side due to repeated contact).
- If due to laryngopharyngeal reflux : Peptic granuloma.
- If due to trauma from intubation : Intubation granuloma.

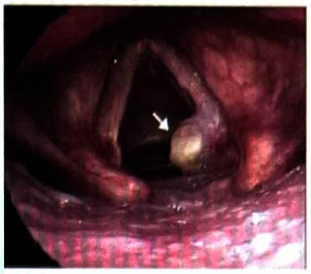

Arytenoid granuloma

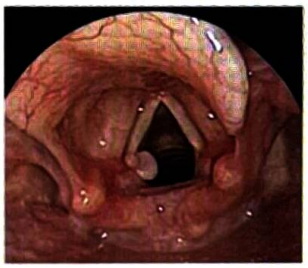

Presentation : Hoarseness of voice.

Diagnosis : Laryngeal endoscopy.

Management :

- Voice rest.
- Management of the reflux.
- If there is no benefit : Excision followed by injection of botox in the thyroarytenoid muscle.

Biopsy of the excised tissue should be sent for histopathology to rule out carcinomas.

Rinke's edema

60c0b5eeaa8ded0e4e7e5ea7 00:27:59

Site : Rinke's space (submucosal space of the vocal cords).

Entire length of the vocal cord is affected.

It is always bilateral.

Etiology :

- Chronic smoking (predominant factor).
- Voice abuse.
- LPR.

The mucosa of the vocal cords is not tightly adherent to the underlying vocal ligament.

Lymphatic supply to the submucosa is also poor, making it more prone for the development of edema.

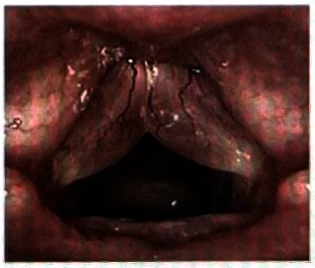

AKA : Smoker's larynx.

Active space

Leave Feedba

Management :

- Smoking cessation.
- Management of the reflux.
- Voice rest and speech therapy.

If there is no benefit : Reduction glottoplasty (incision on the upper surface of the vocal cord and reflection of the mucosa followed by suction of the edematous/excess mucosal tissue and reposition of the mucosa).

Pseudosulcus 00:31:39

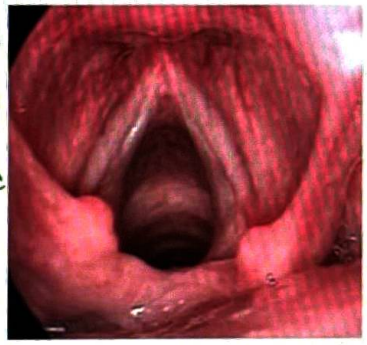

Site : Entire length affected
Appearance : Formation of a sulcus on the medial surface of the vocal cords which occurs due to infraglottic edema.
Etiology : LPR.
Management : Reflux management.

Sulcus vocalis : Congenital abnormality where epithelium of the true vocal cord is adherent to the vocal ligament on its medial/free surface (true sulcus).

Functional disorders of the vocal cords 00:37:03

muscle tension disorder/dysphonia (MTD) :
Voice fatigue which occurs due to alteration in the tension of the muscles of phonation due to stressful conditions.

60c0b3eeaa8ded0e4e7e5ea7

Psychogenic dysphonia/functional aphonia/hysterical aphonia:

- Seen in emotionally labile females.
- Presents with sudden loss of voice.
- On examination of the larynx, vocal cords remain in abduction even when the patient tries to phonate but adduction of the vocal cords occurs when the patient is asked to cough (rules out nerve palsies).
- There is h/o a stressful event.
- Management : Psychotherapy.

Active space

Leave Feedba

Dysphonia plica ventricularis :
Type of voice : Hoarse, husky, low-pitched voice.
Voice produced by : Ventricular folds/false vocal cords/ vestibular folds.
Cause :

- Functional.
- Nerve palsies.

Management : Speech therapy.

Puberophonia/mutational falsetto 00:45:05

At puberty, the voice of a male changes to a low pitched voice due to the growth of the vocal cords much more than the anteroposterior diameter of the larynx leading to relaxation/loosening of the vocal cords (low pitch).

If this growth of the vocal cords fails to occurs at puberty, the vocal cords remain stretched resulting in the persistence of high pitched female voice.

Seen in : Pubertal males (usually introverts).
Cause : Abnormal increased tension of the vocal cords.
Gutzmann pressure test : Larynx is pushed posteriorly and downwards (voice becomes low pitched).
Management :
kumarankitindia1@gmail.com
If the Gutzmann pressure test is positive : Surgery is done to relax/shorten the vocal cords (type III thyroplasty).

Phonesthenia 00:49:50

Voice fatigue/phonesthenia due to weakness of the muscles of the vocal cords which is precipitated by voice abuse under stressful conditions.
Types (depending on the types of muscles involved) :

- Phonesthenia of the thyroaryteoid muscle weakness : Phonatory gap (elliptical gap).
- Phonesthenia due to interarytenoid muscle weakness : Triangular gap posteriorly.
- Phonesthenia due to thyroarytenoid and interarytenoid muscles involvement : Key hole appearance of larynx.

Management : Voice rest and speech therapy.

Active space

Leave Feedba

Elliptical gap

Triangular gap

Keyhole gap

Spasmodic dysphonia

00:52:53

Neurological condition resembling MTD, functional dysphonia.
Cause : Dysphonia due to spasm of the muscles of phonation.
Other features :

- Oromandibular dystonia.
- Blepharospam.

Functional voice disorders : Complaints of voice fatigue is present during all the conditions.
Spasmodic dysphonia : Spasm of the muscles of vocal cords only during phonation and not during laughing/singing/respiration.

Types of spasmodic dysphonia

- Adductor dysphonia (MC) : spasm during adduction.

Voice type : Scratchy/creeky/strangulated/croaky voice.

- Abductor dysphonia : Spasm during abduction.

Voice type : Breathy voice.

- Mixed variety.

Management : Botox.

- In adductor dysphonia : Botox is injected in the thyroarytenoid muscle.
- In abductor dysphonia : Botox is injected in the posterior cricoarytenoid muscle.

Active space

Leave Feedba

NERVE SUPPLY OF LARYNX AND VOCAL CORD PALSY

Nerve supply of larynx 00:01:30

The larynx is supplied by the Vagus nerve.
Vagus nerve emerges from jugular foramen along with 9th and 11th cranial nerves.

The Vagus nerve has 2 ganglions.

- Superior ganglion.
- Inferior ganglion.

Superior ganglion gives rise to Arnold's nerve (Auricular branch).
Pharyngeal branch of Vagus nerve forms pharyngeal plexus along with 9th cranial nerve and sympathetic chain.
Inferior ganglion gives rise to superior laryngeal nerve (SLN).

SLN divides at the level of hyoid into :

1. Internal laryngeal nerve (ILN)
    - Pierces thyrohyoid membrane and enters larynx at upper border of inferior constrictor.
    - Sensory supply to supraglottis and upper part of hypopharynx.
    - ILN injury : Repeated aspiration.
2. External laryngeal nerve (ELN)
    - Supplies the only intrinsic muscle lying externally : Cricothyroid muscle (Tensor)
    - ELN accompanies Superior thyroid artery.

60c6b3eeaa8ded0e4e7e5ea7

Active space

Leave Feedbac

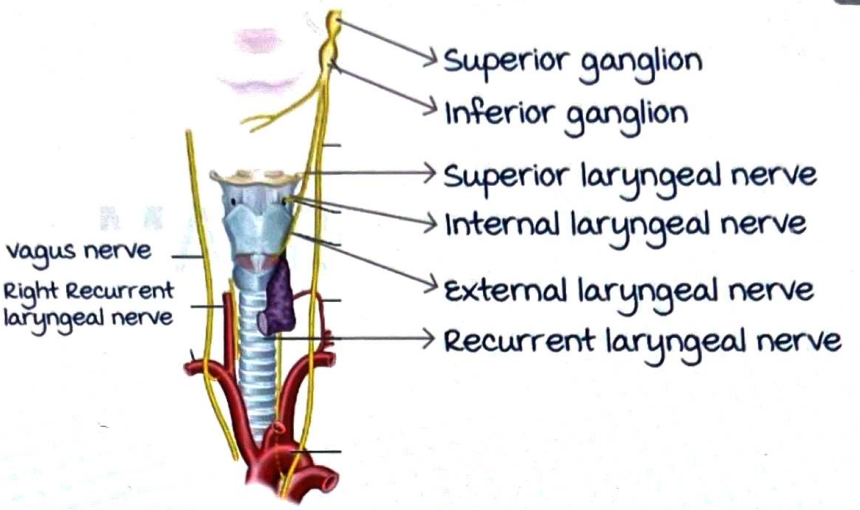

Recurrent laryngeal nerve

00:05:30

60c6b3eeaa8ded0e4e7e5ea7

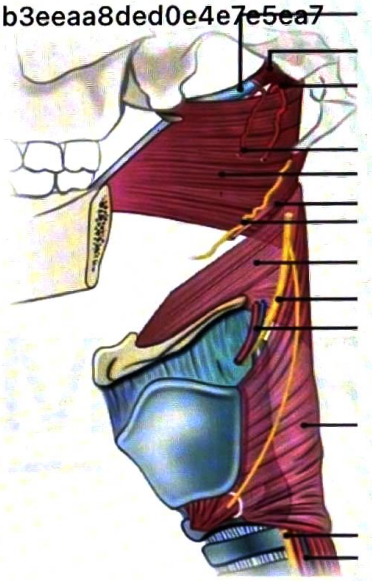

- Enters larynx between inferior constrictor and oesophagus : Lower border of inferior constrictor, behind cricothyroid joint.
- Left RLN :
  The branch is given at arch of aorta.
  It ascends in tracheoesophageal groove and enters larynx.
  It is prone to injury in the mediastinum.
  It has a longer course than right RLN hence more prone to injury.
  Cardiovagal syndrome : In Ortner's syndrome enlarged left atrium compresses left RLN.
- Right RLN :
  The branch is given at subclavian artery.
  It runs in the tracheoesophageal groove.
  It is more prone to be injured in the neck, compared to left RLN.
- RLN gives sensory supply to glottis and subglottis.

Active space

Leave Feedback

- It is the major motor supply of the larynx (All muscles except cricothyroid)
- RLN enters larynx with inferior thyroid artery.

Nerve injury associated with base of skull surgery :

- There may be complete palsy of the whole vagus, including pharyngeal branch (Dysphagia, regurgitation).
- Other cranial nerves may be involved.

Nerve injury associated with carotid triangle surgery : ILN, ELN or SLN.

Nerve injury associated with cervical spine surgeries : Right and left RLN.

Nerve supply of larynx :

Sensory	motor
Supraglottis : ILN Glottis : RLN Subglottis : RLN	All muscles except cricothyroid : RLN Cricothyroid : ELN

Positions of the vocal cords

00:15:51

Position of vocal cords	Distance from midline	Action
Median	At midline	Phonation
Paramedian :	1.5 mm	Whispering
Intermediate/ cadaveric	3.5 mm	Complete palsy
Abduction (slight)	7 mm	Normal respiration
Abduction (full)	9.5 mm	Forced respiration

kumarankitindia1@gmail.com

Active space

Leave Feedba

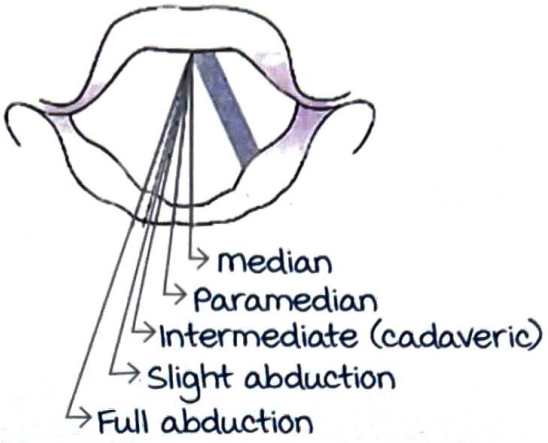

Vocal cord palsy

00:22:25

Complete/ adductor/ SLN + RLN	Incomplete/ abductor/ RLN
Cadaveric/ Intermediate position	median/ paramedian position Wagner and Grossman theory : In RLN palsy, all muscles are gone except cricothyroid keeping vocal cords in median position.

60c6b3eeaa8ded0e4e7e5ea7

Clinical presentations of vocal cord palsy

00:28:00

	Incomplete (Abductor) palsy		Complete (Adductor) palsy	
	Unilateral RLN	Bilateral RLN	Unilateral	Bilateral
Speech	Normal/ slight hoarseness.	Normal	Aphonia, dysphonia.	Aphonia
Respiration	Normal	Stridor	Normal	Normal
Aspiration	Absent	Absent	Occasional	Chronic aspiration.
Management	Conservative	Tracheostomy followed by lateralisation of 1 vocal cord.	medialisation of vocal cord. Aphonia corrected.	Tracheostomy followed by Epiglottopexy. Only aspiration corrected.
SLN ILN	Aspiration.			
ELN	Inability to increase pitch of sound. Vocal cord position : Skewed/ bowed.			

Active space

Leave Feedback

most common cause of unilateral and bilateral RLN injury : Thyroid surgery.
maximum stridor is seen in bilateral incomplete palsy.

Medialisation and lateralisation of vocal cords 00:46:55

medialisation : Inject laterally :

- Collagen
- Silicone
- Fat
- Calcium hydroxyapatite.
- Teflon (not preferred due to granulation).

Lateralisation :

1. Cordectomy and arytenoidectomy.
   - Woodman's procedure
   - Kashima's procedure

2. Cordopexy : Burning a portion of vocal cord using laser.

Thyroplasty : Thyroid framework surgery.
Mnemonic : Thyro-PLASTY

i. Proximalisation/ medialisation : Unilateral complete.
ii. Lateralisation : Bilateral RLN.
iii. Shortening : Puberophonia.
iv. Tightening/ lengthening : Androphonia.

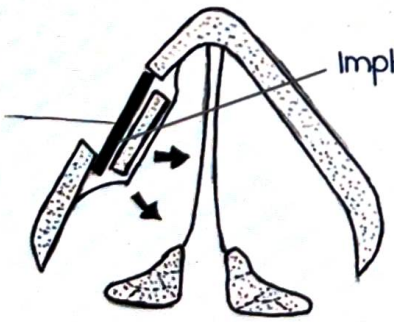

Type 1 Thyroplasty
medialisation of vocal cord

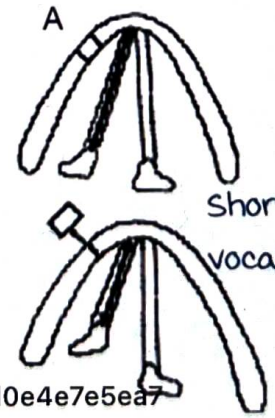

60c6b3eeaa8ded0e4e7e5ea7

Active space

Leave Feedba

Puberophonia

00:53:20

It is also known as mutational falsetto.

Normally in an adult male the larynx diameter increases.

Vocal cord length increases more than the larynx diameter.

↓

Vocal cord becomes lax.

↓

Voice becomes low in pitch.

In puberophonia : Adult male voice remains high pitch.

Management :

Type 3 thyroplasty (Shortening/ relaxation of vocal cord).

- Done if Gutzmann's pressure test is positive. (Posterior and downward compression of thyroid results in low pitched voice).

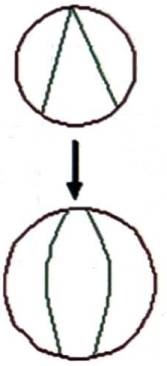

Q. Maximum stridor is seen in :

A. U/L Incomplete.

B. U/L Complete.

C. B/L Incomplete.

D. B/L Complete.

Q. In B/L abductor palsy following is done except :

A. Teflon paste injection.

B. Cordectomy.

C. Nerve muscle implant.

D. Arytenoidectomy.

Q. Aphonia of adductor palsy can be overcome by :

A. Tracheostomy.

B. Arytenoidectomy.

C. Teflon injection.

D. Type II thyroplasty.

kumarankitindia1@gmail.com

Q. 30 year old female following URTI presents with stridor. It can be managed by all the following except :

a. Tracheostomy.

b. Cordectomy.

c. Type I thyroplasty.

d. Type II thyroplasty.

Active space

493
Leave Feedba

CARCINOMA LARYNX

Clinical presentation 00:02:00

Most common variant of carcinoma → Squamous cell carcinoma (SCC).
Male > Female.
Predisposing factors :
60c6b3eeaa8ded0e4e7e5ea7
Smoking (most common), alcohol,
Human papilloma virus infection, Irradiation to the neck.

Most common site → Glottis > Supraglottis > Subglottis.
Least lymphatic metastasis → Glottis (Best prognosis)
Maximum Lymphatic metastasis → Supraglottis (to upper deep cervical and middle deep cervical lymph nodes).
Bilateral lymph node metastasis→: Supraglottic carcinoma (epiglottis).

Presentation :
Glottic carcinoma → Earliest presentation due to hoarseness in voice.
Supraglottic carcinoma → Dysphagia, Lymph node enlargment.
Subglottic carccinoma → Stridor.
Pain in the ear → Referred pain by vagus nerve. Seen in laryngeal carcinoma of any part (Arnold's nerve).

Most common variant of carcinoma in all ENT cases → SCC.
Except few like :
Skin exposed to sun → Basal cell carcinoma.
Carcinoma of Paranasal sinus exposed to wood dust → Adenocarcinoma.

Clinical scenario :
50 year old male who is a chronic smoker presents with horaseness in voice for more than 3 weeks. Next step is?
Laryngeal Endoscopy.

Active space

Leave Feedbac

Carcinoma Larynx : Investigations 00:09:00

Laryngeal Endoscopy : Irregular ulceroproliferative mass seen on vocal cords.

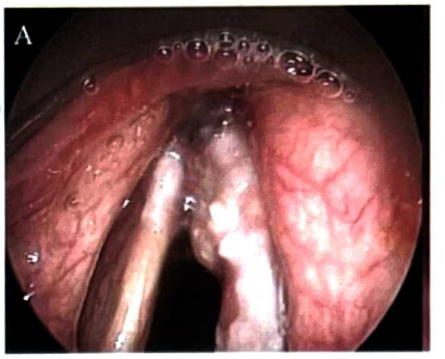

Biopsy : For confirmation.
Done under General anesthesia.
If epiglottic growth/ high up in supraglottis : Can be done under Local anesthesia.
Internal laryngeal nerve is anesthetized just below the hyoid at the thyrohyoid membrane.

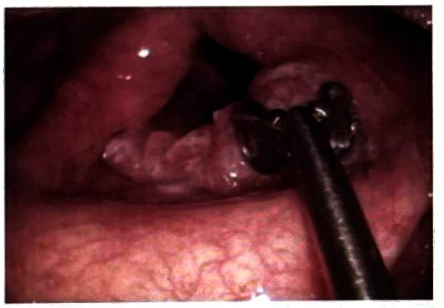

Examination of neck :

- For enlargement of lymph nodes.
- Laryngeal crepitus → Absent if the tumor is extended post cricoid.
  Noted by pushing the larynx posteriorly and moving it sideways. Cricoid is rubbed against vertebrae.

CT + MRI :
CT shows bone involvement.
MRI to look for invasion of cartilage.

TNM Staging of Carcinoma Larynx 00:15:30

T1 : Only one site/subsite involved (one named structure).
With both vocal cords mobile.
T1a : Only one vocal cord involved.
T1b : Involvement of both vocal cords.
T2 : Spread to adjacent sites /subsites.
T2a : With both vocal cords are mobile.
T2b : slight impairment in mobility of vocal cord.
T3 : Fixed vocal cord.
Involvement of pre-epiglottic space/ para-glottic space/post cricoid space/ inner cortex of thyroid.
T4a : local invasion.

60c6b3eeaa8ded0e4e7e5ea7

Active space

Leave Feedba

Anteriorly :
- Thyroid cartilage.
- Thyroid gland.
- Strap muscles.

Superiorly : Tongue muscles.
Inferiorly : Trachea.
Posteriorly : Esophagus.

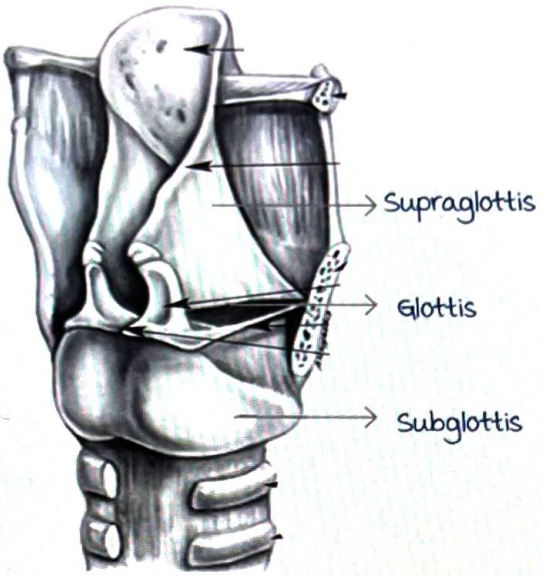

T4b : Unresectable.
Due to involvement of :
- Prevertebral space.
- Carotid sheath.
- mediastenum.

Transglottic tumor : Involvement of all 3 sites i.e, Supraglottis, glottis and subglottis or Paraglottic space.

Node staging →

N0 : No neck node involvement.
N1 : Single ipsilateral node involvement ; size ≤ 3 cm.
N2 : Size > 3 cm to 6 cm.
N2a : Single ipsilateral node involvement ; size >3 cm to 6 cm.
N2b : Multiple ipsilateral nodes involvement ; ipsilateral ; Size < 6 cm..
N2c : multiple / single nodes involvement but contralateral /bilateral ; Size < 6 cm.
N3 : Size > 6 cm.
N3a : Single ipsilateral node involvement ; size > 6 cm.
N3b : Extra nodal extension/ ENE.

N1 to N3a → ENE negative.

kumarankitindia1@gmail.com

Active space

Leave Feedba

Lymphatic spread

00:38:47

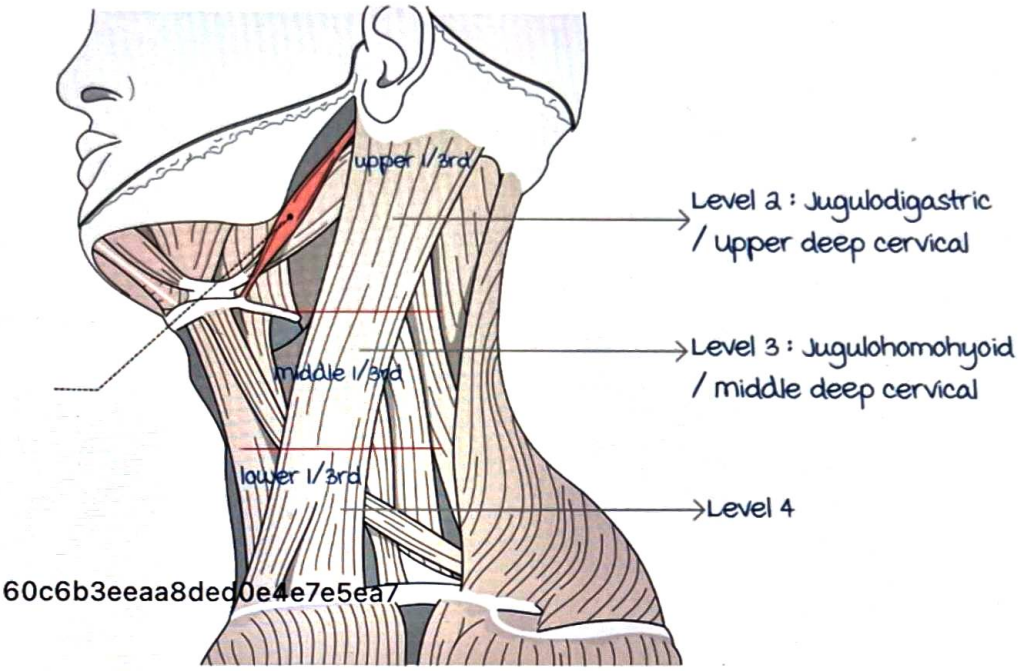

60c6b3eeaa8ded0e4e7e5ea7

Lymphatic drainage from larynx :
Supraglottis is to Level 2, 3 lymph nodes.
Subglottis is to level 4 lymph nodes,
and Level 6 / anterior group of lymph nodes :
Pretracheal and Precricoid / Delphian lymph nodes.

TNM staging :

Stage I → T1 N0 M0.
Stage II → T2 N0 M0.
Stage III → T3 N0 M0 / T 1, 2, 3 N 1 M0.
Stage IVa → T4 N0 M0 / T4 N 1 M0, T 1-4 N2 M0.
Stage IVb → T4b any N M0.
Stage IVc → Any T any N M 1.

Management

00:43:40

management based on tumour staging :

T1, T2 : Radiotherapy or TLm (Transoral Laser microsurgery).
T1a (Single mid-cord lesion) : TLM; no radiotherapy.
T1b, T2a : TLM / Radiotherapy (equal prognosis).
T2b : Radiotherapy (deeper invasion can be missed by TLM).
T3 : Concurrent chemo-radiotherapy.

Active space

T4a : Total Laryngectomy + Radiotherapy.
T4b : Palliative management.

Chemotherapeutic agents :
Cisplatin, Carboplatin, 5 fluorouracil
Extensive cartilage involment : Radiotherapy leads to radionecrosis, hence not advised.

60c6b3eeaa8ded0e4e7e5ea7
TLM cordectomy for glottic tumours :

Type 1 → Subepithelial cordectomy.
Type 2 → Subligamental cordectomy.
Type 3 → Transmuscular cordectomy.
Type 4 → Total cordectomy.
Type 5 → Extended cordectomy.

CO2 laser is used in TLM.

Clinical Scenario :
A patient presented with hoarseness of voice and difficulty in swallowing. On examination, a tumor biopsy revealed squamous cell carcinoma involving supraglottis and glottis with bilateral mobile vocal cords. What is the management of this patient :

Bilateral mobile vocal cords, hence T1 or T2 staging.
management is : Radiotherapy or TLm.

Laryngoscopy shows tumor of single mid vocal cord.

Active space

Leave Feedba

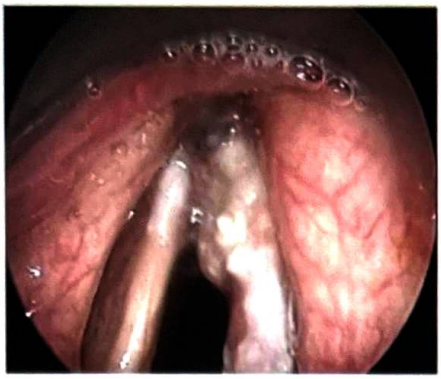

Tumor of larynx involving single vocal cord

Tumor of larynx involving supraglottis, epiglottis, false

Management of above cases if : vocal cords

Bilateral mobile vocal cords → Radiotherapy or TLm.
Impaired mobility of vocal cords → Radiotherapy is preferred.
Fixed vocal cords present → Concurrent chemo-radiotherapy.
Tumor spread to pre-epiglottic space/ para-glottic space/ post-cricoid space/ inner cortex of thyroid →
Concurrent chemo-radiotherapy.
Spread to thyroid cartilage (Thyroid perichondritis) →
Total laryngectomy followed by radiotherapy.

kumarankitindia1@gmail.com

Management of Subglottic carcinoma (rare) :
Early stage → Radiotherapy (TLM cannot be done).
Later stage → Total laryngectomy + Radiotherapy.

Management of Lymph nodes of neck 00:57:30

Tumor spread to lymph node (any N) is present treatment :
Based on primary tumor of larynx management, if
By surgery → Surgical (Radical / Modified radical) neck dissection.
By radiotherapy → Radiation of lymph nodes.

Lymph nodes :
Level I → Submental & Submandibular lymph nodes.
Level 5 → Posterior lymph nodes
(between sternocleidomastoid and trapezius).

Active space

Radical neck dissection	Modified Radical neck dissection
Lymph nodes removed I to V groups	Lymph nodes removed I to V groups
Non lymphatic Structures removed : • Spinal acessory nerve. • Internal jugular vein. • Sternocleidomastoid muscle. • Parotid & Submandibular salivary glands. • Omohyoid muscle.	Structures preserved : • I : Spinal acessory nerve. • II : Spinal acessory + Internal jugular vein. • III : Functional neck dissection : Spinal acessory nerve + Internal jugular vein + Sternocleidomastoid muscle.

Selective neck dissection → N_0 supraglottic carcinoma.
Lateral neck dissection → Lymph nodes II, III, IV
Due to high possibility of occult metastasis.

Management of recurrence following Radiotherapy :

T1, T2 → Open partial laryngectomy/ OPL :
Horizontal/ Supraglottic laryngectomy → Supraglottic CA.
Vertical laryngectomy / Hemilaryngectomy → Glottic CA.
(One half of Thyroid cartilage, True & false vocal cord)
Area removed as shown :

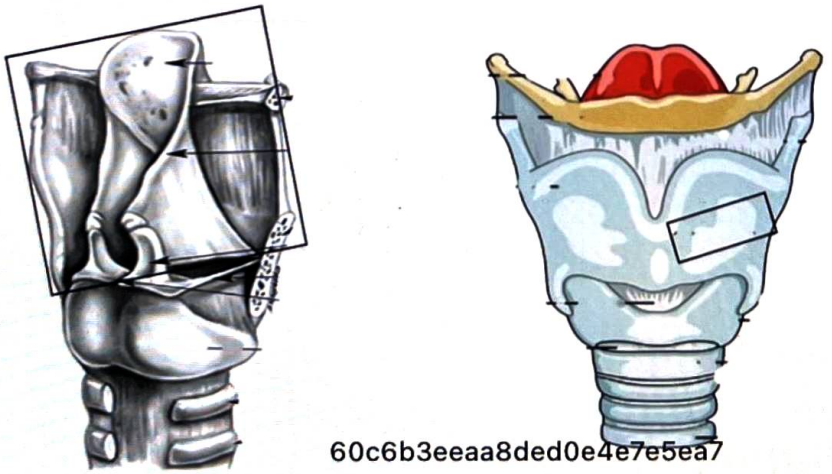
60c6b3eeaa8ded0e4e7e5ea7

Horizontal Laryngectomy Vertical Laryngectomy

T3, T4 → Total Laryngectomy.

Active space

Leave Feedba

Verrucous Carcinoma / Ackerman tumor :

- Variant of Squamous cell carcinoma.
- Locally invasive.
- No metastasis.
- Slow growing.
- Management : TLM / Radiotherapy.
- Can be seen in oral cavity as a whitish growth.

Permanent Tracheostome :

Is done following total laryngectomy, trachea is pulled out and sutured to the skin.

This allows for breathing.

60c6b3eeaa8ded0e4e7e5ea7

Modes of rehabilitation 01:13:30

Speech following laryngectomy.

1. Oesophageal speech → Swallowed air to be regurgitated to vibrate the hypopharyngeal segment to produce speech. Is a very difficult method to learn, was practiced earlier.

2. Trachoesophageal speech →
A one way valve is attached between the trachea and pharynx. Best form (lung powered air).
It allows for air to exit from trachea to pharynx, but food cannot enter the trachea from pharynx.

Active space

To speak the patient closes the opening of tracheostome during expiration. This air vibrates the pharynx, and is used by the patient to speak.
Valve used :

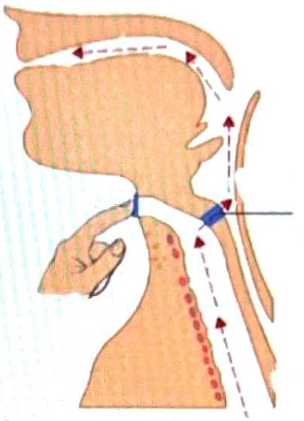

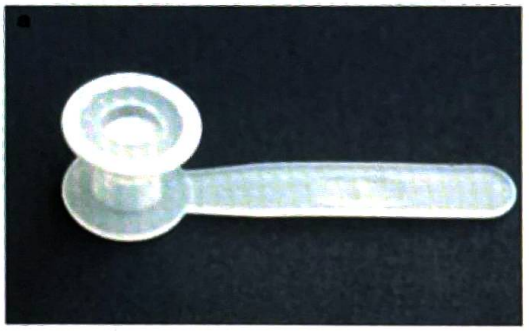

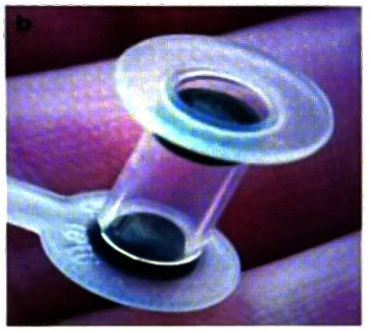

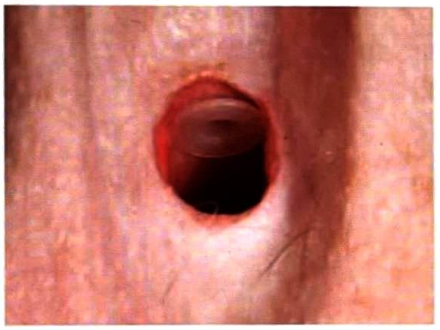

Blom singer and Panje valve prosthesis.

Trachoesophageal speech

Hands free trachoesophageal speech →
A button placed automatically closes the opening of tracheostome during speech. Granulations may form near the valve area and might need to ne closed then Electro larynx is used.

kumarankitindia1@gmail.com

3. Electrolarynx →
The device is placed over the neck which produces vibrations. It produces a monotonous robotic voice.

Active space

Leave Feedba

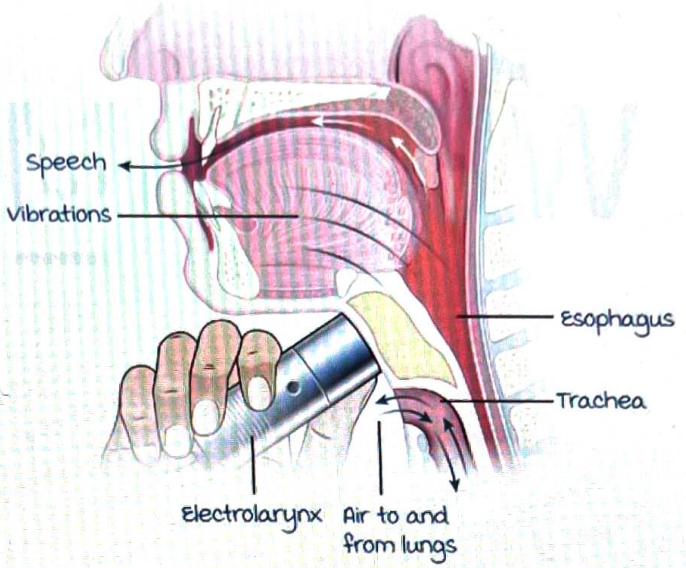

Heat and moisture exchanger →

Used for temperature regulation, humidification and filtering the air, prevents crusting of airways, cough and infections.

kumarankitindia1@gmail.com

Olfactory rehabilitation →

By polite yawning, by closed mouth which creates a negative pressure in the oral cavity, it induces expiration through nose.

In patients with tracheostome →

Inability to lift heavy weights & cough.

Active space

503
Leave Feedbac

TRACHEOSTOMY AND FOREIGN BODIES IN AIRWAYS

Tracheostomy → Opening in the anterior wall of trachea.

Indications of tracheostomy 00:00:26

Mnemonic : Occupy Most Seats in Medical Association.

- Obstruction above the level of trachea, i.e., infectious, tumours, trauma, foreign body, vocal cord palsy.
- Mechanical ventilation for prolonged period. (M/C indication of elective tracheostomy).
- Suction of secretions (intubated patients).

Coughing not possible : Phrenic nerve injury (C-spine injury)

- Maxillofacial, head and neck surgeries.
- Prevent Aspiration (B/L vocal cord palsy).

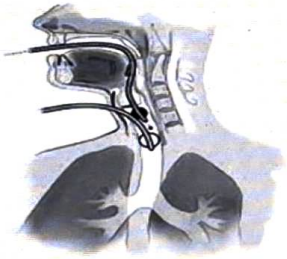

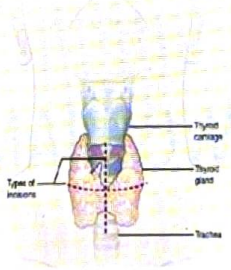

Position → Rose's position.

Extension at :

1. Atlanto occipital joint.
2. Cervicothoracic joint.

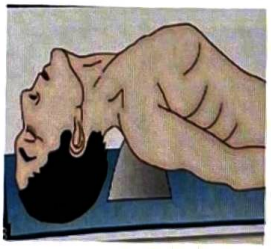

Incision depends on type of surgery.

Emergency tracheostomy → Vertical incision.

Vertical incision → Below cricoid to suprasternal notch.

Elective tracheostomy : Horizontal incision.

Horizontal incision : 2.5 cm above the suprasternal notch.

Incision given along the skin crease.

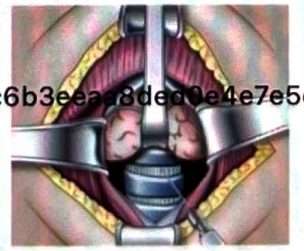

60c6b3eea38ded0e4e7e5ea7

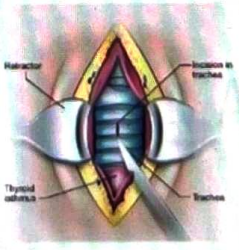

Active space

Leave Feedba

Tracheal incision : On T_2-T_4.

Procedure of tracheostomy 00:14:04

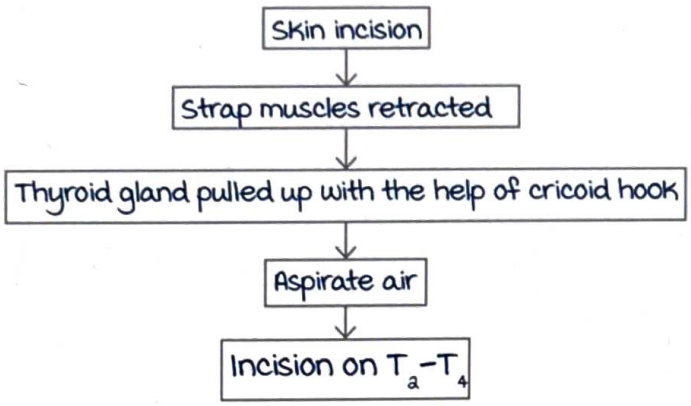

Never on T_1 :

If incision on 1st tracheal ring → High tracheostomy.

Complications of high tracheostomy → Sub glottic stenosis.

Only indication of high tracheostomy → Laryngeal carcinoma.

Bjork flap :

60c6b3eeaa8ded0e4e7e5ea7

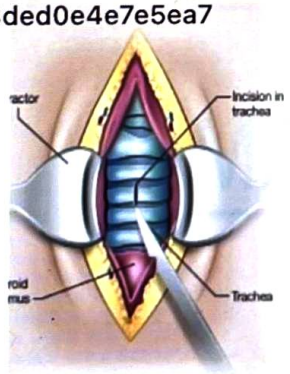

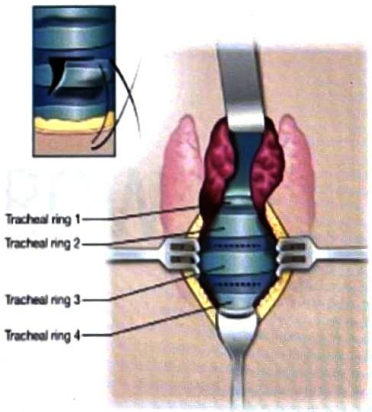

Portex cuffed tracheostomy tube :

High volume low pressure air tight seal.

Secured with the help of straps.

Active space

Leave Feedback

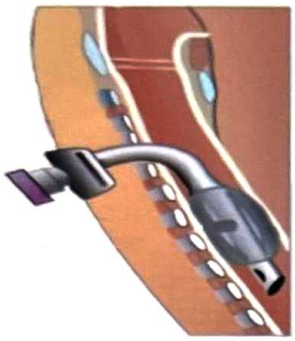

Differences in pediatric tracheostomy :

Skin → Vertical incision.

Tracheal incision on 3rd & 4th rings vertically.

Stay sutures → Edges of tracheal opening.

Post operative care

00:24:20

- Suctioning and cleaning with saline and sodium bicarbonate throughout the day.
- Permanent cuff deflation after 12 hours.
- Change to uncuffed tube :
  - Adult → After 3 days.
  - Child → After 7 days.
- Change of the uncuffed tube.

Metallic tubes :

2 tubes → Outer and inner tube.

Any crusting/occlusion → Inner tube is removed & cleaned.

Disadvantages → Corrosion, pressure necrosis, fistula formation.

Not in use now a days.

Opening in tracheostomy tube → Cuffed fenestrated tube.

Also done by Fuller's bivalved metallic tube.

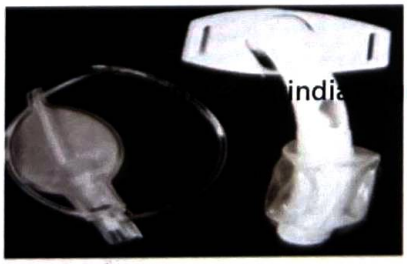

Active space

Leave Feedba

Complications 00:31:37

Immediate :

Mnemonic : HAAPI.

Hemorrhage (Inferior thyroid vein) ;
fatal hemorrhage of thyroidea ima, innominate artery.
Aspiration.
Apnoea → Carbogen.
Pneumothorax.
Injury to adjacent structures.

Intermediate :

- Tube obstruction (most common).
- Completely blocked tube mx → Remove and change the tube.
- Subcutaneous emphysema because of tube blockade.
- Fistula → Tracheo-esophageal fistula.

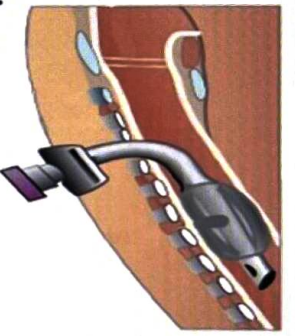

Late complications :

- Infections.
- Granulations.
- Tracheo-cutaneous fistula.
- Difficult decannulation :

Tracheostomy reduces dead space by 30-50% in children.

Foreign body in air passages 00:40:50

MC age → 1-4 years.
MC foreign bodies → Peanuts and nuts, parts of toys.
Earliest symptoms →

Paroxysmal coughing, choking, gagging.

Symptoms depending on site :

- Larynx :

  Partial → Hoarseness, cough, hemoptysis.
  Total obstruction → Respiratory distress.
- Trachea → Palpatory thud or audible slap.

  MC in right bronchus.

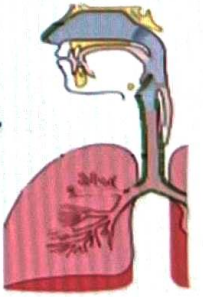

Active space
60c6b3eeaa8ded0e4e7e5ea7

- Until secondary bronchus → Expiratory stridor.
- Tertiary bronchi → Wheeze.
- Complete obstruction of bronchi → Atelectasis, reduced breath sounds.

Management :

If there is no respiratory distress, able to speak : Back blows and encourage coughing.

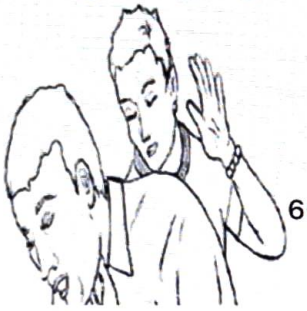

60c6b3eeaa8dcd0e4e7e5ea7

Universal choking sign :

Conscious, holding neck with hand and not able to speak, breathe and cough.

Heimlich maneuver

00:48:53

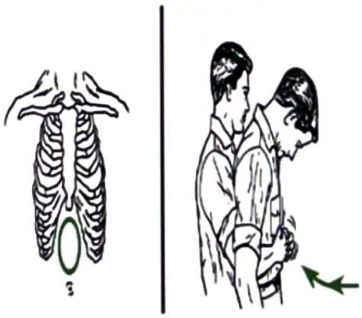

Stand behind the patient.

Make a fist with one hand & place other hand over the fist.

Keep your fist just below xiphisternum and press posteriorly and upwards.

This increases intrathoracic pressure and help foreign body come out.

Complications of Heimlich maneuver :

- Injury to abdominal organs.
- Perforation of esophagus.
- Rupture of stomach.
- Rib fracture.

Active space

Leave Feedba

Contraindications :

- Age < 1 year.
- Unconscious.
- Pregnancy → Higher back blows.

In infants → Chest thrusts.

Self heimlich → Chair thrust.

If visible foreign body → Finger sweep maneuver.

If first aid fails → Cricothyrotomy.

AKA Coniotomy/inferior laryngotomy/mini tracheostomy.

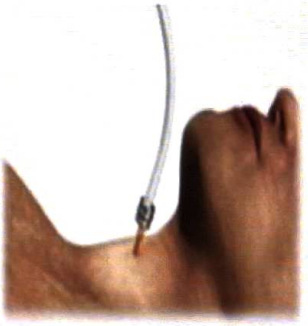

Take up the patient for removal of foreign body by laryngotracheal bronchoscopy (rigid endoscopy).

Radiology of foreign body in air passages 00:56:20

kumarankitindia1@gmail.com

Largest diameter of larynx : Antero-posterior diameter.

Largest diameter of Esophagus : Horizontal diameter.

AP view :

- En face on AP view → Esophagus.
- En face in saggital → Larynx/trachea.

Lateral view : See airway.

MC foreign body in esophagus → Coin.

MC site of foreign body in esophagus →
At or just below cricopharyngeal sphincter.

Active space

Leave Feedba

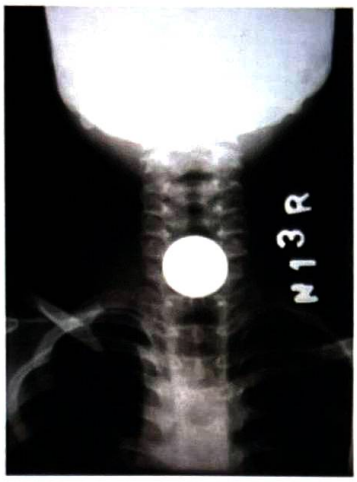

Esophagus

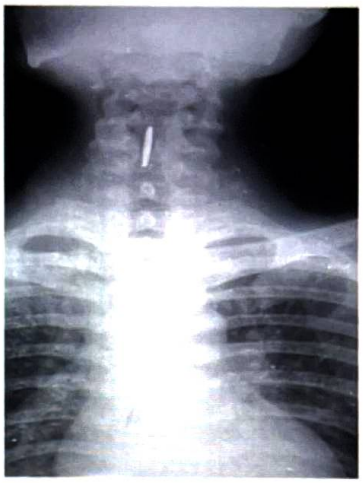

Larynx/Trachea

60c6b3eeaa8ded0e4e7e5ea7

Active space