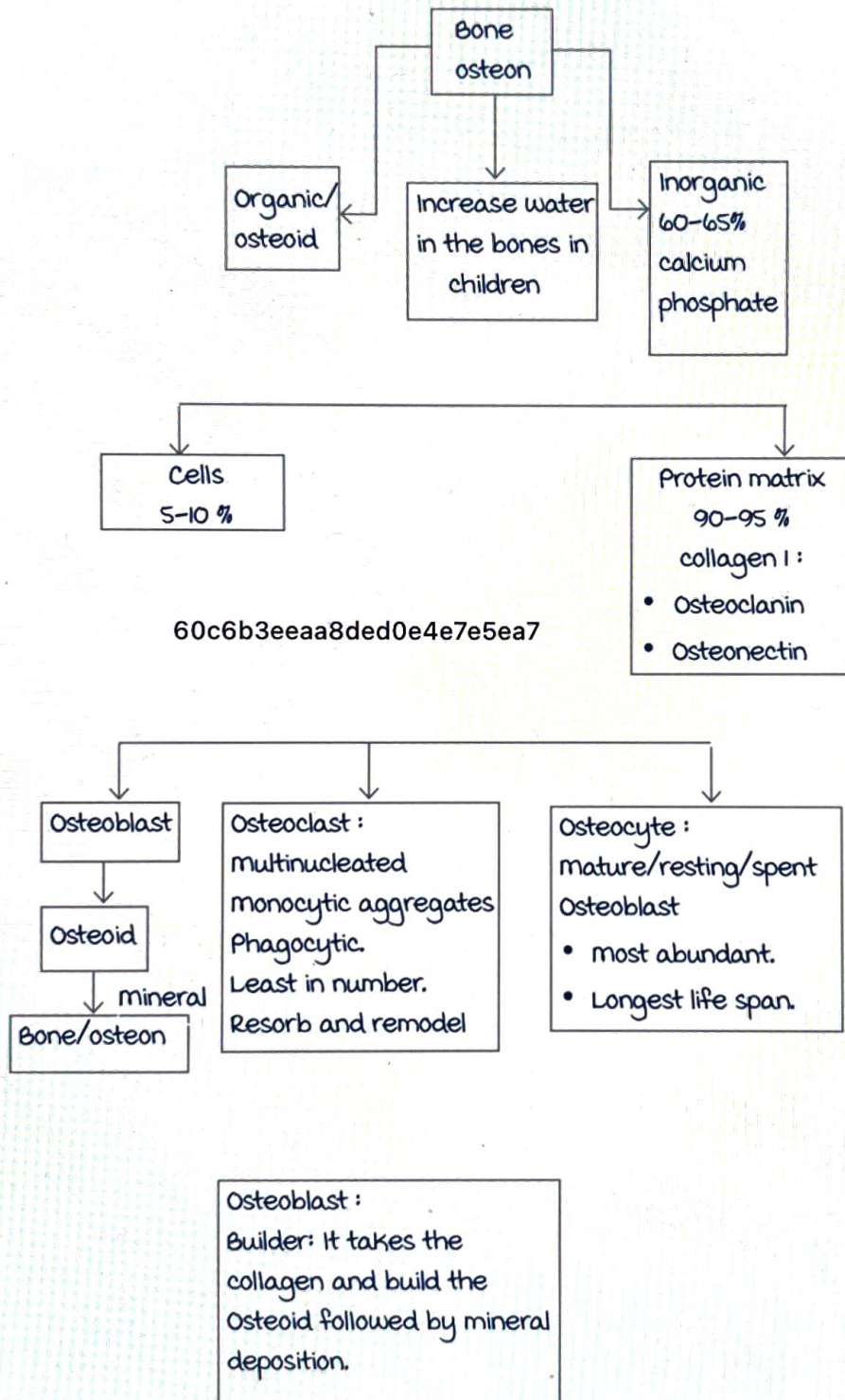


BASICS : HISTOLOGY AND PHYSIOLOGY OF BONES

Introduction

00:00:09



Commonly asked questions :

Osteon = Ostoid + mineral.

Collagen I → Bone & meniscus.

Collagen II → Hyaline cartilage (The articular cartilage lining the joint surface).

Composition of bone :

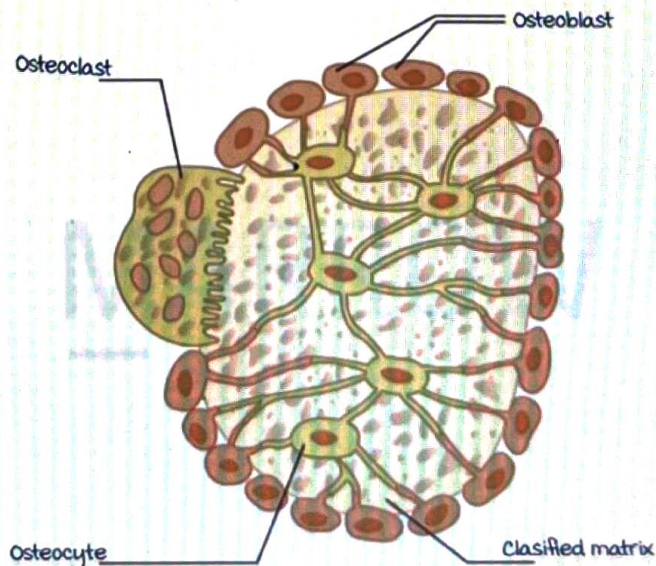
- Water content is more in children.
- Inorganic is predominant part.
- Bone is a combination of protein and mineral.
- Collagen in bone is type I, meniscus is I, IVD annulus fibrosis I.
- Type 2 is seen in articular hyaline cartilage, and nucleus pulposus of the intervertebral disc.

Osteoclasts

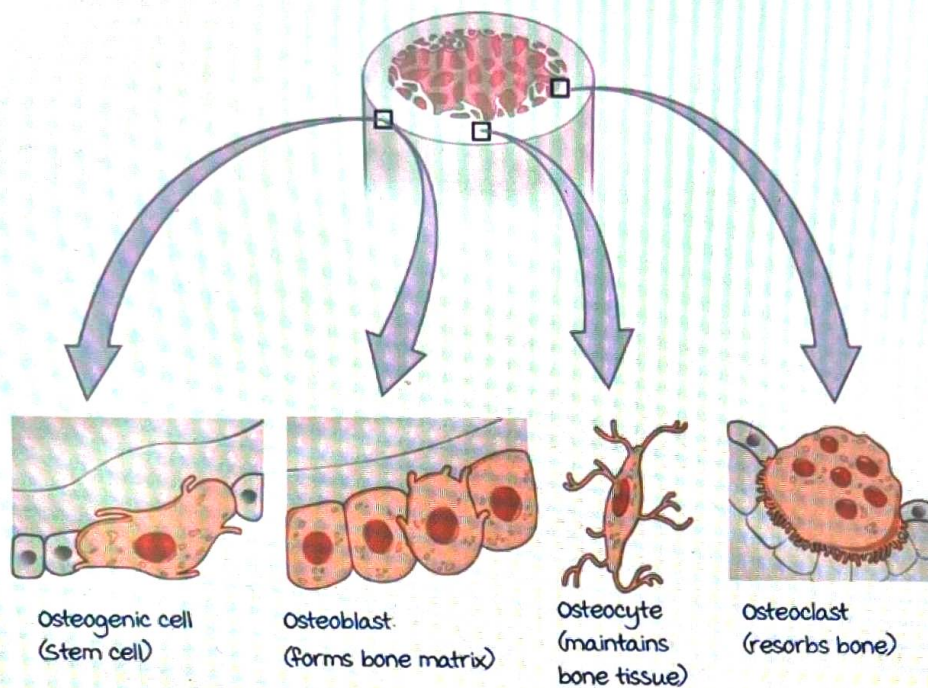
00:10:01

60c6b3eeaa8ded0e4e7e5ea7

- multinucleated giant cells, formed by aggregation of monocytes : **macrophages** of bone.
- They have ruffled borders (inward bendings of the cell membrane) to increase the surface area of contact.
- Strength of bone is derived both from osteoblast and osteoclast.
- **Osteoclast** : Rich in TRAP (Tartarate Resistant Acid Phosphatase) and Carbonic anhydrase.
- **Osteoblast** : Rich in **ALP (Alkaline Phosphatase)**.
- Osteoclasts remodel depending on the activity of a limb. Ex : A hemiplegic individual will have a low bone density.



Active space



Bone markers.

Bone formation markers :

- Procollagen I.
- Osteocalcin.
- Osteonectin.
- **ALP** (Alkaline phosphatase): When a bone breaks down the osteoblasts will act to resynthesis. As a result of this there will be elevated levels of ALP

Breakdown markers :

- Hydroxy proline.
- Hydroxy lysine.
- N and C telopeptide.
- TRAP (Tartrate resistant acid phosphatase).

Bone formation markers are elevated even when there is bone resorption → Bone turnover.

Parts of a long bone

00:15:14

The part that articulates with another bone is called the articulating part.

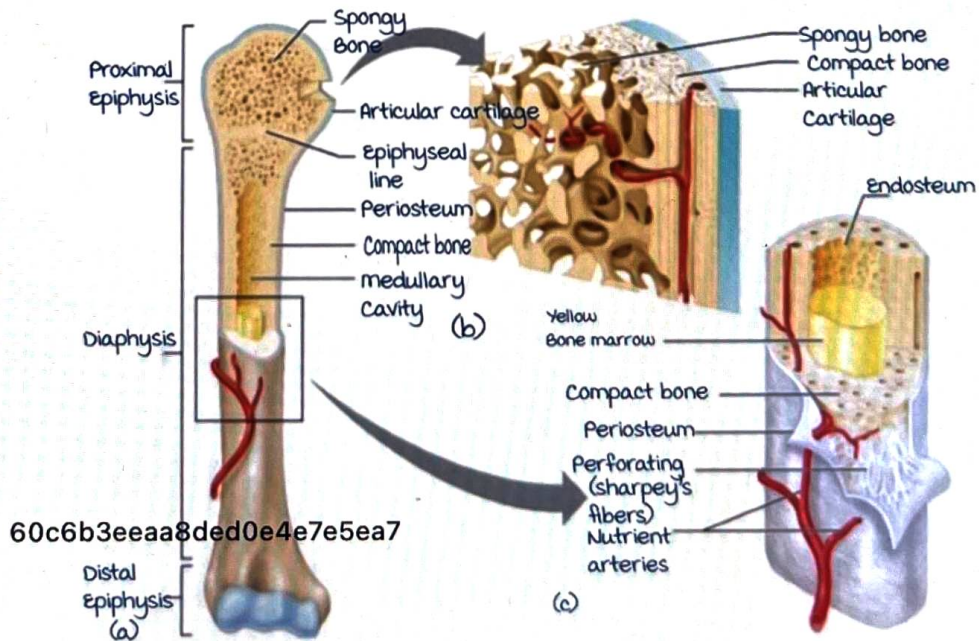
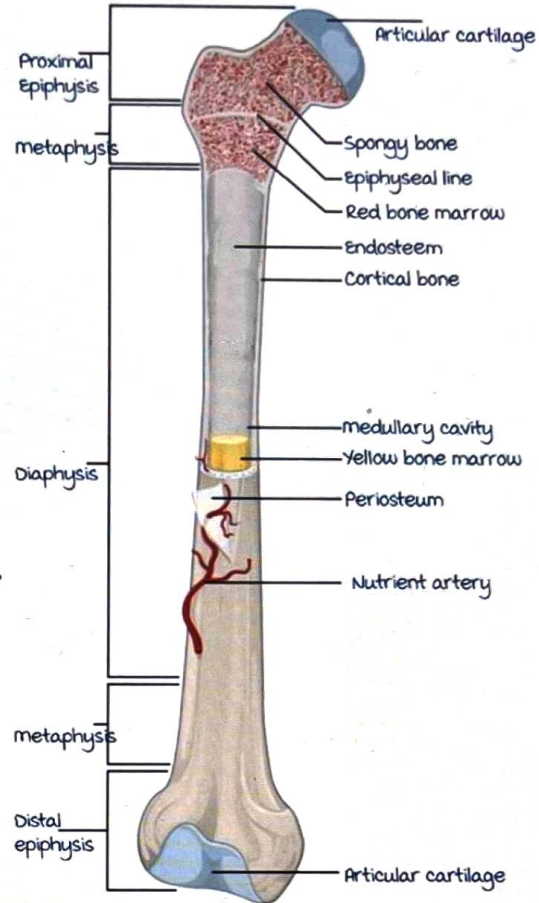
- Epiphysis.
- metaphysis.
- Diaphysis.

Active space

In children there is a cartilaginous **growth plate** between epiphysis and metaphysis.

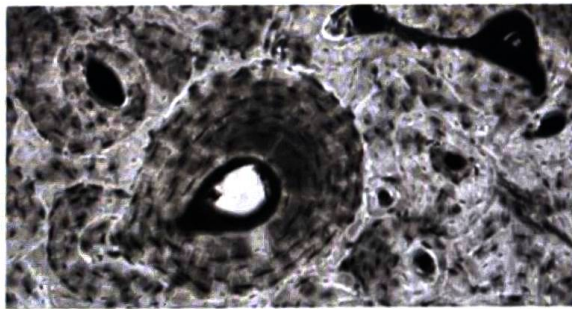
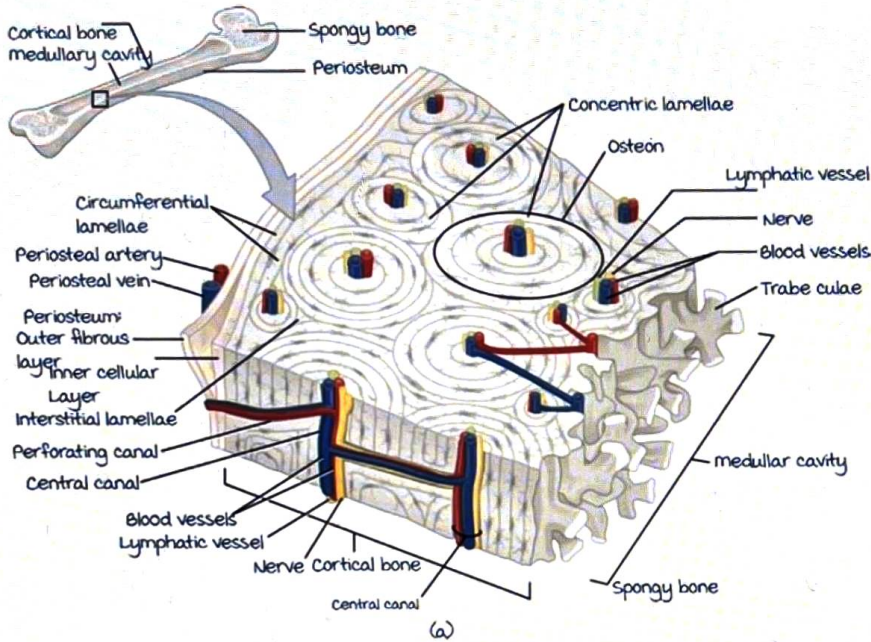
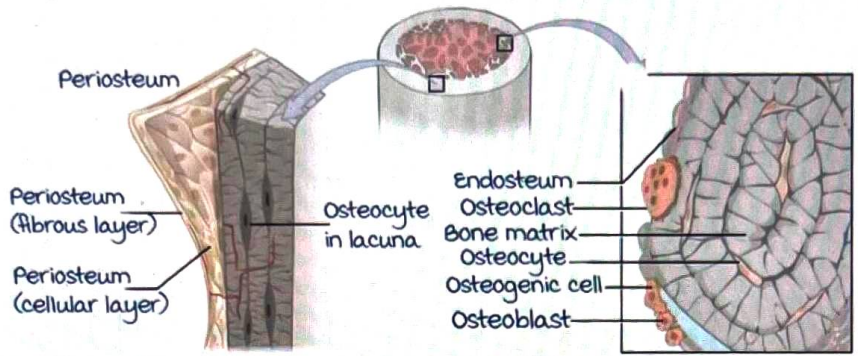
All long bones are surrounded by a layer called periosteum.

- 2 layers :
Inner cellular layer (cambium layer) & outer fibrous layer.
- Cambium : Baby osteoblasts (osteoprogenitor cells).
- Fibrous sheath :
Nutrition and growth.
- Absent on **sesamoid bones**. (Eg : Patella)
- Absent on articular surfaces.
- Children : Growth plate between epiphysis & metaphysis.
- Periosteum : Anchored to bone by Sharpey's fibres.
- medullary cavity : Lies within the bone. Contains the **marrow**, lined by endosteum.



Active space

60c6b3eeaa8ded0e4e7e5ea7



Nutrition of bone

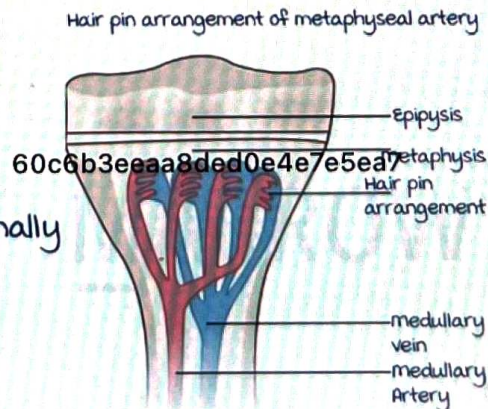
00:20:59

Nutrient foramen :

Nutrient artery enters the medullary cavity via this foramen.

Once it enters, it goes proximally and distally.

vessels are arranged in a **hair pin loop** fashion in the metaphysis.



Active space

Blood flow is sluggish making that area a very vascular environment.

Less defence cells in metaphysis → Increased risk of infection.

metaphysis has a very good healing potential.

Types of bone

00:21:48

Immature bone/Woven bone → Improperly arranged collagen and is weak.

Example : Callus.

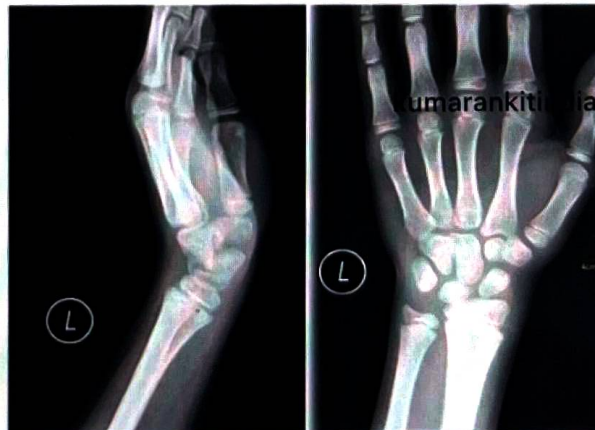mature bone/Lamellar bone :

- Spongy → Cancellous.
Found predominantly in the epiphysis and metaphysis.
- Compact → Cortical, densely packed.
Found predominantly found in the diaphysis.

Clinical significance :

- Spongy bone : more surface area, more bone cells → more vascularity → Better healing & more risk of infection.
- metaphyseal fracture → High vascularity → Heals well → Will go into malunion.
- Epiphysis fracture → Intraarticular fracture, osteoarthritis → ROM (range of movement) decreased.
- Diaphyseal fracture → Vascularity is lesser → Healing is reduced → more risk of non-union.

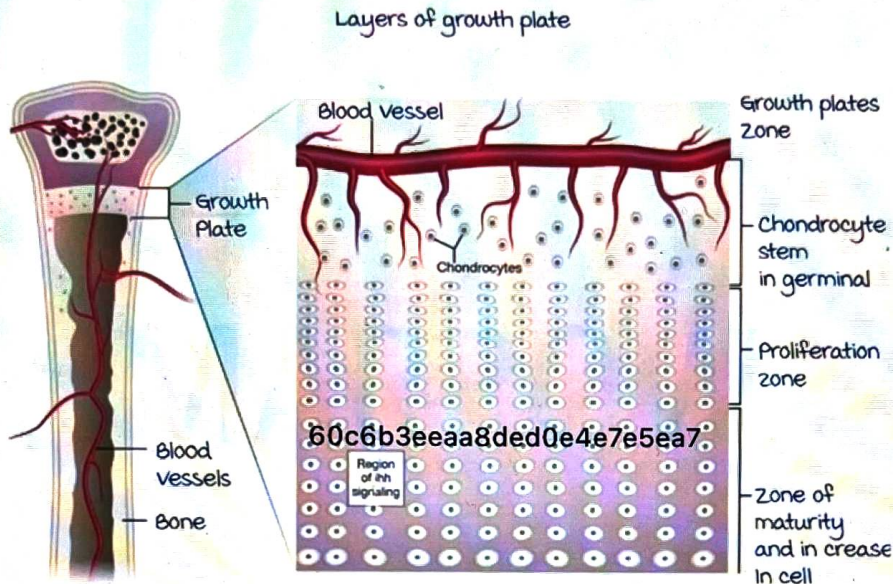
X-ray.



Bones are white → Radio dense/Radiopaque.

Soft tissue → Radiolucent.

Immature bone → Growth plate is visible. The physal plate is black, as the cartilage lacks mineral, hence radiolucent.



Interstitial Growth/Growth in length :

Physal plate helps bone grow in length.

Direction of the growth is from epiphysis to metaphysis.

Layers :

- **Germinal layer** : most important.
Cells take rest.
- **Proliferative layer** : Cells multiply.
- **Hypertrophic layer** : Cells start to grow in size to accommodate calcium (**weakest** layer).
- **Calcification layer**.
- **Ossification layer**.

Growth in **thickness**/ Appositional growth :

Osteo progenitor osteoblast cells present under the endosteum and periosteum grow contributing to the thickness of the bone.

BASICS FRACTURE & HEALING

Fracture (#)

00:00:10

60c6b3eaaa8ded0e4e7e5ea7

Breach or a break in the continuity of cortex of bone.

Diagnosis :

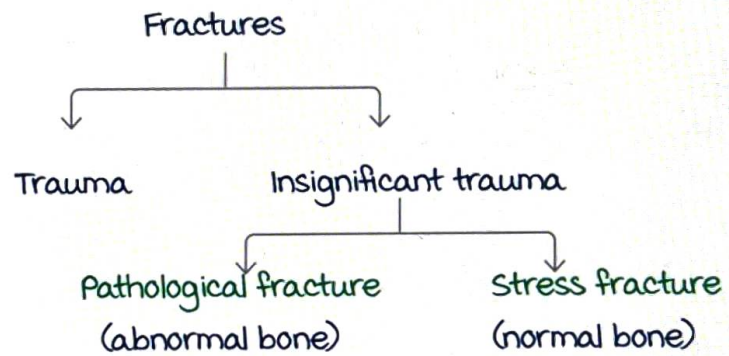
Clinically :

Pathognomic sign : Abnormal mobility > Crepitus.

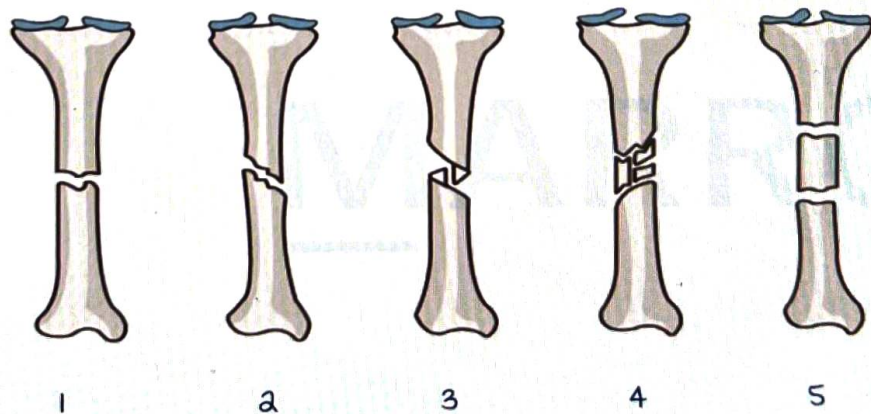
most consistent sign : Tenderness.

Radiologically : X-ray.

Causes of fractures :

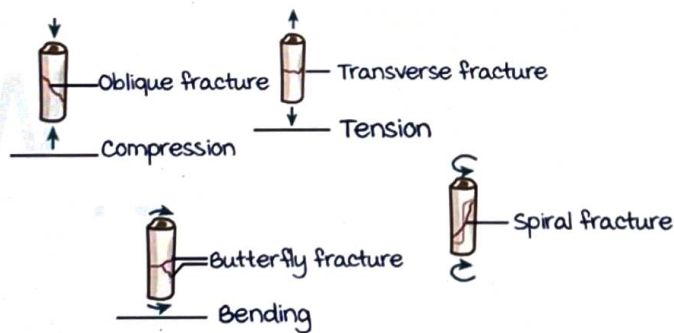
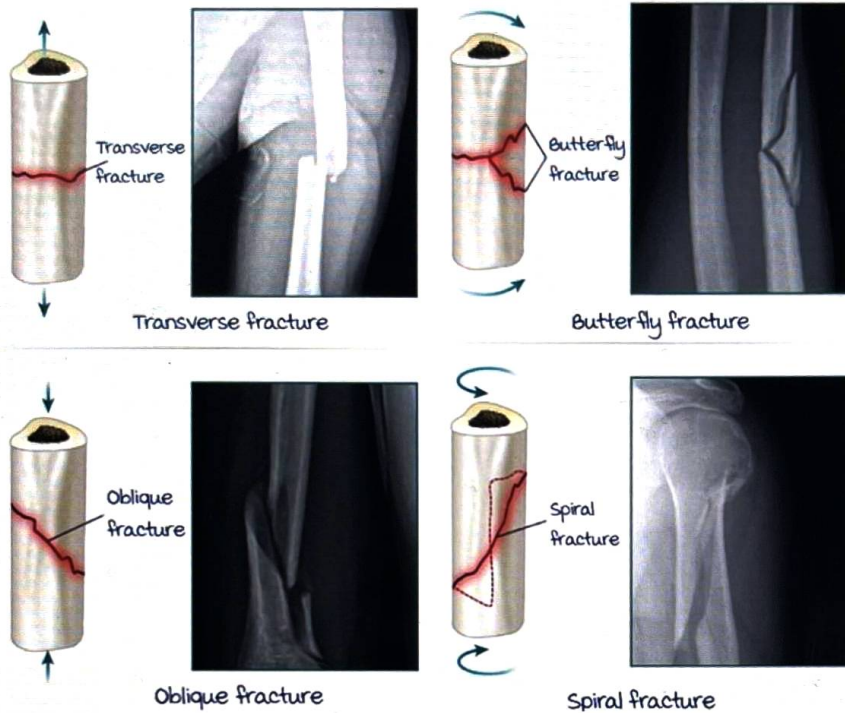


Traumatic fracture patterns :



1. Transverse fracture : Fracture line is transverse to the long axis of the bone. Direct force of action from opposite directions of the bone (tension).
2. Oblique fracture : Compressive force.

3. Spiral fracture : Twisting force to the bone.
Butterfly fragment : Bending force.
4. Comminuted fracture (direct trauma or crush injury) : multiple fragments.
5. Segmental fracture : Separating a fragment in middle.

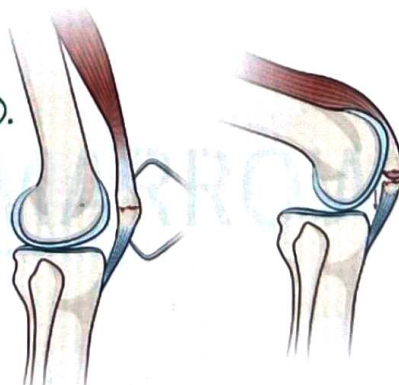


6. Avulsion fracture :

Pulled tendon cause avulsion of a part of bone.

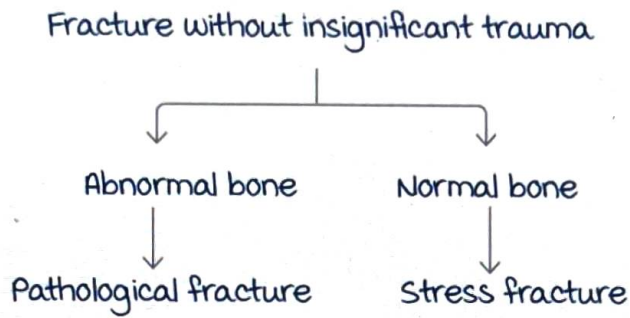
Breaking of a piece of bone, attached to strong muscle fragment.

Example : Olecranon (triceps)
& patella fracture (quaridceps).



Fractures with insignificant trauma

00:08:42



Pathological fracture :

Bone is rendered weak due to a disease process.

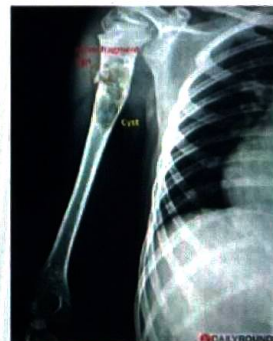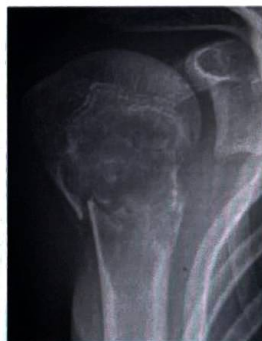Causes :

Localized	Generalized
Infection	Rickets
Ischemia	Osteomalacia
Lesions	Osteogenesis imperfecta
Cyst	Osteopetrosis
Radiation	Osteoporosis (most common) (fragility fracture)
	Pagets disease
	metastasis
	Scurvy

Clinical features : Pain before the fracture.

Investigations : X-ray (lesion in the bone).

kumarankitindia1@gmail.com



Active space

management : According to mirels criteria :

Mirel's criteria (Score > 8 suggests prophylactic fixation)			
Score	1	2	3
Site	Upper limb	Lower limb	Peritrochanteric
Pain	mild	moderate	Functional
Lesion	Blastic	mixed	Lytic
Size	< 1/3	1/3 to 2/3	> 2/3

If score > 8 : Prophylactic internal fixation.

most common location :

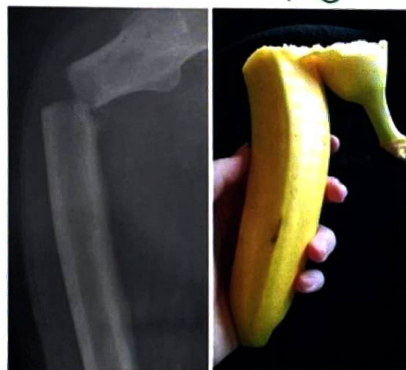Osteoporosis : Spine > Hip > Colles fracture.

metastasis : Proximal femur (neck of femur or subtrochanteric region) & spine.

Investigation for metastasis : **FDG PET-CT scan.**

Pathological fracture (banana fracture pattern) :

Subtrochanteric fracture, seen in paget's disease.



Treatment of pathological fracture :

- Internal fixation.
- Treat the underlying cause.

Stress fractures :

Pain after fracture.

Also known as **fatigue fracture.**

Fracture is due to abnormal/repetitive loading of a normal bone. Seen in dancers, athletes, military recruits etc.,

Commonly seen in the lower limb bones (point tenderness) > upper limb bones.

History of a sudden increase in intensity/frequency.

Investigations : X-ray are positive 2 to 3 weeks later.

Investigation of choice for stress : **MRI**.

- Picks up soft tissue edema.
- Also the IOC for occult fracture.

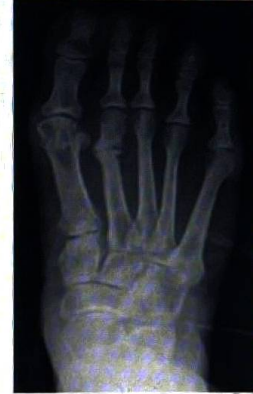most common bone affected in the body : **Tibia**.

most common bone affected in the foot : **metatarsal**.

(march fracture) : 2nd > 3rd metatarsal neck > shaft.



60c6b3eaa8ded0e4e7e5ea7



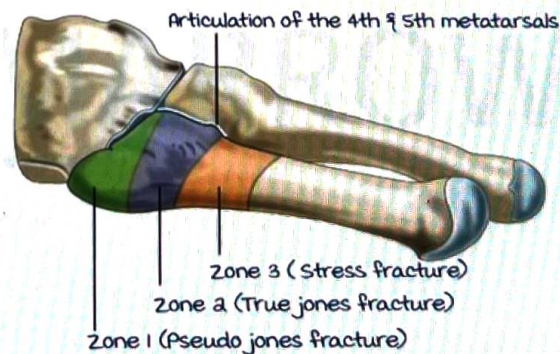
Investigation of choice for multiple stress fracture : **Bone scan**.

Jones fracture

00:20:06

Fracture at the metaphyseal diaphyseal junction of the 5th metatarsal at the level of the 4th to 5th intermetatarsal articulation.

Fractures of 5th metatarsal



Occur at **zone 2**.

Occurs at the **watershed area** of the bone in terms of vascularity.

Extremely high chance of non union.

Shin splints :

medial periostitis of the tibia (anteromedial aspect).

Usually seen in marathon runners or trekkers.

medial Tibial Stress Syndrome (MTSS).

clinical features : Pain on the anteromedial aspect of the leg.

X ray : Normal.

Differential diagnosis :

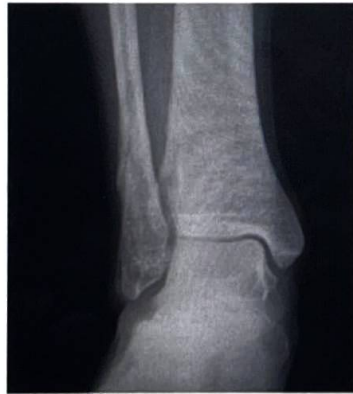Popliteal entrapment syndrome :

Pain in the posterior aspect of the leg without any fracture on x ray.

It is a congenital anomaly where popliteal artery passes through the gastrocnemius muscle which is usually hypertrophied in athletes, this causes compression of the popliteal artery causing ischemia distally.

Runner's fracture :

Occur at the lower end of the fibula.



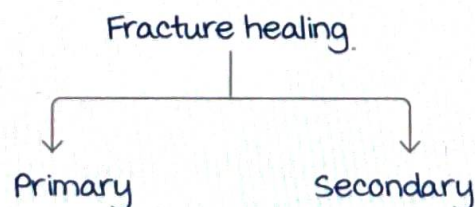
Treatment of stress fracture :

- Rest.
- Immobilisation.

Fracture healing

kumaran.kt.india@gmail.com

00:25:22



Active space

Primary	Secondary
Direct healing	Indirect healing
No callus seen	Callus is formed
Result of absolute stability	Result of relative stability
Rigid	Micro movement at the fracture site

Secondary fracture healing :

1. Hematoma formation :

Bleeding at fracture site, it has chemotactic factors that aggregate fibroblasts.

2. Granulation tissue formation (inflammation) :

Growth factors released by the tissue mature the fibroblasts into osteoblasts.

3. Callus formation :

Osteoblasts produce osteoid (callus) : Relatively less mineral.


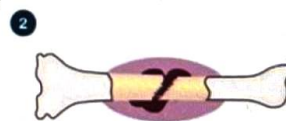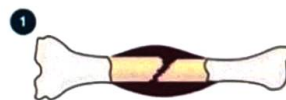
4. Consolidation :

makes soft callus into rigid one due to calcium deposition.

Irregular collagen : Woven bone.

5. Bone remodelling :

Regular collagen (lamellar bone) replaces the woven bone.



60c6b3eaa8ded0e4e7e5ea7

The fracture environment is acidic before calcium depositing & alkaline after calcium deposition.

First stage of fracture healing : Hematoma.

Last stage of fracture healing : Bone remodelling.

First stage of fracture healing visible radiologically : **Callus**.

Callus visibility needs atleast 3 weeks.

First stage of the clinical union : **Consolidation**.

Chronological order :

Hematoma : 2 to 3 days.

Granulation : 2 to 3 weeks.

Callus : 2 to 3 months.

Consolidation : 2 to 3 years.

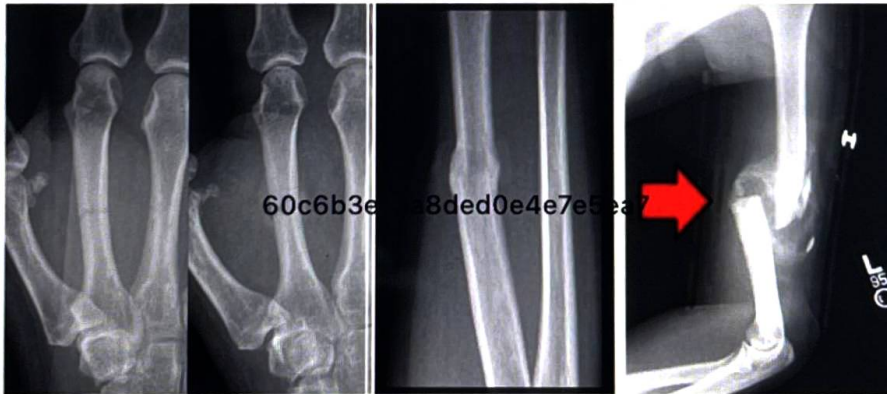Remodelling : > 3 years.

Implant removal :

There is no need to remove implants unless there is infection or tissue irritation.

Ideally removed after 2 years.

Callus :



Fractures affecting fracture healing :

1. Patient : Age, nutrition, tobacco, alcohol.
2. Type of fracture : Open, contamination, interposition.
3. Tissue : Ischemia.
4. Treatment : Inadequate reduction, **improper immobilization** (most common).

Non union

00:35:48

No callus > 6 months : Delayed union.

No callus > 9 months : Non union.

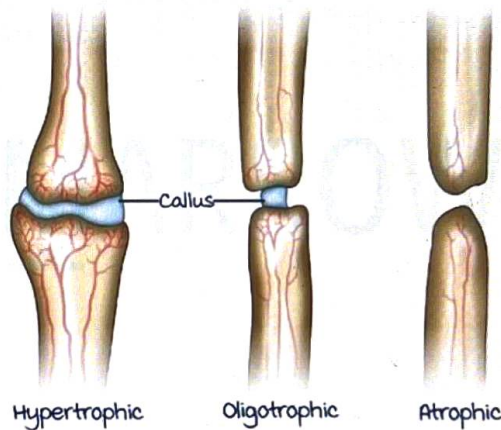
Diaphyseal bone usually undergo non union.

metaphyseal fractures undergo malunion.

Lower 1/3rd tibia fracture is the most common site for non union.

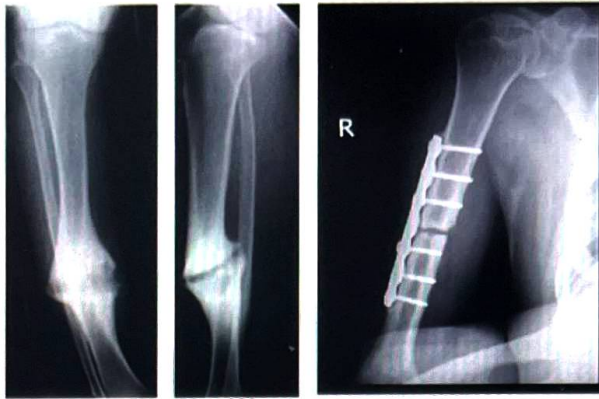
Types of non union :

Types of Non Union



Hypertrophic	Atrophic
Fracture line is still visible	Fracture line is still visible
Fracture ends are smooth & sclerotic	Fracture ends are smooth & sclerotic
Callous not bridging the fracture	No callous
Biology is good	Biology of the bone is abnormal
Immobilization/mechanics affected	Immobilization may be good
Treatment : Immobilization	Treatment : Autologous bone grafting. Treat the underlying cause.
	Typical non union

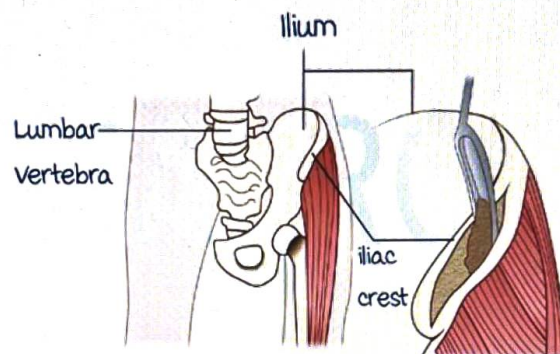
Active space



Bone graft :

60c6b3eaa8ded0e4e7e5ea7

most common source : **iliac crest** (cancellous bone).



Characteristics of ideal bone graft :

1. Osteogenesis : Graft itself forms bone with the help of osteoblasts.
2. Osteoconduction : when graft allows for the growth of bone on it as a scaffold on its surface.

Examples include :

Calcium phosphate.

Calcium sulfate.

Pmma.

3. Osteoinduction :


Something that stimulates the host to form bone.

These are recombinant growth factors.

Example :

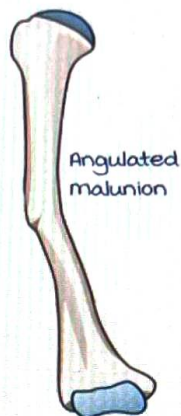Bone morphogenic proteins.

used to coat the implants used in fracture fixation.

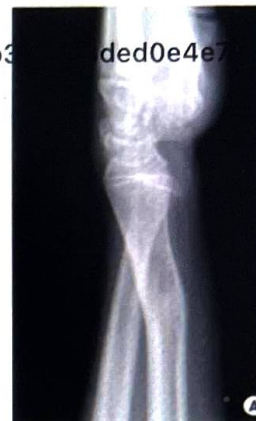

Malunion

00:44:52

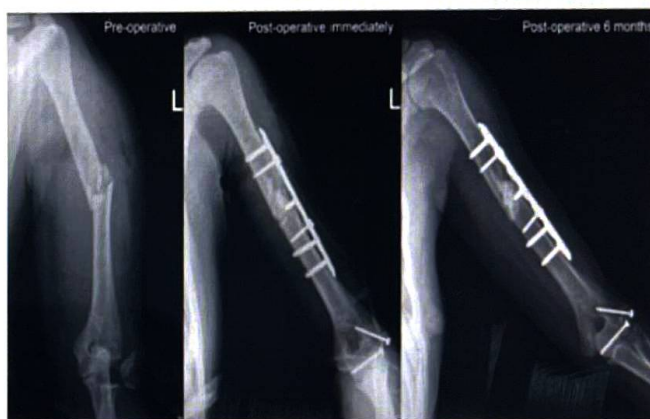

60c6b3... ded0e4e7... ea7



Healing in an anatomically abnormal position.

Treatment: **Osteotomy.**



Abnormal outcomes :

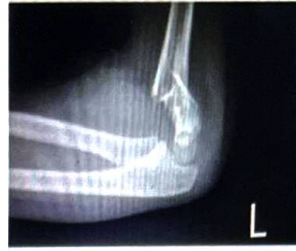malunion	Non union
Clavicle (most common).	Lower 1/3 rd of tibia (most common).
Supracondylar humerus.	Lateral condyle humerus.
Colles.	Scaphoid.
Inter trochanteric (extra capsular) femur.	Neck of femur .
	(intracapsular) femur.
	Neck of talus.

Active space

management of fracture :

1. Displacement :

Relationship of movement of the bone distal to the fracture site. They displace due to the pull of muscular force.



2. Reduction :

Bringing the fracture fragment back to the normal anatomy by application of force to counter the pull of muscle.

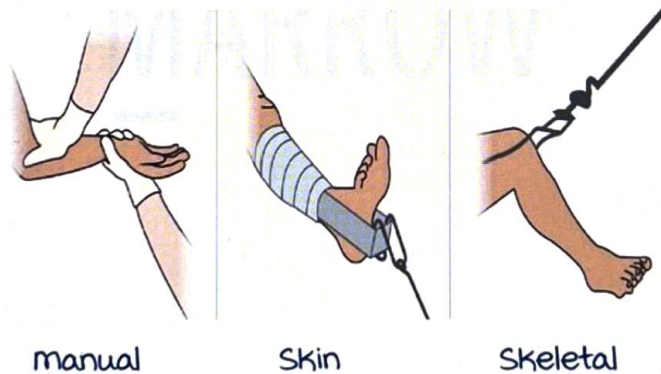
3. Traction :

Application of force to counter the muscular force causing the displacement (applied with counter traction).

4. Fixation :

To keep the fracture in reduced position till it heals.

Traction :



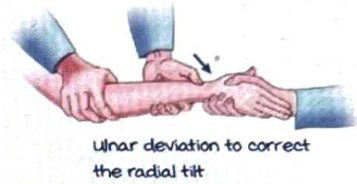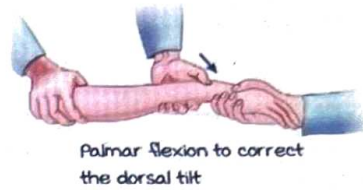
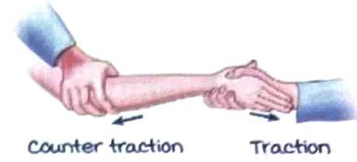
manual

Skin

Skeletal

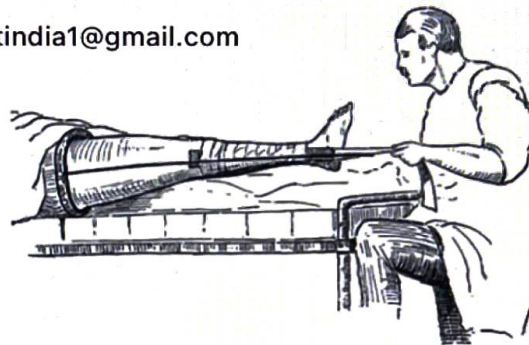
	Skin traction	Skeletal traction
Indication	mild to moderate force.	moderate to severe force.
Weight used	5 to 6 Kg.	15 to 16 Kg.
Applied with	Buck's traction.	Steinmann pin or Denham pins or K wire or Crutchfield's tong.

manual reduction & traction :



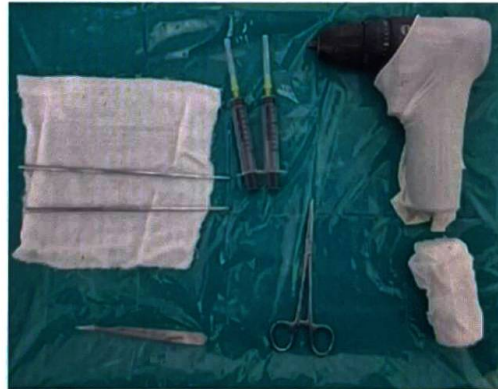Skin traction :

kumarankitindia1@gmail.com



Application of upper tibia pin traction

00:56:42



Drill, 2% lignocaine.
Artery forceps.
Blade No II.

Bohler stirrups.

Active space

Denham & steinmann pins :

Denham pins :


Smooth pin with serrations in center.
used in cancellous bone/osteoporotic bone.
Calcaneal traction.

Steinmann pins :

Smooth.

used in normal young **healthy adult bones.**

Tibial/femoral traction.



Steps :

- Preparation of the site.
- Localisation of location of insertion of skeletal traction pin.
- Local anesthetic is injected **2.5 cm below & behind the tubercle.**
- Using surgical blade No 11, stab incision is made.
- Dilating using artery forceps, to confirm that there is no presence of soft tissue along the way.
- Pin is inserted into drill and the bone is drilled from lateral to medial side.
- Removal of drill & application of dressing.
- Bohler stirrups mounted over the traction pin.
- Ring of the bohler stirrups is attached to skeletal traction rope attached with weights.

Splints to reduce pain

01:03:52

Purpose of splinting fracture :

To support fracture to minimise pain.

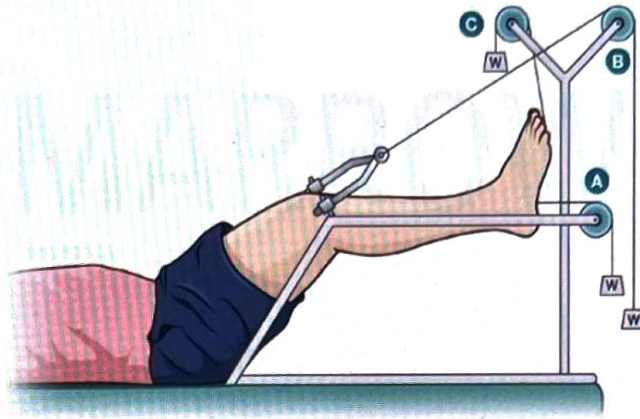
Father of British orthopaedics : **James Spence**

Father of Orthopedics : **Nikolas andrey.**

Father of modern Orthopedics : **Sir Robert Jones**

1. Bohler Braun splint :

A thin steel rod penetrates the shin bone to which the stirrup is attached.

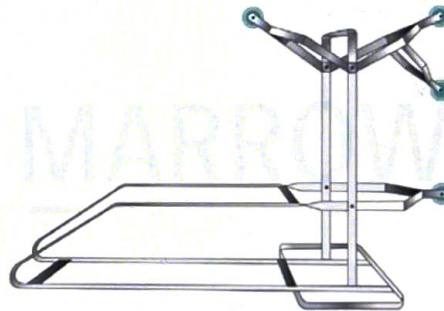


used in lower limb fracture.

60c6b3eeaa8ded0e4e7e5e27
The weight acting through pulley:

- Pulley B: Pulls up the lower fragments of the femur with body weight providing the counter traction.
- Pulley A: Holds the tibia in proper position.
- pulley C: To prevent foot drop.

Sliding traction device, ideal in ward situation.



a. Thomas splint:

Invented by Hugh Owen Thomas, considered as father of British orthopaedics.

Father of orthopaedics is Nicolas Andry

Father of modern orthopaedics Sir Robert Jones

Originally invented for TB knee.



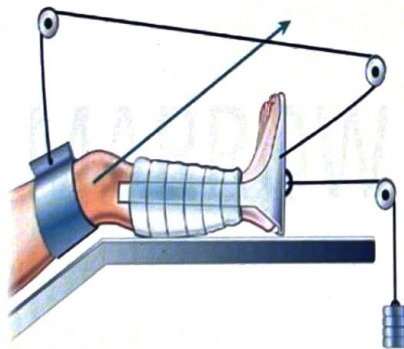
measuring for a Thomas splint :

Fixed traction device, two rods & one ring ,ideal in mobile situation.

1. measure the oblique circumference of the thigh immediately below the gluteal fold of buttock and ischial tuberosity. This may be too painful on the affected leg ,so measure the unaffected leg & add 5 to 6 cm to accomodate for swelling.
2. This measurement should correspond with the internal circumference of Thomas's splint ring.
3. measure the distance from the groin to the heel & add 15 to 25 cm to allow plantar flexion of the foot.
4. This distance should correspond to the medial (inner side bar of the splint).

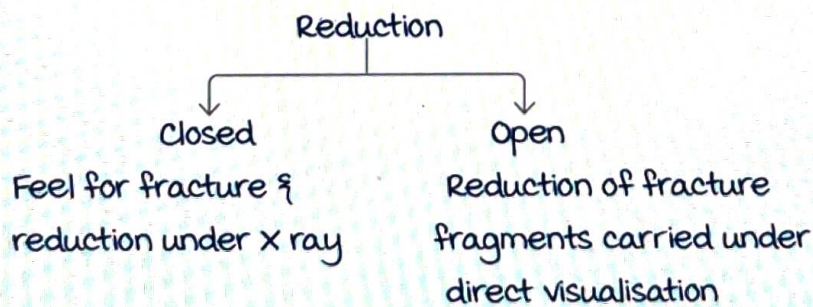
Russel traction :

conservative management of Inter trochanteric fracture of femur.

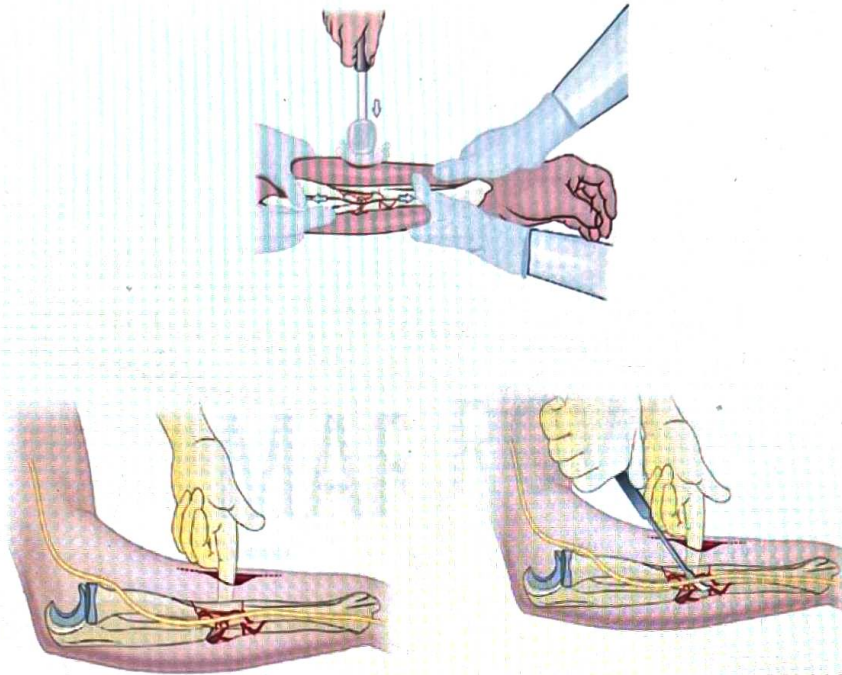


Definitive management of fracture

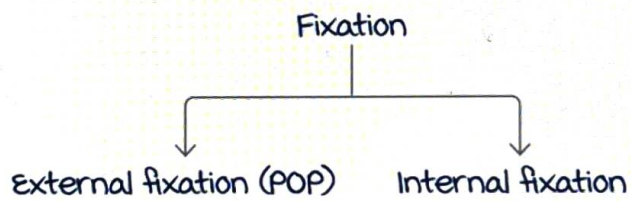
01:08:36



Closed reduction



Open reduction



Two types of fractures :

1. Intra articular fractures :

Open reduction + Internal fixation with plates.

2. Extra articular fractures :

Closed reduction + POP

Upper limb :

Open reduction + Internal fixation with plates.

Lower limb :

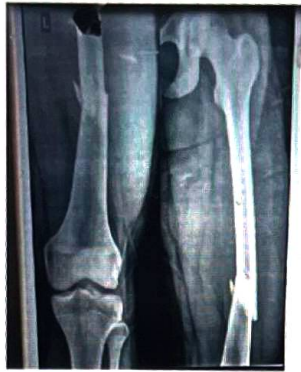Closed reduction + Internal fixation with rods/nails.

Active space

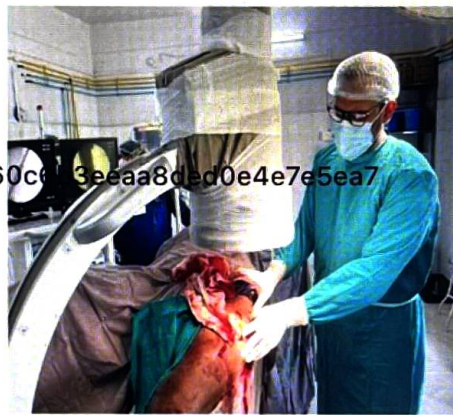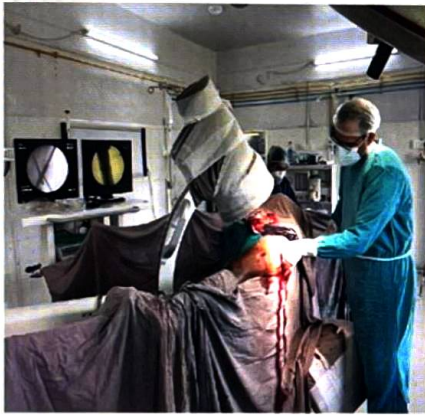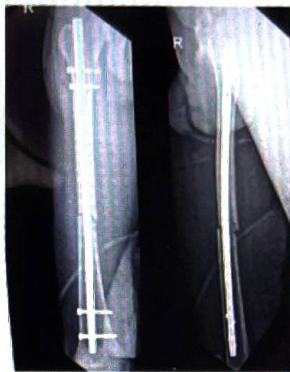60c6b3eaa8ded0e4e7e5ea7

Closed reduction with internal fixation using intramedullary interlocking nail :

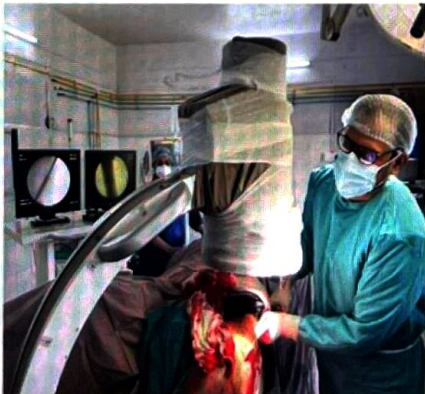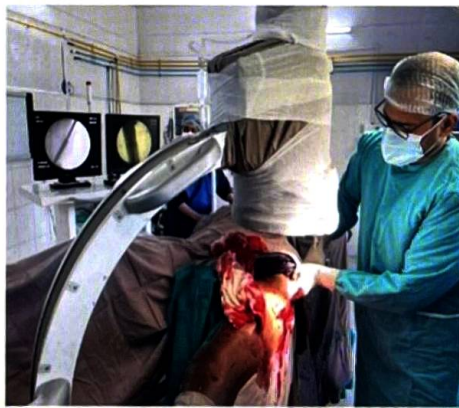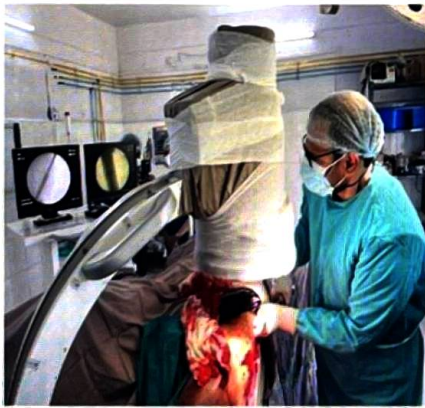Pre operative



Post operative



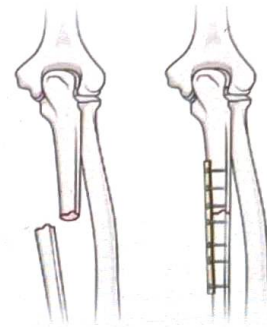
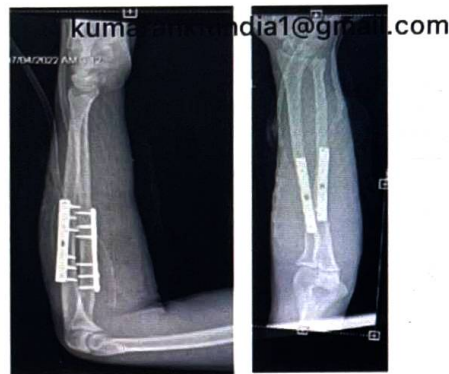60c63eaa8ded0e4e7e5ea7



Active space

shaft of radius/shaft of ulna fracture :

Extra articular fracture : Open reduction with internal fixation.

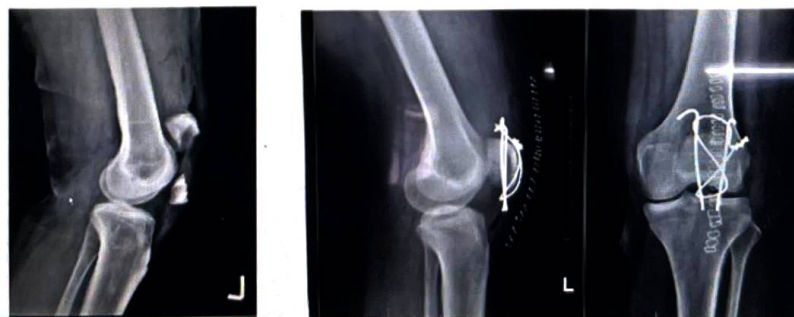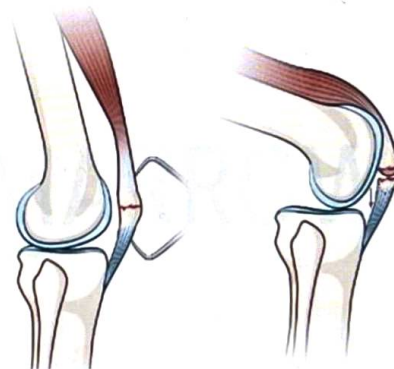


Patellar fracture :

Strong distractive forces converted into compressive force by **tension band wiring**.

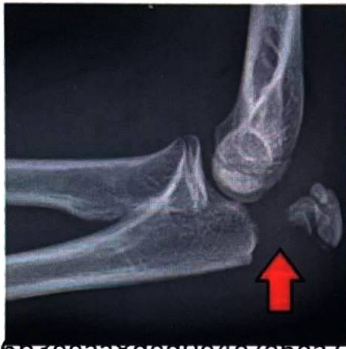Treatment :

Open reduction + internal fixation with tension band wiring.

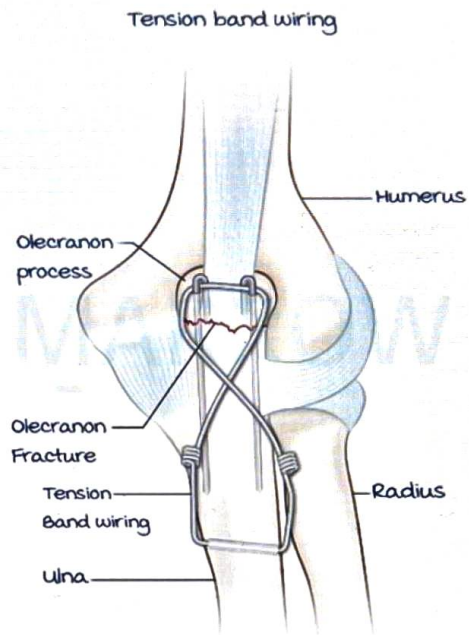


Olecranon fracture :

Open reduction + internal fixation with tension band wiring.



60c6b3eeaa8de00e4e7e5ea7



Active space

OPEN FRACTURES, AMPUTATIONS AND POLYTRAUMA

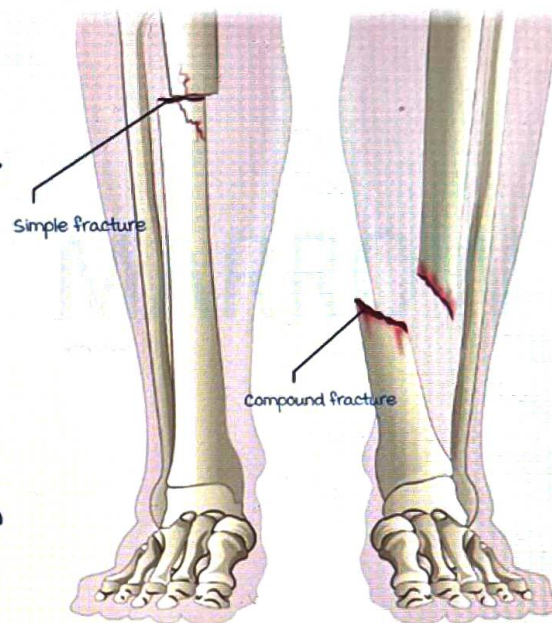
Open fracture

00:00:13

Open fracture is soft tissue injury associated with a break in the skin and underlying soft tissues. Environment communicates directly with the fracture and its hematoma.

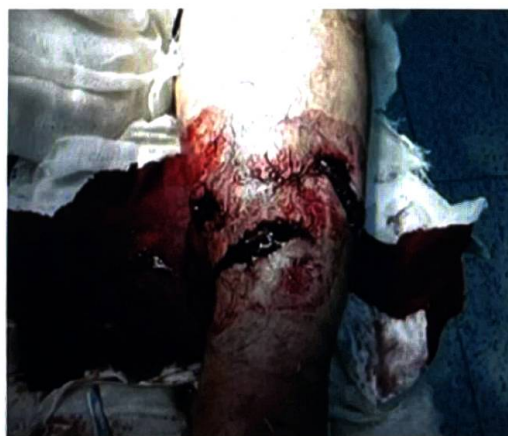Staph aureus is the most common organism that causes infection in the musculoskeletal system.

Simple and compound fracture



Infection of the bone and medullary cavity : Osteomyelitis.

Infection of the joint : Septic arthritis.



60c0b3eeaa5ded0e4e7e5ea7

Gustilo-Anderson classification of open fracture :

Type I : Wound < 1 cm long (considered as a closed fracture).

Type II : Wound 1-10 cm long but without significant soft tissues stripping, gross contamination, or high energy fracture patterns.

Type III A : Wound > 10 cm long or lesser skin lesions with gross contamination and or high energy fracture patterns. Bone coverage adequate.

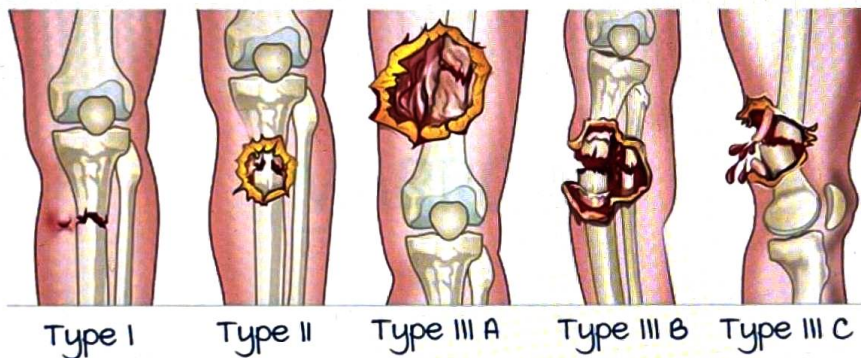
Fracture occurred in a contaminated area : Farm, firearm, sewage.

Type III B : Extensive soft tissue stripping that typically needs some type of soft tissue flap for coverage.

Periosteal stripping.

Type III C : Large wound with major arterial artery.

Associated with vascular injury.



management of open fracture : Emergency.

Wound :

Broad spectrum antibiotics.

Debridement.

Wash the wound with normal saline or :

Sterile normal saline.

Povidone iodine.

Hydrogen peroxide.

Wound closure :

Delayed for second look if :

If **more than 6 hours** (golden period of wound) : Delay primary closure.

Associated neurovascular injury.

Edges cannot be approximated.

When you are not satisfied with the debridement.

Fracture : Stabilisation with external fixation.

And its modifications.

management of open fracture : Emergency.

Grade 1 : manage like **closed fracture**.

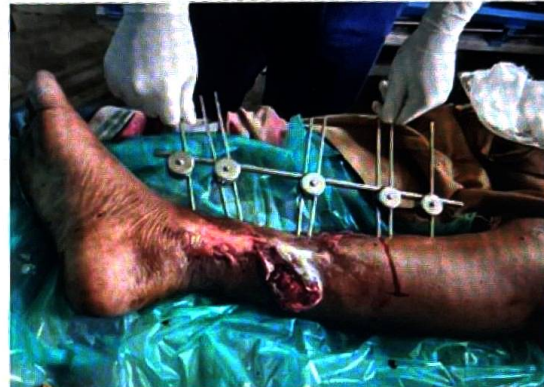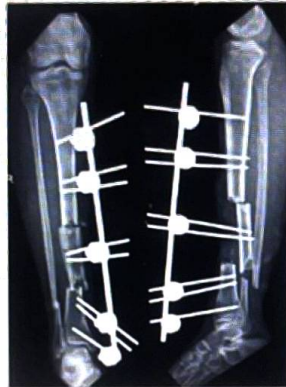Grade 2, 3a : If clean (<6hr) like closed, otherwise like open.

Grade 3b, 3c : **External fixation**.

External fixator : Schanz pins with external rods.

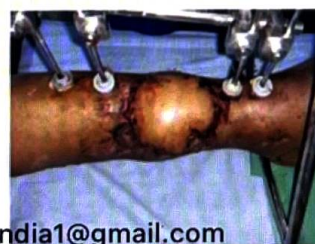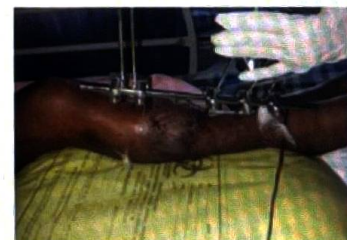main purpose is to **stabilise the fractures**.

varieties of external fixators : uniplanar, multiplanar, single rod, double rod.

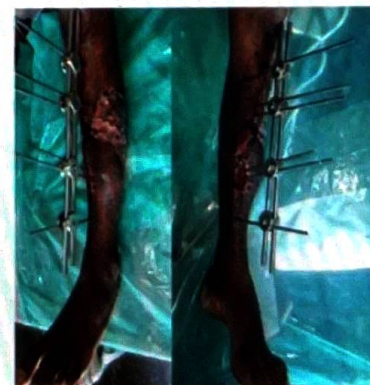
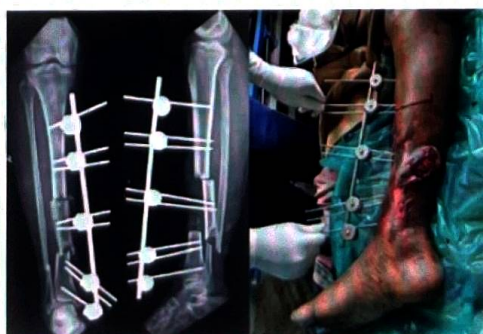

The most commonly used is the Ilizarov ring fixator.

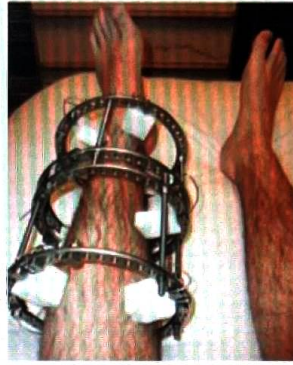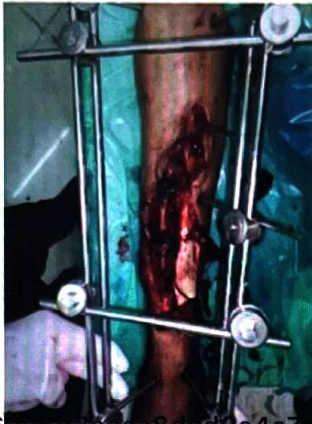External fixator set



kumarankitindia1@gmail.com



Active space



60c0b3eeaa8ued0e4e7e5ea7

Ilizarov ring fixator

00:09:48

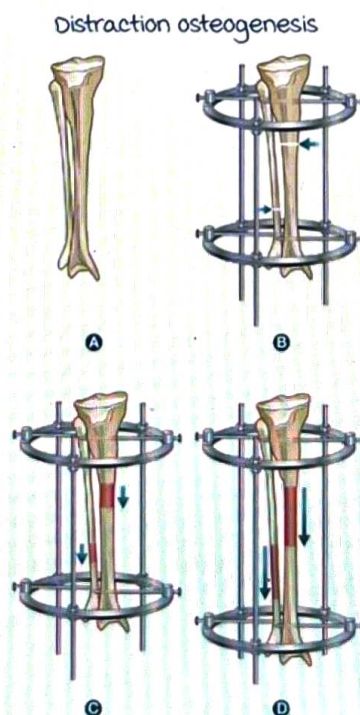
Instead of rods and pins, there are rings and pins.

Distraction osteogenesis/callotaxis :

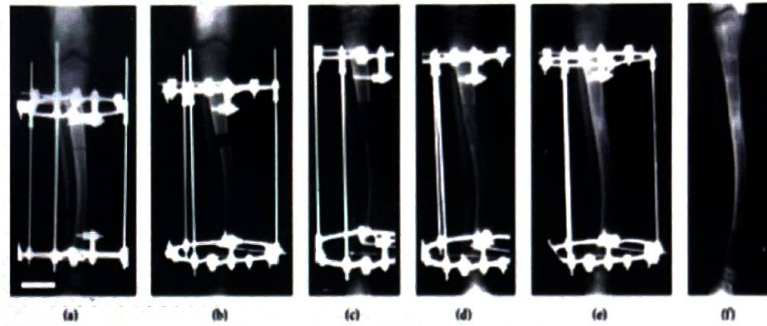
In the case of an open fracture, if a bone piece is missing it can be replaced by growing a new bone.

This is done by first cutting the bone (corticotomy) and placing the frame.

Once this is done, distraction is applied at the corticotomy site at the rate of 1mm/day (physiological limit). As a result there of which new bone formation takes place. This is called distraction osteogenesis.



Active space



Uses :

- Open fractures.
- Open infected fractures.
- Osteomyelitis.
- Deformity correction/malunion.
- Limb lengthening .
- Non-union.
- Fracture with bone loss.


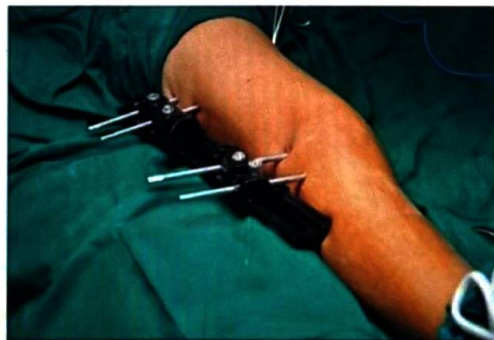
60c6b3eaa8ded0e4e7e5ea7

Rail fixator/Limb Reconstruction System (LRS) :

Adjustable rod

Combination of compression and external fixation.

External fixator on right tibia

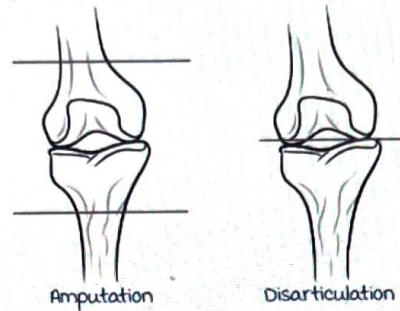


Complications of external fixator :

Due to the heat generated by the drilling or direct infection, there is necrosis around the pin inserting size as a result of which the bone in that area dies.

This is known as **ring sequestrum (m/c)**.

Active space



To increase the stability of external fixators :

Increase the number of in **uniplanar pins < rods < planes.**
multiplanar : Ring and pins (most stable).

In cases where the bone is damaged and contaminated :

Amputation : It is cutting of the limb through the bone.

Disarticulation : Cutting of the limb at the joint.

Decision of amputation is based on the following scoring systems :

MESS (Mangled Extremity Severity Score).

Velocity of injury or soft tissue coverage.

Ischemia time (most important parameter).

Score doubles if time more than 6 hrs.

Shock of blood pressure.

Age of the patient.

If the score is >7 , amputation is carried out.

Limb salvage Index.

Ganga score.

Amputations

00:18:35

Crush injury due to road traffic accident is the most common cause in India.

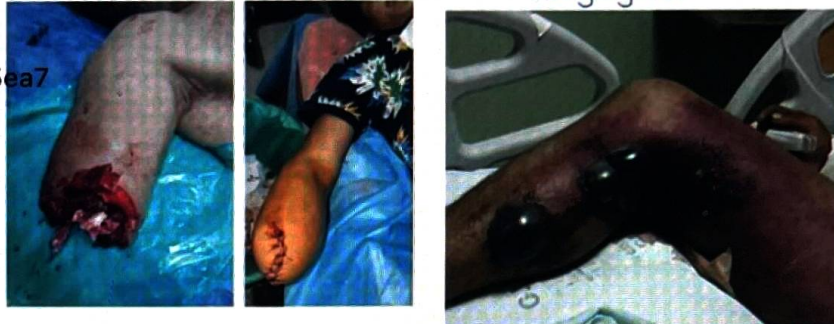Peripheral vascular diseases like diabetes mellitus most common in the world.

Frost bite, gas gangrene, malignant tumour.

Congenital deficiency of limb/abnormal limb/neuromuscular disease like polio that has rendered the limb functionless.

Dead (crush/peripheral vascular disease).
 Dangerous (gas gangrene/malignant tumor).
 Dumb limb is attached to the body but has no purpose
 instead, causes harm.

60c6b3eaa8ded0e4e7e5ea7



most common indication is **gas gangrene**.

Types of amputation :

Closed : When the skin is closed in the primary surgery.

Open or Guillotine : Where the skin is kept open and closed
 in the second stage.

Infected/contaminated stumps.

Amputations for ischemic indications.

Principles for amputation :

Torniquet application :

Torniquet is a tight constriction band that will decrease the
 blood flow distally, helps to minimise the blood flow in the
 surgery and achieve a blood less field.

Should be avoided in cases of ischemia or peripheral vascular
 disease.

methods of closure :

myodesis :

muscle is sutured with the bone.

Preferred over myoplasty.

It is contraindicated in PVD amputations.

In ischemic disease the vascularity of the muscles are
 already compromised therefore, attaching it to another
 avascular structure, the bone is not beneficial.

myoplasty :

muscle is sutured to muscles.

When the indication of amputation is ischemia.

Cutting the bone :

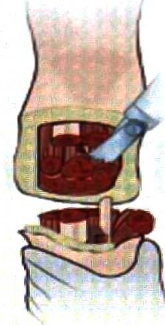
Bone is cut 5cm shorter than the soft tissue to be able to close the wound.

Closure of the flap :

Symmetrical method : Suture line is on the mid coronal plane.

Advantage : Easy.

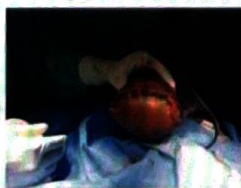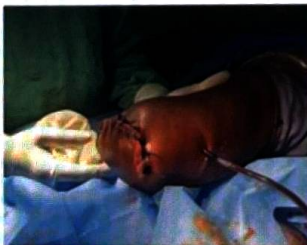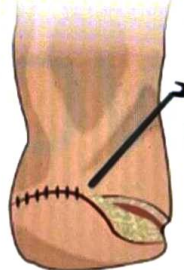
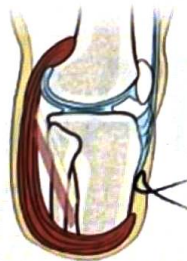
Disadvantage : When the prosthesis is applied, it will be on the suture causing pain and wound dehiscence.



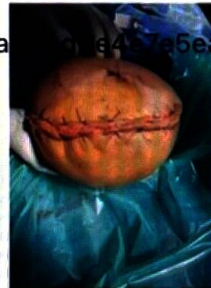Skewed method : The posterior flap is longer than the anterior flap.

It is approximated anterior to the mid coronal plane.

Advantage : Decreased the problems of application of limb prosthesis and wound dehiscence.



Skewed flap



Symmetrical flap

Active space

Terminology of amputation

00:27:48

Upper limb :

Fore quarter : Through shoulder girdle.

Shoulder disarticulation : At the glenohumeral joint.

mid arm amputation : Transhumeral.

Elbow disarticulation.

Forearm :

kumarankitindia1@gmail.com

mid forearm.

Krukenberg functional : The radius and ulnar can be used as a pincer.

Wrist disarticulation.

Ray amputation : Removing the full digit and axis.



Krukenberg

Lower limb :

Hind quarter : Through hemi pelvis.

Hip disarticulation.

mid-thigh : Transfemoral.

Knee disarticulation.

Below knee amputation (contraindicated in DM).

most common : **Transtibial amputation.**

Symes : Ankle.

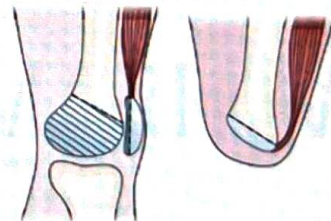
Chopart : Intertarsal joint.

Lisfranc : Tarso metatarsal joint.

Gritti Stokes amputation :

Done at distal femur.

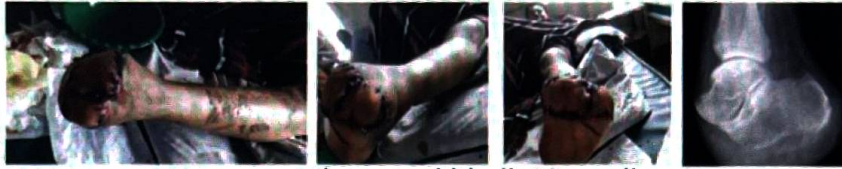Closed with patella and its soft tissue.



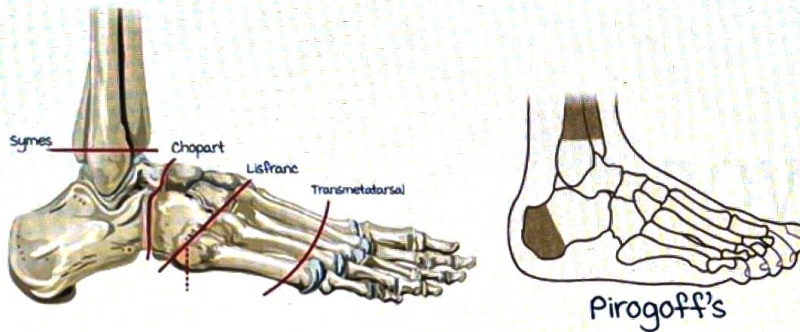
Amputations of the foot :

midfoot :

Chopart : At the intertarsal joint between the talonavicular and the calcaneocuboid.



kumarankitindia1@gmail.com



Lisfranc : Between the tarsal and metatarsal bones.

Symes : 0.6 cm above the dome of talus (wide base).

Sarmientos : 1.3 cm proximal to the ankle with both malleoli. (narrow base).

Boyd : After talectomy fuse calcaneum to tibia.

Pirogoff : After talectomy calcaneus is cut and rotated then fused to tibia.

Length of amputations stump/energy expenditure relationship :

Length of the stump should be kept as long as possible.

It is better for prosthetic fitting.

It reduces energy expenditure.

Hip disarticulation require **100% more energy** to perform same.

Knee disarticulation require **50% more energy** to perform same action.

Complications of amputation :

Infection.

Bleeding.

Flap necrosis : Too tight suturing.

Amputation neuroma :

On amputation, the proximal end gives out axonal sprouts which are naked and is

sensitive to any kind of stimuli.

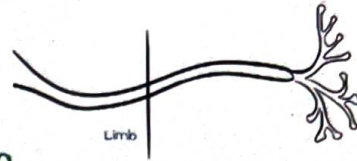
This is known as a neuroma.

This can be prevented by pulling

the nerve and then cutting it using a fresh sharp blade. On

doing so, even if neuroma formation takes occurs, it lies deep

within the tissues.



Treatment : Best is **excision**.

60c6b3eeaa8ded0e4e7e5ea7

Transcutaneous Electrical Nerve Stimulation (TENS) and inferential therapy.

Phantom limb sensation : Patient feels still attached to the body (seen in 50-80%) and sensation disappears in a distal to proximal fashion (telescopic relief).

Prosthesis

00:36:51

It is the artificial limb.

Parts :

Socket.

Connecting rod.

Terminal device/foot device :




Sach-rigid keel : Solid ankle, cushioned heel.

Jaipur foot : Flexible keel.

made by Dr. P K sethi.

SAFE : Stationary Attachment Flexible Endoskeleton, similar to Jaipur foot.

Keel is the connection between prosthesis and the terminal device.



Prosthesis	SACH	Jaipur foot
Appearance	Does not look normal	Looks normal
Walking barefoot	Not possible	Possible
mobility	Restricted	Allowed
Dorsiflexion	Absent	Present
Inversion/ Eversion	Absent	Present
Squatting	Not possible	Possible
Cost	High	Low

Amputation in children :

Save as much as possible.

Disarticulation is preferred over amputation as it does not disturb growth of bone by protecting the growth plate.

multiple revisions of stump is required.

Children adapt well to prosthesis.

Reimplantation of limb :

Only in clean wound with low MESS score.

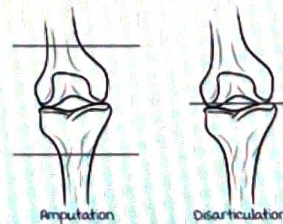
Transportation of the appendage.

Clean in sterile NS/RL.

Wrap in sterile gauze piece soaked in NS or RL.

Keep in a plastic bag, seal it.

Then keep it in the ice box (this increased the ischemia time to 12-24 hours).



Then keep in the box

Order of reconstruction :

1. Bone : The first structured to be reimplemented followed by the rest.
2. Extensor tendons.
3. Flexor tendons.
4. Artery.
5. Nerve.
6. Vein.
7. Skin.

Polytrauma :

A patient who has 2 organ systems involved in the injuries.

Head injury.

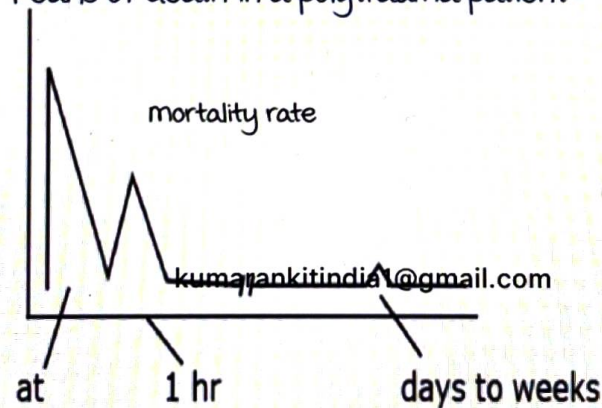
Chest injury.

Abdominal injury.

Fracture.

CAB (chest compression, airway, breathing) protocol is for BLS and ACLS, whereas ABC is for ATLS (trauma).

Peaks of death in a polytrauma patient :



X-axis : Time.

Y axis : mortality rate.

Spot death : massive head or vascular injury.

Prevented by creating more awareness.

Can be prevented, occurs in the first hour of trauma (golden hour).

Causes included haemothorax, pneumothorax, cardiac tamponade.

Can be prevented by ATLS.

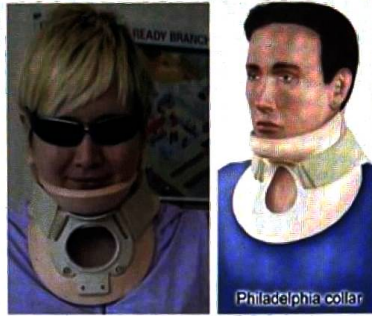Occurs days to weeks later.

Cause : sepsis.

ATLS

00:46:11

Simultaneous diagnostic and therapeutic activities intended to identify and treat limb and life threatening injuries beginning with the most immediate.



It is for non-cardiac arrest patient, he is a trauma patient.
To prevent death in the golden hour of trauma.

Haemothorax

Pneumothorax

Cardiac tamponade.

Order of evaluation :

~~Primary and secondary survey~~ **Primary and secondary survey** of cervical spine motion.

Cervical spine can be stabilised by a Philadelphia collar.

Breathing : Ensure there is expansion of the chest.

Circulation : Stop the bleeding (internal or external).

Pelvis and femur fracture are the most common cause of bleeding in polytrauma patients.

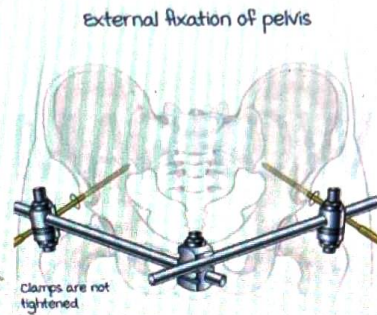
Pelvic fracture management :

Pelvis is a flat bone (cancellous), it has many vessels. In the event of a fracture, the plexus around the pelvis ruptures and cause bleeding along with the cancellous bone.

Pelvic binders : To tamponade the blood loss (1.5-2 L of blood is less, i.e., 4-8 units).

IVF : RL > NS, theoretically can control acidosis with release of pyruvated and bicarbonate from lactate.

External fixation to the pelvis in compression mode.



Disability evaluation :

Glasgow Coma score	
Eye opening	
Spontaneous	4
Open to verbal command	3
Open to pain	2
No eye opening	1
Verbal response	
Oriented	5
Confused	4
Inappropriate words	3
Incomprehensible sounds.	2
No verbal response	1
motor response	
Follows command	6
Localises to pain	5
Withdrawals from pain.	4
Flexes to pain.	3
Extends to pain.	2
No movement.	1
Total score:	3-15

Exposure (undress) and environment (temperature control).

Transportation of the patient to the hospital from the polytrauma site :

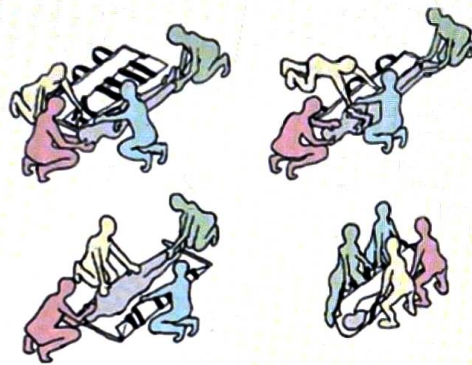
Place the patient on a stretcher with log rolling technique to prevent an incomplete injury from progressing to a complete injury.

Log roll technique : Turning the patient without twisting the spine and slide the stretcher, placing him in the supine position.

Other fractures are not of immediate concerns except for fractures that can cause further contamination or bleeding. (femur fracture : 1-1.5 L of blood is lost).

In such cases, femur fractures are stabilised temporarily.

Log Roll technique



Damage control orthopaedics (DCO) :

It is that modality of management where you think if the patient first rather than the fracture.

Limited surgical intervention in a patient who is grossly injured, to control haemorrhage and contamination.

Early temporary fixation is done by external fixation.

Patient is shifted to ICU for optimisation.

Definitive treatment.

Example : Fat embolism syndrome, chest injury, coagulopathy, hypothermia, severe acidosis.

kumarankitindia1@gmail.com

Crush syndrome

00:51:14

Limb is compressed for a prolonged period.

Hypoperfusion and myonecrosis of the crushed limb.

When the limb is released from the compression, toxic metabolites get released to cause reperfusion injury.

Result in a systemic reaction due to tissue necrosis.

Free myoglobin can lead to acute tubular necrosis.
myonecrosis lead to metabolic acidosis with
hyperkalaemia and hypocalcaemia.

management of crush syndrome : Encouraging high urine
flow, along with alkalisiation of urine with sodium bicarbonate
to prevent precipitation of haemoglobin in the renal tubules.

Questions :

For a case of non-union of a long bone fracture, which drug
helps improve the chances of union ?

- Calcium phosphate
- Calcium sulphate
- PMMA
- Bone morphogenic proteins.

Bone morphogenic proteins are osteoinductive in nature.
Whereas calcium phosphate, calcium sulphate and PMMA are
all osteoconductive, they act as a scaffold over which the
bone will grow.

Which of the following is a major mineral of the bone matrix ?

- Calcium chloride.
- Calcium hydroxyapatite.
- Calcium pyrophosphate.
- Calcium carbonate.

Which of the following is a diagnostic sign of the fracture ?

- Abnormal mobility at fracture site.
- Pain at the fracture site.
- Tenderness.
- Swelling.

All are true for pathological fractures except

- Osteoporosis and secondary deposits are commonest
cause.
- Mirel's criteria predicts risk.
- Internal fixation is the treatment of choice.
- Anaemia is a common cause.

All are true about fracture healing except

- a. Nutrition affects healing.
- b. Stable fixation promotes healing.
- c. Compression at fracture sites causes non-union.
- d. Hormonal status may affect healing.

The correct order of priorities in the initial management of a patient with head injury is ?

- a. Airway, breathing, circulation treatment of extracranial injuries.
- b. Treatment of extracranial injuries, Airway, breathing, circulation.
- c. Circulation, Airway, breathing, treatment of extracranial injuries.
- d. Airway, circulation, breathing, treatment of extracranial injuries.

In an unconscious severely injured patient of multiple fractures and an open bleeding wound on the right thigh, the first thing to be done is ?

- a. Secure airway.
- b. Blood transfusion and treat shock.
- c. Tourniquet and splinting.
- d. GCS scoring.

A vascular repair is warranted in which type of Gustilo Anderson injury ?

- a. III C
- b. I
- c. II
- d. III B

Tarsometatarsal amputation is also known as ?

- a. Choparts amputation.
- b. Lisfranc's amputation.
- c. Pirogoff's amputation.
- d. Syme's amputation.

myodesis is employed for amputations for all of the following indications except?

- Trauma.
- Tumor.
- Children.
- Ischemia.

Pain due to post amputation neuroma is best treated by,

- Infrared therapy
- Interference therapy
- ultrasound therapy
- Surgical excision.

All of the following statement about SACH foot are except?

- 'SACH' stands for "solid ankle cushioned heel"
- Forms the base of a lower limb prosthesis
- may wear out with time.
- Wooden keel absorbs the impact of heel strike.

Following an RTA, a patient develops Type IIIa compound tibial fracture arrange the following external fixation devices in terms of stability (lowest to highest)

- Ilizarov
 - uniplanar with single rod
 - uniplanar with double rod
 - Biplanar.
- 60c6b3eeaa8ded0e4e7e5ea7
- 1,2,3,4.
 - 4,3,1,2.
 - 2,1,4,3.
 - 2,3,4,1.

Following a femur shaft fracture, your consultant asks you to provide Tibial skeletal traction. which of the following will you request from the nurse to do the same?

- Thomas splint.
- K-wire.
- Steinman's pin.
- Denham's pin.

5. Bohler's stirrup.
 6. Bohler brown splint / frame.
- a. 3,4,1.
 - b. 3,5,6.
 - c. 2,1,6.
 - d. 4,6,1.

60c6b3eaaa8ded0e4e7e5ea7

Upper tibial pin traction :

1. Steinman's pin or Denham's pin.
2. Drill.
3. Artery forceps.
4. Blade no:11
5. Local anesthetic.
6. Bohler's stirrup.

The pin is placed 2.5 cm behind and below the tibial tuberosity.

Enter from the lateral side and go towards the medial side.

Which of the following is true about an open fracture ?

1. Tibia and phalanges are most involved.
2. Usually, no co-existing injuries.
3. Compartment syndrome does not occur in open fractures.
4. Early debridement should be done.

1 and 4.

1 and 2.

2 and 4.

2 and 3.

Compartment syndrome : $> 30\text{mmHg}$.

Pitfalls :

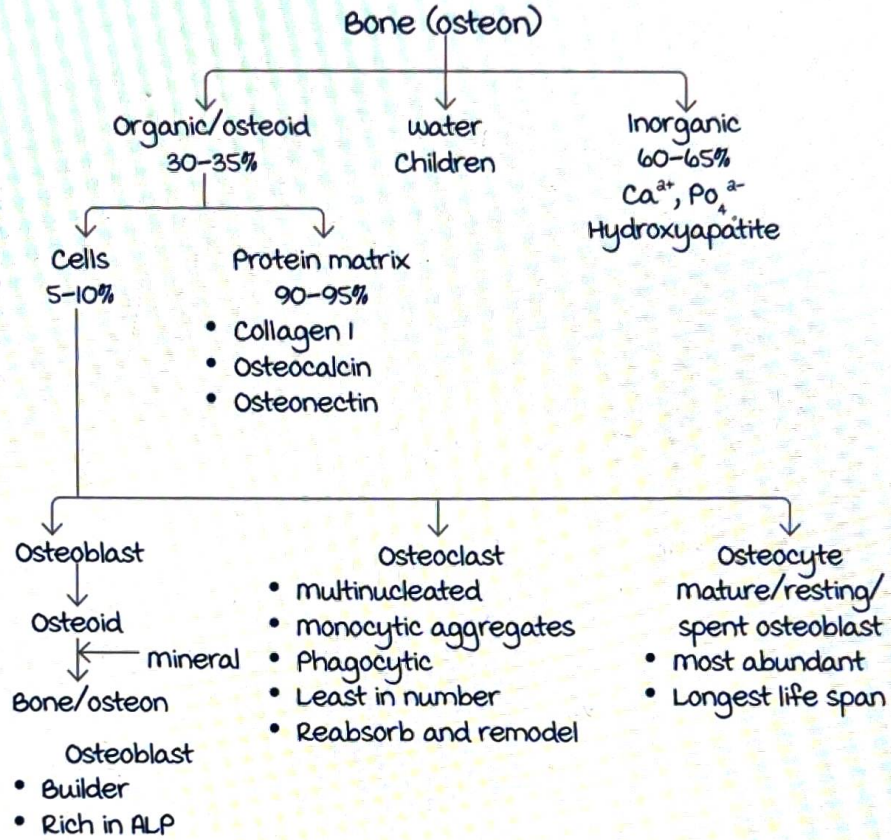
1. The incidence of compartment syndrome associated with high and low energy injuries is nearly equal.
2. Compartment syndrome can occur in open fractures.
3. Have a high index of suspicion and be particularly vigilant in patients with an altered level of consciousness.

Normal pressure : $< 10\text{mmHg}$.

METABOLIC BONE DISEASES : PART 1

Constituents of the bone

00:01:33



Physiology of the bone

00:03:09

Calcium homeostasis is regulated by :

- PTH.
- Calcitonin.
- Vitamin D.

60c6b3eaa8ded0e4e7e5ea7

Trigger	Agent	Effect
Hypercalcemia	Increase calcitonin	Decrease Ca ²⁺ and phosphate
Hypocalcemia	Increase PTH	Restores serum Ca ²⁺ back to the normal
Hypocalcemia/ Hypophosphatemia/ Hyper PTH	Increase Vitamin D	Restore Ca ²⁺ and phosphate back to the normal

Active space

Secondary hyperparathyroidism :

Hypocalcemia is the trigger for PTH secretion (hyperparathyroidism).

PTH restores the serum Ca^{2+} back to normal.

This results in inhibition of the secretion of PTH due to the **negative feedback** mechanism.

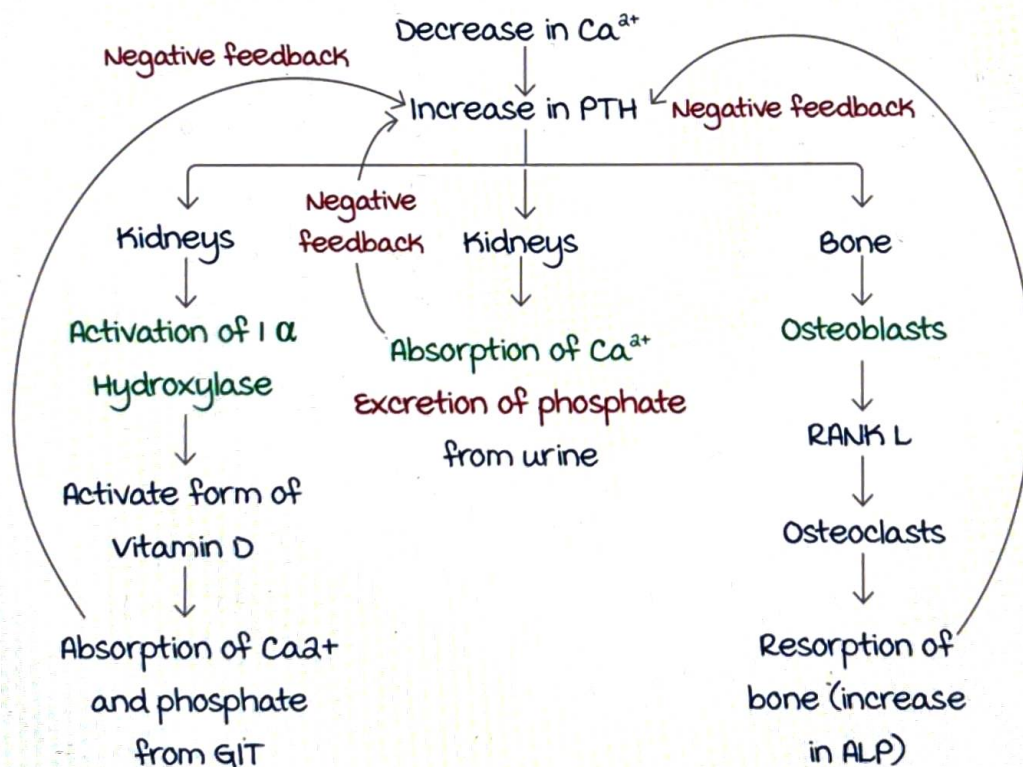
Primary hyperparathyroidism :

This is due to the **disease in the PTH gland** which results in secretion of excessive amounts of PTH.

It has no triggers.

Serum Ca^{2+} is increased beyond the normal levels.

mechanism of action of PTH :



PTH receptors are present on the osteoblasts.

Denosumab : RANK ligand inhibitor.

Bone resorption leads to activation of osteoblasts and causes resynthesis of bone (elevation of serum ALP).

Lab findings in secondary hyperparathyroidism :

- Ca^{2+} : **Decreased/normal**.

- PTH : Increased.
- phosphate : Decreased.
- ALP : Increased (bone turnover).

Lab findings in primary hyperparathyroidism :

- **PTH : Increased.**
- Ca^{2+} : Increased beyond the normal levels (works without any negative feedback).
- Phosphate : Decreased (due to continued excretion of phosphate from the kidneys).
- ALP : Increased (excessive breakdown of the bone).

Metabolic bone disorders

00:18:19

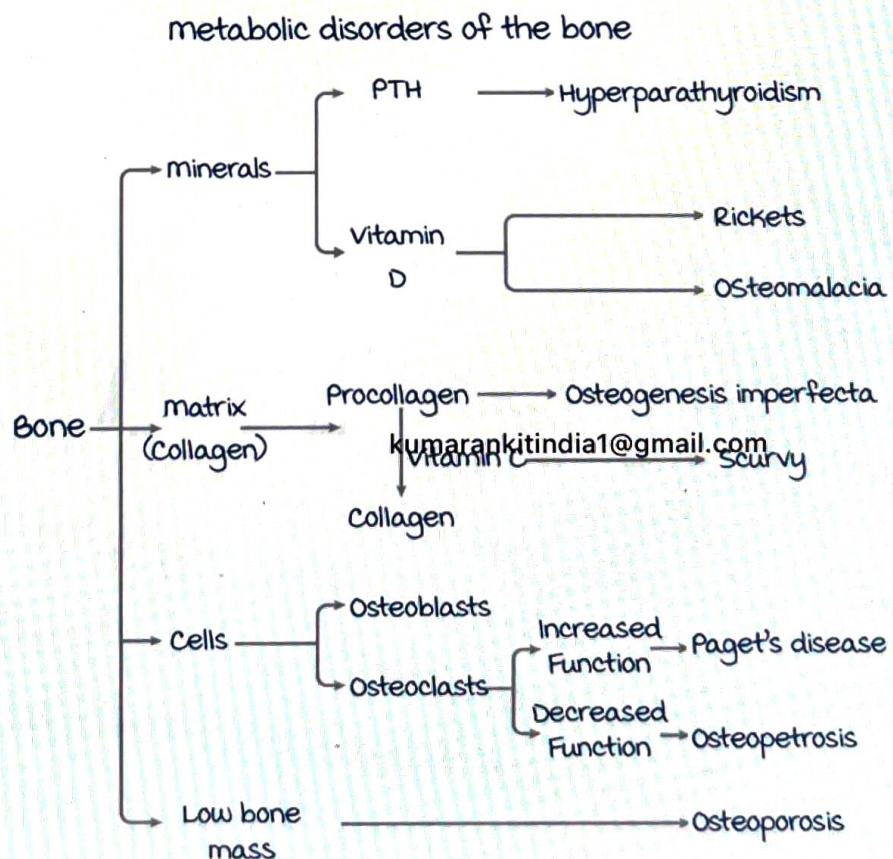
Weak bone : Presents with bone pain.

Pathological fractures (pathology in the bone).

Radiological features.

Lab parameters disturbed.

Clinical features are due to disturbed lab parameters.



Rickets

00:26:23

Rickets occurs **before skeletal maturity** (in children).

Osteomalacia occurs **after skeletal maturity** (in adults).

Causes :

- Decrease in **Vitamin D** : Hypocalcemia.
 1. Nutritional (m/c).
 2. malabsorption.
 3. Lack of sunlight exposure (sunscreens > SPF 30).
 4. Liver and kidney diseases.
 5. **Drugs**.
- Decrease in calcium.
- Decrease in phosphate.

Terminologies :

Osteoid maturation time : Time taken by the osteoid to become osteon.

Hypocalcemia increases the osteoid maturation time.

mineral apposition time : Speed at which the mineral gets deposited on the osteoid.

Hypocalcemia decreases the mineral apposition time.

Lab findings :

- Ca^{2+} : **Decreased**/normal.
- PTH : Increased (secondary hyperparathyroidism).
- Phosphate : Decreased.
- ALP : Increased (bone turnover).

Skeletal manifestations

00:31:31

Skull :

- **Craniotabes/ping pong skull** : Softening of the skull (earliest change).
- Frontal bossing.
- Delayed closure of fontanelle.

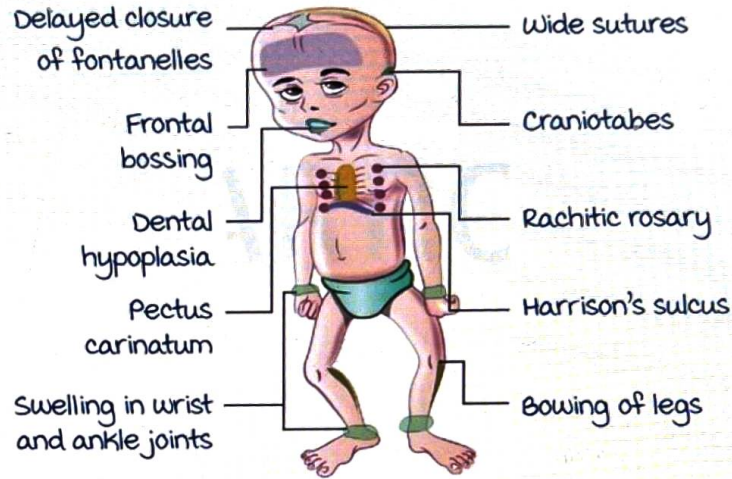
Chest :

- **Rachitic rosary** : Costochondral junction swellings (**blunt and non-tender**).

- Pigeon chest/pectus carinatum : Prominent sternum.
- Harrison sulcus : Under the ribs where the diaphragm inserts.

Bending of long bone : Once the child starts bearing weight (not seen in infants).

10 important clinical features in rickets

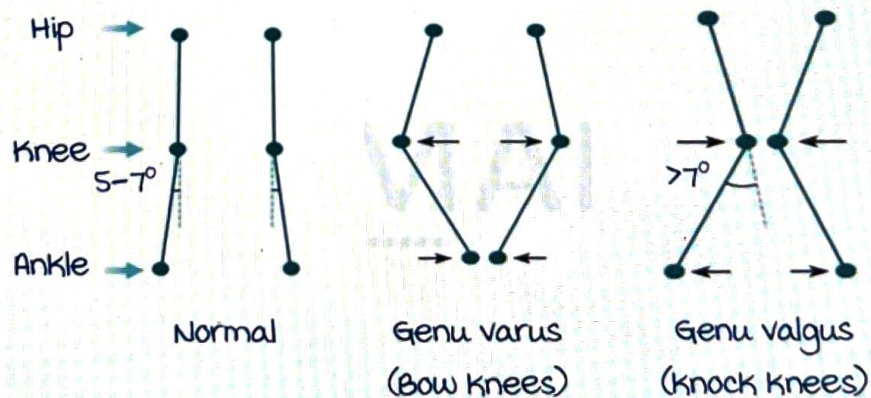


Terms related to joints :

- Coxa : Hip.
- Genu : Knee.
- Cubitus : Elbow.

The type of deformity is based on the part distal to a joint.

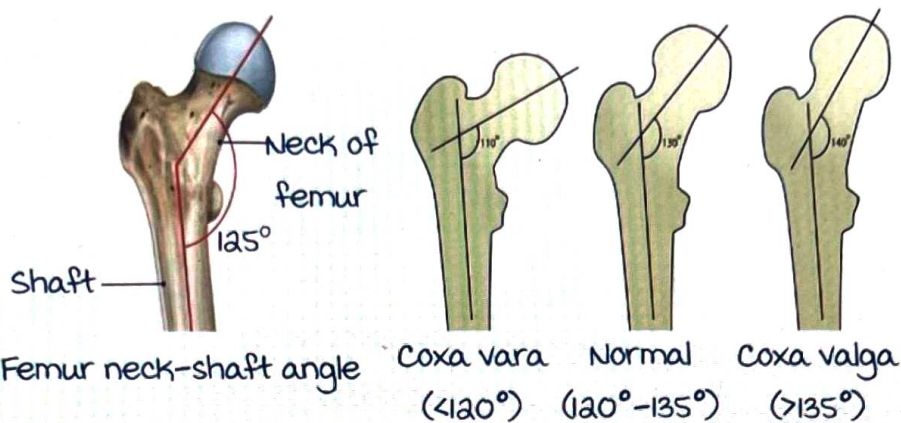
- Distal part is away from the midline : Valgus.
- Distal part is towards the midline : Varus.



Proximal part of the femur :

Normal angle between the neck and the shaft of the femur is $125^\circ - 130^\circ$ (neck shaft angle/mikuliczs angle).

Active space



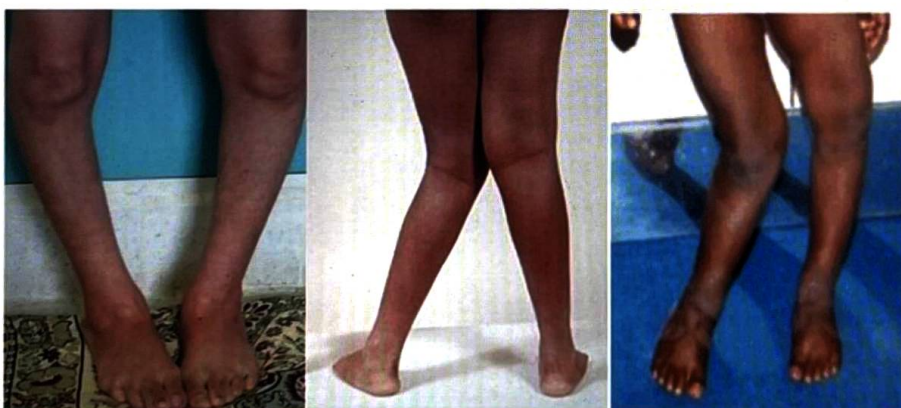Clinical findings :

In knee :

- Bilateral Genu valgum (Knock knees).
- Bilateral Genu varum (bow knees).
- Wind swept deformity (varus on one side and valgus on the other side).

kumarankitindia1@gmail.com

1. MCC overall : Rickets.
2. MCC in children : Rickets.
3. MCC in adults : Rheumatoid arthritis.



Bow knees

Knock knees

Wind swept deformity

	Bilateral Genu Varum (Bow Legs)	Bilateral Genu valgum (Knock Knees)	Wind Swept Deformity
MCC in Children	Rickets > Idiopathic	Idiopathic > Rickets	Rickets
MCC in adults	Osteoarthritis > Rheumatoid Arthritis	Rheumatoid Arthritis > Osteoarthritis	Rheumatoid Arthritis

Active space

Radiologic features of rickets :

Bowing of long bones.

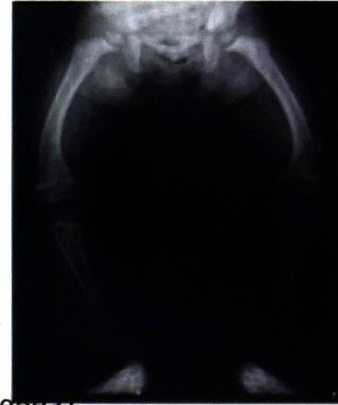Joints : Swollen (hypertrophic layer of the growth plate keeps on expanding without the mineralization).

Cupping of metaphysis.

Splaying of metaphysis.

Fraying of metaphysis.

widening of the epiphyseal plates.

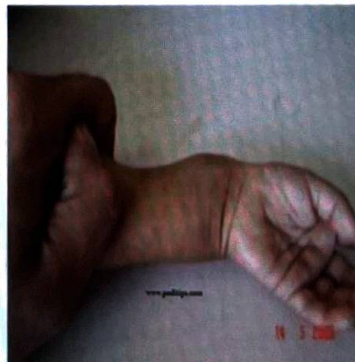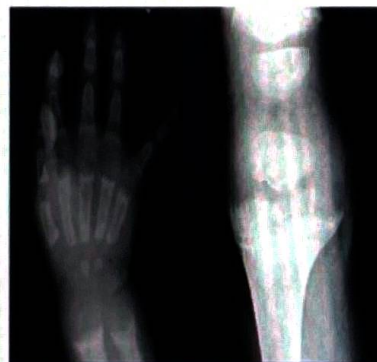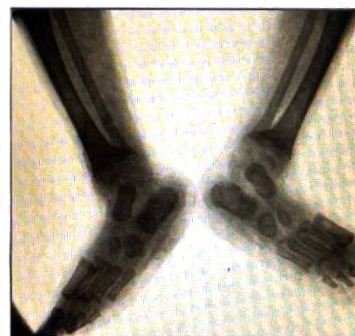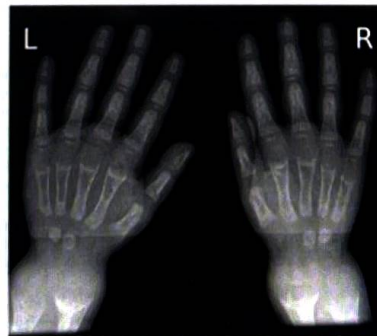
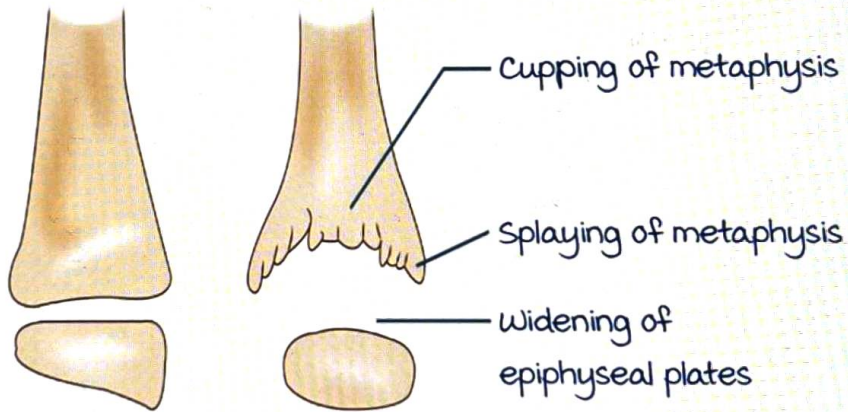


Bowing of legs

Osteoclasts cannot act on improperly ossified bone.

most of the deformities are reversible on treatment with vitamin D.

Radiological features of rickets



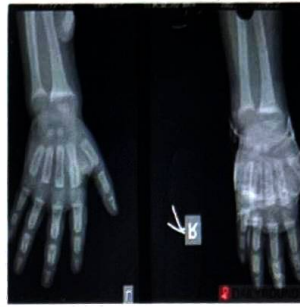Active space

Healing rickets

00:45:33

Dense mineralization of growth plate :
Healing rickets.

Whiteline of Frankel : Thick band of calcification on the metaphysis.
Best method to assess the healing of rickets is X-ray > serum ALP.



Treatment of deformity in rickets

00:46:55

- mermaid splint and vitamin D therapy.
- Surgery for deformity correction.
 1. Young : wait for remodelling.
 2. Older child : Osteotomy after the bone activity is reduced which is assessed by bone turnover (normal Serum ALP).

Osteomalacia

00:49:44

Occurs after skeletal maturity.

Female > male.

Young people.

Presentation : Polyarthralgia, bone pains, proximal myopathy.

Deformities/x-rays :

milkman's fractures/looser zone/pseudo

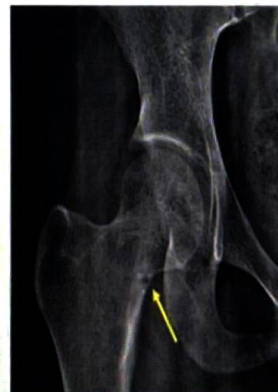fractures :

AKA cortical infarctions.

Pulsations from the arteries around the bone can cause stress fractures which heal by the callus which is deficient in mineral.

These appear as transverse bands of rarefaction which are perpendicular to long axis of bone.

MC sites : Neck of femur, clavicle, ribs, scapula, pubic ramus.



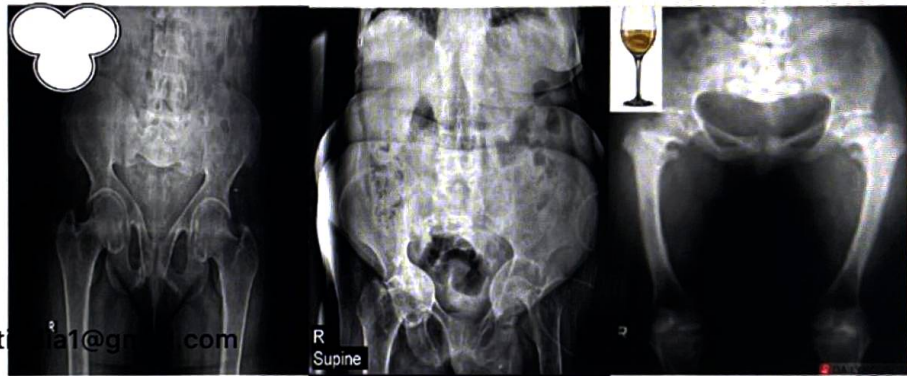Looser's zone

Looser's zones are also seen in :

- Hypothyroidism.
- Paget's disease.
- Fibrous dysplasia.
- Osteogenesis imperfecta.
- Renal osteodystrophy.
- X linked hypophosphatemic rickets.

Other deformities in osteomalacia :

- Triradiate pelvis.
- Trefoil pelvis.
- Protrusio acetabuli.
- Champagne glass pelvis (also seen in achondroplasia).



Trefoil pelvis

Protrusio acetabuli

Champagne glass pelvis

Treatment of rickets and osteomalacia

00:53:27

STOSS regimen which is given as either :

- 3 lakh - 6 lakh IU deep IM or oral (stat / over 1 - 5 days).
- Daily : 2K-5K IU for 4-6 weeks.
- Weekly : 50K-60K IU for 8-12 weeks.

Tumors that induce osteomalacia :

- Fibrosarcoma.
- Osteoblastoma.
- Osteosarcoma.
- Non-ossifying fibroma.

Scurvy

00:54:29

Collagen maturity defect because of vitamin C deficiency.
Laboratory values are normal as mineralisation is normal.
Problem is in endothelium/skin/gums.

Clinical manifestations of scurvy

Bone

Diaphysis :

- Ground glass appearance.
- Pencil thin cortex.

metaphysis :

- Whiteline of Frankel.
- Scorbutic zone.

(Trummerfeld zone)

- Pelkan's spur.

Epiphysis :

- Wimberger ring sign (sclerotic rim around the epiphysis).

Blood vessels

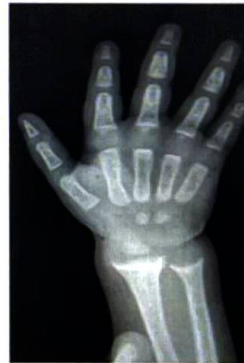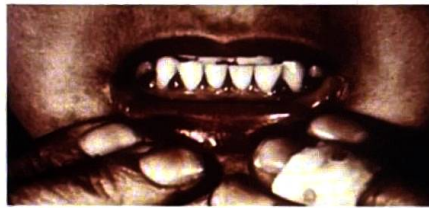Bleeding gums.

Costochondral junction :

- Scorbutic rosary.
- Tender and sharp.

Bone :

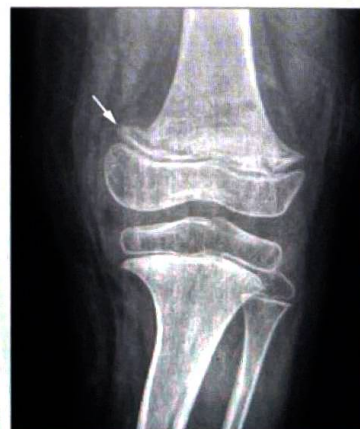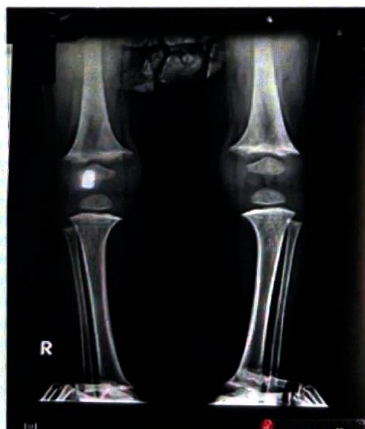Subperiosteal hemorrhage.



kumarankitindia1@gmail.com

D/D of whiteline of Frenkel :

- Healing rickets.
- Congenital syphilis.
- Plumbism.
- Leukemia.



Conditions which can present with pseudoparalysis (due to pain on movement) :

- Scurvy (due to subperiosteal hemorrhage).
- Osteomyelitis.
- Septic arthritis.

Barton's disease

00:57:42

Due to deficiency of vitamin C and D.

Presents with overlapping rickets and scurvy features.

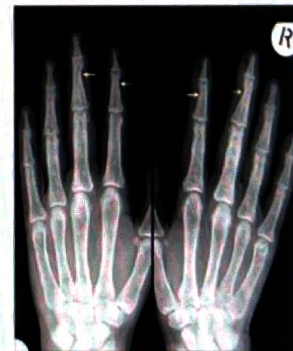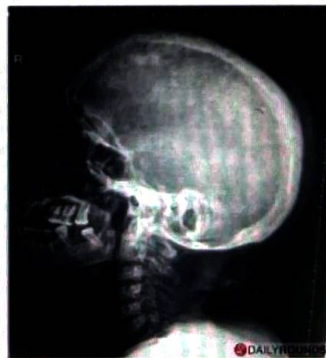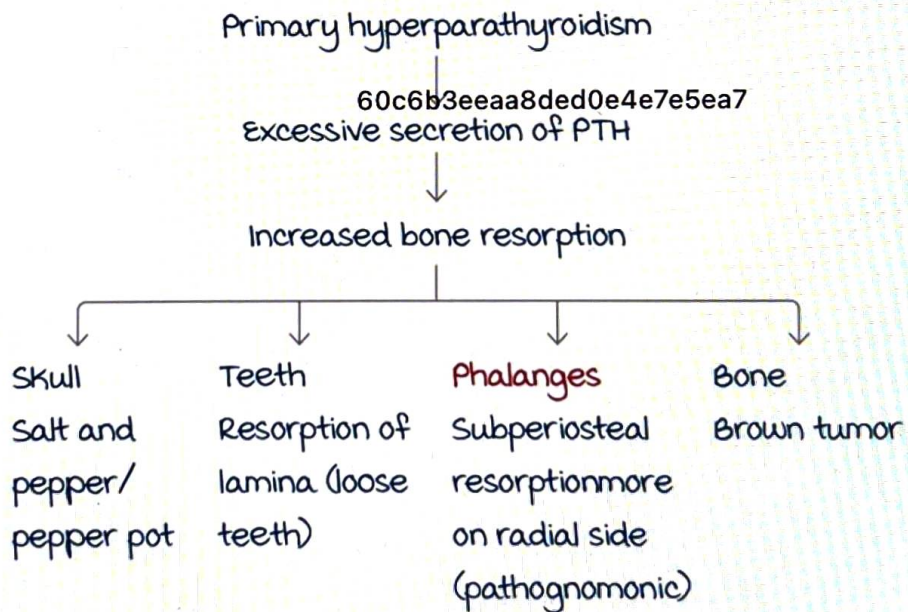
Barton's fracture : Intra-articular fracture at the distal end of the radius.

Hyperparathyroidism

00:58:13

Primary hyperparathyroidism : **Adenoma** of the PTH gland (MC cause).

Secondary hyperparathyroidism : Hypocalcemia (vitamin D deficiency, liver failure, renal failure).



There is no feedback to the PTH secretion leading to :

- Excessive bone breakdown.
- Excess accumulation of $S. Ca^{2+}$.

manifestations due to increased $S. Ca^{2+}$: (mnemonic : **Bones, stones, groans, fatigue, psychiatric overtones**) :

Painful bones	Painful bone condition (classically osteitis fibrosa cystica)
Renal stones	kidney stones (can ultimately lead to renal failure)
Abdominal groans	Gastrointestinal symptoms; nausea, vomiting, constipation
Psychiatric moans	Effects on nervous system; lethargy, fatigue, memory loss, psychosis, depression

Laboratory findings :

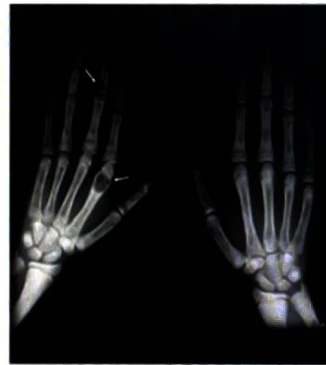- **PTH : Increased**
- Calcium : Increased.
- Phosphate : Decreased.
- ALP : Increased.
60c6b3eeaa8ded0e4e7e5ea7

Brown tumor :

Accumulation of blood in the cavities formed due to bone reorption where hemoglobin breaks down into hemosiderin (brown colored fluid).

AKA osteitis fibrosa cystica.

AKA von Recklinghausen disease of the bone.



Treatment of primary hyperparathyroidism : Surgical excision of the adenoma.

Renal osteodystrophy

01:03:57

Seen in renal failure patients which leads to :

Deficiency of vitamin D : Hypocalcemia.

Renal failure leads to excess excretion of calcium.

Phosphate levels are high.

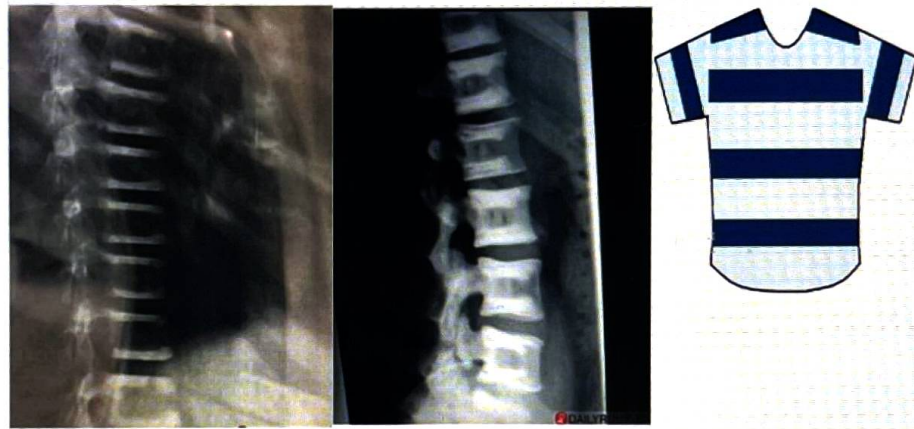
Hypocalcemia triggers PTH (Secondary hyperparathyroidism)

leading to excessive breakdown of the bone (increased ALP) to release free calcium which gets excreted out from the kidneys.

Laboratory findings :

- Calcium : Decreased
- PTH : Increased
- Phosphate : Increased
- ALP : Increased

Radiological feature : Rugar jersy spine (destruction of the bone just under the endplates)



Laboratory findings summary :

	Primary	Secondary	Renal osteodystrophy
Calcium	↑↑	↓/N	↓
PTH	↑↑	↑	↑↑
Phosphate	↓	↓	↑↑↑
ALP	↑	↑	↑

kumarankitindia1@gmail.com

METABOLIC BONE DISEASE : PART 2

Osteoporosis

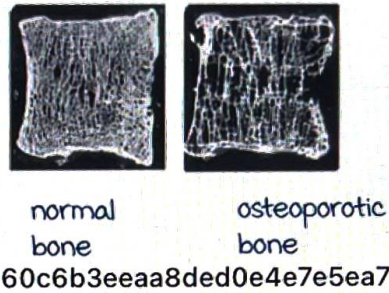
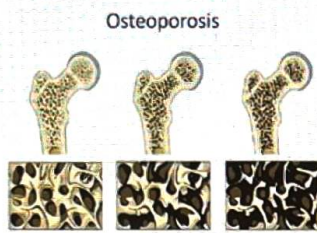
00:00:31

Volume/ mass/ density of bone decreases.

Quantitative defect.

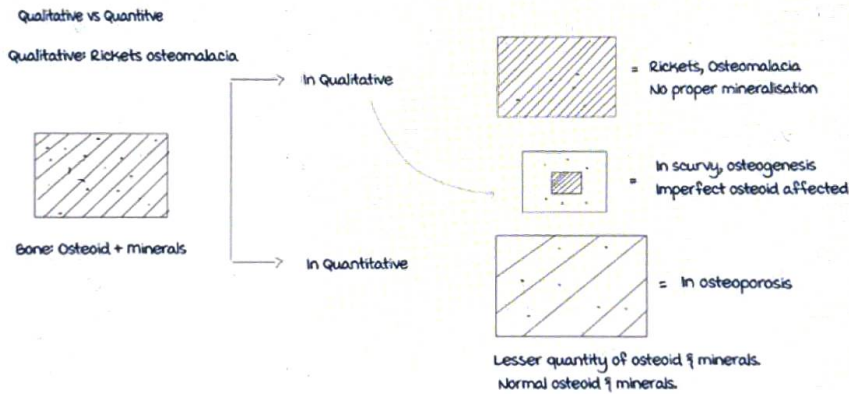
Porous bone disease

Normal bone quality.



60c6b3eaa8ded0e4e7e5ea7

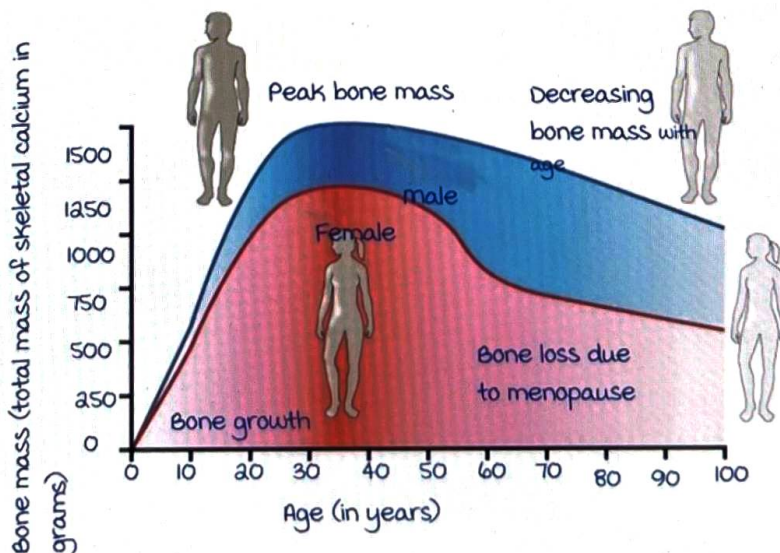
Qualitative versus quantitative defect :



Osteoblast : Bone formation.

Osteoclast : Bone resorption.

In young age, the balance shifts towards osteoblast & In old age shifts towards osteoclast.



Active space

Estrogen is protective against osteoporosis.

At 50-60 years, the female's graph shows dip due to bone loss due to menopause.

m/c cause : Age

m/c risk factor : menopause.

Peak bone mass :

maximum at ~ 30 years. Declines with age.

Determined by multiple factors :

Genetics / nutrition / exercise / activity.

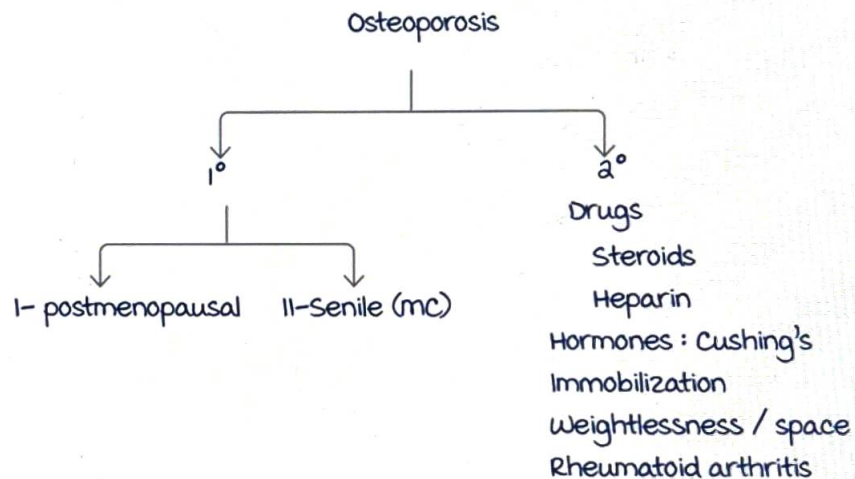
Risk factors :

modifiable :

Sedentary life style, alcohol / smoking.

Non modifiable :

Age, race, asian, female.



Normal : LL bone > UL bone density.

Localised osteoporosis : In hemiplegia / bedridden patients :

upper limb (UL) > lower limb (LL)

Proximal > distal.

60c6b3eaaa8ded0e4e7e5ea7

manifestations :

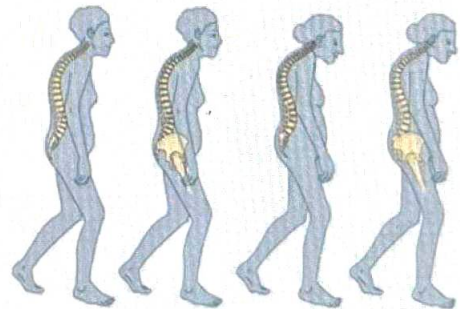
Female > male.

Elderly women usually.

Pain in lower back : **Earliest symptom** (before fracture).

Since, osteoporotic bones affect weight bearing → microscopic fractures → eventually macroscopic fractures.

MC & earliest fracture site : vertebral fractures.



Laboratory investigations : Normal .

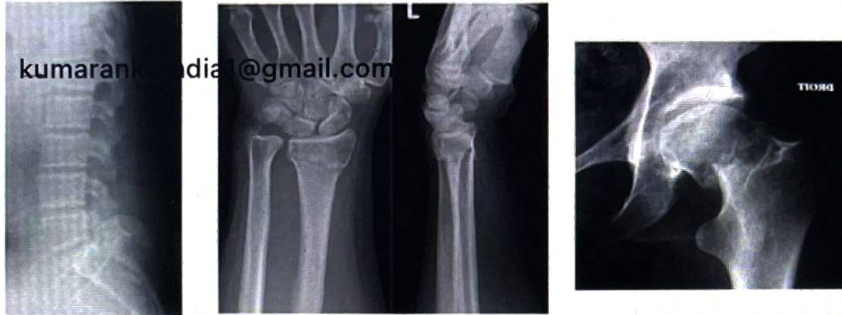
m/c complication :

Fragility fracture - Spine, neck of femur/hip, Colles fracture.

Spine fracture → Deformity : Kyphosis.

Kyphosis is due to **vertebral compression**.

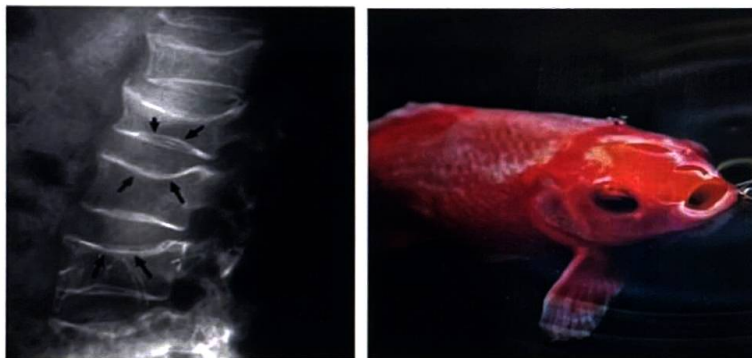
Height reduces and patient bends forward.



Codfish / fish mouth vertebrae :

soft vertebrae & end plates compresses around inter-vertebral disc.

Evident after 30% loss of bone.



Screening options :

- **Quantitative CT Scan :**
Expensive & more radiation exposure.
- **Single photon emission absorptionmetry :**
Do not give generalised picture.
- **DEXA Scan - IOC**
Dual energy xray absorptiometry.
was invented to measure body fat.

DEXA Scan results are compared between two population.

Z-Score :

Same sex & race of **same age**.

Not used for diagnosis of osteoporosis.

Example : In elderly, even reference will have low density.

T-Score :

Same sex & Race of **young reference (30 years)**.

male/female.

used for diagnosis of osteoporosis.

T Score : WHO classification.

Standard deviation

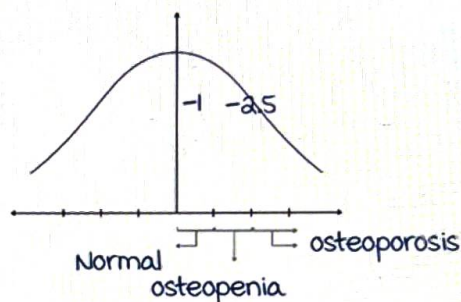
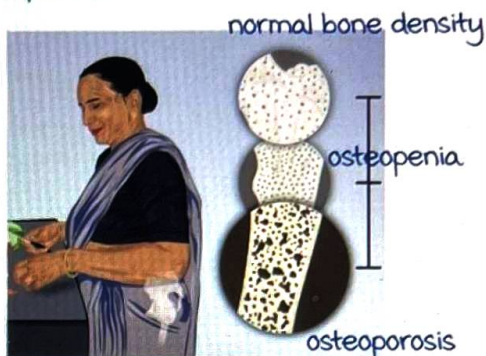
0 to (-1) : Normal

(-1) to (-2.5) : Osteopenia

< (-2.5) : Osteoporosis

< (-2.5) with fracture :

Severe osteoporosis



Osteoporosis screening by NOF (National Osteoporosis Foundation) :

- Woman age 65 or older.
- man age 70 or older.
- If break a bone after age 50.
- Woman of menopausal age with risk factors.
- Postmenopausal woman under age 65 with risk factors
- man age 50-69 with risk factors.

Laboratory investigations like calcium/PTH/phosphate/ALP :
Normal.

Treatment of Osteoporosis

00:22:02

- medical

Decrease Bone Resorption	Increase Bone Formation	Does Both
Bisphosphonate	Teriparatide (rPTH)	Strontium Ranelate
SERM - Raloxifene	Abaloparatide (PTHrp)	Not used now
HRT - For Post menopausal Syndrome	Romosuzumab	

Active space

60c6b3ee2a80e0e47e5ea7

Supplements	Dosage
Calcium	800-1200mg/day
Vit D	400-800 IU/day
Vit K	200-400 IU/day
Calcitonin	-

Bisphosphonates :

Drug of choice.

Inhibit bone resorption.

Risedronate : Once a week dosage.

Ibandronate : Once a month dosage.

Zoledronate :

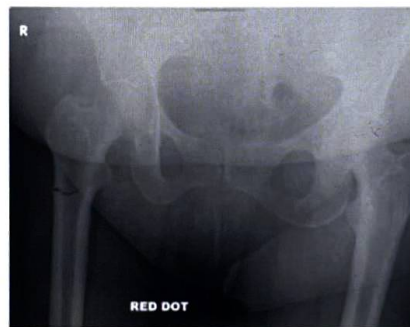
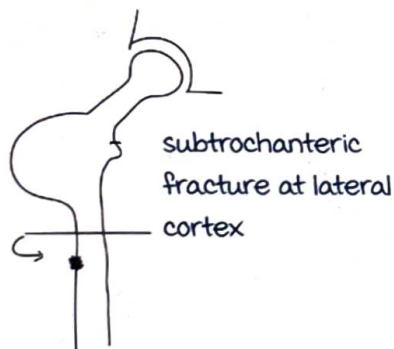
Once a year dosage.

Good compliance.

Complication :

3-5 years of intake of bisphosphonates leads to

Atypical fracture occurring in hip (in ~ 5%).



Prevention of atypical fracture :

Drug holiday : Patient asked to stop intake after 3-5 years of use for few months - 1 year.

Alternate drugs prescribed.

Later bisphosphonates can be given.

Teriparatide :

Synthetic parathormone (acts as anabolic drug).

Parathormone acts on osteoclast and latter releases

Receptor activator of nuclear factor Kappa-B ligand (RANKL) causing bone resorption.

But in small doses, RANKL is not released but increases osteoblast.

Romosuzumab :

Antisclerostin .

Sclerostin : Osteoblast inhibitor.

Increases bone formation formentorindia1@gmail.com

In **severe osteoporosis** patient is started on anabolic drugs (Teriparatide) to increase bone density and later put on Bisphosphonates.

Deformity correction :**Kyphosis correction :**

vertebral compression stable : Taylor brace.

vertebral compression unstable :

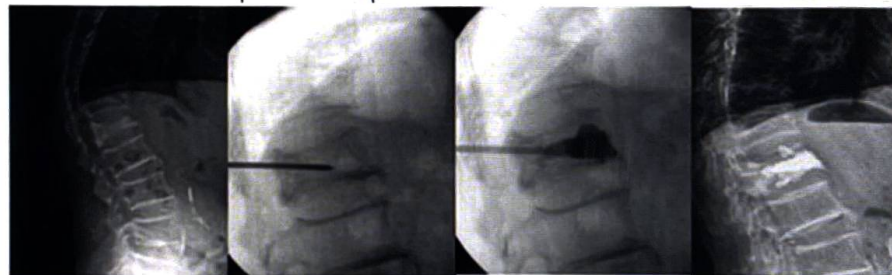
2 ways : vertebroplasty Or kyphoplasty.

Vertebroplasty :

Insert needle into fracture

Put bone cement polymethylmethacrylate (PMMA).

Hold bone fragment together.



Pre-operative

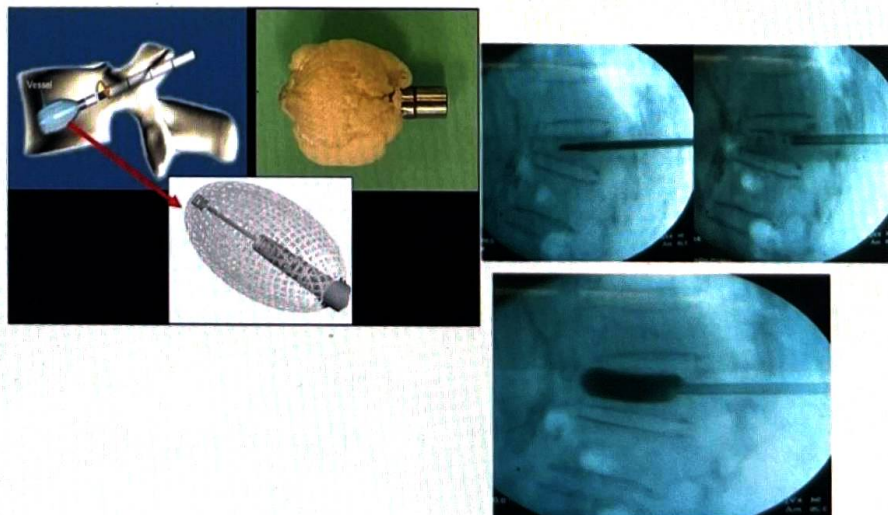
Intra operative

Post-operative

Balloon kyphoplasty :

Restore vertebral height.

Balloon helps in restoring collapsed vertebrae and with needle bone cement inserted.



Locking plate :

Instruments for fixing in osteoporotic soft bones.

Plate with threaded holes & screw which lock on bone .

Weight of screw falling on plate prevents cutting of bone.



Paget's disease

00:34:14

Also called as **Osteitis deformans**.

Abnormal activity of osteoclasts.

Stages :

Lytic.

mixed.

Blastic.

male > female

mainly in elderly patient (5th decade).

m/c cause : Idiopathic

m/c manifestation : Pain

Association :

SQSTM1 gene mutation.

Paramyxovirus.

Pelvis > tibia

Pathology :

Increased osteoclastic activity.



Increase the bone resorption.



Increased bone formation by osteoblast.



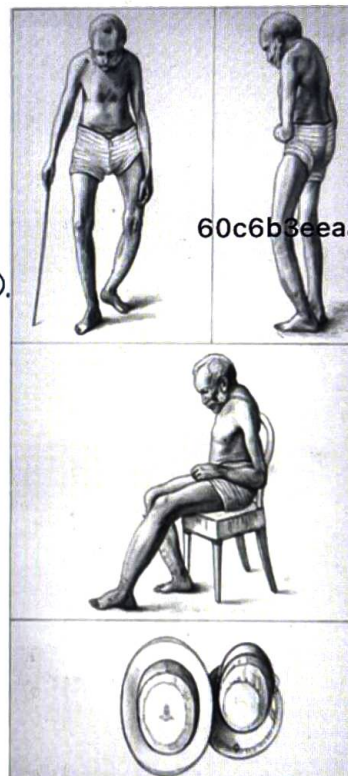
Increased bone turnover hence **increase in ALP**

(may be upto 20 times).

S.calcium & phosphate : Normal

Qualitative defect that is :

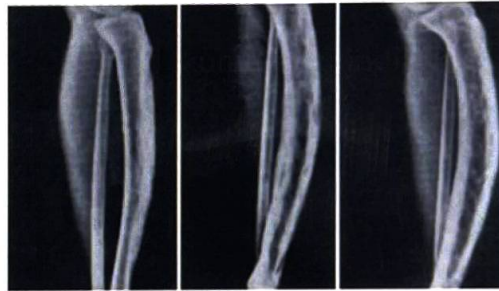
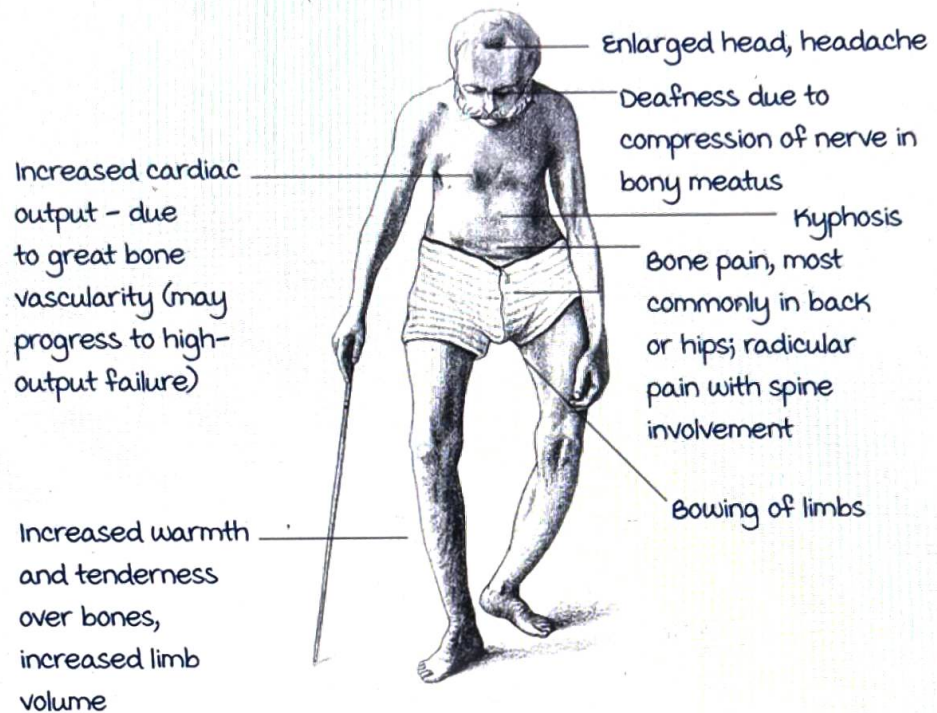
Immature, weak, vascular woven bone (poor bone quality)



60c6b3eaa8ded0e4e7e5ea7

Clinical manifestations of Paget's disease

may occur single or in combination



Clinical features :

Pain : m/c complaint.

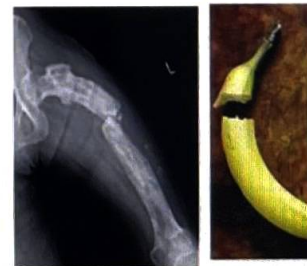Bone :

Warm to touch (due to vascular)

Thickened.

Weak bone.

Banana fracture.



Cranial foramen stenosis :

2nd, 5th, 7th, 8th nerve (leads to hearing loss)

Hearing loss occurs due to :

Cranial foramen stenosis of 8th nerve.

Otosclerosis

Thickening of skull :

Frequent change in hat sizes.

Diagnosis :

Clinically

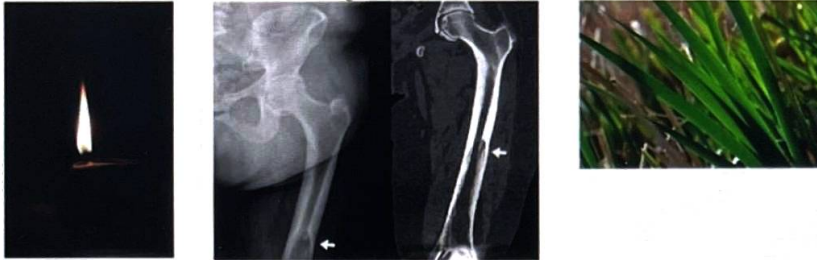Biopsy of bone : mosaic pattern.

Radiologically :

- Lytic phase :

Osteoporosis circumscripta

Flame shaped / Blade of grass appearance



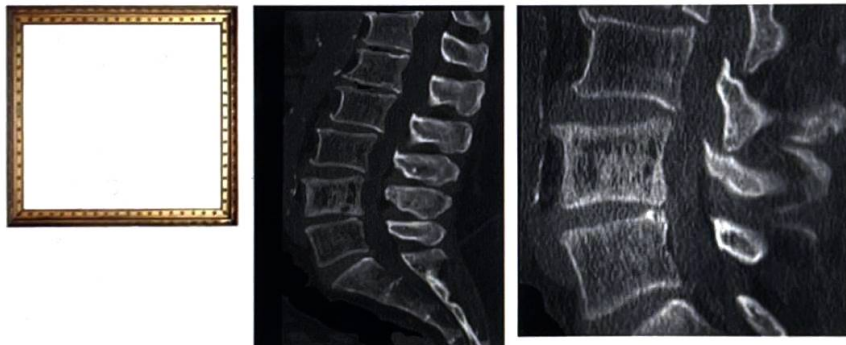- mixed phase :

Picture frame vertebrae

Ivory vertebrae

Cotton wool skull

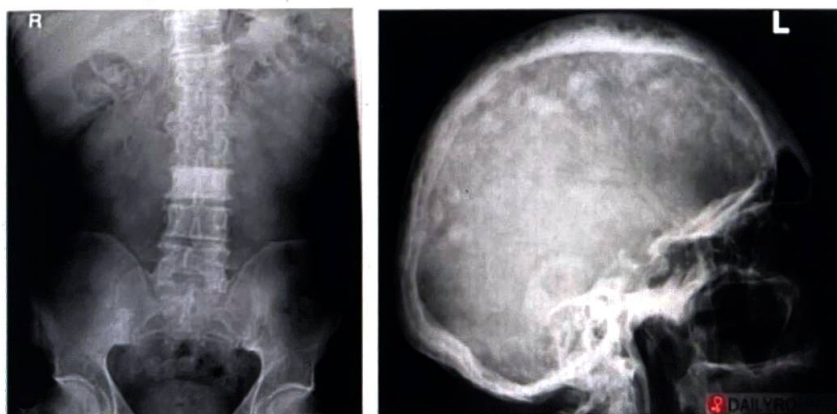
Picture frame vertebrae



60c6b3eeaa8ded0e4e7e5ea7

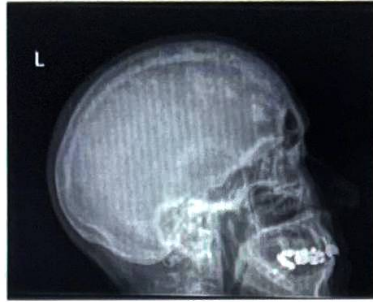Ivory vertebrae

Cotton wool skull



- Blastic Phase

Tam O Shanter skull / Diploic swelling (thickening of skull)



Complications :

High output cardiac failure due to high vascularity of bones :
m/c cause of death.

Banana fracture.

Cranial nerve compression — 2,5,7, 8.

High risk of osteosarcoma.

Treatment :

Suppress osteoclasts with bisphosphonates.

Long acting eg: Zolendronate.

Pain can be managed with Calcitonin (Salmon > Porcine).

Osteogenesis imperfecta

00:44:20

aka brittle bone disease.

COL1A1 Gene defect

AR / Type II :

Still born.

Lethal form of the disease.

AD / Type I / Classical :

Weak bone leads to recurrent pathological fracture.

Fractures even with trivial force

Labs investigation : Normal

multiple fractures in different stages of healing

Diaphyseal

Rule out battered baby syndrome

Battered Baby Syndrome :

Affects metaphyseal part.

Inconsistent history by parents.

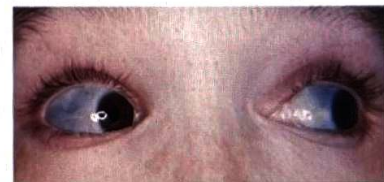Features :

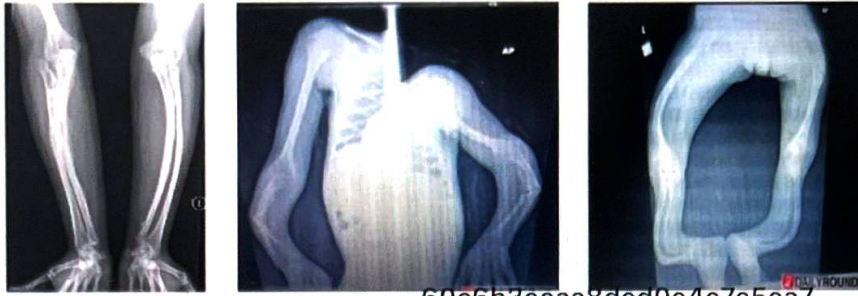Blue sclera.

Delayed dentition.

Bruising.

Deformed bones / Bent — use splints or braces.

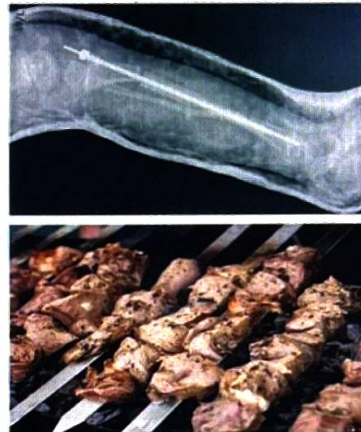
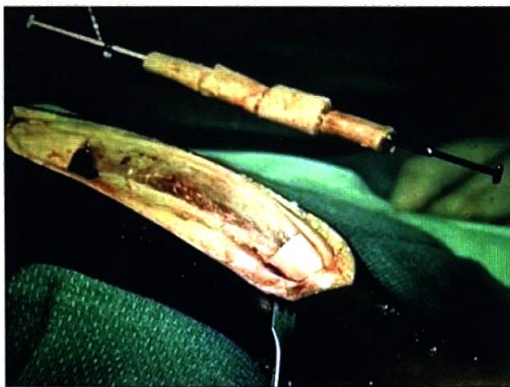



60c6b3eaa8ded0e4e7e5ea7

Treatment :

multidisciplinary approach for fracture prevention with bisphosphonates, fracture management when present, and realignment osteotomies for long bone deformities.



Realignment osteotomy :

The bent part removed and cut into fragments.
Rod called Duboin rod is inserted and bone is put in fragments.
Also called as Seekh kebab/Scofield miller operation.

	Calcium	PTH	Phosphate	ALP
Rickets/om/ Sec Hyper PTH	/N	↑	↓	↑
Renal Osteodystrophy	↓↓↓	↑	↑↑↑	↑
Osteoporosis	N	N	N	N
Primary Hyper PTH	↑↑↑	↑↑↑	↓	↑
Paget's Disease	N	N	N	↑↑↑

MCQs

00:50:07

- Q. Osteomalacia is associated with which one of the following?
A. Decrease osteoid volume & osteoblastic activity

Active space

- B. Increase mineral opposition rate
- C. Increase in osteoid maturation time & defective osteoclastic resorption of uncalcified osteoid.
- D. Defective proliferation of physis

Q. All of the following are the Biochemical changes seen in Osteomalacia except ?

- A. Serum Ca^{2+} Increases
- B. Serum Ca^{2+} decreases
- C. Serum Ca^{2+} Normal
- D. Serum ALP Increases

Q. A 30yr female has low serum calcium and Low serum phosphate with elevated Serum parathormone. what is your likely diagnosis?

- A. Vitamin D deficiency.
- B. Primary hyperparathyroidism.
- C. Osteoporosis.
- D. Paget's disease.

Q. During a routine check-up, a 67yr old man is found to have a level of serum alkaline phosphatase three times the upper limit of normal. Serum calcium, phosphorus and liver function tests are normal. He is asymptomatic otherwise. The most likely diagnosis is?

- A. metastatic carcinoma
- B. Primary hyperparathyroidism.
- C. Paget's disease of bone.
- D. Osteomalacia.

Q. A 65yr old female presented with fracture of T12 vertebra. Her labs show increased alkaline phosphatase and parathormone level along with low calcium and low phosphates. what is your most likely diagnosis?

- A. Osteoporosis.
- B. Paget's disease.
- C. Primary hyperparathyroidism.
- D. Vitamin D deficiency.

Q. A 2yr old child with rickets & foot deformity is on calcium

supplements for treatment. When should the patient be referred for surgical correction of the deformity?

- A. When vitamin D levels return to normal.
- B. When growth plate healing is seen radiographically.
- C. When bone specific alkaline phosphatase is normal.
- D. When serum calcium becomes normal

Q. A child comes to you with Rickets and has genu varum of the right knee. Vitamin D was given for 3 months, and growth plates healed on X-ray. But deformity has persisted. What will be the best time to refer this patient to the Orthopedic surgeon for a corrective osteotomy?

- A. When serum Vitamin D levels become normal
- B. When serum Alkaline phosphatase levels become normal
- C. When Femoro-tibial angle $> 15^\circ$ on X-ray
- D. When serum calcium phosphorous levels become normal

kumarankitindia1@gmail.com

Q. All are True regarding scurvy Except?

- A. Vitamin C deficiency leading to defective collagen & osteoid formation.
- B. Defective elastic fibres & bone mineralization.
- C. Ring sign and metaphyseal fractures.
- D. Dense line between epiphysis & metaphysis.

Q. Which of the following is not a feature of osteitis fibrosa cystica?

- A. Fracture
- B. Tetany
- C. Increased serum calcium
- D. Increased alkaline phosphatase

Q. True regarding Paget's disease is All Except?

- A. Deafness is due to otosclerosis
- B. Heart failure is a dreaded complication
- C. Pain best relieved by NSAIDs
- D. Elevated serum alkaline phosphatase is a common lab finding.

Q. Which of the following is seen in Osteoporosis?

- A. Low Ca, High PO₄, High Alkaline Phosphatase
- B. Low Ca, Low PO₄, Low Alkaline Phosphatase

C. Normal Ca, Normal PO₄, Normal Alkaline Phosphatase

D. Low Ca, Low PO₄, Normal Alkaline Phosphatase

Q. The maximal change in bone mineral density in a hemiplegic patients after 1 year of disease process is seen in?

A. Proximal Humerus of the paretic side

B. Proximal femur of the paretic side

C. Distal radius of the paretic side

D. Proximal Humerus of the Normal side.

Q. All are true about osteoporosis except ?

A. Calcitonin decreases bone pain

B. Bisphosphonates are workhorse for treatment

C. PTH is used in severe osteoporosis

D. T score is < -1.5 in osteoporosis

Q. A 72yr old female is on treatment with alendronate for 7yrs for osteoporosis. Now she complains of pain in right thigh. What is the next investigation to be performed?

A. DEXA scan

B. X-ray

C. Serum vit D levels

D. Serum alkaline phosphate levels

Q. Screening for Osteoporosis should be started at the age of ?

A. 50 y

B. 55 y

C. 60 y

D. 65 y

Q. Which of the following is the IOC for the diagnosis of Osteoporosis?

A. Bone scan

B. DEXA scan

C. Quantitative CT scan

D. Serum biochemistry

Q. Which of the following is a Bone forming drug?

A. Bisphosphonates

B. Teriparatide

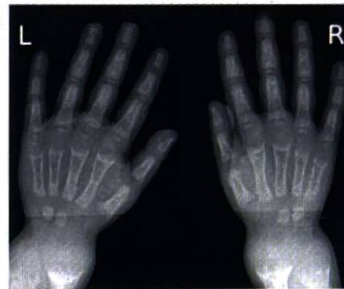
- C. Raloxifene
- D. Calcitonin

Q. Which of the following is the Best method to assess healing in a case of Rickets?

- A. Serum vitamin D levels
- B. Serum Alkaline phosphatase levels
- C. X ray
- D. Serum Calcium phosphate levels

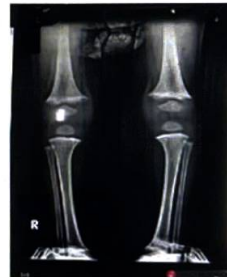Q. What is the Diagnosis in the given X-ray?

- A. Scaphoid fracture
- B. Colles fracture
- C. Rickets
- D. Osteoporosis



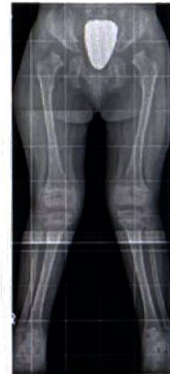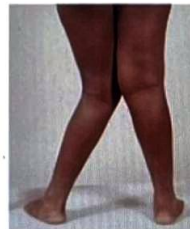Q. A 5-year-old child was brought to the pediatrician with complaints of bilateral knee pain. His bone mineral density is normal. X-ray image of the joints is given below. What is the most likely diagnosis?

- A. Rickets
- B. Scurvy
- C. metaphyseal dysplasia
- D. Pyknodysostosis



Q. What will be the Next step in management when the girl in the given image presents to you in your OPD ?

- A. USG Knee
- B. CT Knee
- C. X-ray Scanogram
- D. MRI



Q. A 55 year old female complains of lower backache. The radiographic image of her lumbosacral spine is given below. What is the probable diagnosis?

- A. Osteoporosis
- B. Ankylosing spondylitis

- C. Osteomalacia
- D. Renal osteodystrophy

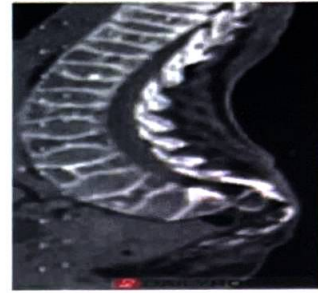
Note :

causes :

Osteoporosis

Osteogenesis Imperfecta

Osteomalacia



Q. Screening for bone mineral density in women is done at the age of ?

- A. At 50 years
- B. At 55 years
- C. At 60 years
- D. At 65 years

Q. Which of the following tests are not commonly used in osteoporosis:

- | | |
|----------------------|-------------------|
| A. DEXA | A. A, B, and C |
| B. Bone scan | B. A and B |
| C. Quantitative CT | C. B, and C |
| D. Chemical analysis | D. A, C, D, and E |
| E. X-ray | |

Q. A 60-year-old woman with history of Colles' fracture 8 months ago, attained menopause at the age of 52, comes with a T score of -2.5 on DEXA Scan, she is currently asymptomatic. What treatment that you will give her?

- A. HRT / Estrogen
- B. Calcium & Vitamin D supplementation
- C. Start Alendronate STAT
- D. Repeat DEXA scan in another 3 months

60c6b3eaa8ded0e4e7e5ea7

Q. A 60-year-old postmenopausal female with previous history of Colles fracture came with complaints of lower backache. On evaluation, her T score was -2.5. Which of the following statements are false about the management of her condition?

- A. Teriparatide should be started before supplementing with bisphosphonates
- B. Bisphosphonates are not given for more than a year
- C. Calcium requirement is 1200 mg per day
- D. Oral vitamin D3 is given along with oral calcium

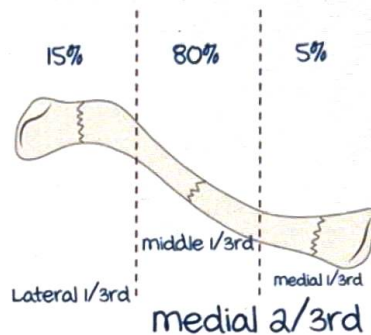
UPPER LIMB TRAUMA : CLAVICLE AND SHOULDER

Upper limb trauma usually occurs due to **falling on an outstretched hand**.

Clavicle

00:02:34

Only long bone arranged horizontally in the body & ossifies in the membrane.
First bone to ossify (5th intrauterine week) & the last bone to complete ossification (20-25 yrs).



Only long bone that has 2 primary centres of ossification.
Curved S-shaped bone.

medial 2/3rd is tubular while lateral 1/3rd is flat leading to vulnerability at the junction.

MC fracture occurs at middle 1/3rd (junction of lateral 1/3rd & medial 2/3rd) or (junction of lateral 2/5 & medial 3/5).

MC bone fracture at the time of birth/difficult birth/birth extraction : **Clavicle fracture.**

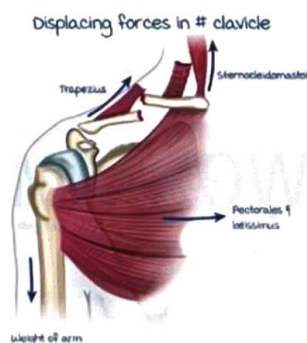
MC fracture in new born : **Clavicle.**

MC fracture overall : **Clavicle.**

Displacements of clavicle fracture :

Weight of the limb.

Pectoralis muscle.

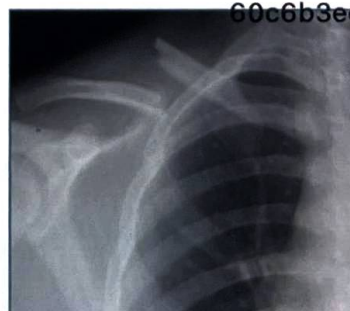


MC complication of clavicle fracture : **malunion.**

Other complications :

Neurovascular injury : Branchial plexus, subclavian vessels.

Non-union (very rare).



60c6b3eeaa8ded0e4e7e5ea7
Active space

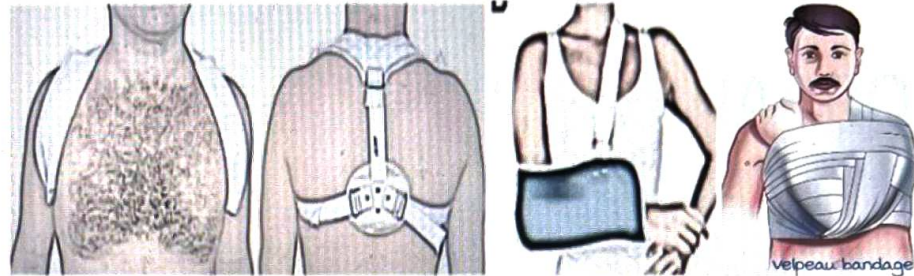
Treatment :

Conservative management :

Figure of 8 bandage : Brings the medial fragment down.

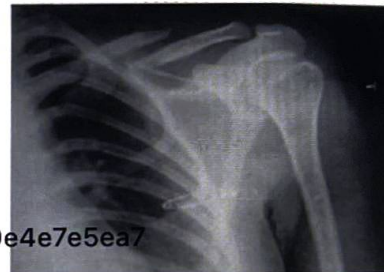
Arm sling/arm pouch : Brings the lateral fragment up.

Velpeau bandage.

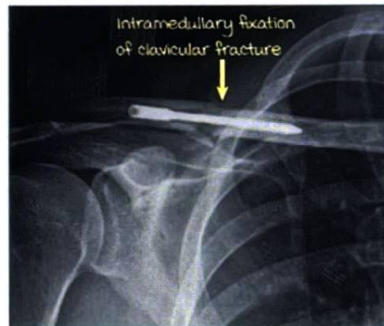

Indications of surgery :

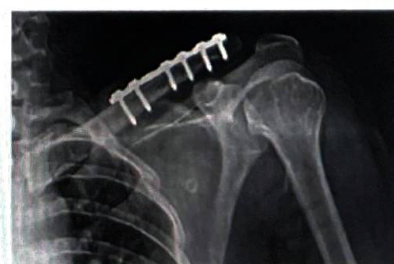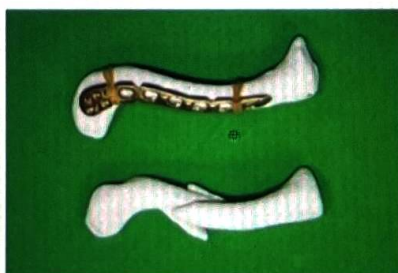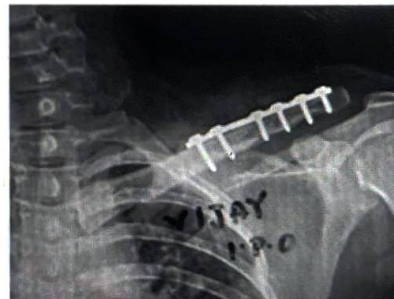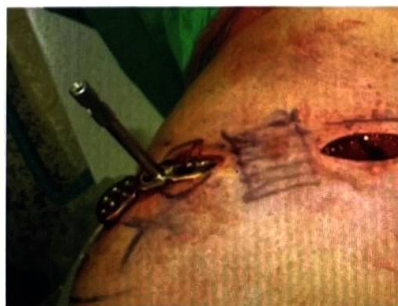- Open clavicle fracture.
- massive displacement (tenting of skin).
- Clavicle fracture involving acromioclavicular joint).
- Fracture with neurovascular injury.
- Floating shoulder : fracture clavicle + fracture glenoid.



Floating shoulder



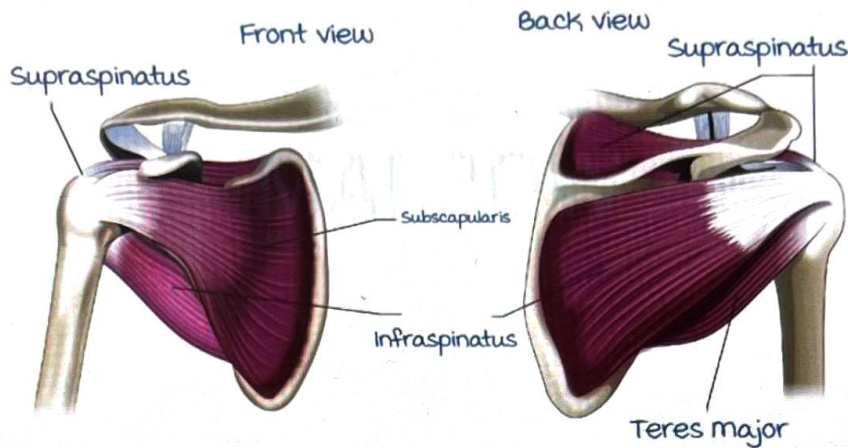
Intramedullary fixation of clavicular fracture



Active space

Shoulder joint

00:13:41



Head of humerus is 4 times larger than the glenoid.

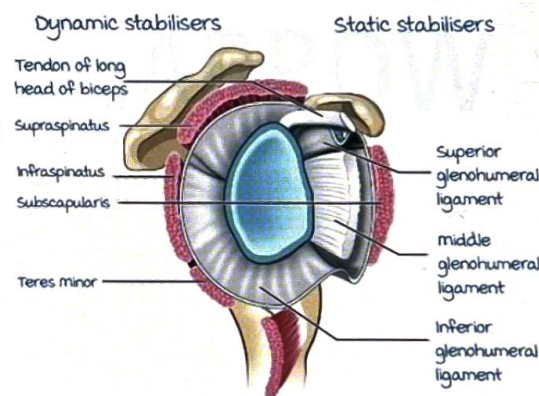
It is a mobile joint, therefore less stable joint.

MC dislocated joint.

Stabilizers :

Dynamic stabilizers :

1. Rotator cuff muscles : Supraspinatus, infraspinatus, teres minor, subscapularis.
2. Deltoid.
3. Long head of biceps.



Static stabilizers :

kumarankitindia1@gmail.com

1. Capsule.
2. Labrum (fibrocartilagenous rim around glenoid).
3. Gleno humeral ligaments : Superior glenohumeral, middle glenohumeral, **inferior glenohumeral** (most important).

Shoulder joint is weakest : **Inferiorly.**

But dislocation is mc : **Anteriorly.**

Shoulder dislocation :

most mobile & **mc** dislocated joint (50% of all joint dislocations).

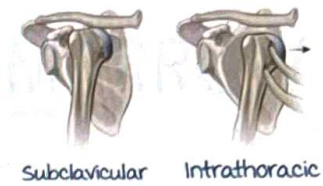
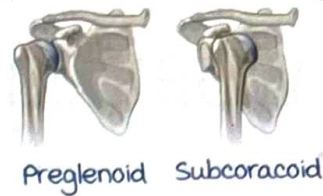
MC dislocation : Anterior (90-98%) > Posterior > Inferior (rare).

Active space

Anterior dislocation :

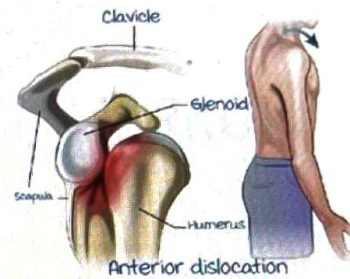
Subtypes :

- Preglenoid.
- Sub coracoid (mc).
- Infra clavicular.
- Intrathoracic.



Attitude of limb :

Arm by the side of the body.
Abducted & externally rotated.



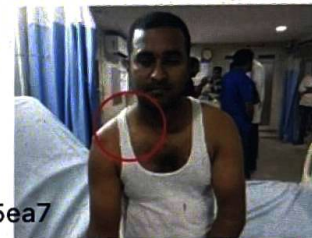Other features :

Difficulty in adduction & internal rotation.

Flattened shoulder contour.

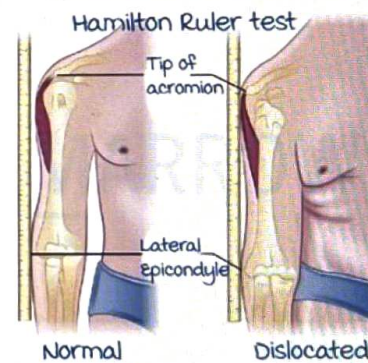
Other injury : Axillary nerve injury (mc nerve).

60c6b3eaa8ded0e4e7e5ea7




Tests :

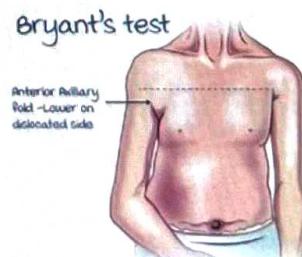
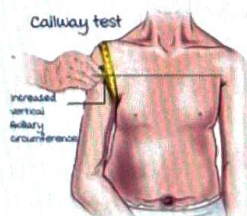
Hamilton's ruler test : Ruler over lateral aspect of arm. Check for touching of the acromion & lateral epicondyle of humerus.



Duga's test : Difficulty to touch opposite shoulder.



Callaway's test : measuring girth of affected shoulder (axilla) & compared with unaffected. Increased girth indicates dislocation.



Bryant's test : Increased vertical axillary circumference.

Active space

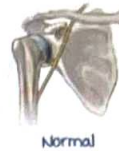Axillary nerve is quite well protected, however can be injured by :

- Proximal shoulder fracture.
- Dislocation of shoulder joint.

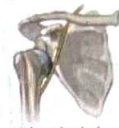Axillary nerve examination :

Deltoid & teres minor.

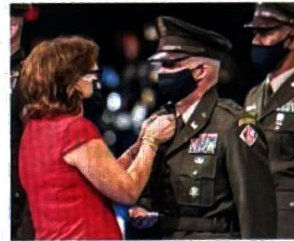Regimental badge area : Pain, paresthesia, tenderness.



Normal



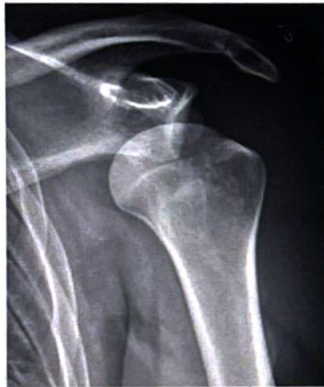Dislocated shoulder



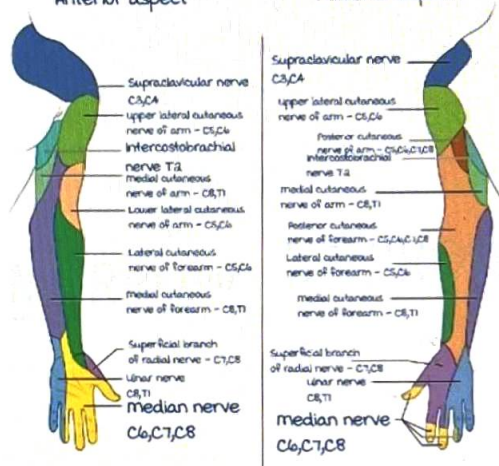
Confirm with X-ray :

AP.

Lateral/axillary view.



Cutaneous Innervation of upper limb Anterior aspect Posterior aspect



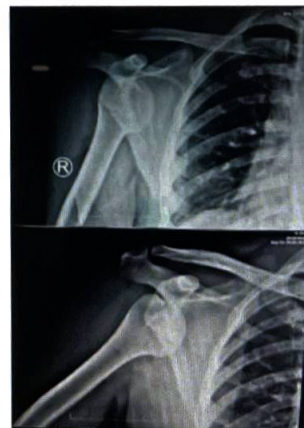modified Kocher's technique : TEAM.

Traction is applied.

External rotation.

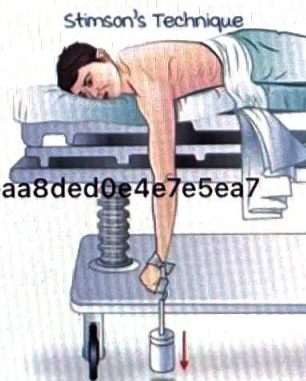
Adduction.

medial rotation/internal rotation.



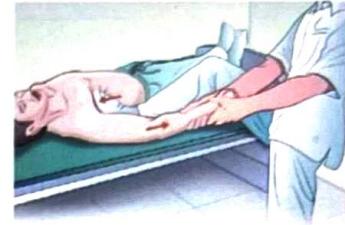Stimson's technique :

Patient prone on table with affected limb hanging freely over edge, 10-15-lb weight is suspended from wrist. Gradual traction overcomes muscle spasm and in most cases achieves reduction in 20-25 minutes.



Active space

Hippocratic technique : Reduction is done by placing the foot in the axilla, and using the axilla as a fulcrum. Not preferred.



Complications:

Bankart lesion :

MC lesion associated with dislocation.

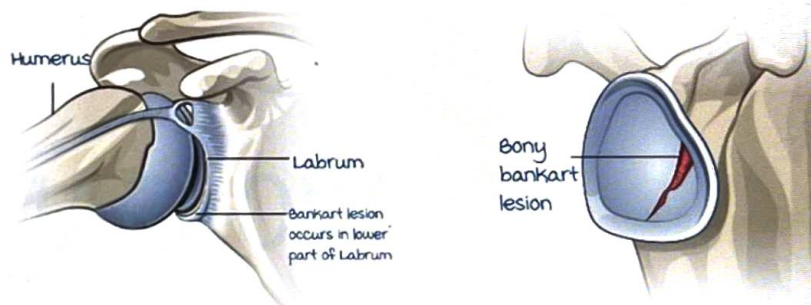
Avulsion of the labrum from the anteroinferior glenoid rim.

It is usually soft tissue bankart or sometimes bony bankart.

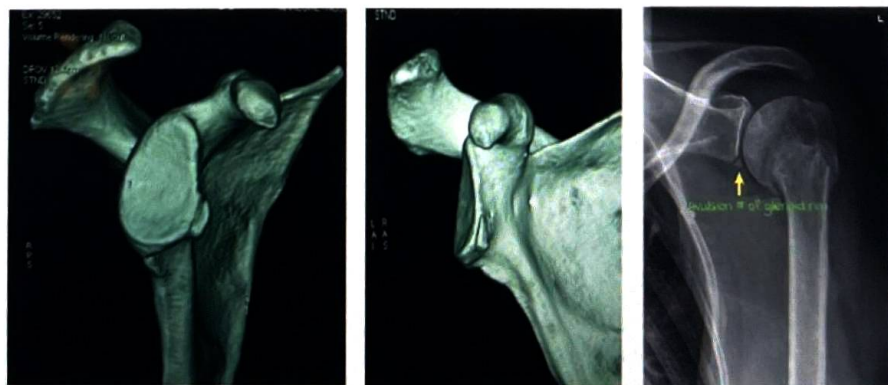
As the glenoid labrum is avulsed, it chips off a small piece of bone with it, this is known as bony bankart lesion (very rare).

Bony Bankart lesion :

Due to tear of anterior part ofIGHL, the principle stabilizer of shoulder joint against anterior shoulder dislocation




Bankart lesion



Hill Sach's lesion :

A defect or excavation on the postero-lateral surface of

60c6b3eeaa8ded0a4e7e5aa7
 humeral head due to repeated impact against the anterior glenoid rim.



mc complication of shoulder dislocation : **Recurrent shoulder dislocation.**

mc early complication of shoulder dislocation : **Axillary nerve injury.**

mc late complication of shoulder dislocation : **Recurrent shoulder dislocation.**

mc nerve injured in shoulder dislocation : **Axillary nerve.**

mc type of shoulder dislocation : **Anterior dislocation.**

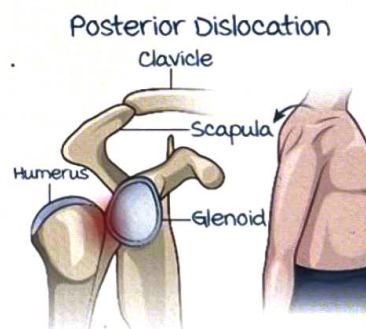
mc sub type of shoulder dislocation : **Subcoracoid.**

Weakest part of the shoulder joint : **Inferior.**

Rarest type of shoulder dislocation : **Inferior dislocation.**

Posterior dislocation :

mechanism of injury : High voltage electric shock, ECT, seizure, fall on outstretched hand, direct trauma.



Attitude : Adducted & internally rotated.

Shoulder contour is not lost.

Inability to abduct or externally rotate.

Light bulb sign seen on x ray.

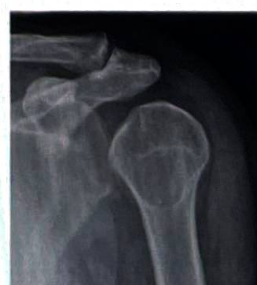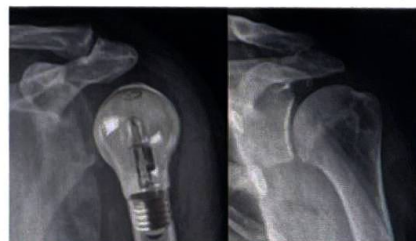Lesions :

Reverse Bankart :

Postero-inferior.

Reverse Hill Sach's :

Antero-medial.



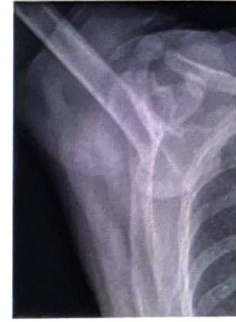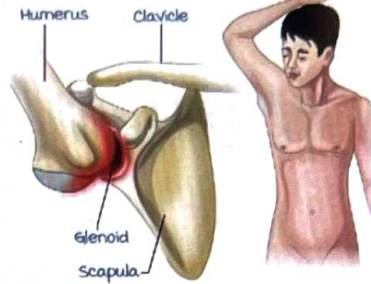
Inferior dislocation :

Luxatio erecta :

mechanism of

injury : *Hyper abduction injury.*

Arm by the side of the head.



Tests for shoulder instability :

Anterior :

1. Fulcrum test.
2. Crank test.
3. Apprehension test : Abduct & external rotate shoulder.

Posterior : Jerk test

Inferior : Sulcus test.

Surgeries for shoulder instability :

Putti Plat operation :

Subscapularis & anterior capsule is double breasted, leading to internal rotation of shoulder. Prevents external rotation and therefore prevents dislocation of shoulder.

Bristow Latarjet operation :

Coracoid is osteotomized & placed in front of humerus near glenoid which prevents dislocation acting as a door stopper.

Nowadays, arthroscopic Bankarts and Hill sach surgeries are preferred.

60c6b3eaa8ded0e4e7e5ea7

UPPER LIMB TRAUMA

ARM AND ELBOW

Proximal Humerus Fractures

00:00:08

Two necks of proximal humerus :

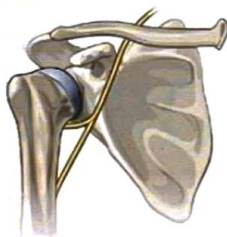
Anatomical neck is located just under the articular surface.

Surgical neck goes through the greater and lesser tuberosity.

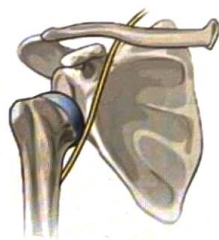
most common location of fracture of proximal humerus.

Axillary nerve injury :

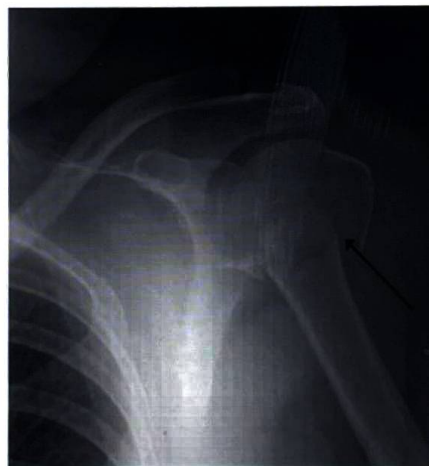Fracture of proximal humerus invariably causes axillary nerve injury due to its proximity.



Normal



Dislocated shoulder



X-ray shows fracture of surgical neck of humerus

Proximal humerus fracture :

60c6b3eaaa8ded0e4e7e5ea7

- Seen in post menopausal, elderly osteoporotic females.
- Less dense other bones as density decreases in UL > LL and proximal > distal.
- mc complication - Stiffness of shoulder
- mc injured nerve : Axillary nerve.

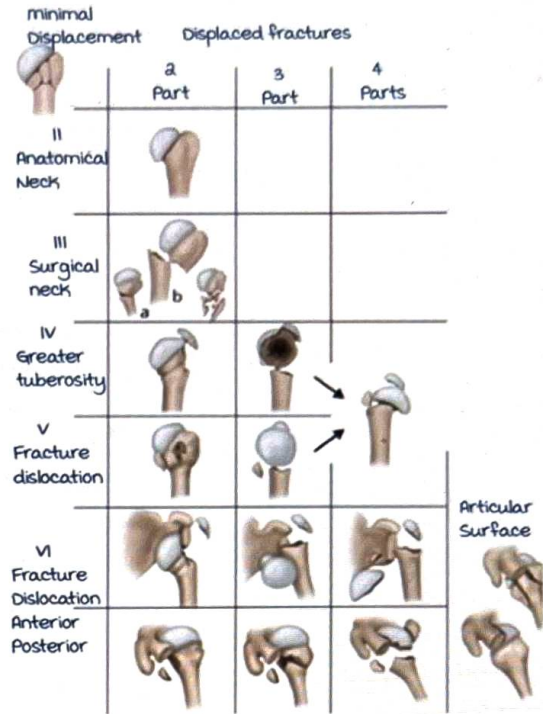
Active space

Neers classification :

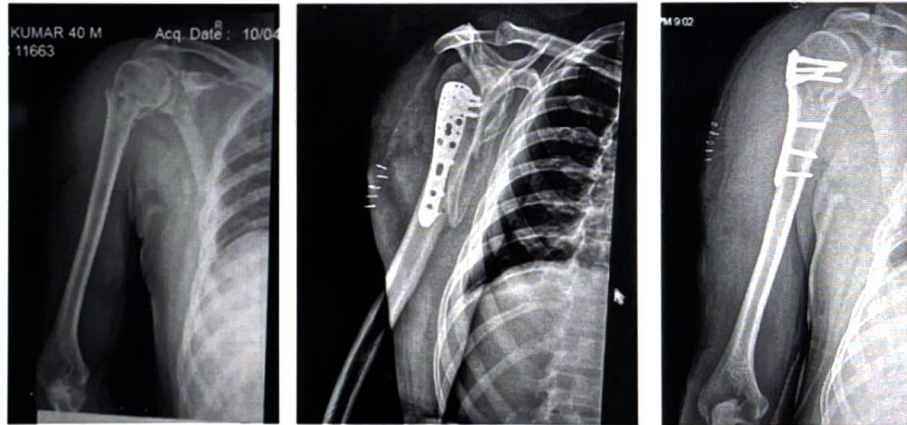
- I : undisplaced.
- II : 2 parts fracture.
- III : 3 parts fracture.
- IV : 4 parts fracture (worst prognosis).

- Parts :
1. Head of humerus.
 2. Greater tuberosity.
 3. Lesser tuberosity.
 4. Shaft of humerus.

Classification of proximal Humerus Fractures



Treatment : Open reduction and internal fixation.



Shaft of Humerus Fractures

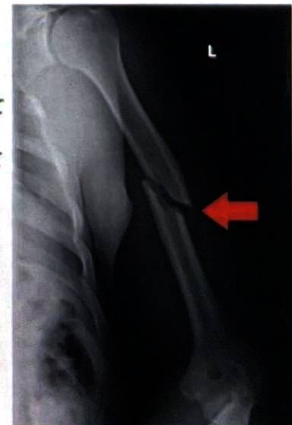00:04:05

Shaft of humerus : Part of the humerus distal to the surgical head of the humerus and proximal to supracondylar region.

600639e8e4e7e5ea7

Conservatively with u Slab or hanging cast (patient needs to be erect in hanging cast as weight of cast causes the reduction.. Not preferred).

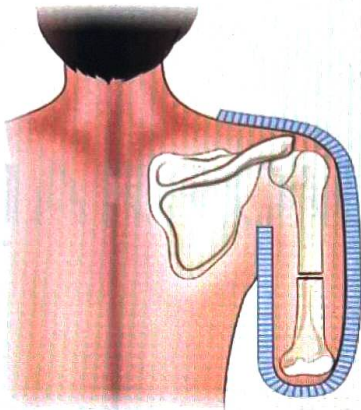
Surgical : Open reduction and internal fixation/ORIF with Plates.



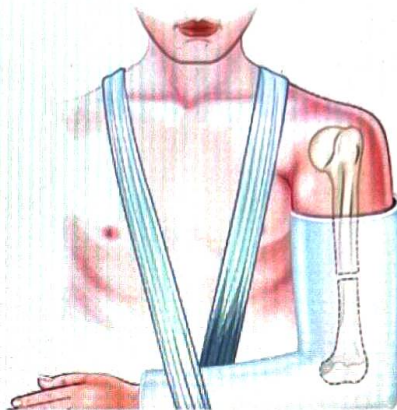
Active space

Complication : Radial Nerve Injury

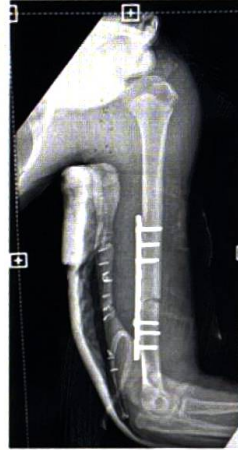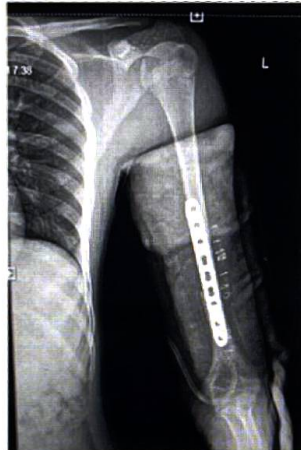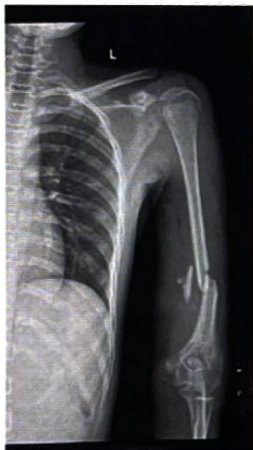As radial nerve runs in close proximity to shaft of humerus.



U slab



Hanging cast

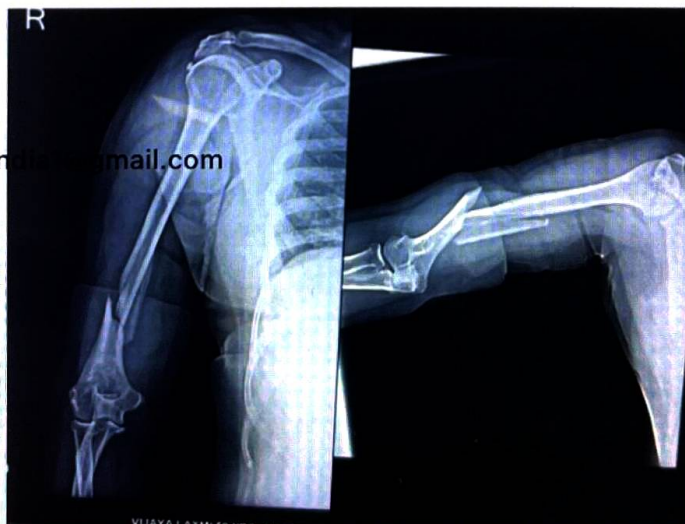

Open reduction & internal fixation of fracture shaft of shaft.

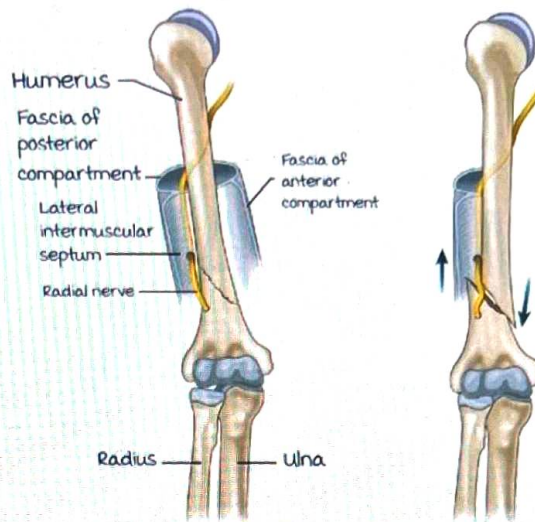
Holstein Lewis fracture :

Fracture of the distal third of the humerus resulting in entrapment of the radial nerve.

kumarankitin@gmail.com



Active space



Nerve is least mobile as it passes through lateral intermuscular septum in distal third of arm

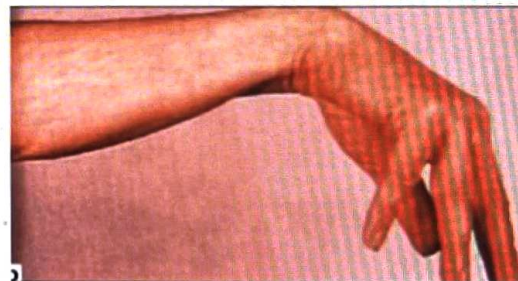
Oblique fracture is typically angulated laterally, and distal fragment is displaced proximally

mc cause of radial nerve injury : Holstein Lewis fracture.

60c6b3ee... 18 Dec 2016 04:17:54
 nerve gets crushed before ECRL.

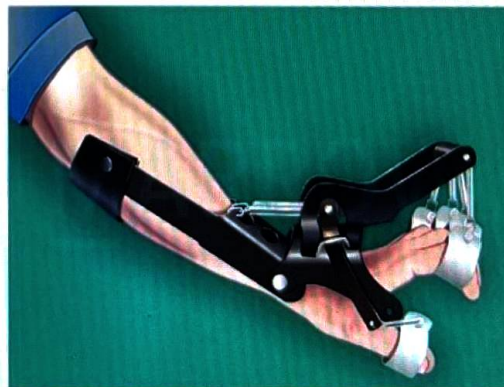most common type of injury is **neuropraxia**, which is physiological, reversible conduction block.
 Wrist drop, sensory loss, thumb drop, finger drop.

Treatment :
 Rx of # with no radial nerve palsy : Conservative
 Cock up splint
 Static cock-up splint
 Dynamic cock-up splint



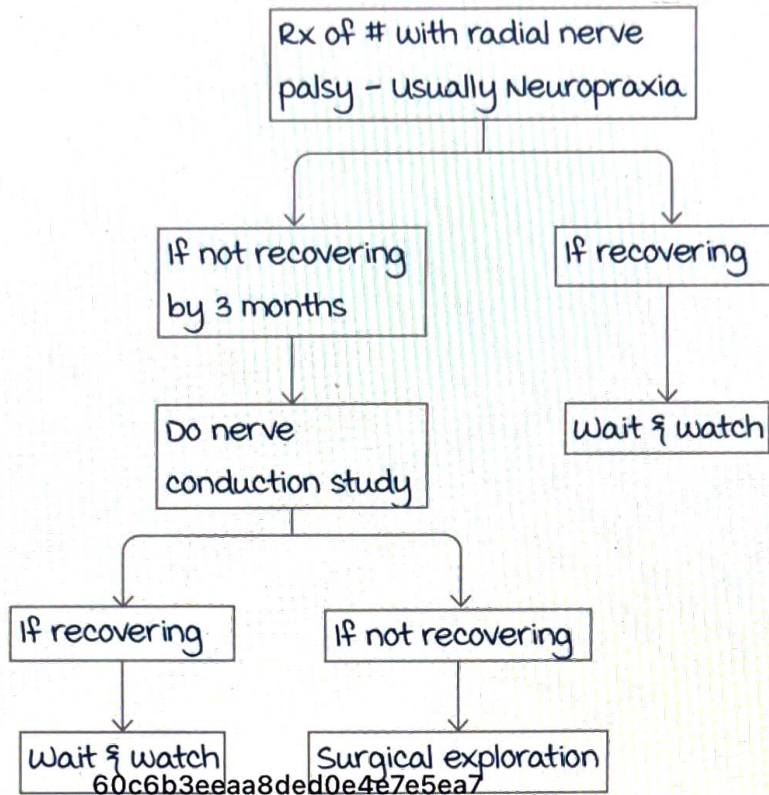
wrist drop

Neuropraxia : usually recovers fully in 3 months.



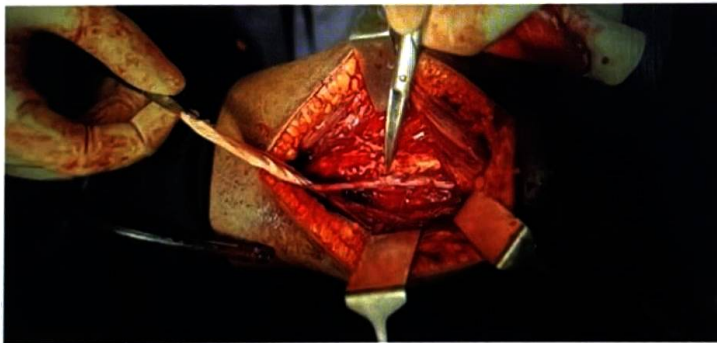
Cock up splint

Active space

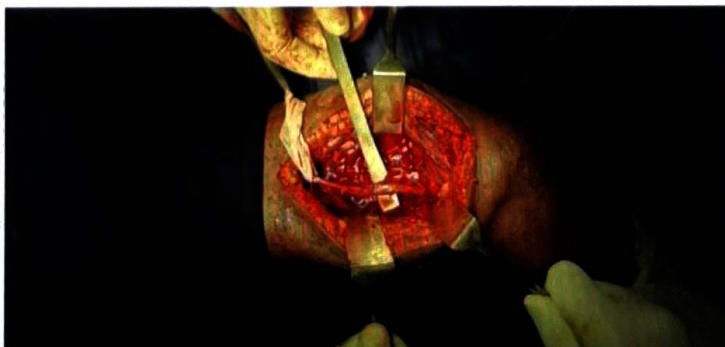


Rx of Open #: ORIF with exploration of nerve.

Case: A patient presented with shaft of humerus # with no recovery after 6 months.

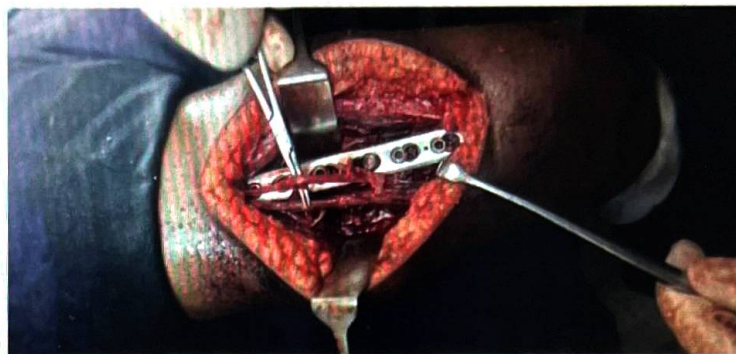


Posterior approach to humerus, a vertical incision is made. Radial nerve passes from medial side and goes laterally.

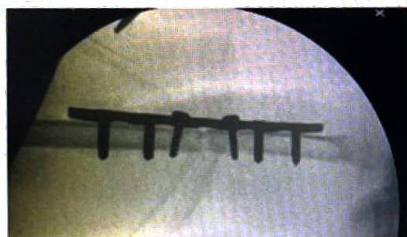


Active space

Radial nerve if tethered, is broken and freed from the callus.



After releasing the radial nerve, humerus is internally fixed by a plate : Open reduction & internal fixation



Algorithm of management :

Conservative management : Paster of Paris / POP.

If Conservative management failed : ORIF.

Explore & ORIF in :

Iatrogenic injury of nerve (while attempted reduction).

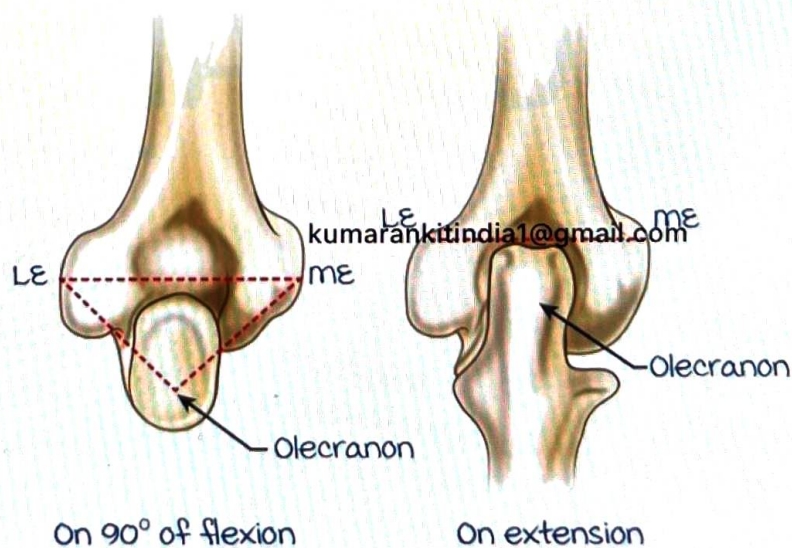
Open fracture with nerve injury

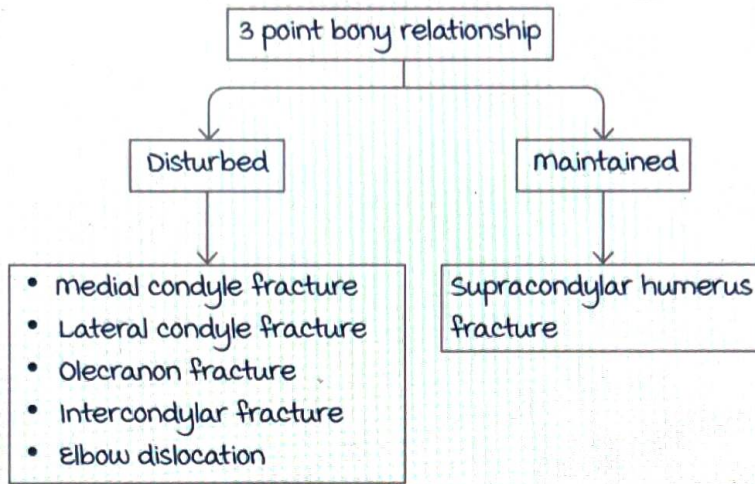
Nerve injury not recovering even after wait and watch period

Shaft of Humerus Fractures

00:17:33

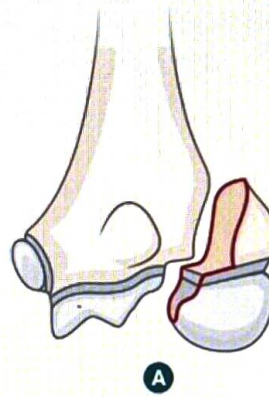
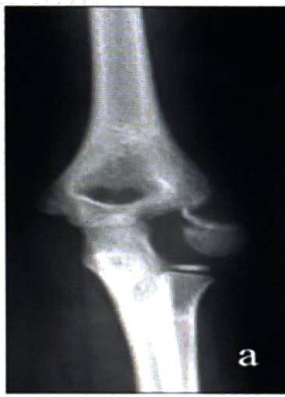3 bony point relations in elbow :





Lateral condylar humerus fractures

00:20:55



Fracture of a condyle above the radial head.

Salter Harris's type IV injury of physeal plate: Involves all 3 layers - metaphysis, physis and epiphysis.

Intra articular # / Fracture of necessity: Necessitates surgery, no role of conservative management.

3 Point bony relationship is disturbed.

Fractures of necessity:

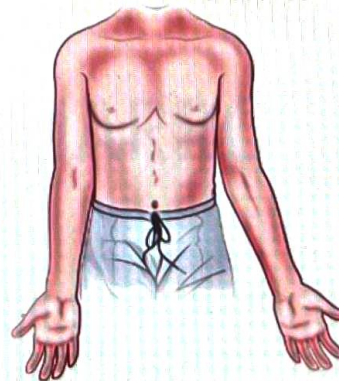
- Intra articular fracture
- Lateral condylar humerus
- Monteggia / Galeazzi
- Neck of femur

Complications:

Stiffness of elbow.

Non-union, due to:

- Pull of common extensor group of muscles.
- Intracapsular, hence washed by synovial fluid, which prevents healing.



Active space

- Has compromised vascularity.

Cubitus valgus : Due to more growth of medial condyle compared to lateral condyle. medial side gets stretched with time & beyond a point results in ulnar nerve palsy.

Non-Union → Cubitus valgus.

Deformity. → Tardy ulnar nerve palsy (behind the medial condyle in the cubital tunnel) occurs months to years later after the injury.

Tardy → Late/Lazy.

Carrying angle :

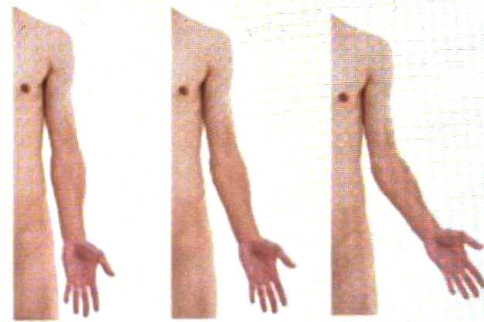
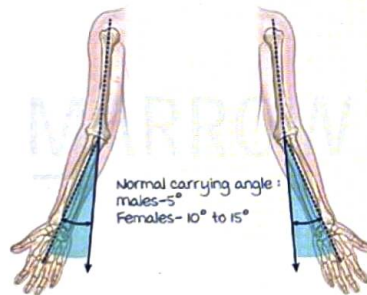
Normally on extension of elbows, arm and forearm are not in a straight line. It is in slight valgus :

males : 5°.

Females : 10 to 15°.

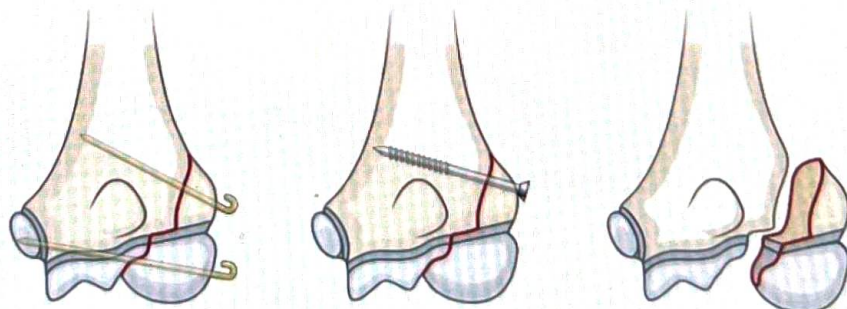
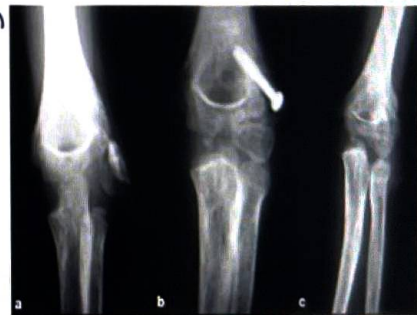60c6b3eaa8ded0e4e7e5ea7

Carrying angle



Cubitus varus Normal Valgus

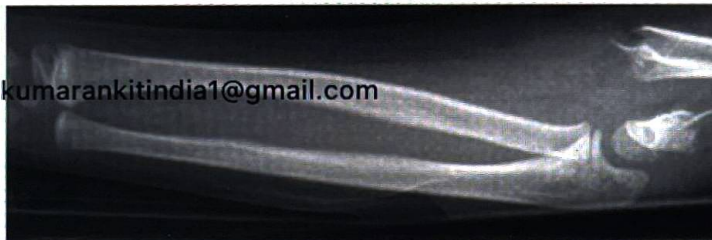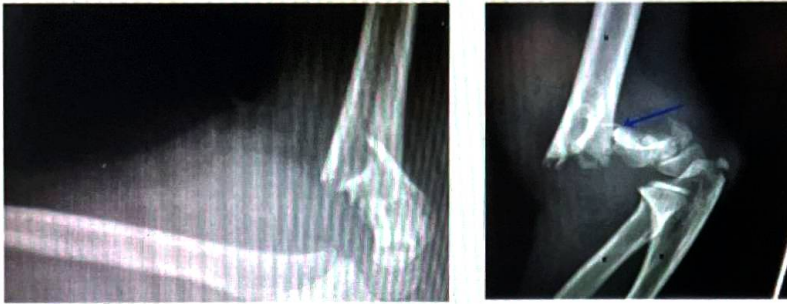
Treatment : ORIF/ Open reduction & internal fixation.



Active space

Supracondylar Humerus Fractures

00:29:38



MC fracture around the elbow in children.

MC fracture following a fall on outstretched hand (FOOSH) in a child.

MC mode of injury : FOOSH.

MC mechanism of injury : Hyper extension.

Reason :

Geometry of bone changes from triangular superiorly to a flat bone inferiorly.

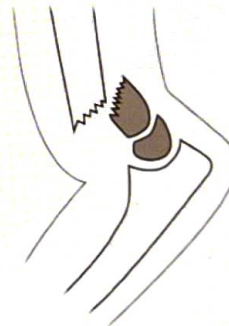
There are 2 fossae, olecranon & coronoid fossa at the distal end of humerus.

Fossae make the bone thin and weak.

Hence , high risk of fracture.

The fracture passes through the olecranon fossa

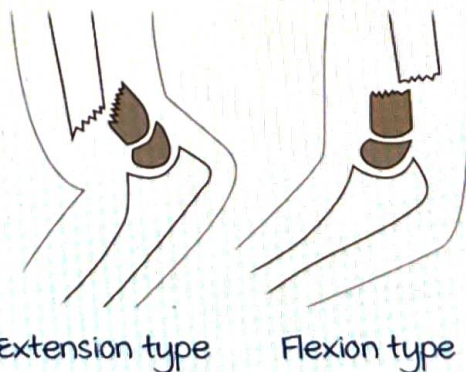
Salter Harris type I or type II #/extra-articular.



Types :

1. MC : Extension type / distal fragment goes posteriorly, due to pull of triceps.

- Postero-medial type
- Postero-lateral type.

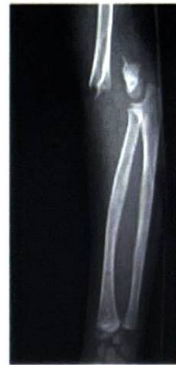
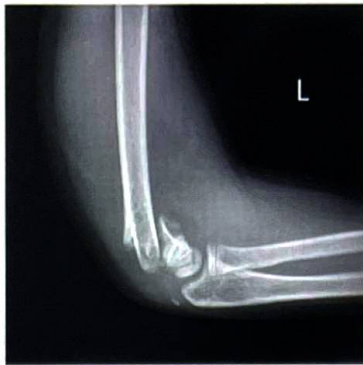
Extension type

Flexion type

2. Flexion type /distal fragment goes anteriorly.

Active space



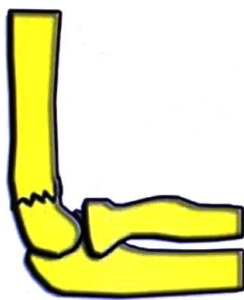
Flexion type

Extension type

Displacements :

- Proximal migration.
- medial tilt & medial shift (assessed by **Bauman's angle**)
- Internal rotation (visible on xray giving the **fish tail sign**)
- Posterior tilt & posterior shift.

Supra condylar Humerus # : **Gartland classification**
kumarankitindia1@gmail.com



Type I



Type II



Type III

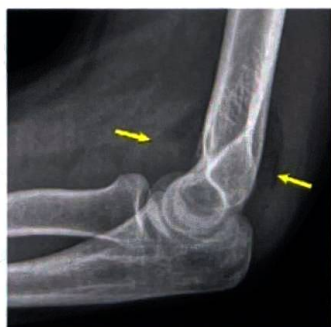Type I : Undisplaced fracture. Not visible on X-Ray.

Type 2 : Incomplete /partial fracture.

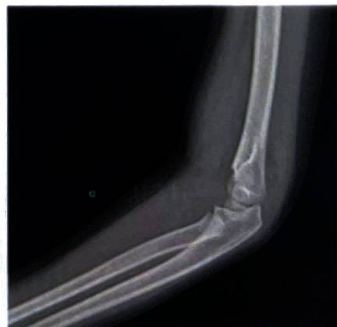Only anterior cortex is broken, posterior cortex is intact with it's periosteum.

Type 3 : Complete fracture/both anterior & posterior cortex is injured/broken.

Active space

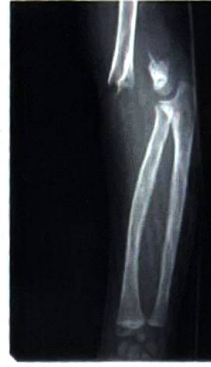

Type I : Fatpad sign



Type II

Type I diagnosed by indirect signs.
Fatpad sign : Fat pushed by the fracture haematoma appears as lucency around the bone
Or Sail sign.

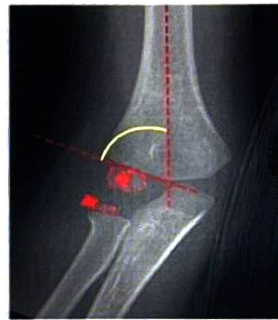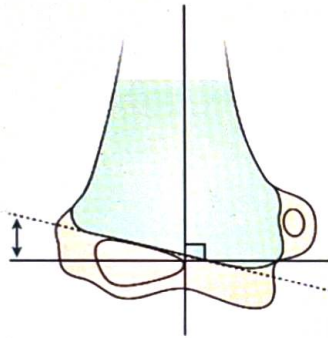


Type III

Baumann's angle (Helps in assessment of reduction)

Angle between :

A line parallel to the longitudinal axis of the humeral shaft.
And a line along the lateral condylar growth plate.



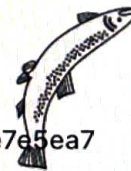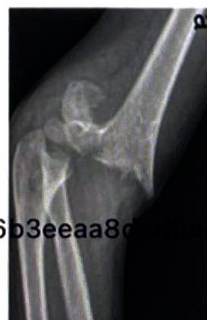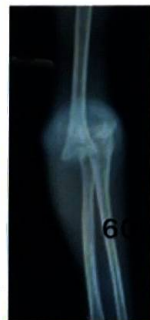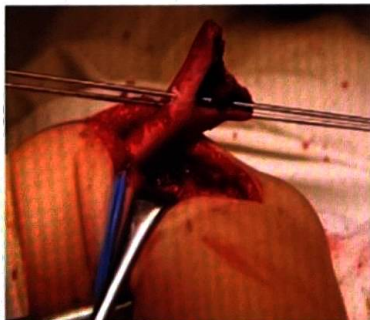used to assess the medial tilt.

Normal Baumann's angle falls between $\sim 70^\circ - 75^\circ$

As the Baumann's angle increases the carrying angle decreases, leading to cubitus varus.

Fish tail sign

Helps assess the internal rotation of the distal fragment



In supracondylar fracture, the distal fragment goes into internal rotation, hence distal humerus looks like a fish tail in AP view.

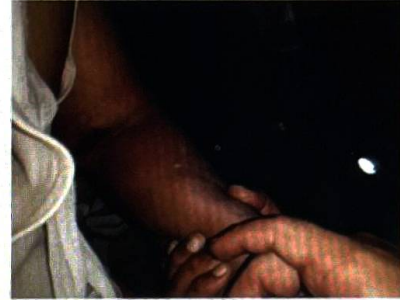Supracondylar humerus fracture - management :

MC fracture associated with :

- Vascular injury in child.
- Nerve injury in child.
- Compartment syndrome in child.
- Volkmann's ischaemic contracture in child.

Early complications :

- Brachial artery injury.
- Volkmann's ischemia.
- Compartment syndrome.
- Volkmann ischemic contracture.
- Nerve injury : Anterior Interosseous Nerve > median nerve
> Radial nerve.



Late complications :

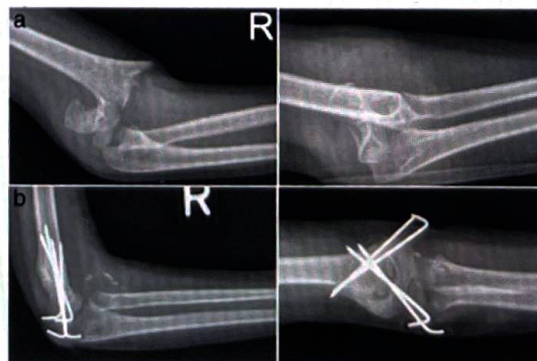- (MC) malunion : Cubitus Varus deformity / Gunstock deformity / Decrease in Carrying Angle
- myositis ossificans.

Treatment :

Type 1 is undisplaced fracture : POP.

Type 2 incomplete / partial fracture : Reduce + POP or
Reduce + K Wires.Type 3 complete fracture : Open Reduction
& Internal Fixation with K Wires.In compound / open fracture / comminuted fracture : Dunlop
Traction for temporary stabilization.

60c613ea87d0c1e75a2 of supracondylar humerus fracture.

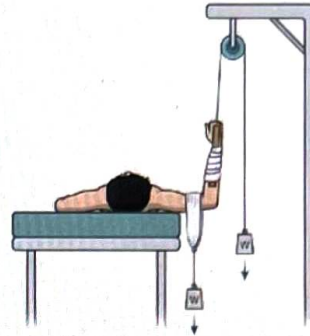


This is type III fracture showing reduction and fixation with K wire.

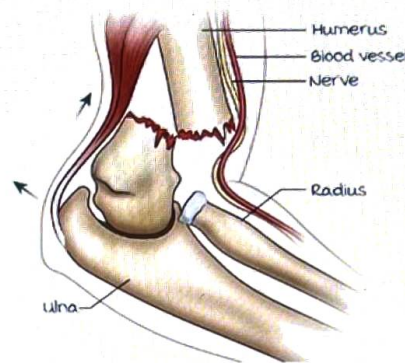
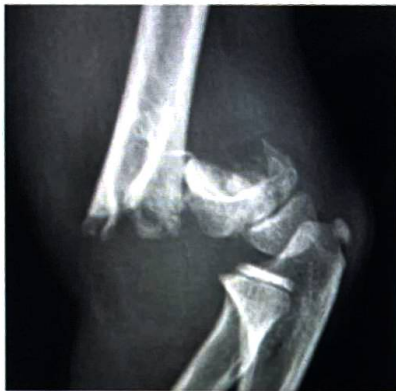MC injured vessel : Brachial artery

MC injured nerve : AIN / Anterior interosseous nerve > median.

Injury of these structures occur due to proximal fragment.



Dunlop traction



Compartment syndrome

00:49:30

kumarankitindia1@gmail.com

As a complication of supracondylar humerus fracture.

The proximal fragment injures the brachial artery.

Distal blood flow is compromised → Flexor group of muscles are affected first.

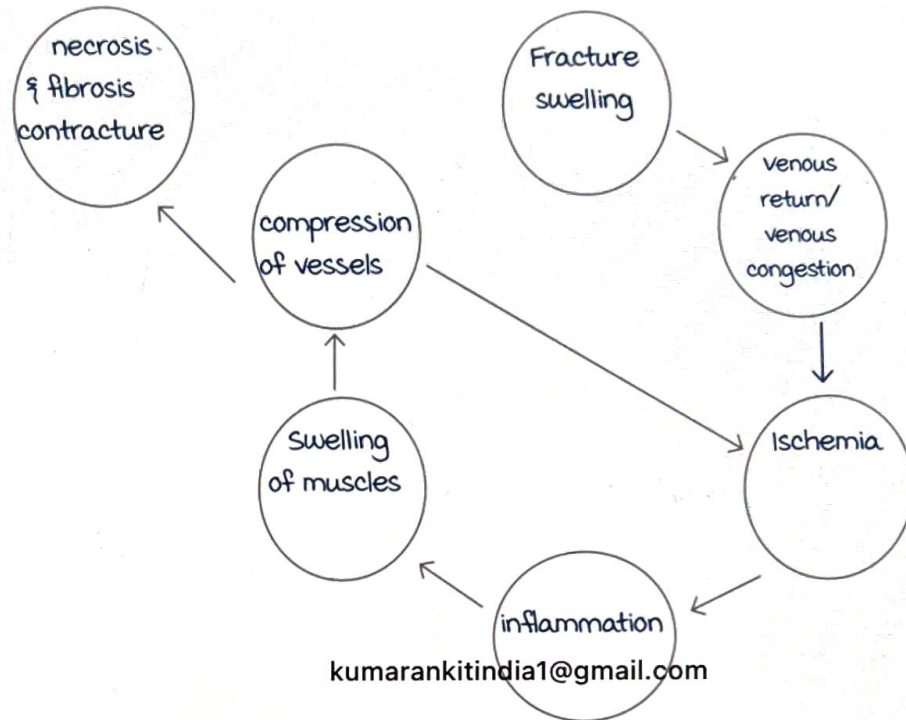
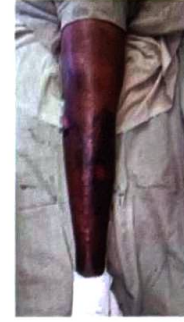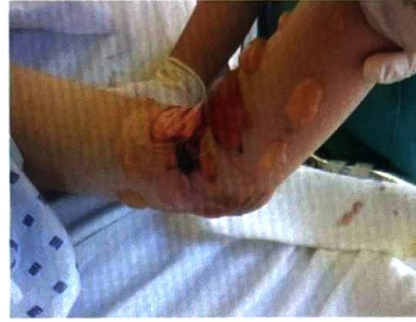The largest muscle of the flexor group : Flexor digitorum profundus has high metabolic requirement.

Hence it is the earliest muscle to be affected in ischemia.

Fracture swelling leads to decreased venous return/venous congestion

Ischemia of muscles (FDP) → Inflammation → Swelling of muscle inside the fascial compartment → Compression of capillaries providing blood to the muscles, this leads to vicious cycle of further ischemia and compression of vessels.

This leads to muscle necrosis → Fibrosis → Contracture of muscles.



Clinical features :

- Pain on passive stretch - most important criteria for Dx
- Puffiness/swelling.
- Pallor.
- Paraesthesia.
- Paralysis.
- Pulselessness (very late in the disease process, hence least important criteria).

If patient is unconscious, use manometer to measure the pressure inside compartment.

Normally < 10 mm Hg

> 30 mm Hg → Compartment syndrome.

Treatment is Fasciotomy.

Upon fasciotomy, the fascia is cut open, muscles will bulge out, intracompartmental pressure falls down and vascularity is resumed.

Case scenario :

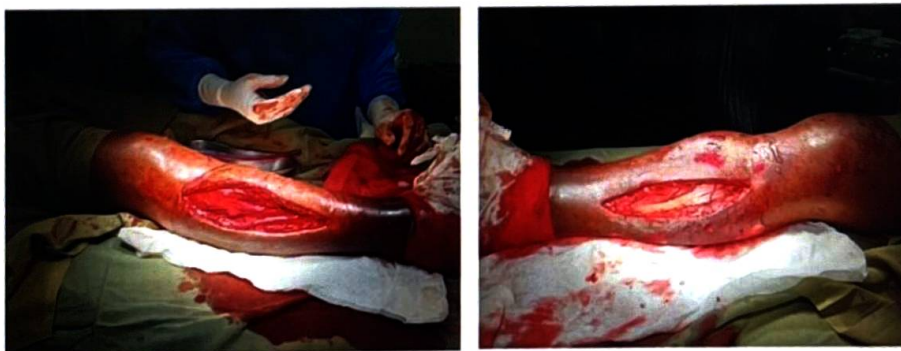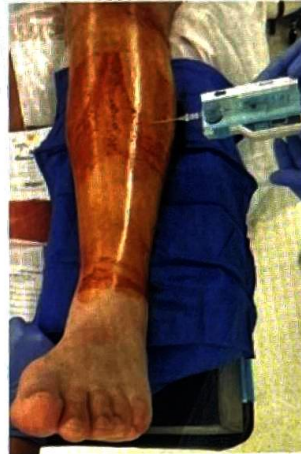Patient with tense swelling in right lower limb, following proximal tibial fracture which was neglected, presented with tense swelling in the leg, and pain on passive stretch. Patient also shows blisters which are perforated over skin of leg (due to superficial skin being necrosed by compartment pressure).

This is a case of acute compartment syndrome of lower limb.

It is treated by decompression of all 4 compartments : Anterior, lateral, posterior superficial and posterior deep compartments.

A long medial longitudinal incision is made to reach the posterior superficial and deep compartments.

To access the lateral and anterior part of the leg, incision is made over the lateral part of the leg. Skin, superficial fascia and deep fascia are incised.




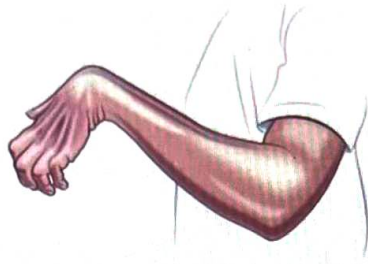
Low blood pressure following a trauma :

Differential pressure/ ΔP : Difference between diastolic pressure and compartment pressure.

If absolute pressure $> 30\text{mmHg}$ or $\Delta P < 30\text{mmHg}$ diagnosis of compartment syndrome.

Volkman's ischemic contracture :

- Ischemia.
- Fibrosis of forearm muscle.
- Flexion contracture of wrist & fingers.
- Sensory loss & motor paralysis in the forearm & hand.



Turn buckle splint

Treatment :

mild contracture : Passive stretching using a turn buckle splint (Volkman's splint)

moderate contracture : muscle sliding (max page) operation

Severe contracture : Bone shortening

MC cause of compartment syndrome overall : # Tibial diaphysis.

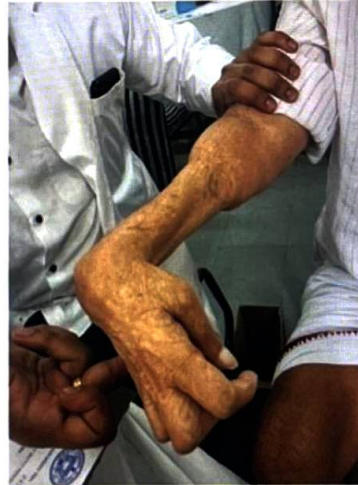MC cause of compartment syndrome in children : SCH #

MC cause of Volkmann ischemia in children : SCH #

Other causes : Burns.

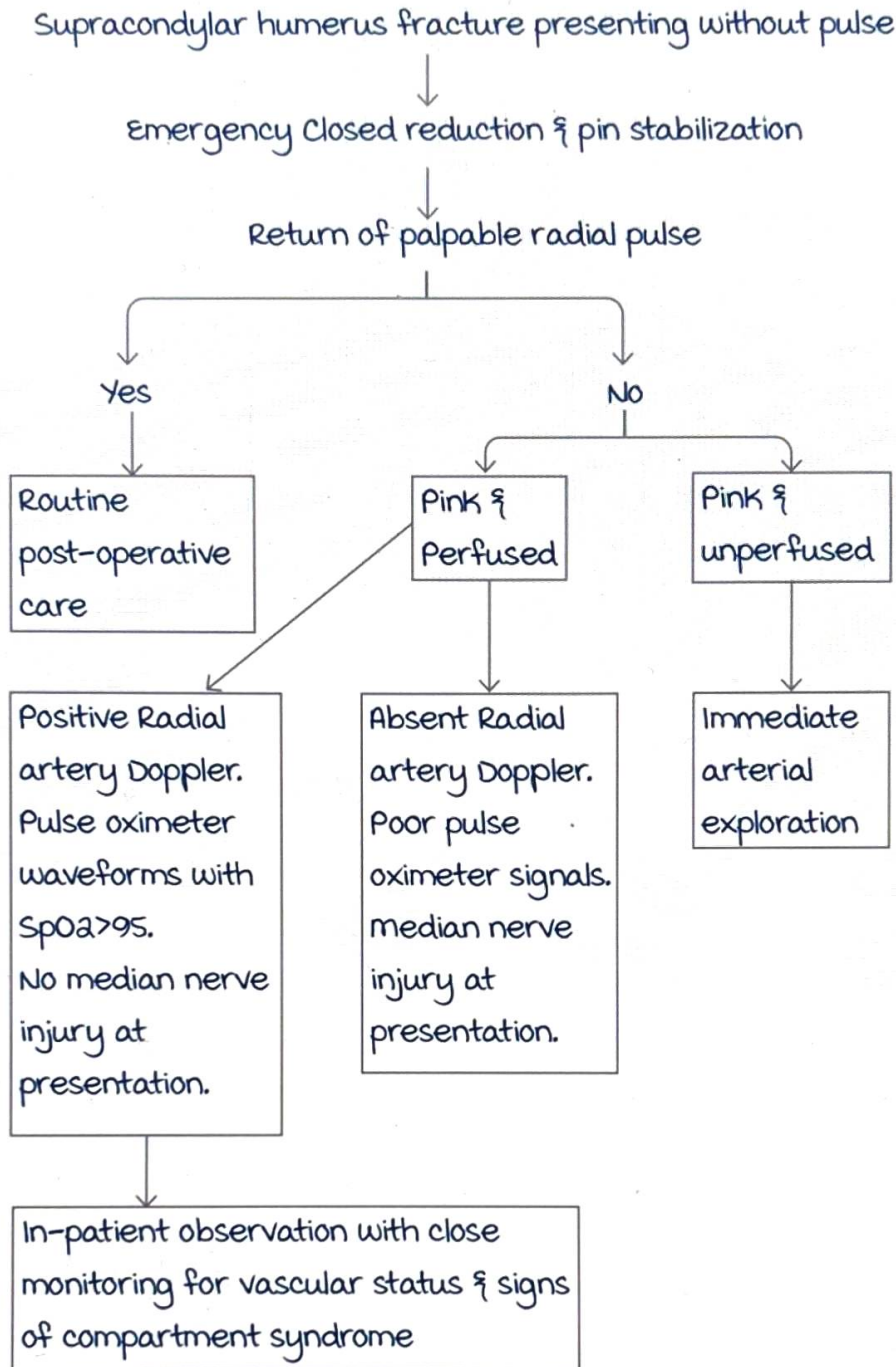
Soft tissue injury.

Tight pop.



Pink pulseless hand

- A pink pulseless limb is one that remains pink and well perfused without a palpable pulse following SCH # or after closed reduction.
- Because of anastomosis around the elbow the vascularity is not critically compromised. kumarankitindia1@gmail.com
- Temporary kinking of vessel.
- Will be relieved if fracture reduced and stabilized.

Supracondylar Humerus Fracture management 01:07:30**Malunion/Cubitus varus deformity**

01:07:30

MC complication of SCH #

Due to medial tilt & internal rotation displacement.

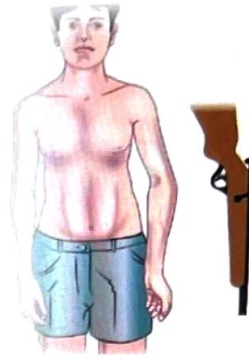
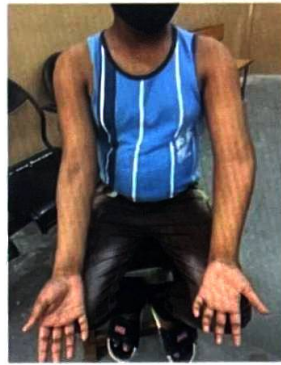Gunstock deformity

Elbow function: Normal (since extra articular #)

Rx: **modified French osteotomy** (bilateral to single wedge osteotomy).

Carrying angle: **decreased**

Bowman's angle: **increased**

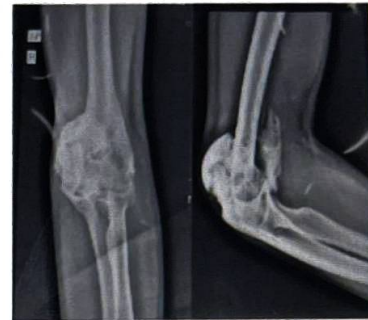

Malunion/Cubitus varus deformity

01:10:33

Due to massage of fracture.

- MC muscle involved : Brachialis
- MC joint involved : Elbow > Hip
- Restriction of elbow movement or
range of movement :
Decreases.



massage causes dislodgement of fracture hematoma which lands in a muscle. It starts the process of healing : Hematoma
→ Inflammation → Callus formation → Consolidation.
This leads to bone formation inside a muscle is known as myositis ossificans.

Treatment :

- Active phase : Only NSAIDS (indomethacin)
- Latent phase : Active physiotherapy (Not Passive)
- If elbow movements not restored : Excise the mas
surgically.

Pain on passive stretch : Compartment syndrome.

History of massage : myositis ossificans.

Femur # + difficulty in breathing : Fat embolism.

Fractures distal to SCH

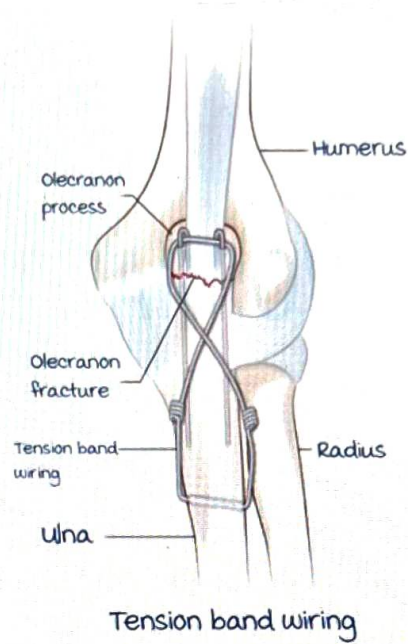
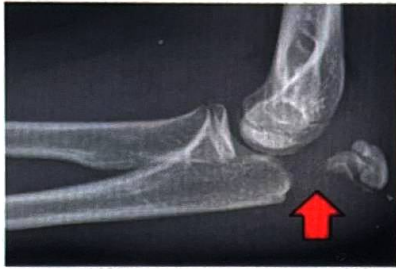01:13:03

Fracture olecranon of ulna :

Triceps attached to the olecranon process of ulna causes distraction of fracture fragment and prevents it from healing.

Treatment by : Open reduction and internal reduction by

Tension band wiring fixation.

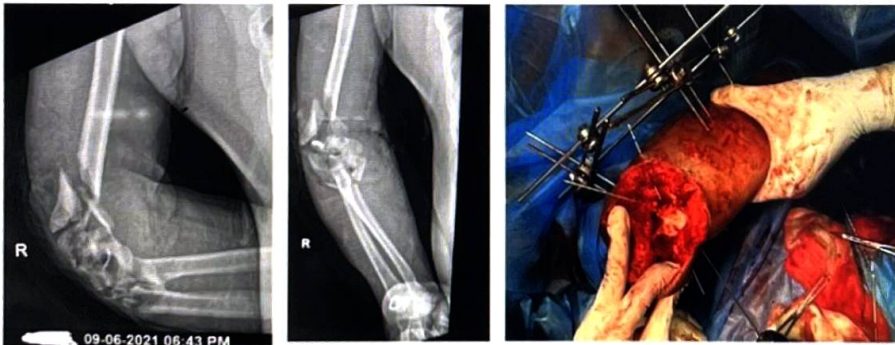


Side swipe injury/baby car injury :

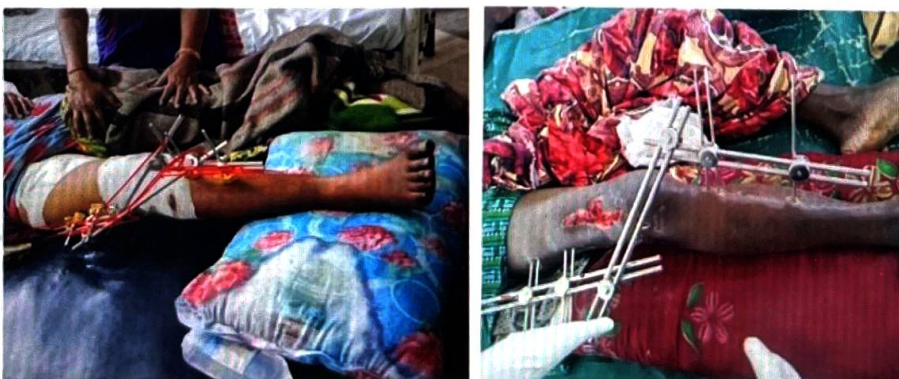usually caused in children sitting in a car with elbow placed outside the window and gets hit by another vehicle passing by the side.

Results in periarticular fractures i.e :

- Fracture of Distal humerus.
- Fracture of Proximal Radius & Ulna.



Elbow spanning external fixator
Knee spanning external fixator :



Joint spanning external fixators used in periarticular fractures

Elbow dislocation

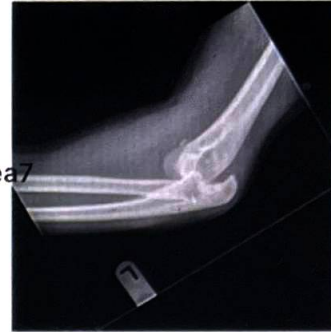01:15:19

MC dislocation in children.

ulno-humeral joint is dislocated.

MC type is posterior/posterolateral dislocation.

Attitude following dislocation : **Flexion at elbow.**



3 bony point relation in elbow :

Reversed.

Clinically bowstring sign - triceps become prominent like bowstring.

MC nerve injured : **Ulnar nerve.**

X-ray : Coronoid process behind the humerus.

Terrible Triad of elbow (Hotchkiss)

1. Posterior elbow dislocation
2. Coronoid #
3. Radial head #

Pulled elbow :

In children below 3 to 5 years of age, radial head is not completely ossified.

Radial head is located within the annular ligament.

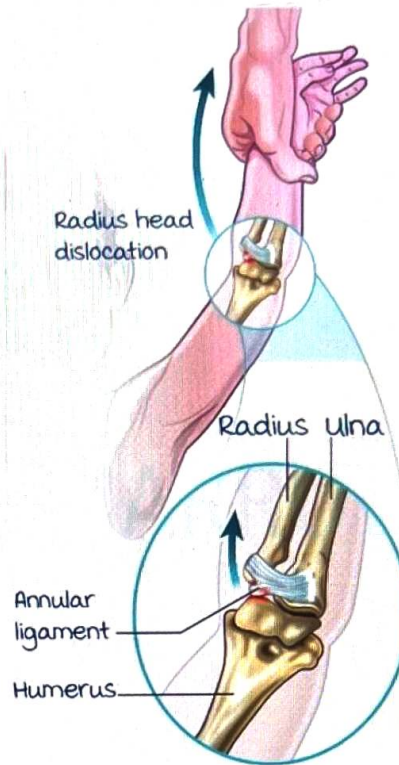
Radial head in children below 3 to 5 years is smaller compared to annular ligament (hence unstable).

On applying axial traction on extended and pronated hand, distal subluxation of radial head out of annular ligament occurs.

Commonly seen in children when their parents or baby sitters lifts them.



Ossification center	Age
Capitellum	1
Radial head	3
Internal epicondyle (medial)	5
Trochlea	7
Olecranon	9
External epicondyle (lateral)	11



60c6b3eaa8ded0e4e7e5ea7

Mnemonic for ossification centers: CRITOE

Attitude elbow can be flexed/extended with pronation.

Classical presentation: Child playing with his father, suddenly starts crying, pulls away the elbow and does not allow anyone to touch it.

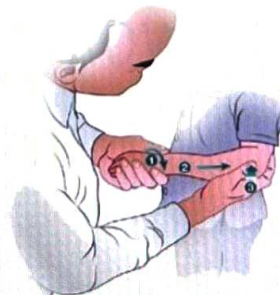
Reduction: usually self-limiting subluxation.

Flex the elbow & supinate.

3 point bony relation remains the same.



mechanism



Reduction

Active space

UPPER LIMB TRAUMA : FOREARM, WRIST AND HAND

Forearm

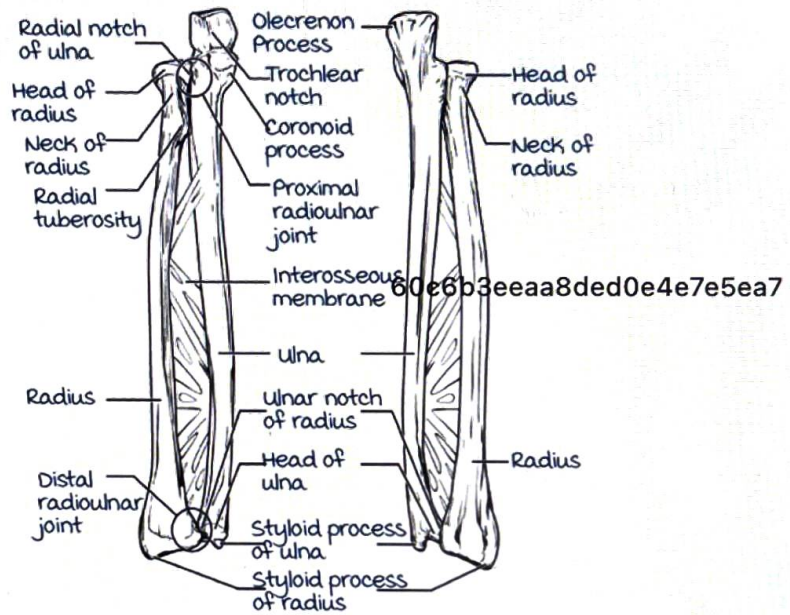
00:00:16

Bones → Radius and ulna.

Radius rotates over ulna and helps in supination and pronation.

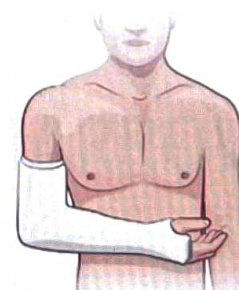
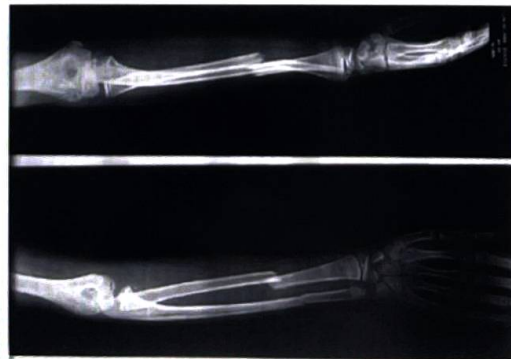
Joints → Proximal and distal radioulnar joints.

Radius and ulna are connected to each other by **interosseous membrane**.



Forearm fractures :

Both bone forearm fracture (shaft of radius & ulna)



POP position in forearm fractures

management → Closed reduction and POP application
OR open reduction internal fixation (ORIF)

Active space

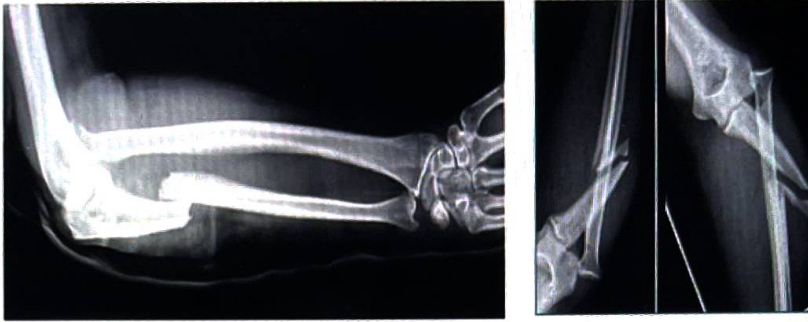
POP position in forearm fractures :

- upper 1/3rd fracture : Supination (supinator) .
- middle 1/3rd fracture : mid Prone.
- Distal 1/3rd fracture : Pronation (pronator quadratus).

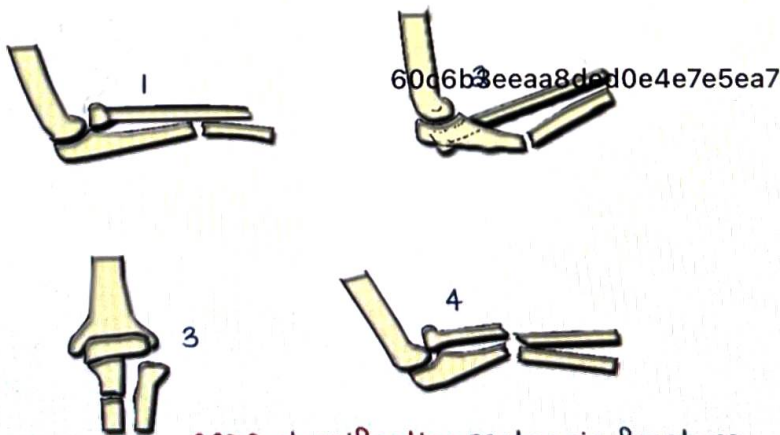
Monteggia fracture

00:03:04

upper 1/3rd ulna diaphysis with radial head dislocation



Type	Radial head dislocation	Fracture
Type 1 : 60%	Anteriorly	Fracture ulna diaphysis with anterior angulation.
Type 2 : 15%	Posterior/ Posterolateral	Fracture ulna diaphysis with posterior angulation.
Type 3 : 20%	Lateral/Anterolateral	Fracture ulna metaphysis.
Type 4 : 5%	Anterior	Fracture proximal third ulna and radius.



BADO classification Monteggia fracture

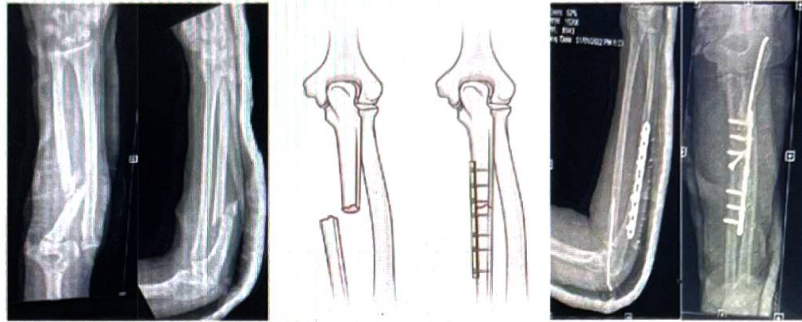
management :

ORIF with plates (ulna, radial head usually falls into place)

Cannot be managed conservatively (fracture of necessity)

MC nerve injured → Posterior interosseous nerve (Finger drop)

ξ thumb drop without any sensory deficit
 MC nerve injured in shoulder dislocation → Axillary nerve.
 MC nerve injured in supracondylar humerus fracture →
 Anterior interosseous nerve > median nerve



Monteggia fracture fixation

kumarankitindia1@gmail.com

Galleazzi/Pied mont/Reverse Monteggia fracture 00:06:34

“Dislocation or subluxation of the distal radio-ulnar joint (DRUJ) in association with a fracture of the radius at the junction of the middle and distal third”

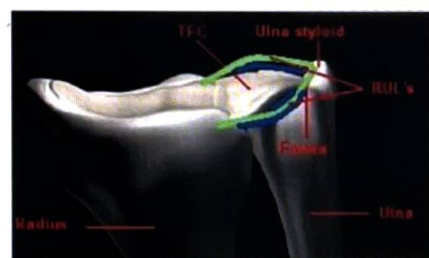
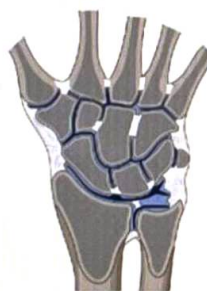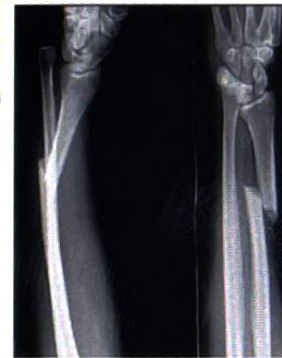If DRUJ is disrupted :

Dorsal migration of ulna → Piano Key sign.

Triangular Fibrocartilage Complex (TFCC)

can get injured

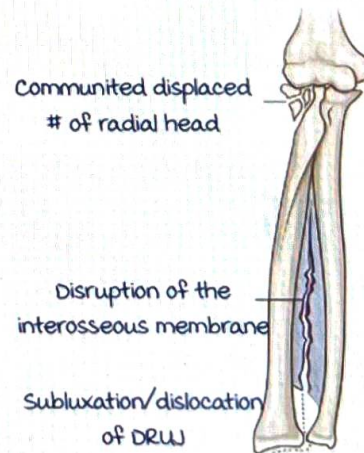
Rx → ORIF with plates (Radius)



Essex-Lopresti fracture :

Axial loading of the forearm bones following fall on an outstretched hand leads to

- Radial head fracture.
- DRUJ gets disrupted.
- Forearm bones lose their alignment leading to a tear in the interosseous membrane.



Active space

Rx → Radial head excision in adults but not in children as it causes growth disturbances (limb-length discrepancies)

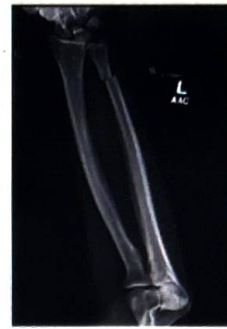Night stick fracture :

minimally displaced oblique fracture of ulna without associated fracture of the radius

Self defense injury.

mode of injury → Direct trauma to forearm while in a defensive stance.

Rx → Closed reduction for apposition of ends with plates



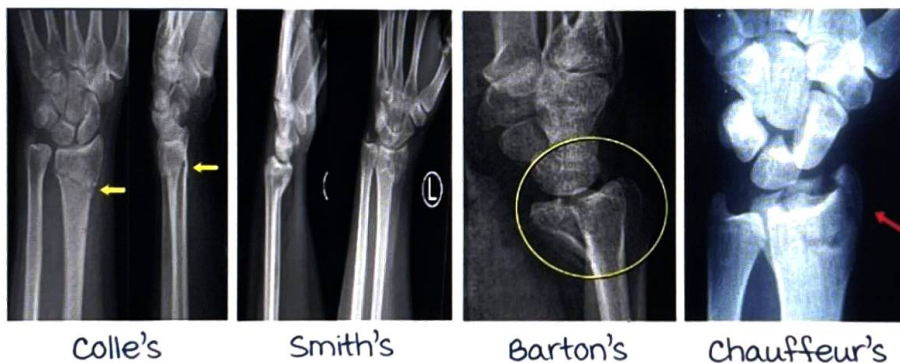Night stick fracture

Distal end of radius fractures/Metaphyseal

00:11:35

Described by Abraham Colle's

- Colle's fracture.
- Smith's fracture.
- Barton's fracture.
- Chauffeur's fracture.



Colle's

Smith's

Barton's

Chauffeur's

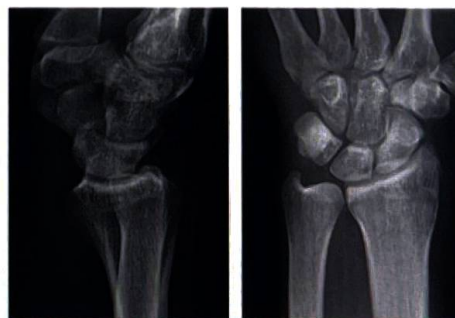
Anatomy of distal end of radius :

Distal end of radius faces towards

- Palmar/volar side (lateral view).
- Ulnar side (AP view).

Distal end of radius fracture

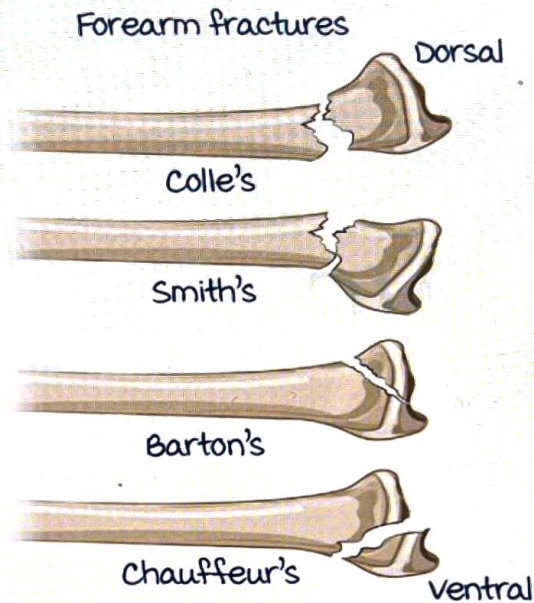
→ Identify if the fracture is extra-articular or intra-articular.



If extra-articular fracture → Look for the position of distal fragment (dorsal/ventral)

Intra-articular fracture → Barton's.

Name	Fracture	Distal fragment displacement
Colle's	Extra-articular	Dorsally
Smith's	Extra-articular	Ventrally
Barton's	Intra-articular	Dorsal / ventral + Carpal Subluxation
Chauffeur's	Intra-articular	Isolated Radial Styloid



Colle's fracture

00:15:35

Fracture distal end of radius at cortico-cancellous junction
Extra-articular fracture.

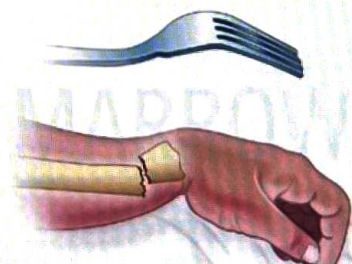
Common in elderly post-menopausal women.

MOI → Fall on outstretched hand, wrist in extension

(Smith fracture → wrist in flexion)

Displacement of distal fragment :

- Dorsal tilt/shift.
- Lateral tilt/shift.
- Impaction (most important).
- Supination.



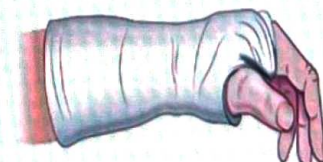
Dinner fork deformity

Treatment :

1. **Colle's cast** → Below elbow cast, position :

- Pronation
- Ulnar deviation
- Palmar flexion of wrist

AKA **Hand shaking cast.**

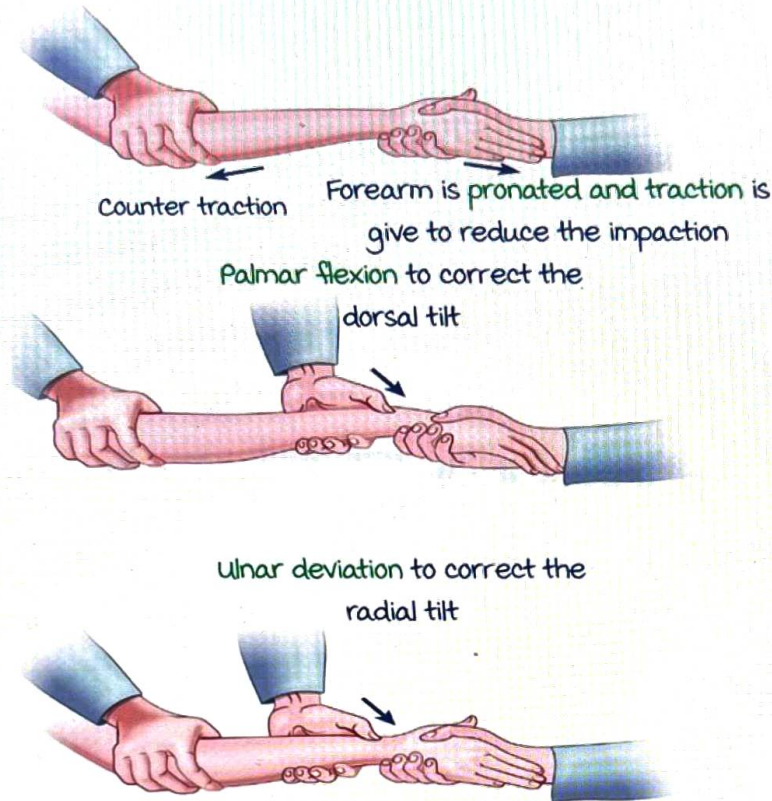


Colle's/Hand shaking cast

Active space

2. Closed reduction-internal fixation (CRIF) with K-wires
3. ORIF with plates

Technique of reduction of Colle's fracture :



POP application → Cast is always applied below the elbow to prevent stiffness at the elbow.

Complications of Colle's fracture :

- 1st MC → stiffness of fingers
- 2nd MC → malunion leading to dinner fork deformity.
- Complex regional pain syndrome / Sudeck's dystrophy → Sympathetic overactivity around the wrist.
- Rupture of extensor pollicis longus tendon.
- Carpal tunnel syndrome causing median nerve compression.
- Nonunion is extremely rare.

Reverse Colle's/Smith's fracture

00:24:11

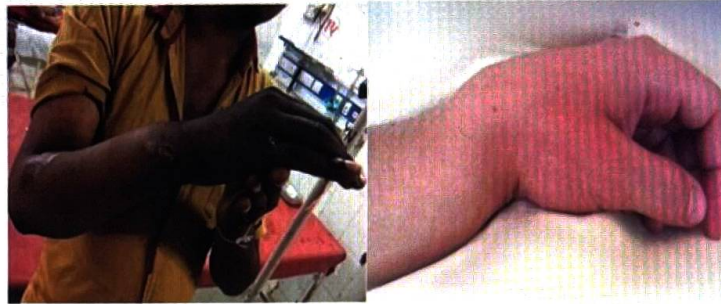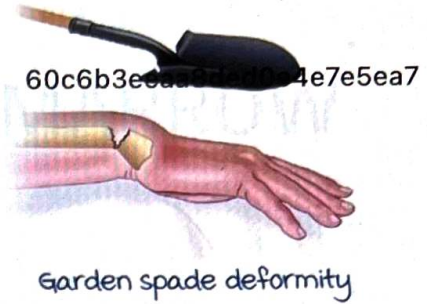
Extra articular.

Distal end of radius → Volar displacement.

MOI → Fall on outstretched hand with wrist in flexion.


Garden spade deformity

Rx → POP or ORIF with plates.




Garden spade deformity Vs Dinner fork deformity

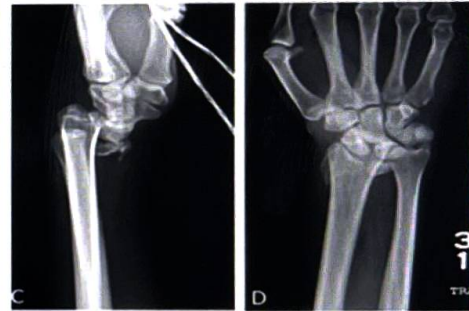
Barton's fracture :



Dorsal Barton's fracture



volar Barton's fracture



volar Barton's fracture

Distal end of the radius is the only bone which articulates with the carpal bones.

There is a lip/rim around the distal end of the radius which gives its concavity.

In Barton's fracture, there is disruption of this rim leading to subluxation of the carpal bones dorsally/ventrally.

Fracture distal end of radius with intra articular extension with carpal subluxation.

Rx → ORIF.

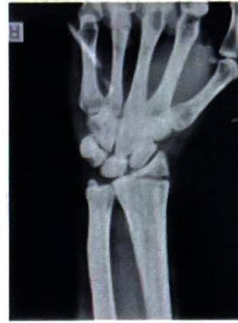Chauffer's fracture :

Fracture distal end of radius with isolated radial fracture.



Active space

Chauffer → French word for drivers
AKA Hutchinson's/backfire fracture →
This fracture gets that name because it
was MC in Chauffer's who used to get
accidental injury of the radiostyloid joint
by the handle which was used to start
the engine.



Chauffer's fracture

Carpal bones

00:27:45

mnemonic → She Looks Too Pretty Try To Catch Her.

Scaphoid, Lunate, Triquetrum, Pisiform,
Trapezium, Trapezoid, Capitate, Hamate
Largest Bone → Capitate.

Smallest → Pisiform.

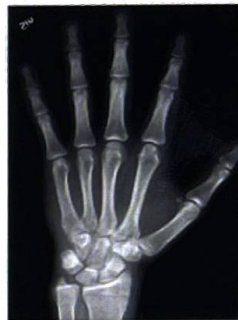MC fractured → Scaphoid.

MC dislocated → Lunate.

MC nerve injured in Lunate dislocation →
median nerve.

1st to ossify → Capitate (around 2 months).

Last to ossify →: Pisiform (around 12-13 years).



Fracture scaphoid :

Scaphoid is divided into 3 parts :

- Distal pole/ tubercle.
- Waist (MC fracture).
- Proximal pole.

MC carpal bone fractured → Scaphoid

MOI → Fall on outstretched hand.

MC in adolescents/young adults

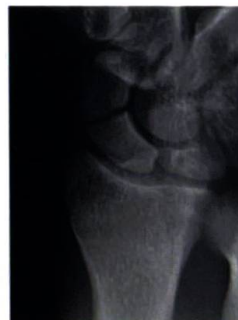Clinically :

Pain/tenderness/fullness in **anatomical snuff box**

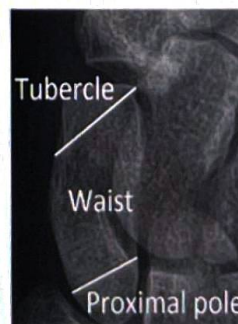X-ray :

AP/Lateral/Oblique wrist view (best)

MRI : If fracture is not visualized on X-ray
(up to 2 to 3 weeks)



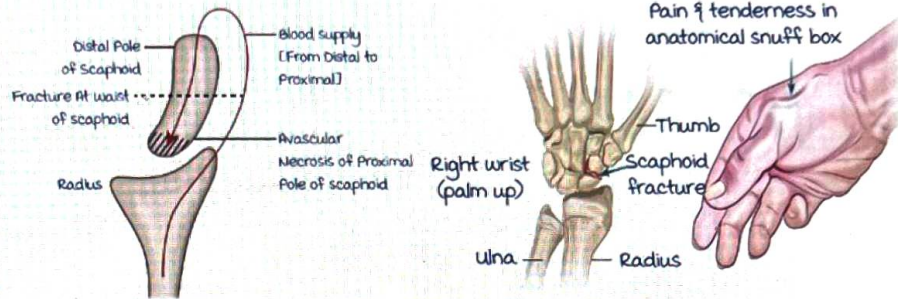
Fracture scaphoid



vascularity of Scaphoid → Distal to proximal.

Fracture at waist of scaphoid → Proximal pole undergoes Avascular necrosis (AVN).

Non-union of the scaphoid fracture is a complication.



It is managed conservatively with a scaphoid cast, even if the fracture is not visible on X ray, just based on the clinical history and findings so as to prevent the complications of it.

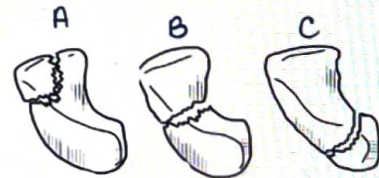
Types of Scaphoid fracture :

- A. Fracture of distal 1/3rd (mc in children)
- B. Fracture of waist of scaphoid (mc site of fracture)
- C. Fracture of proximal 1/3rd → Highest chance of non-union & AVN because it is farthest away from the blood supply.

mc complication of waist of

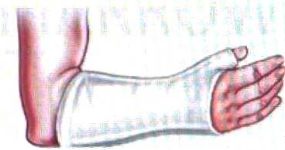
scaphoid fracture →

Non-union > AVN (mc : Proximal pole)

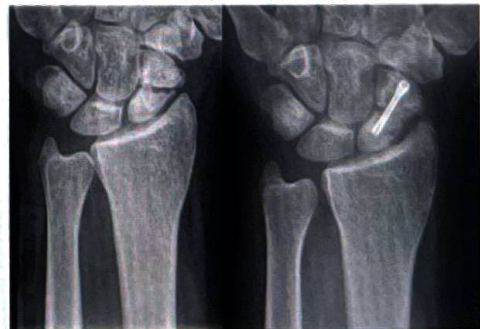


Treatment :

- Undisplaced fracture **Glass holding cast** → Dorsiflexion and radial deviation of wrist.
- Displaced fracture → ORIF with **Herbert screw** (Headless screw with differential threading)



Scaphoid cast (glass holding cast)



Herbert screw



Active space

Anatomy :

Distal end of radius articulates with scaphoid and lunate bones.

Distal end of ulna does not articulate with any carpal bones

Radius, Lunate and Capitate usually are in one alignment.

Scaphoid-lunate dissociation

00:36:30

Scapho-Lunate ligament →

Injury leads to increased gap between scaphoid & lunate.

This is known as scapho lunate dissociation.

Normal gap → < 2 mm.

Gap is > 3-4 mm.

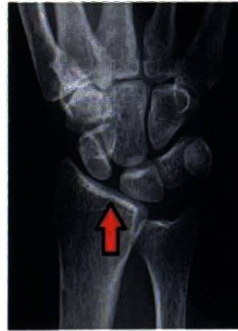This finding is indicative of carpal instability.

Described as **Terry Thomas Sign**.

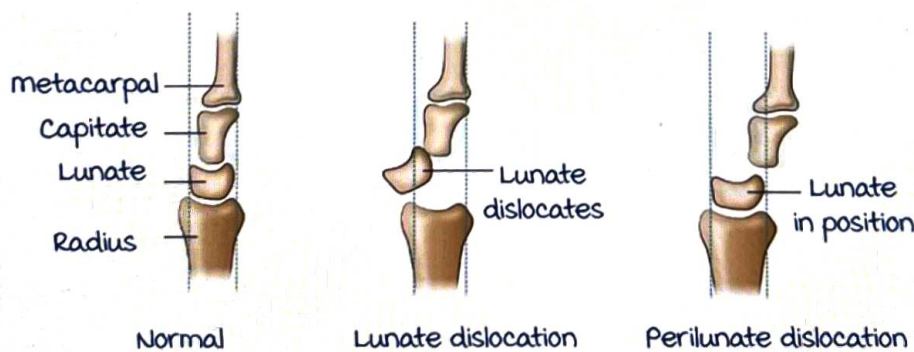
It leads to carpal dislocation if left untreated

Types of carpal dislocation :

- Lunate dislocation.
- Perilunate dislocation (mc).



kumarankitindia1@gmail.com



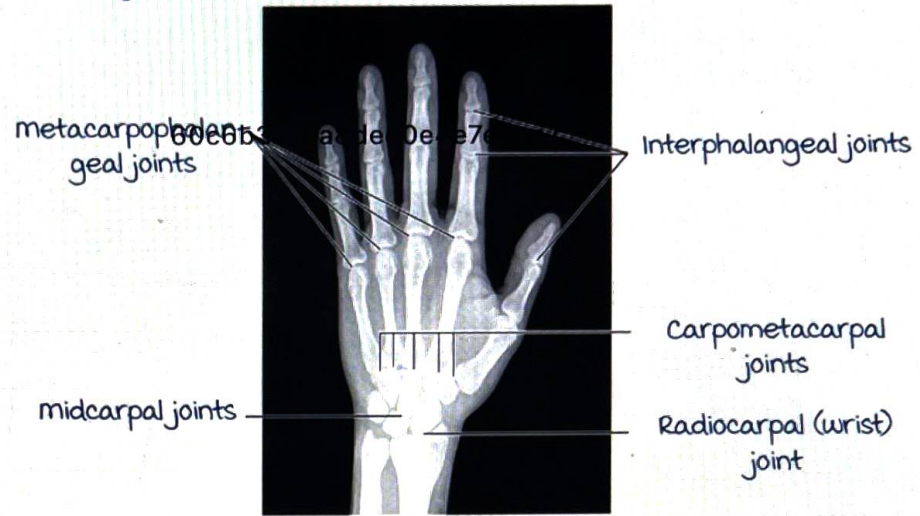
Lunate	Perilunate (mc)
Isolated lunate dislocation	Radius & lunate in alignment
Capitate & Radius in alignment	Carpal bones dislocated dorsally/ventrally
Spilled coffee cup sign	Tavenmier's maneuver used for reduction

Active space

Fractures in the hand

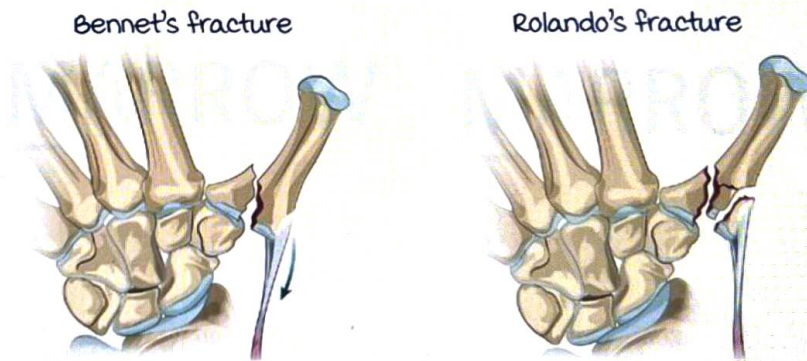
00:39:19

Anatomy :



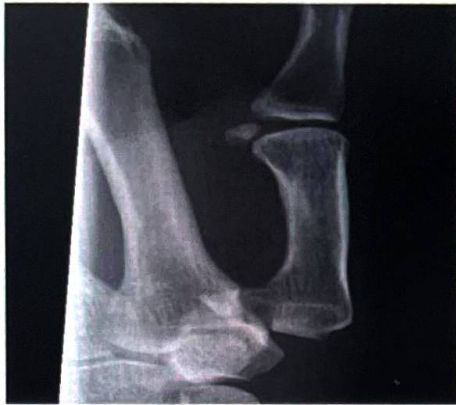The 1st metacarpal (thumb) articulates with Trapezium :
Trapezio-metacarpal joint.

Fracture base of 1st metacarpal (Bennet & Rolando) :

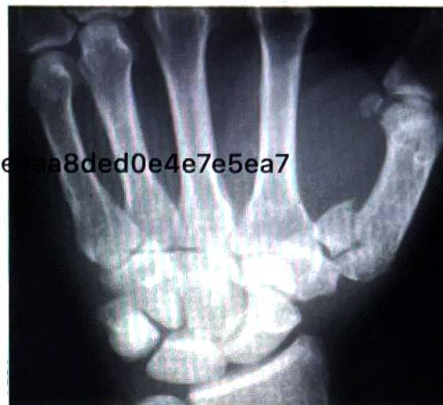

Bennett's	Rolando's
intra-articular fracture at base of 1 st metacarpal joint. Trapezio metacarpal joint. Abductor pollicis longus causes a pull.	
Partial fracture	Complete comminuted fracture, T or Y-shaped.
Displaced fracture	undisplaced fracture (only a small fragment is pulled by Abductor pollicis longus).

Active space



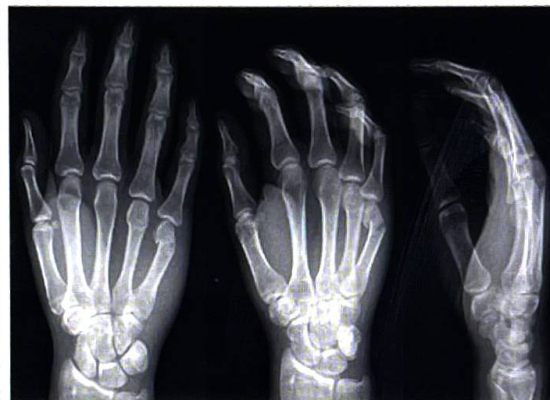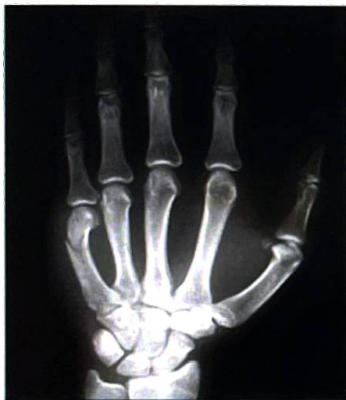Bennet's fracture



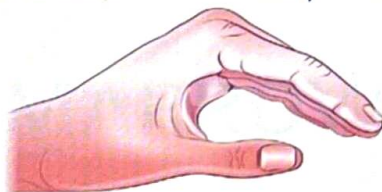
Rolando's fracture

Boxer's fracture :

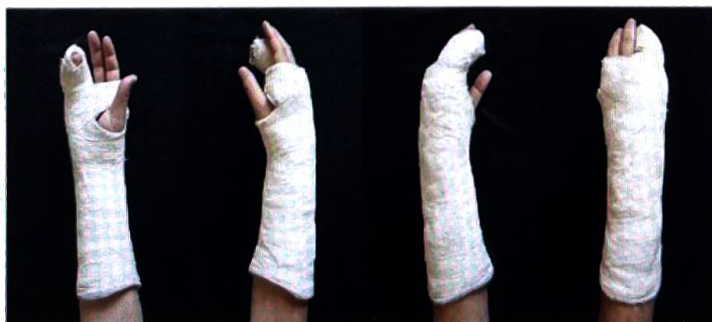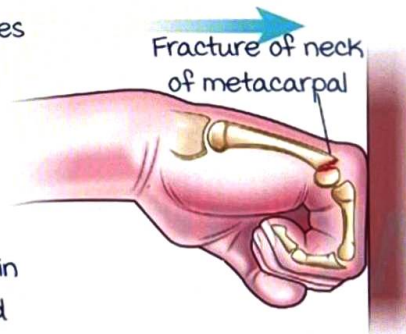
Fracture neck/extra-articular fracture of the 5th metacarpal



Jame's position : Position of safe immobilisation for metacarpal fractures



Wrist is slightly extended, MCP joints in full extension, IP joints extended and thumb in abduction



Anatomy :

Bones → Distal, middle, proximal phalanx

Joints → metacarpophalangeal joint (MCP), Proximal

Active space

interphalangeal joints (PIP), Distal interphalangeal joints (DIP)
Tendon which inserts to the base of the distal phalanx on the dorsal side → **Extensor Digitorum Communis (EDC)**.

Tendon which inserts to the base of the distal phalanx on the volar side → **Flexor Digitorum Profundus**.

mallet finger/Baseball finger :

MOI → **Hyperflexion** injury of the DIP joint when it is in active extension.

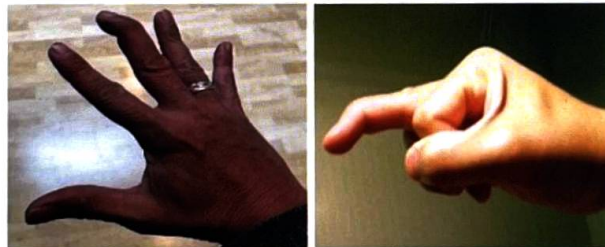EDC gets teared in the substance/
can get avulsed at the base of the distal phalanx on the dorsal side.

Clinical features :

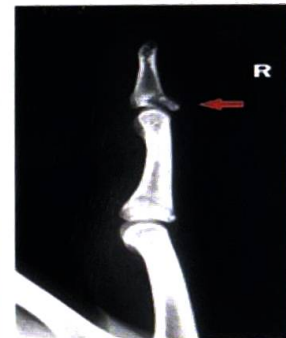
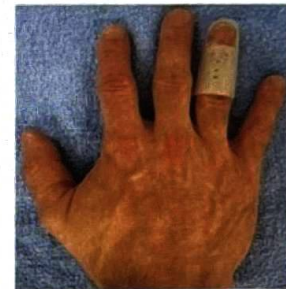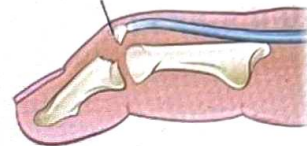
- Inability to actively extend the DIP (passive extension is intact)
- **Flexion deformity** of DIP joint

Rx → **mallet splint/stax splint**.

In mallet finger only 1 finger is involved, while in RA multiple fingers are involved.



mallet finger : Avulsion injury of EDP at DIP joint



Jersey finger :

MOI → **Hyperextension** injury of the DIP joint when it is in active flexion.

FDP gets teared in the substance/
can get avulsed at the base of the distal phalanx on the volar side.

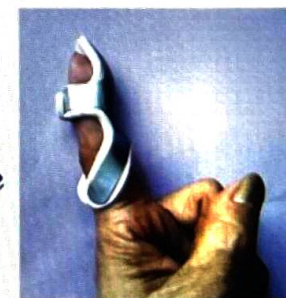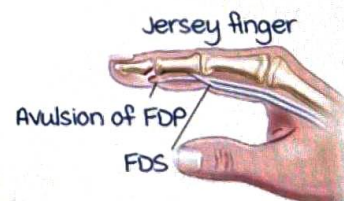
Clinical features :

- Inability to actively flex the DIP (passive flexion is intact).
- **Extension deformity** of DIP joint.

Rx → **Frog splint**.

mallet finger MC in the index finger.

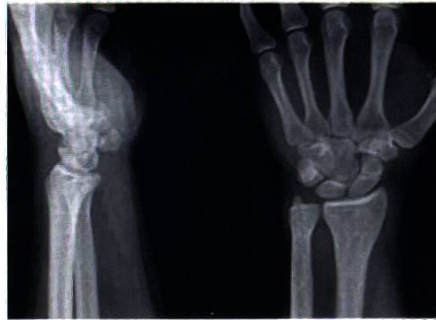Jersey finger is MC in the ring finger.



Q. A 30-year-old female fell on an outstretched hand while riding a bike. She complains of wrist pain & tenderness in anatomical snuff box. She has restriction of wrist movement, attached is the X-ray image. What is your diagnosis?

kumarankitindia1@gmail.com

- A. Transverse scaphoid fracture with perilunate dislocation.
- B. Scaphoid fracture.
- C. Smith fracture.
- D. Hamate fracture.



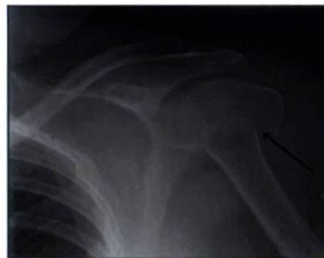Q. A 11 year old boy came to OPD with deformity in his left elbow. What is the most likely injury to cause this deformity?

- A. Supra-condylar fracture elbow.
- B. Olecranon fracture elbow.
- C. Radial head fracture.
- D. Elbow dislocation.



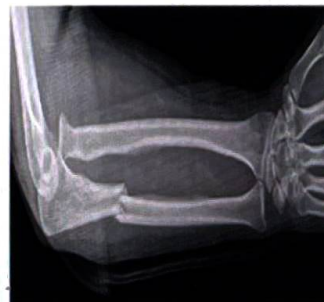Q. What type of fracture is shown in the X-ray?

- A. Neer's type 2 proximal humerus.
- B. Garden's type 2 proximal humerus.
- C. Schatzker's type 2 proximal humerus.
- D. Gustilo type 2 proximal humerus.



Q. What is the diagnosis of this fracture?

- A. Monteggia fracture type II
- B. Side swipe fracture.
- C. Galeazzi fracture.
- D. Monteggia fracture type I



Active space

Q. A patient with history of recurrent posterior dislocation of humerus was evaluated, which part of the head of the humerus will you expect the lesion of humerus to be on?

- A. Antero medial.
- B. Anterior.
- C. Postero lateral.
- D. Posterior.

Q. Which proximal humerus fracture has highest chances of AVN?

- A. One part.
- B. Two part.
- C. Three part.
- D. 4 part.

Q. A patient with closed spiral fracture of humerus shaft came to ERD with wrist drop. Fracture was reduced and splinted by a junior doctor on duty. Wrist drop still persists on 1 week follow up. What should be next line of management?

- A. Only wait & watch.
- B. Surgically explore immediately.
- C. Wait for 1-3 months for recovery, do EMG and if required do surgery then.
- D. Remove the cast do NCS and post for surgical exploration.

Q. True about supracondylar humerus fracture is?

- A. Distal fragment is most commonly dislocated anteriorly.
- B. Cubitus valgus malunion is more common than cubitus varus.
- C. Causes weakness of elbow flexion.
- D. Nerve injury manifestations are transitory.

Q. First sign of Volkmann's ischaemia is?

- A. Paraesthesia.
- B. Pain on passive extension of fingers.
- C. Pain on active extension of fingers.
- D. Swelling of fingers.

Active space

60c6b3eeaa8ded0e4e7e5ea7

Q. Most prominent part on examination of elbow in posterior dislocation of elbow is?

- A. Radial head.
- B. Coronoid.
- C. Lateral condyle.
- D. Olecranon.

Q. Myositis ossificans occurs most commonly around which joint? kumarankitindia1@gmail.com

- A. Knee.
- B. Elbow.
- C. Hip.
- D. Wrist.

Q. A 3yr old boy comes with pain at elbow after being suddenly jerked at the forearm. He is crying & holds the forearm in pronation and refuses to move the limb, what is the appropriate management at this stage?

- A. Examine the child under GA.
- B. Elevate the limb and observe.
- C. Apply Dunlop traction.
- D. Flex the elbow and supinate.

Q. PIN is injured in?

- A. Posterior dislocation of elbow.
- B. Reverse Monteggia fracture.
- C. Monteggia fracture.
- D. Supra condylar humerus fracture.

Q. Colles' fracture is associated with all except?

- A. Common fracture in postmenopausal elderly.
- B. Postero lateral displacement of distal fragment.
- C. Impaction and shortening.
- D. Postero medial displacement of distal fragment.

Q. Position of wrist in Colles cast is?

- A. Dorsal deviation & supination.
- B. Dorsal deviation and pronation.
- C. Palmar deviation and supination.
- D. Palmar deviation and pronation.

Q. Barton's fracture is?

- A. Fracture distal end radius.

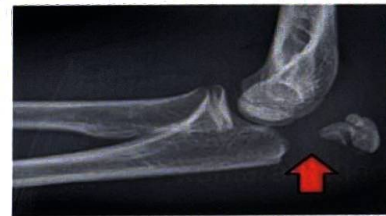- B. Extra articular fracture distal end radius.
- C. Intra articular fracture distal end radius.
- D. Intra articular fracture distal end radius with carpal subluxation.

Q. One of the common fractures that occur in Boxer's while punching their opponent with a closed fist ?

- A. Monteggia fracture.
- B. Galeazzi fracture.
- C. Smith's fracture.
- D. Bennett fracture.

Q. Symptoms of Sudeck's dystrophy are all except ?

- A. Pain.
- B. Sweating.
- C. Stiffness.
- D. Increased Bone density.

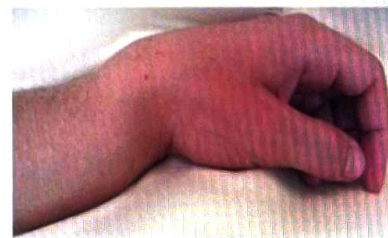

Q. Ideal treatment for the fracture in the X-ray.

- A. Excision & resuturing of triceps.
- B. Closed reduction POP.
- C. Arthrodesis.
- D. TBW.

Q. Fish tail deformity is seen in which of the following fracture ?

- A. Distal end of radius.
- B. Distal end of humerus.
- C. Distal end of tibia.
- D. Distal end of femur.



Q. An old lady fell and injured herself. She took traditional treatment. After one year she presented with a deformity and pain at the wrist. What is the likely diagnosis ?

- A. Malunited extra articular fracture of wrist with dorsal displacement.
- B. Malunited extra articular fracture of wrist with volar displacement.
- C. Malunited intra articular fracture of wrist.
- D. Extensor tenosynovitis.

Q. An old lady slipped and fell at home. She was diagnosed with a Colles fracture and managed with a POP cast. What is the correct sequence of reduction?

- A. Traction, Ulnar deviation, Palmar flexion, POP.
- B. Traction, Palmar flexion, Ulnar deviation, POP.
- C. Traction, POP, Palmar flexion, Ulnar deviation.
- D. Palmar flexion, Ulnar deviation, Traction, POP.

Q. match the name of the fracture with the site

A. Jone's fracture	1. 5 th metatarsal
B. Bennet's fracture	2. 2 nd metatarsal
C. march fracture	3. 1 st metacarpal
D. Boxer fracture	4. 5 th metacarpal

- A. A - 1, B - 2, C - 4, D - 3
- B. A - 1, B - 4, C - 3, D - 2
- C. A - 1, B - 3, C - 2, D - 4
- D. A - 1, B - 2, C - 3, D - 4

Q. A 45-year-old patient with a Tibial fracture on cast presents to emergency department with complaints of intense pain. Cast was removed and on examination Passive flexion was painful, dorsalis pedis and posterior Tibial pulses are palpable & loss of sensation over the first web space was noted. What is the next step in management?

- A. measure anterior compartment pressure.
- B. Duplex imaging / Venous / Color doppler.
- C. Reapply cast.
- D. Give analgesics.

60c6b3eaa8ded0e4e7e5ea7

Q. Which of the following findings appear late in compartment syndrome?

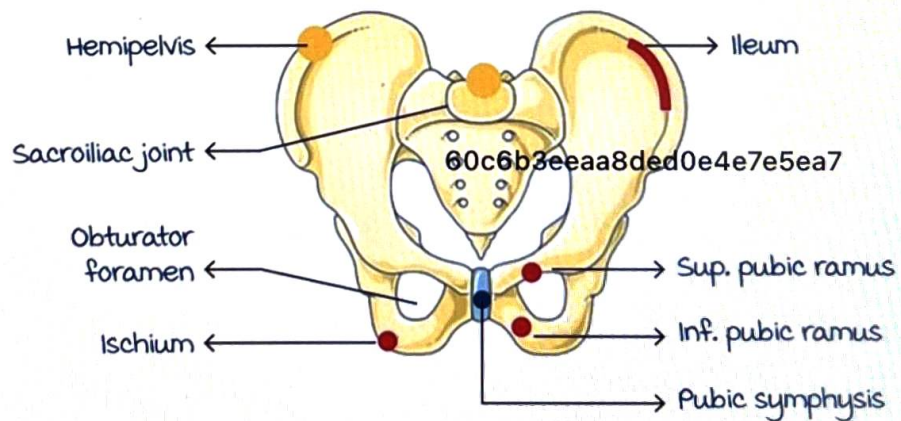
- A. Pallor.
- B. Pulselessness.
- C. Paralysis.
- D. Pain on passive stretch.

LOWER LIMB TRAUMA : PART 1

Pelvis with both hips.

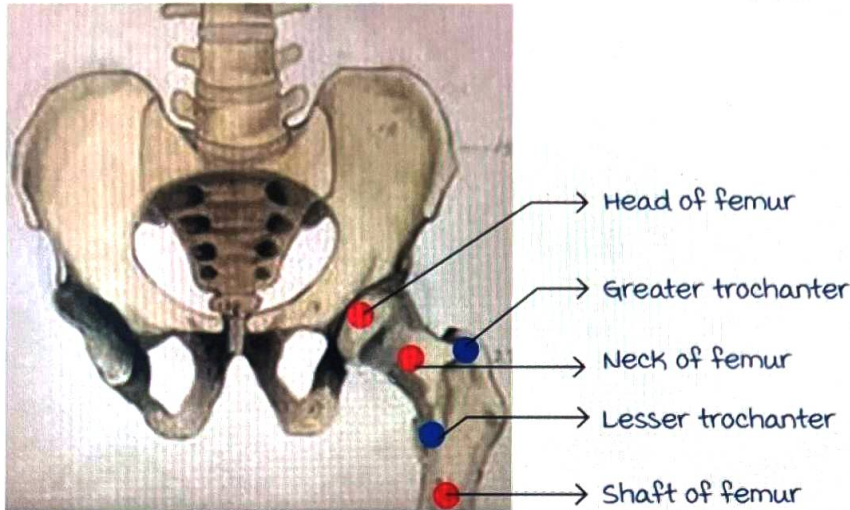
Parts :

- Sacroiliac joint.
- Hemipelvis.
- Obturator foramen.
- Ilium.
- Ischium.
- Pubis.
- Superior and inferior pubic rami.
- Opening known as obturator foramen.
- Acetabulum : Cavity that accommodates the head of the femur to form the hip joint.
It has two walls the anterior and posterior wall.
Head of the femur articulating with the head of the acetabulum.
- Acetabulum is deep.

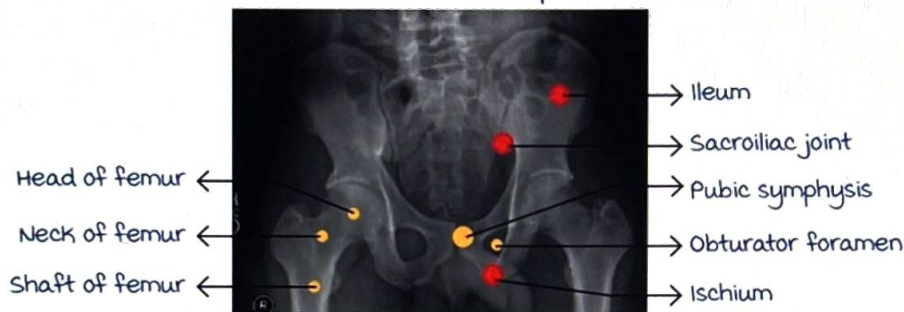


Parts of the femur :

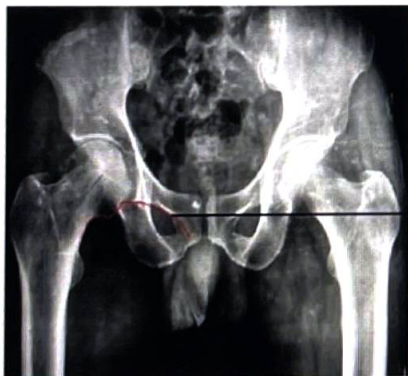- Head is slightly anteverted.
- Neck of the femur.
- Greater trochanter and lesser.



60° Oblique Femoral Neck X-RAY



Landmarks :



1. First landmark : **Shenton's line** or arch is normally is a continuous arch.

The line starts from the **inferior margin** of the **superior pubic ramus**.

Runs **laterally** towards the medial part of the head of the femur and then proceeds **down**.

This arch is called **Shenton's line**.

If there is any pathology then this line is discontinuous.

This includes any kind of pathology that affects the hip

joint affects this normal continuous line :

- Neck of femur fracture.
- Hip dislocations.
- Proximal femur fractures.
- Osteoarthritis
- Avascular necrosis.

2. Head should be located inside the acetabulum, if not this indicates a dislocation.

If there is an obvious fracture line it is definitely a fracture.

3. The tip of the greater trochanter usually coincides with the centre of the acetabulum.

If the tip of the greater trochanter has proximally migrated it causes limb shortening. Whereas, if the tip migrates distally, the limb is lengthened.

4. Neck shaft angle :

The angle between the neck and shaft of the femur. normally it is between 125 to 130° . It is slightly more in children and reduces as the child grows.

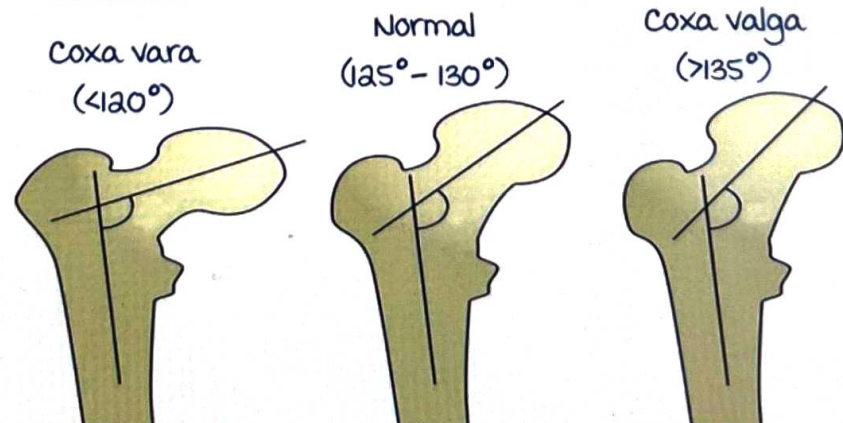
If the neck shaft angle:

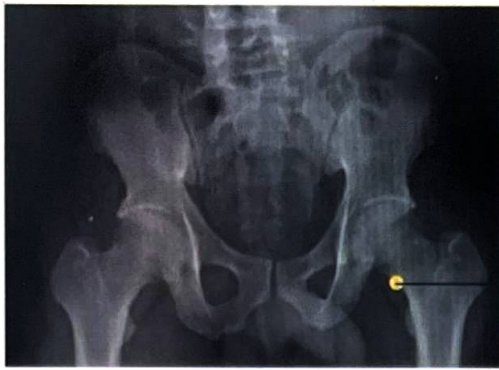- Increases coxa valgum : Limb is lengthened.
- Decreases coxa vara : Limb is shortened.

Coxa vara

00:07:37

- Greater trochanter is proximally migrated.
- Trendelenburg gait.
- Limitation of abduction and internal rotation with axis deviation.

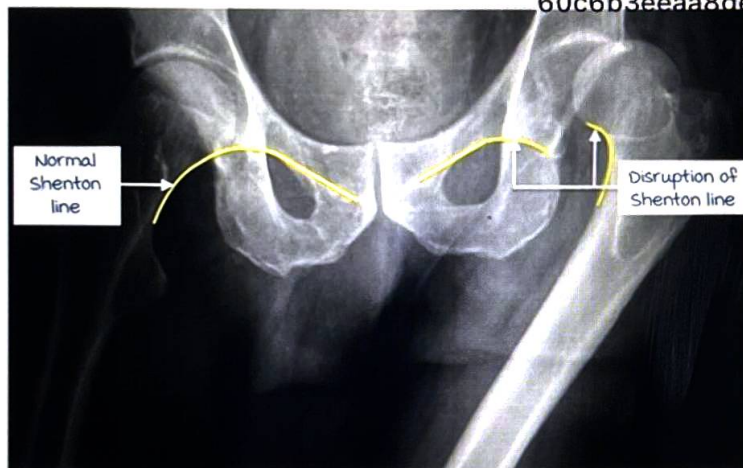




→ Lesser trochanter

In AP view, if the limb is externally rotated the lesser trochanter becomes more prominent in the X-ray.

If the limb is internally rotated the lesser trochanter disappears the head of the acetabulum.



60c6b3eaaa8ded0e4e7e5ea7

Normal
Shenton
lineDisruption of
Shenton line

Right side : Normal.

- Shenton's line is present.
- Inside the acetabulum.
- Neck shaft angle is maintained.
- Tip of the greater trochanter coincides with the head of the acetabulum.

Left side : Abnormal.

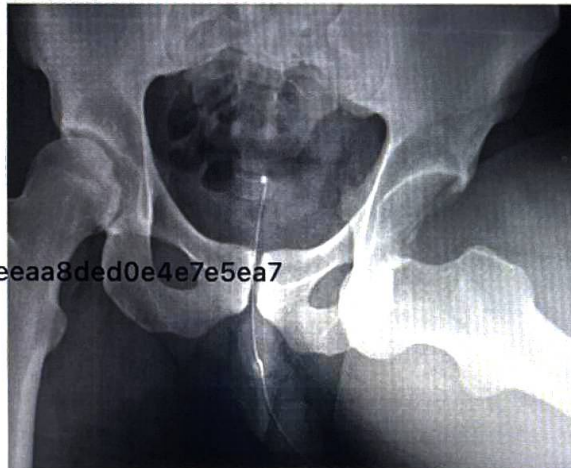
- Shenton's line is broken.
- The head of the femur is not inside the acetabulum.

Inference :

- Dislocation without obvious fracture.
- Tip of the greater trochanter: Proximally migrated - Limb shortening.

Active space

- Thigh looks adducted.
- Neck shaft angle is maintained (only disturbed when there is a congenital anomaly like coxa vara or a fracture)
- Lack of visibility of the lesser trochanter
Inference : Limb is in internal rotation.



Right side :

- Shenton's line is maintained.
- Head of femur is inside the acetabulum

Left side : Abnormal.

- Shenton's line not maintained.
- Head of the femur is not inside the acetabulum.
- Tip of the greater trochanter is not coinciding with the acetabulum.
- Limb is shortened.
- Full visibility of the lesser trochanter suggests the limb is externally rotated.

Pelvic fracture

00:12:04

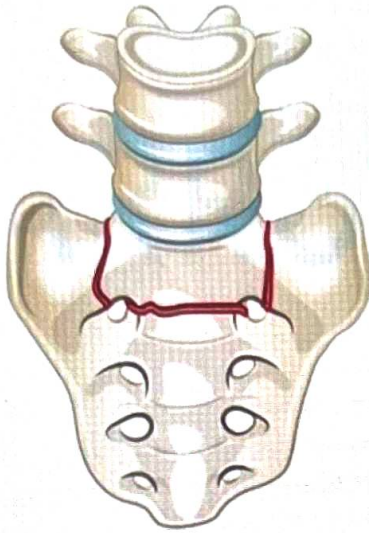
Causes :

High velocity RTA.

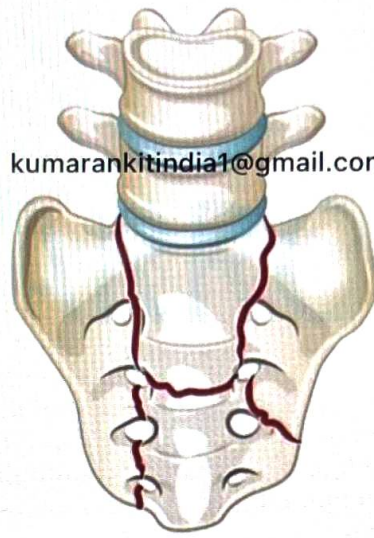
Following fall from height : Jumpers fracture.

Fracture of sacrum occurs mostly.

U shaped or H shaped fracture.



U-Shaped fracture



H-Shaped fracture

Pelvic ring :

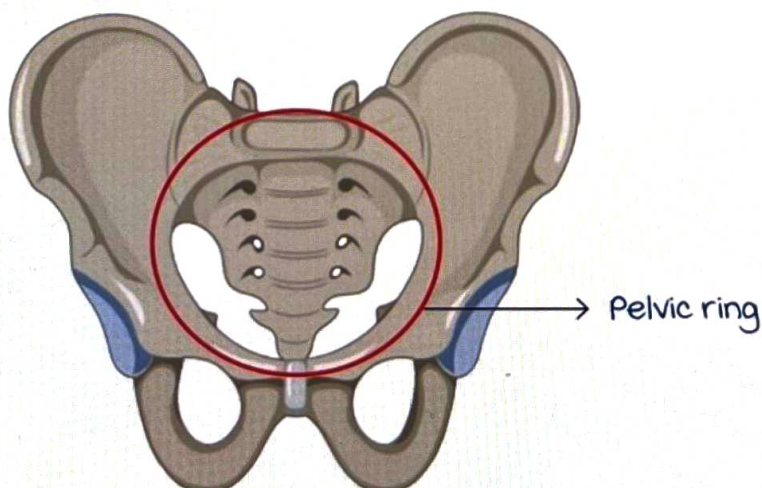
The stability of the pelvic ring is essential for the stability of the pelvis.

Any fracture that disturbs this pelvic ring is called an **unstable fracture**.

The fractures that does not affect the pelvic ring are called stable fracture.

The pelvic ring comprises of :

- The sacroiliac joint.
- Sacrum.
- Ilium.
- Superior pubic ramus.
- Pubic symphysis.
- Iliopectineal line.

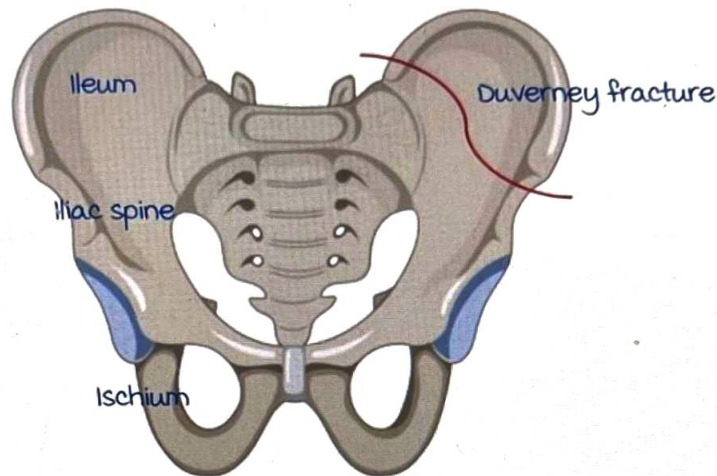


Active space

Tiles classification :

Stable : Injury other than the pelvic rim.

Unstable : Injury to pelvic rim/ ring.



Stable fractures/Type A fractures according to tiles classification :

Pelvic ring not injured. 60c6b3eaa8ded0e4e7e5ea7

Fractures of :

1. Ilium
2. Ischium
3. ASIS
4. AIIIS

Duverney fracture.

Unstable fractures/ Type B fractures

00:15:25

Injury to the pelvic ring.

Young's and Burgess classification

Based on type of injury :

- Anteroposterior compression.
- Lateral compression.
- Complex force.

Antero posterior compression (APC) :

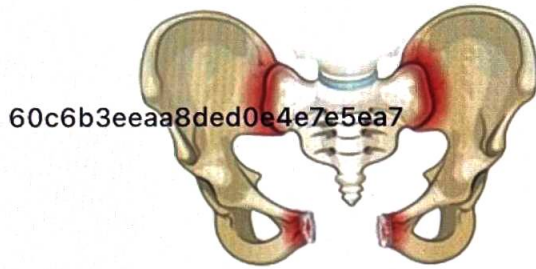
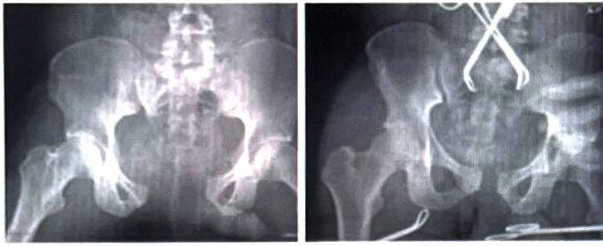Eg : If a man is leaning against the wall and a car hits from the front it. Can lead to APC fracture.

Open book fracture/Pubic diastasis.

Pelvis opens up and there is pubic diastasis.

Ring is injured.

APC/ Antero posterior compression
Open book fracture / Pubic diastasis



Lateral compression force :

This occurs when a person gets a lateral blow on one side, while leaning against a wall on the opposite side (laterally).

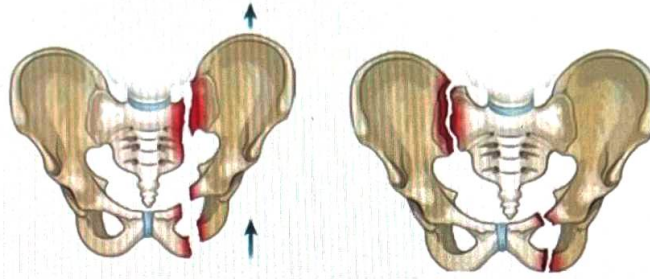
- malgaigne's fracture :
Fracture of ipsilateral superior and inferior pubic ramus with ipsilateral sacroiliac joint disruption.

- Bucket handle fracture :
Ipsilateral sacroiliac disruption.
Contralateral superior and inferior pubic ramus fracture.

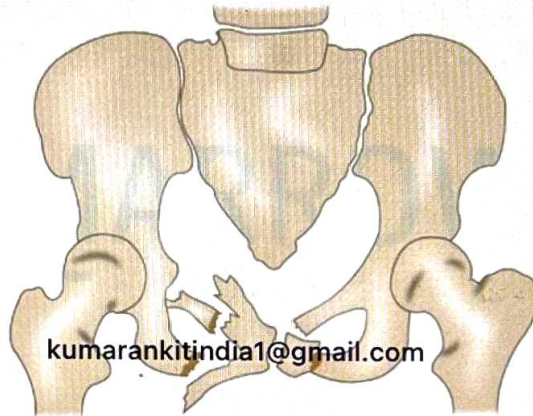


Lateral compression
force

malgaigne Fracture Bucket handle fracture



Straddle fracture / complex force :
Bilateral superior and inferior pubic ramus fracture



Straddle fracture

management of pelvis fracture :

Flat bones are most cancellous hence they bleed more.
venous plexus around the pelvis leads to massive bleeding.

Complication :

Bleeding is the most dangerous complication and can die of haemorrhagic shock.

Soft tissue Injury : **urethral injury**.

Polytrauma management :

1.5 to 2 L blood loss or 4-8 units.

(average human has 5L).

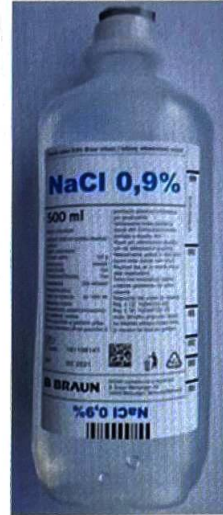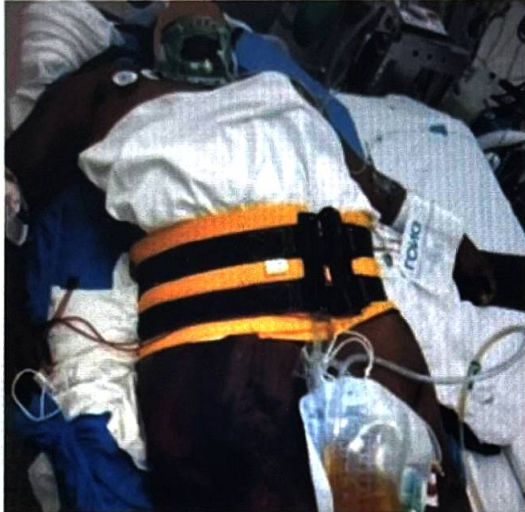Advanced trauma life support (ATLS) :

Simultaneous diagnostic and therapeutic activities intended to identify and treat life and limb threatening injuries beginning with the most immediate.

If the patient is not in cardiac arrest, in order to prevent the patient from deteriorating because of injuries.

- Airway with restriction of cervical spine motion.

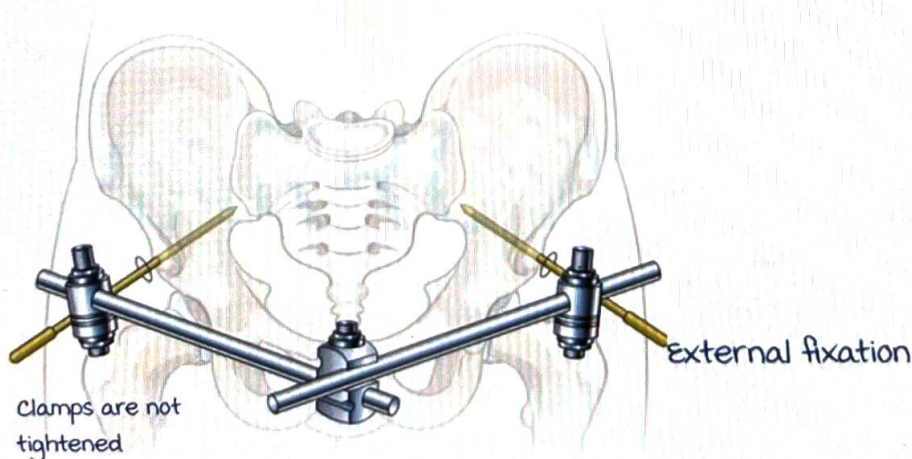
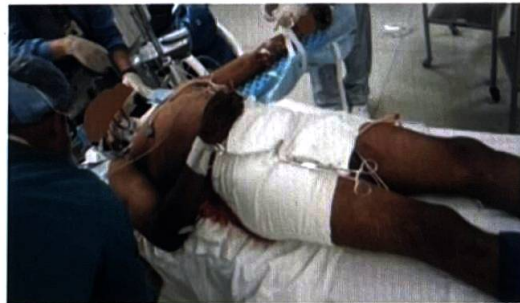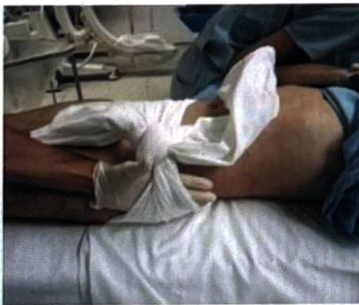- Breathing : Chest expansion.
- Circulation, stop the bleeding (very important)
- Disability or neurological status
- Exposure (undress) and environment (temperature control)



How to stop bleeding in pelvic fracture?

1. Pelvic tamponade with pelvic binder which is wrapped around the pelvis.
2. IVF- RL > NS to restore the volume (ideally blood should be given).
3. Apply external fixation in compression mode.

kumarankitindia1@gmail.com



Acetabular fracture

00:25:19

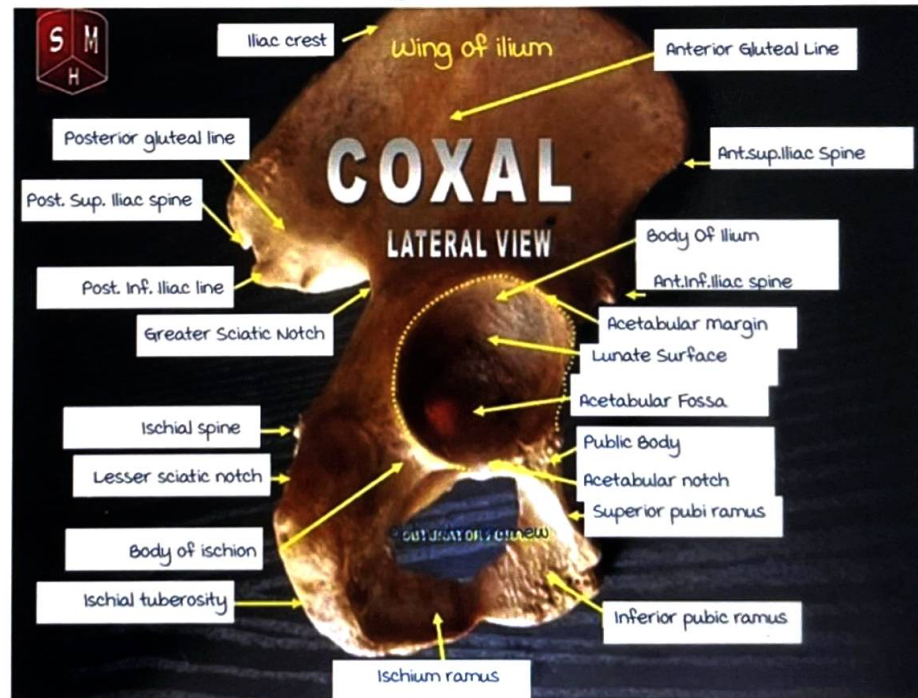
Parts :

- Acetabulum.
- Anterior wall.
- Posterior wall.
- Anterior and posterior column.
- Iliopectineal part.

There are 2 walls and 2 columns supporting the acetabulum.

Fracture of acetabulum is classified using JUDET classification:

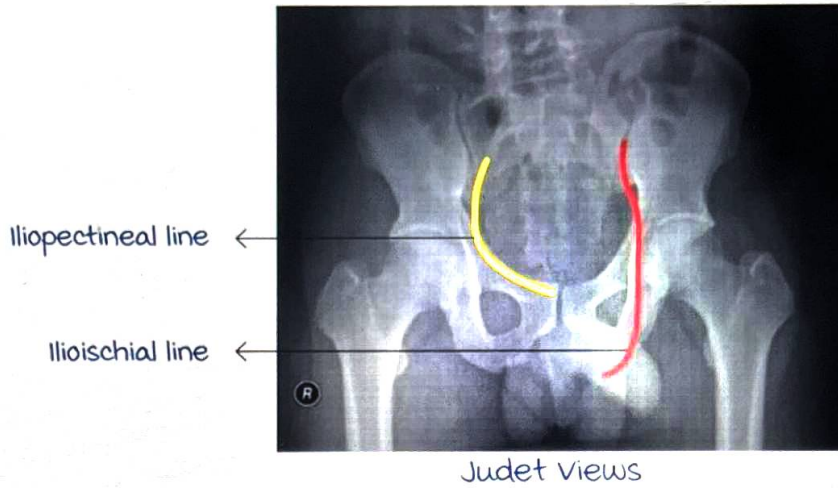
- Anterior wall
- Anterior column
- Posterior wall (most common)
- Posterior column.
- Bi-columnar : X-ray shows SPUR sign.



Judet views :

Iliopectineal line is the radiographic landmark for the anterior column.

Ilioischial line is the radiographic landmark for the posterior column.



Requirement of normal gait :

Normal abductors of the hip (muscle and nerve)

Trochanter at the normal level.

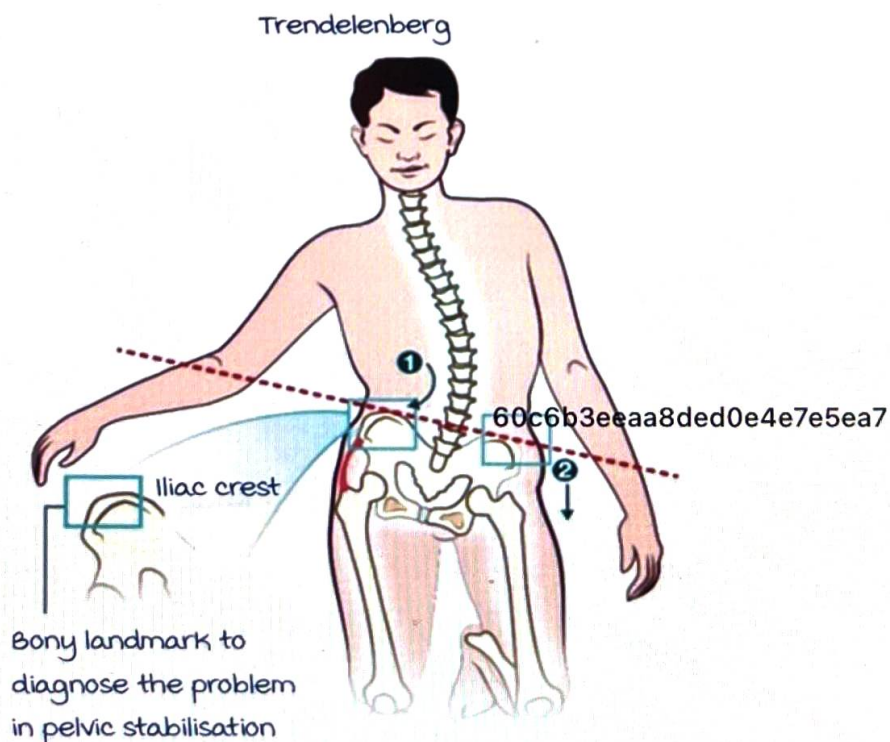
Coxa vara reduces the length of the muscles hence weakness.

Pathology causing positive tredelenburg test is caused by :

- Gluteus medius palsy.
- Gluteus minimus palsy.
- Superior gluteal nerve palsy.
- Coxa vara.

Trendelenburg gait

00:35:40



Coronal plane test.

Aim of the test is to assess the **abduction** of the hip.

Gluteus medius and **minimus** muscles are the primary abductors of the hip.

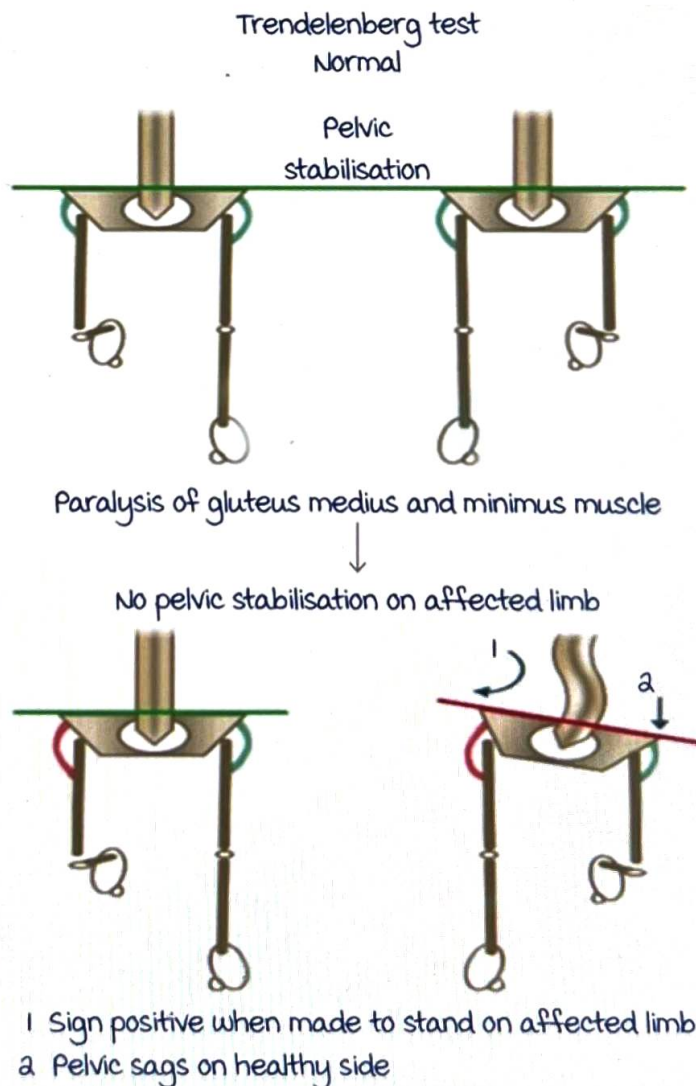
Both muscles receive their intervention from the **superior gluteal nerve**.

When the leg supports the **weight of the body** on the lesioned side, there is dipping of the pelvis towards the contralateral normal side.

Because the pelvis cannot be maintained in a level plane by the lesioned abductors, the patient lurches towards the healthy side to bring it back up.

And leans the torso towards the lesioned side to maintain balance.

This type of gait is known as Trendelenburg gait.



Tredelenburg test steps

00:36:44

1. Patient should be **standing**.
2. Examiner stand in front/ behind.
3. Both ASIS/PSIS are exposed (landmarks).
4. Patient is asked to stand on the normal side with affected side foot off the ground (affected hip is kept extended).
5. The ASIS/PSIS on affected side should move upwards or atleast stay at the same level.
6. Then ask the patient to stand on the affected side keeping the normal side foot of the ground (with normal hip extended).

Inference : The test is positive if ASIS/PSIS of the normal side goes down while the weight bearing on the affected side for 30 seconds.

Abduction of hip assessment :

Abductors are gluteus medius and minimus.

Superior gluteal nerve.

On nerve and muscle damage :

Patient will be unable to abduct.

unable to tilt pelvis back to neutral therefore sinking

Positive Trendelenburg test.

60c6b3eaa8ded0e4e7e5ea7

If the right side affected, the left hip tilts down.

This results in Trendelenburg gait :

uses the trunk to lift the healthy side up by lurching towards the pathological side.

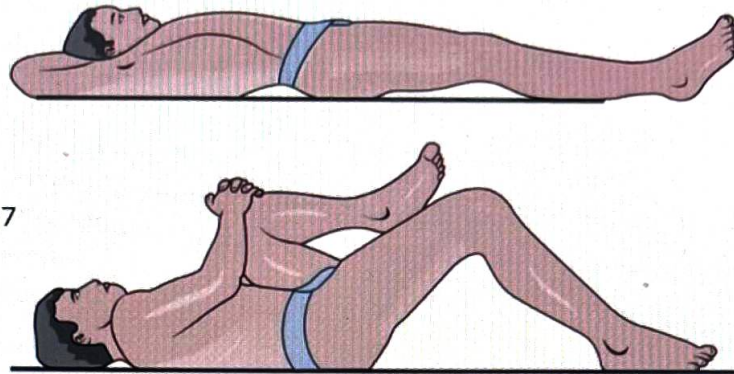
Waddling gait : Due to bilateral failure of abductors.

Active space

Thomas test

00:45:11

Thomas test (or as it called Hugh Owen Thomas well leg raising test) to measure flexure contracture of hip.



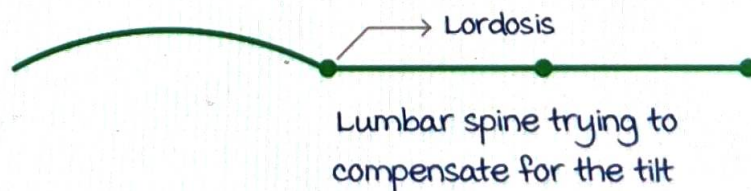
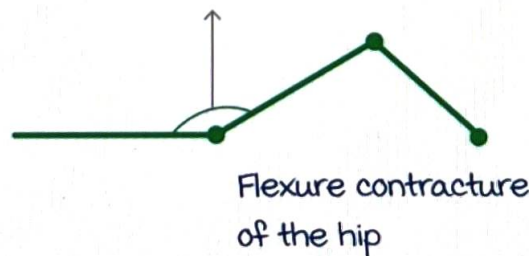
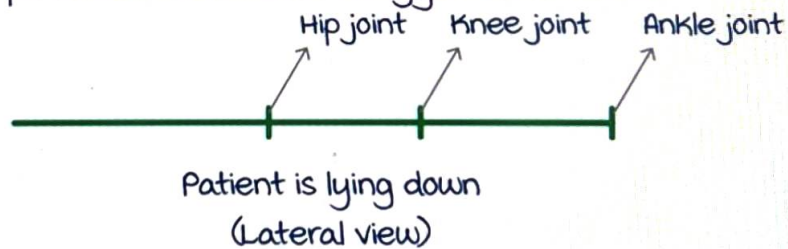
60c6b3eaa8ded0e4e7e5ea7

Thomas Test

Sagittal plane test.

Whenever there is a pelvic contracture the lumbosacral spine compensates for this contracture by going into lordosis.

In flexion contracture of hip, there is a deformity of the hip and pelvis is tilted. As a result of which the lumbar spine compensated and causes exaggerated lordosis.



Active space

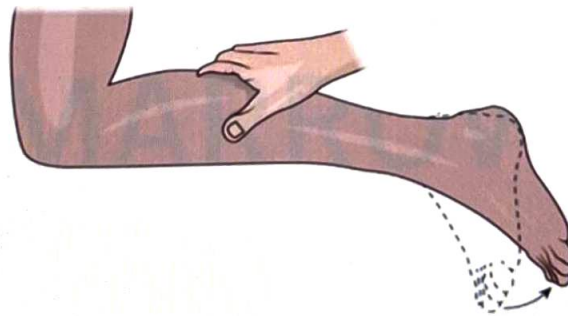
The aim of the test is to remove the lumbar lordosis to reveal the Flexure contracture of the hip.

Steps :

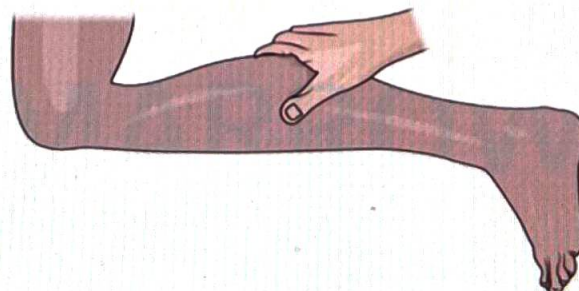
1. Patient lies supine over hard couch and both limbs parallel to each other.
2. If an exaggerated lumbar lordosis is seen, the examiner can insinuate his hand between the spine and couch.
3. Keeping the hand under exaggerated lordotic spine, the unaffected hip is gradually flexed keeping the knee in flexion till lumbar lordosis is obliterated.
4. Once taken out, the hand cannot be insinuated again
5. At the same time, the affected hip goes for flexion
6. make sure the opposite ischium has not lifted off the couch. Kumarankitindia1@gmail.com
7. Now as the patient to hold the unaffected flexed knee and measure the flexion of affected hip on horizontal plane.

Thompson test

00:56:18



Squeezing calf produces plantar flexion of foot when heel cord is intact



Squeezing calf produces no motion of foot in injured leg

Active space

Assesses the integrity of tendo achilles.

Also known as Symonds Thompson test.

Normally on squeezing the gastro-soleus complex, there is plantar flexion.

In disruption of the Tendo achilles this does not happen.

Dislocation of hip

01:00:10

Hip is a very stable joint.

Dislocation of the hip means that the head of the femur escapes the acetabulum.

Supported by a strong iliofemoral ligaments

Recurrent dislocations are very rare.

Simple or complex dislocations.

Types :

1. Pure :

- Anterior.
- Posterior.

2. Fracture dislocations :

- Posterior.
- Central (# through acetabulum).
- Anterior.

Posterior dislocation of hip :

most common type.

mechanism of injury often by impact of knee with dashboard, which drives the femoral head backwards, out of the acetabulum. kumarankit1@gmail.com

Typical deformity :

Injured limb adducted internally rotated and flexed at the hip and knee, with knee resting on opposite thigh.

Dislocated femoral head lies posterior and superior to acetabulum.

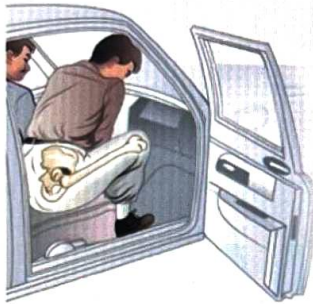Femur adducted and internally rotated.

Hip is flexed. Limb shortening present.

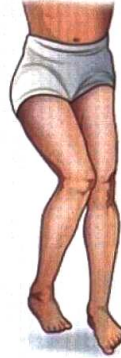Sciatic nerve may be stretched.

AP view : Shows superior position of femoral head and no apparent fracture of the acetabulum.

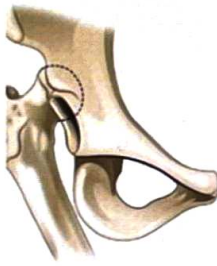Posterior hip dislocation



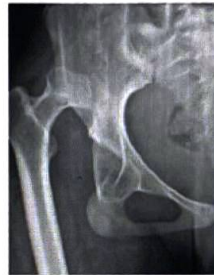Mechanism of injury often by impact with dashboard, which drives the femoral head backwards, out of the acetabulum



Typical deformity: Injured limb adducted, internally rotated and flexed at the hip and knee, with knee resting on opposite thigh

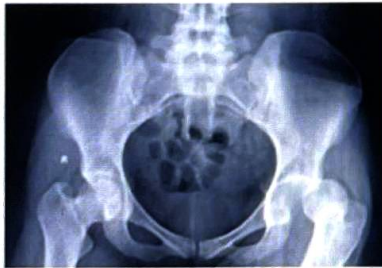

Dislocated femoral head lies posterior and superior to acetabulum. Femur adducted and internally rotated; hip flexed. Sciatic nerve may be stretched



AP radiograph shows superior position of femoral head and no apparent fracture of the acetabulum

(MC) dislocation of Hip - Posterior



X ray :

Right side : Normal.

Left side : Shenton's line is broken.

Head of the femur is outside the acetabulum.

Thigh is adducted.

No visibility of the lesser trochanter suggesting it is internally rotated.

kumarankitindia1@gmail.com

Anterior dislocation :

Occurs in deceleration injuries.

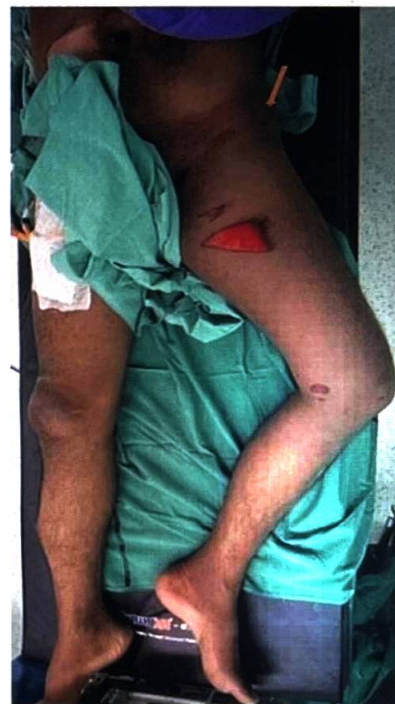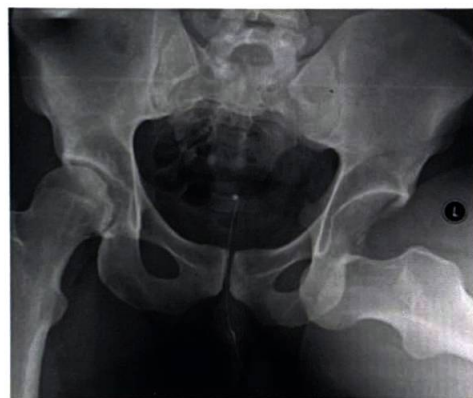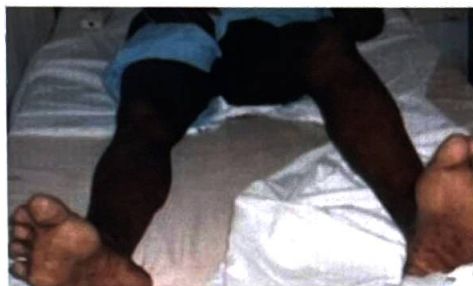Fall from height.

Attitude :

60c6b3eaaa8ded0e4e7e5ea7

- Flexion at the hip.
- Abduction.
- External rotation with limb lengthening.

Flexion abduction external rotation



Xray :

Left side.

Shenton's line is broken.

Head of the femur is outside the acetabulum.

Lesser trochanter is fully visible : Externally rotated

Tip of the greater trochanter is distally migrated - limb lengthening.

Fracture dislocations

01:08:32

Any attitude can be present other than the pure dislocation attitude.

Post dislocation, if the **head of the femur** is palpable in the

- **Gluteal region** : Posterior fracture dislocation

- **Femoral triangle**/Anterior triangle of the thigh :
Anterior dislocation.
- Inside the **pelvis** : Central fracture dislocation (this can be palpated by **per rectal examination**)

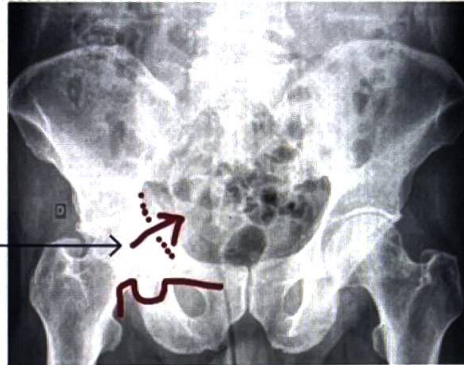
XRAY :

Right side :

Shenton's line is disturbed.

Acetabulum is fractured and head of femur has moved inside.

This is a **central fracture dislocation**.



					Complex injury mechanism.	
Dislocation	moi	Attitude	Limb length	Palpation	Dislocation	Palpation
Posterior dislocation.	Dash-board injury	<ul style="list-style-type: none"> • Flexion • Adduction • Internal rotation. 	Limb shortening	Head palpable in the gluteal region.	Posterior fracture dislocation	Head palpable in the gluteal region.
Anterior Dislocation	Deceleration injury, fall from height.	<ul style="list-style-type: none"> • Flexion • Abduction • External rotation 	Limb lengthening	Head palpable in the femoral triangle region.	Anterior fracture dislocation	Head palpable in the femoral triangle region.
				Central fracture dislocation.		Head palpable on per rectal examination.

management :

This is an emergency condition.

- Reduction with in 6-12 hours.
- Dislocated for > 6-12 hrs : Increased risk of **avascular necrosis**.
- Closed reduction.

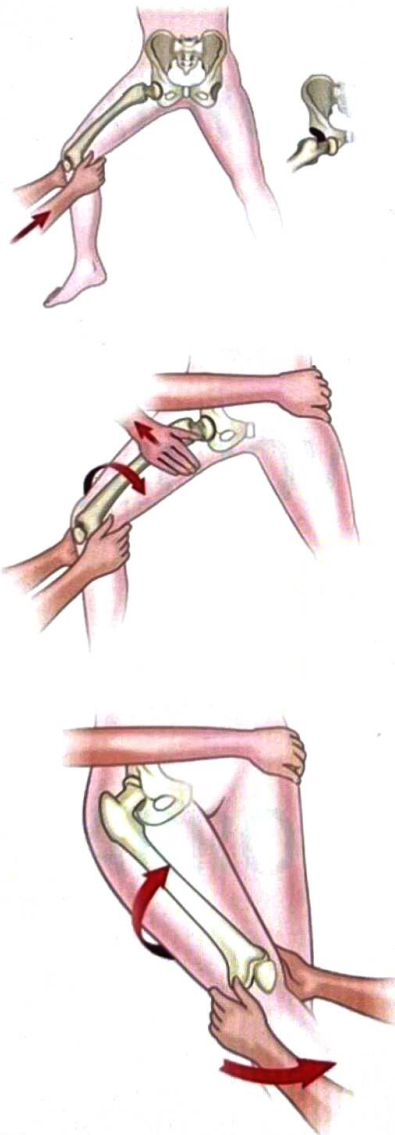
Active space

- Closed reduction under anaesthesia.
- Open reduction.

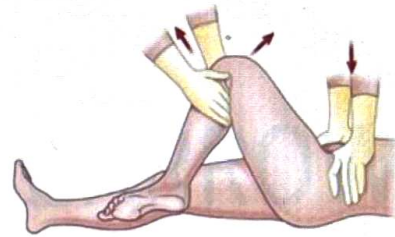
60c6b3eaa8ded0e4e7e5ea7
Reduction manoeuvres :

Allies.
Bigelow's.
Stimson
East Baltimore.

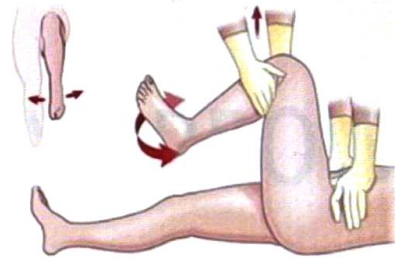
Bigelow maneuver



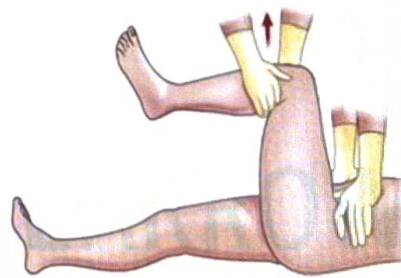
Allis maneuver



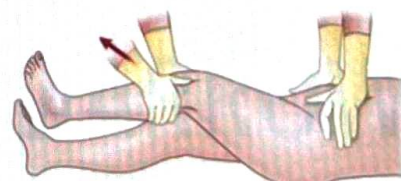
Stabilize the hip at ASIS



Apply traction to leg, internal and external rotation of hip



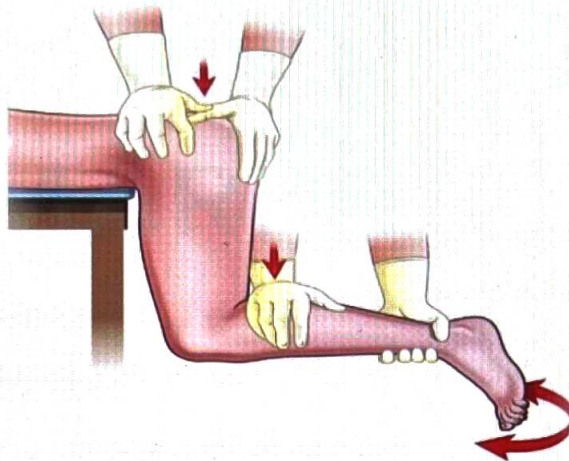
Slowly increase leg traction and flex the hip to 90 degrees



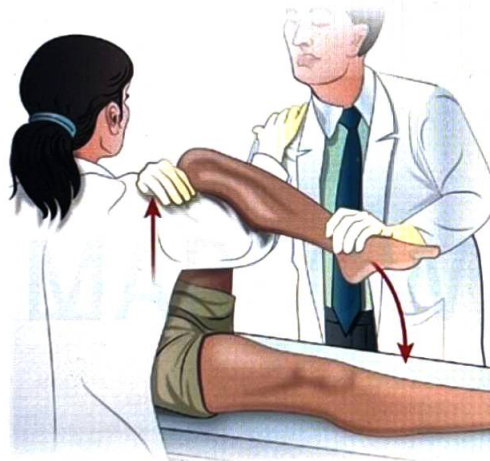
Extension following reduction

Active space

Stimson maneuver



East Baltimore Lift manoeuvres

Vascular sign of **Narath** :

- Inability to palpate the femoral artery while the popliteal, dorsalis pedis and posterior tibial artery will be palpable.
- This sign is seen in any condition where the head of the femur is **not in place**.
- Surgical removal of head.
- Developmental dysplasia of hip
- Disease process that destroys the head.

Complications :

most common avascular necrosis (6-12hrs).

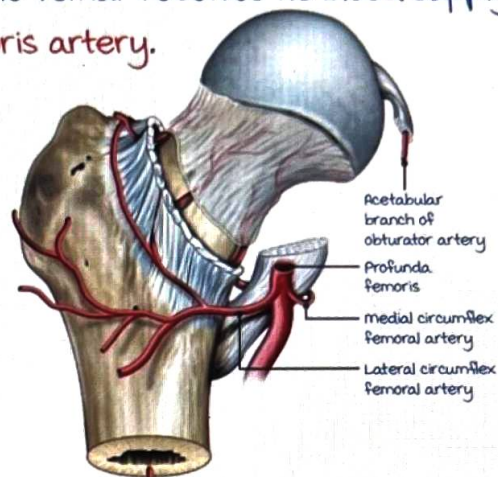
Sciatic nerve injury (posterior dislocation).

Femoral nerve injury (anterior dislocation).

Blood supply picture

01:16:04

The head of the femur receives its blood supply from **profunda femoris artery**.



The profunda femoris artery gives rise to **two** branches : the medial circumflex artery and lateral circumflex artery. The predominant source of supply is the medial circumflex artery and it runs behind the intertrochanteric region.

When neck of femur fracture occurs the fracture disrupts the blood supply, whereas intertrochanteric fracture does not affect the blood supply.

The chances of **AVN** and non-union is more with neck of femur fracture.

And the chances of malunion is more with intertrochanteric fracture.

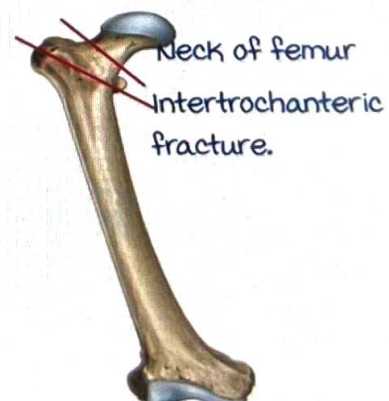
The intertrochanteric line is also the **anatomical landmark** of the insertion of the capsule of hip joint.

Any fracture proximal to the intertrochanteric line is considered to be **intracapsular fracture** (E.g # NOF)

Any fracture distal to the capsular attachment is called an **extracapsular fracture** (E.g. Intertrochanteric #)

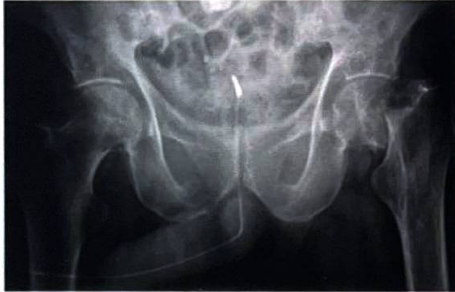Proximal fractures of the femur.

- Neck of femur fracture
- Inter trochanteric fracture that runs between the greater and lesser trochanter.

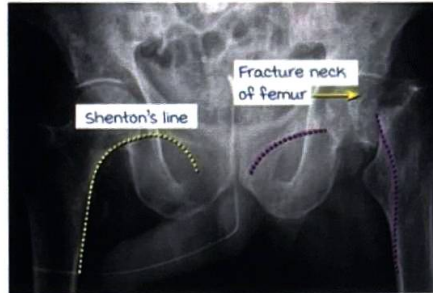


Although these two sites lie close to each other, they have similar presentation but management and outcome is different.

Neck of femur fracture
(Intracapsular)



Shenton's line in fracture
of neck of femur

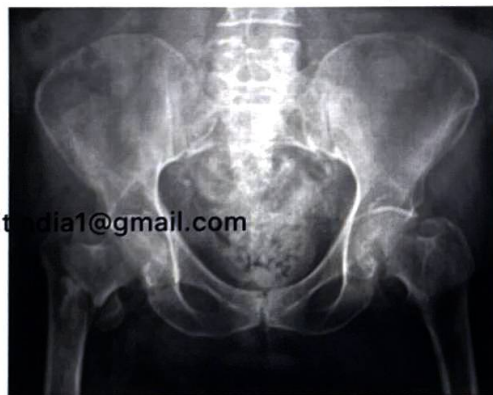

Left side :

Shenton's line disrupted.

Diagnosis : Intracapsular neck of femur fracture.

Fracture NOF - Extracapsular



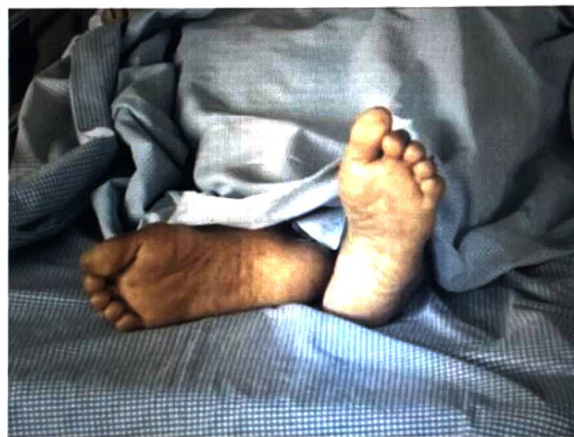Right side :

Shenton's line is broken.

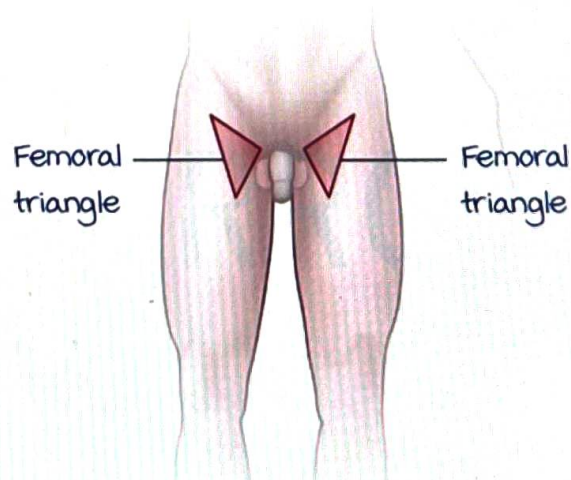
Diagnosis : Intertrochanteric extra capsular fracture.

	Neck of femur fracture/ Intracapsular	Intertrochanteric fracture/ Extracapsular
Age	50-60 years	70-80 years
Sex	Female > male	Female > male
Trauma	Trivial fall	moderate to severe fall
Pain	mild pain	moderate to severe pain
Location	Pain in Scarpa's triangle/femoral triangle.	Pain in trochanteric region
Shortening	Shortening < 1 inch	Shortening > 1 inch
Deformity/ Attitude	External rotation < 45° (capsule limits it)	External rotation > 45°
Complication	AVN (45%) > Non-union (30%)	mal-union/ Coxa vara/ Decrease in neck shaft angle, trendelenburg gait.

External rotation of lower limb



Femoral triangle/Scarpa's triangle



Active space

external rotation of limb is limited in neck of femur fracture as it is limited by capsule.

Whereas in intertrochanteric fracture there will be marked external rotation (almost 90°)

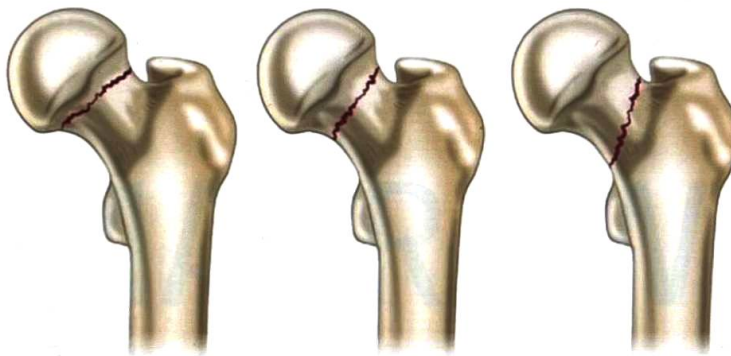Causes of non-union of neck of femur fracture.

1. Synovial fluid inhibit healing.
2. Periosteum around neck of femur lacks cambium layer that has osteoprogenitor osteoblasts (function is to synthesis the bone).
3. Decreased vascularity.

60c6b3eaa8ded0e4e7e5ea7

Neck of femur fracture :

Anatomical classification



Anatomical classification :

1. Sub capital (worst prognosis).
2. Trans cervical.
3. Basi cervical (best prognosis).

Significance : more proximal the fracture, even worse prognosis.

Pauwels classification :

more the angle, more vertical and unstable is the fracture.

Pauwels angle : The angle subtended by the fracture line with the horizontal plane.

- Type I : 30°
- Type II : $30-50^\circ$
- Type III : $>50^\circ$

Garden's classification :

Based on the disruption of the trabecular alignment.

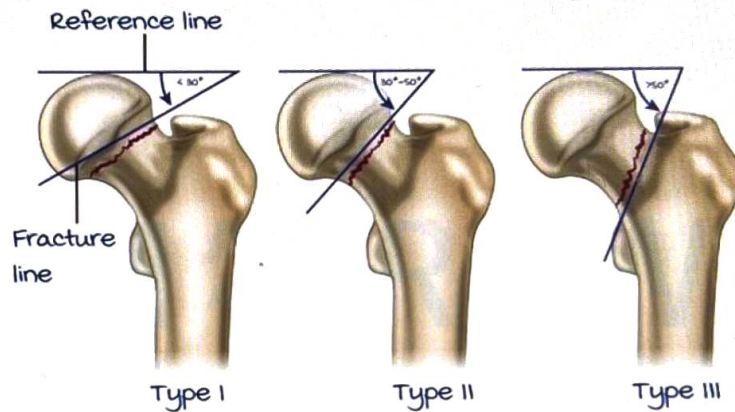
Stage I : Undisplaced incomplete, including valgus impacted fractures.

Stage II : undisplaced complete (only in this type trabecular alignment between head, neck & acetabulum is maintained).

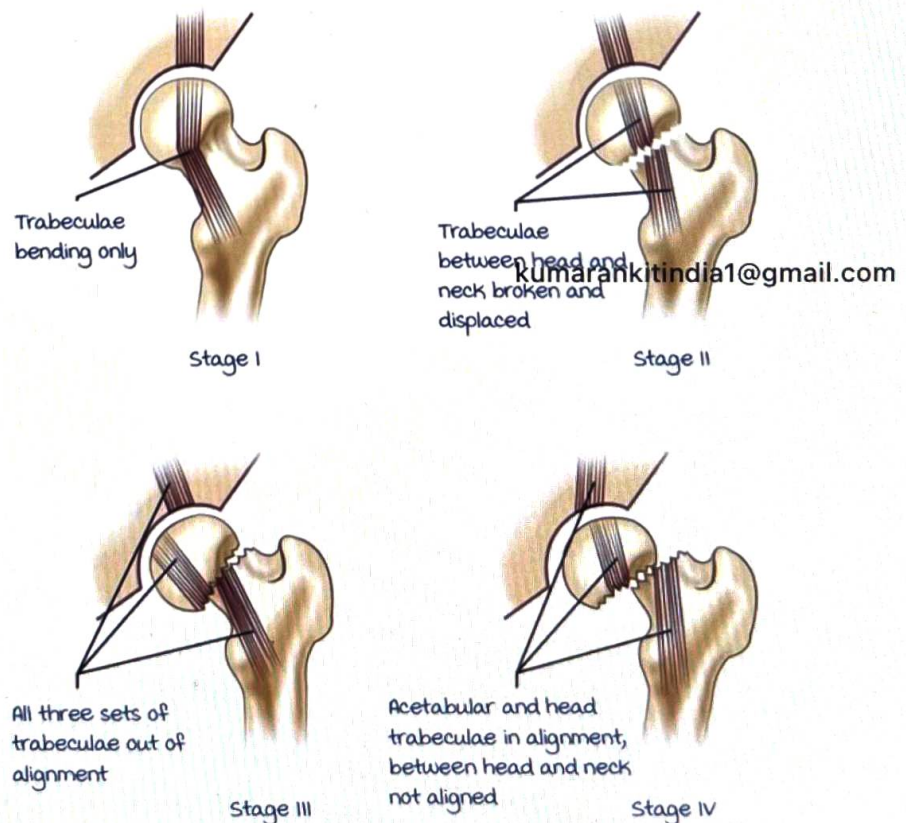
Stage III : Complete fracture, incompletely displaced.

Stage IV : Complete fracture, completely displaced.

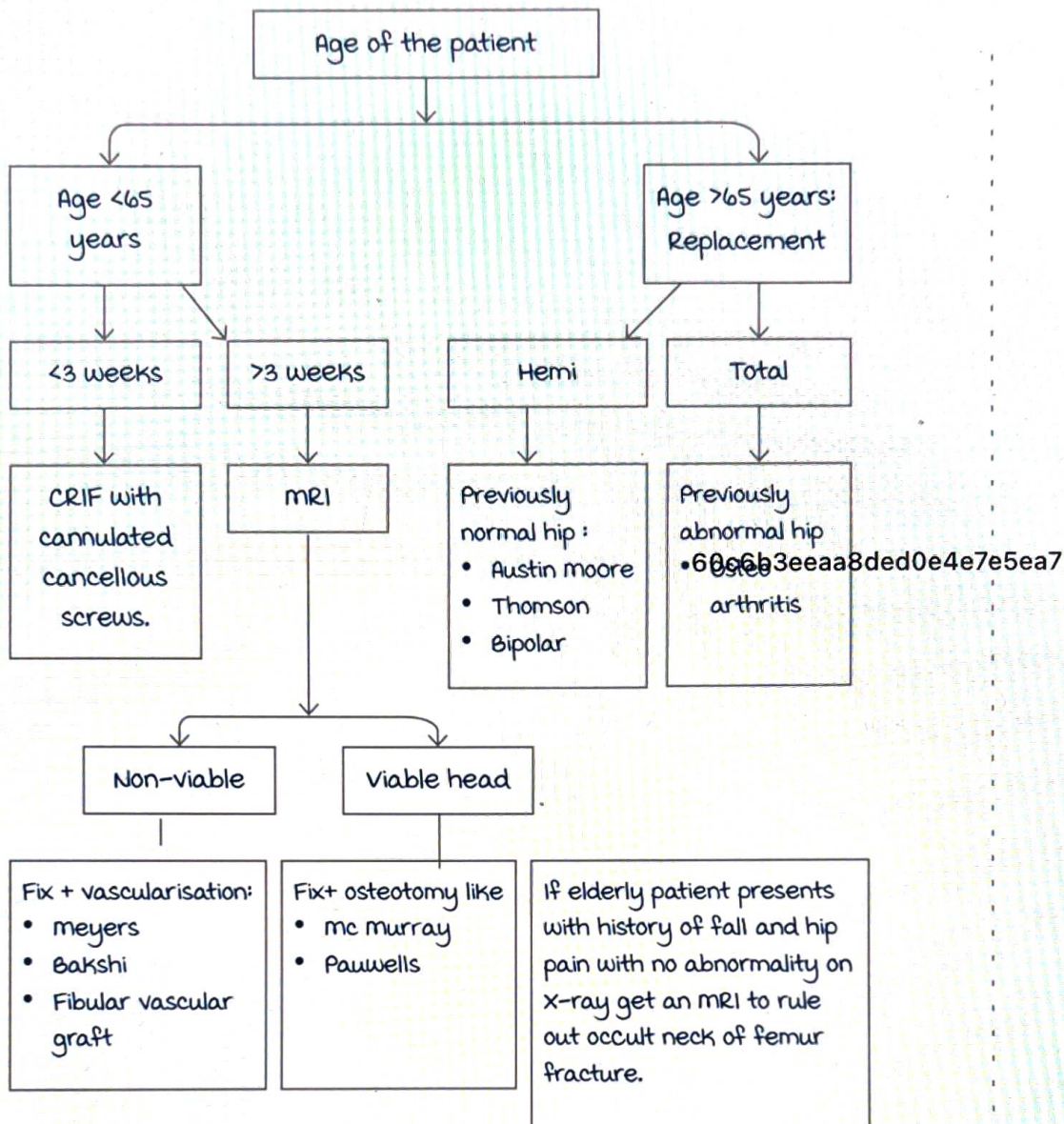
Pauwels classification of fracture neck of femur



Garden classification of fracture neck of femur



management of neck of femur fracture :



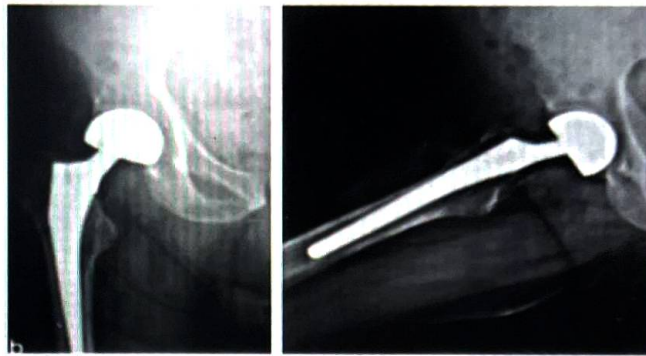
- Compromised blood supply : Reduction of fracture with vascular graft.
- Osteonecrosis of femoral head : Hemiarthroplasty.
- Tendency of non-union : Osteotomy.

Young patient : Fresh fracture closed reduction internal fixation with cannulated cancellous screws.

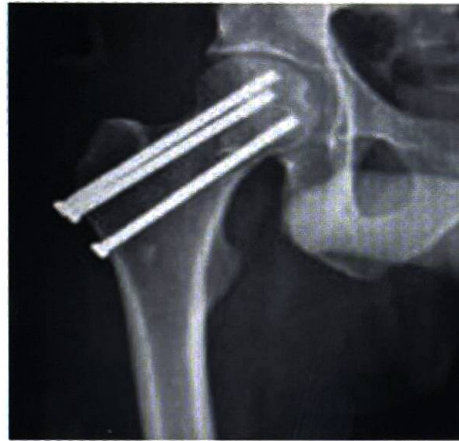Elderly patient : Hemiarthroplasty

Active space

Hemiarthroplasty



Fixation with cancellous screws.



Prosthesis used :

- Bipolar : Preferred as it has 2 articulating sites.
- Austin moore
- Thompson.



Bipolar



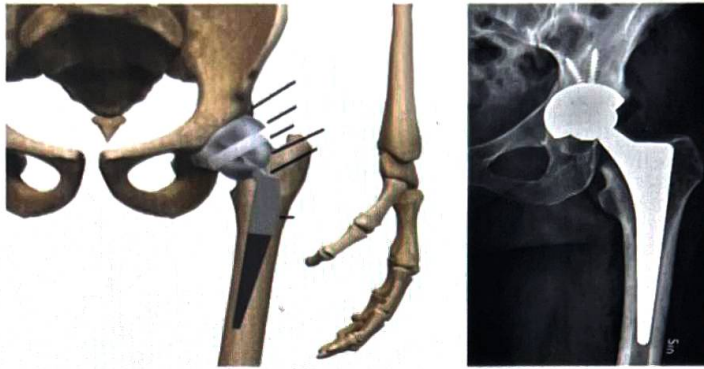
Austin moore



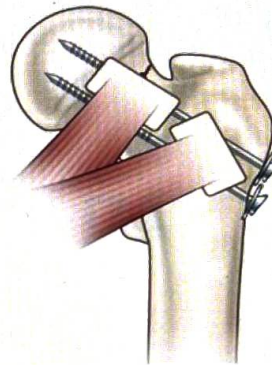
Thompson

If patient has pre-existing hip condition like osteoarthritis; total hip replacement is preferred. Here the head of the femur as well as the acetabulum is replaced.

Total Hip Replacement



Vascularisation procedure :
 meyer's: **Quadratus femoris muscle**
 Remove bone from insertion
 of muscle, and muscle + bone
 is attached to neck.



Bakshi's : **Tensor fascia Lata**
 Remove the bone from the insertion of
 the muscle with the bone and place it on the neck.
 If the viability is good and the neck of femur is not uniting
 osteotomy is done
Osteotomy.

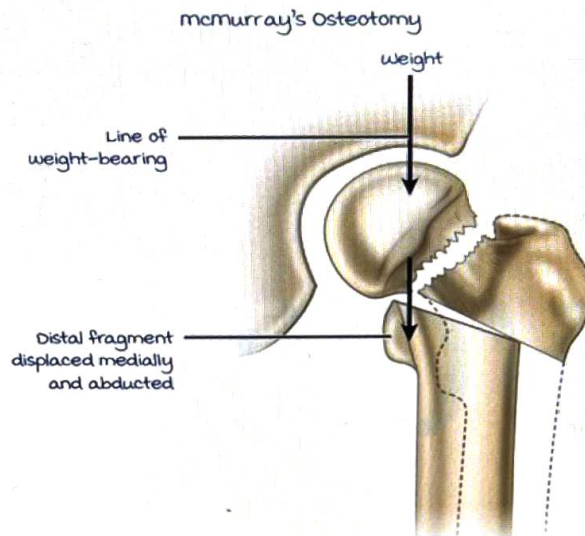
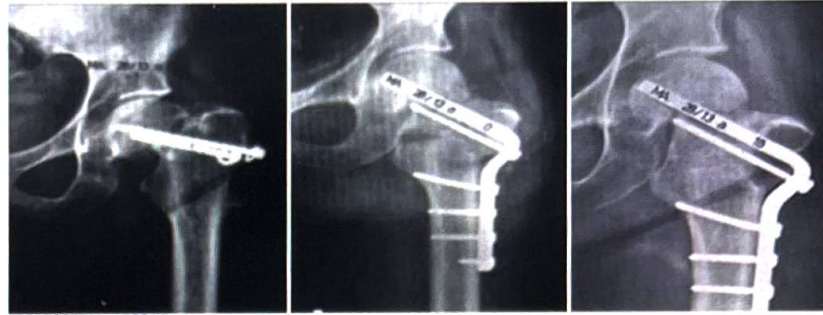
Pauwels osteotomy :
 Converts the vertical frax pattern to a horizontal
 pattern-change the **orientation** of the frax.

mcmurray osteotomy :
 medialisation osteotomy.
 Armchair effect.

Transposing the shaft medially, so that the weight of the
 body is transmitted directly into the shaft **bypassing the**
 fracture line. kumarankitindia1@gmail.com
 (Weight bearing axis bypass the fracture) show in the
 image.

Active space

Pauwels osteotomy - orientation change



1. A 45 year old male with history of fall. X-ray showed fracture neck of femur. History is more than 3 weeks old.
kumaraankitindia1@gmail.com
 Best management plan will be

- Hemiarthroplasty
- Total hip replacement
- Fixation with cancellous screw
- McMurray's osteotomy

If an elderly patient comes with history of fall and pain in the hip. Diagnosis?

Neck of femur fracture.

Even the patient is able to walk : It can be valgus impacted type.

If X-ray is normal : Fracture neck of femur until proven otherwise with MRI.

management of intertrochanteric fracture :

- Prevent malunion.

- Reduce efficiently.
- Neck shaft angle must be maintained.
- Fracture can be fixed with proximal femoral nail.

An older device used is the dynamic hip screw : sliding compression mechanism is used.

Complications of neck of femur extracapsular malunion :
Coxa vara leading to Trendelenburg limp (greater trochanter has migrated, gluteus medius and minimus is shortened)

Conservative management :

For old patients, cases where surgery is contraindicated, or patients with comorbidities, of extreme ages.

- Russel traction
- Derotation boot for inoperable cases : The boot which apply on the patients limb with a rod.

The rod prevents external rotation thereby, preventing malunion (not ideal).

60c6b3eaaa8ded0e4e7e5ea7

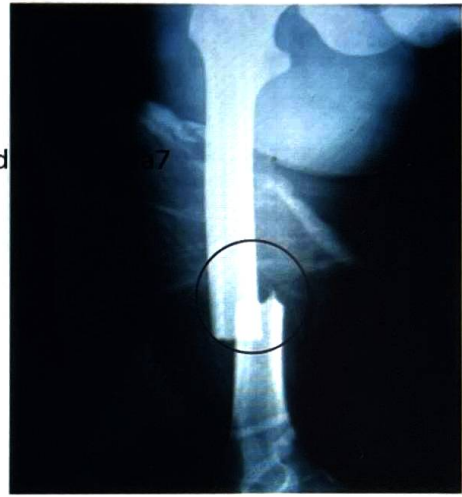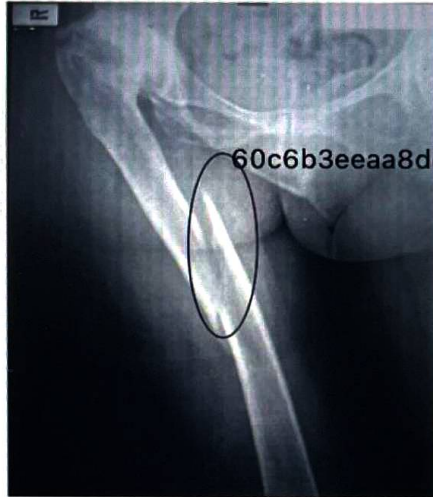
Active space

LOWER LIMB TRAUMA : PART 2

Femur shaft fracture

00:00:08

Fracture shaft of femur in adults :

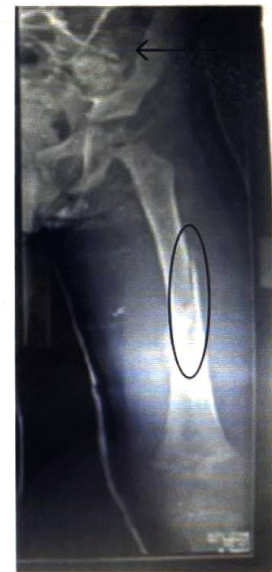

Fracture shaft of femur in child :
Triradiate cartilage has not fused in the head of the femur.

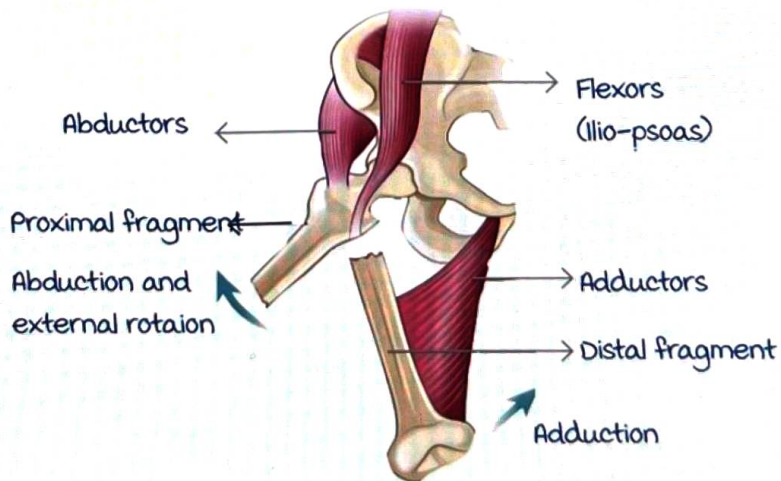
Displacement of fractured ends in femoral shaft fracture :

In proximal fragment :

- Flexion.
- Abduction.
- External rotation.



Active space



Winquist & Hansen classification :

mc complication : Stiffness of knee joint.

Delayed/non union.

Shock : 1-1.5 L of blood loss.

60c6b3eaa8ded0e4e7e5ea7

Key words in other clinical scenario :

massage history : myositis ossificans.

Pain on passive stretching following a fracture : Compartment syndrome.

Femur fracture/difficulty in breathing :

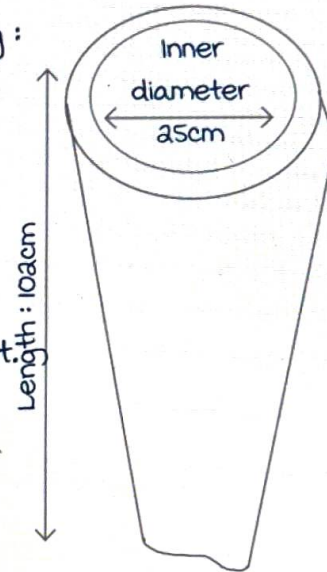
Fat embolism syndrome.

Thomas splint :

Long bone fractures in lower limb particularly femur fracture can be temporarily stabilized by Thomas splint.

Other splint :

Bohler and Braun splint.



management of shaft of femur fracture :

< 6m : Pavlik Harness.

6m - 5 yrs : Hip spica cast (not in children < 2 yrs / < 12 kg).

Hip spica is hip immobilization with spine.

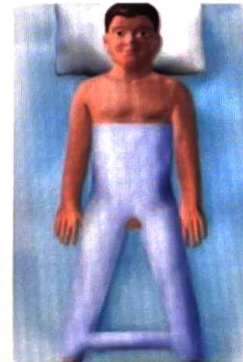5 - 10 yrs : Flexible nails (plates if unstable),

Ender's nail, titanium elastic nail system (TENS).

> 10 yrs : Closed reduction and internal fixation with intramedullary interlocking nails.



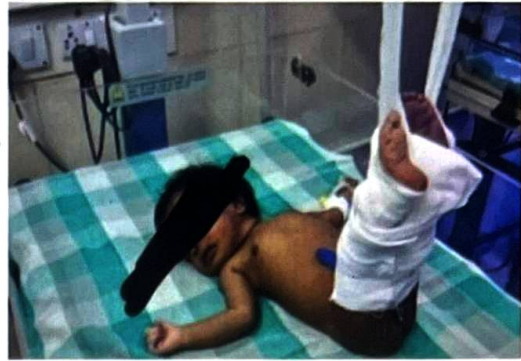Pavlik Harness



Hip Spica Casts

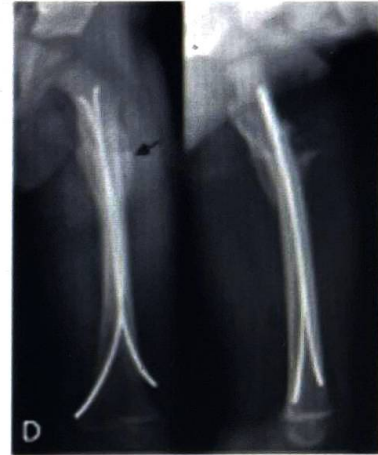Gallow's traction :

For children <2yrs & < 12kgs.
Both the lower limbs are hanging.
For temporary stabilisation.

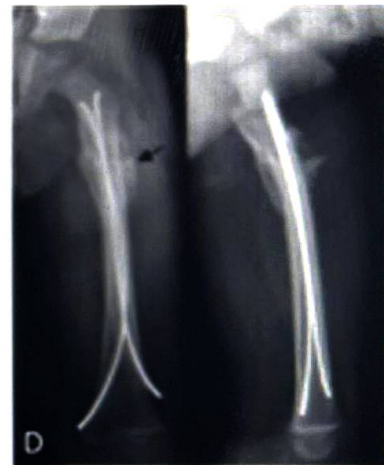

Elastic/flexible nails :

Titanium Elastic Nail system (TENS).



Intramedullary interlocking nail femur :



60c6b3eaaa8ded0e4e7e5ea7

Kuntshner nail :

It's an old nail.

It's straight nail and femur is a curved bone.

By putting a straight nail in a curved bone we get three-point fixation.

It is used for isthmus fractures of the femur.

Not used in segmental/comminuted fracture.

The cross section of the nail is clover leaf like in shape.

Eye of the nail or the slot of the nail is faced anterolaterally.



Fat embolism syndrome : After 48 hours after the fracture.

Not seen in children.

Clinical scenario : Long bone fracture in an adult. 24 to 48 hours later.

Presents with the classical triad of fat embolism syndrome :

Respiratory symptoms : Dyspnea or tachypnea.

Neurological symptoms : Confusion or disorientation.

Petechial rash : In axilla, neck, periumbilical area, conjunctiva of lower lid, front and back of chest, shoulder.

Differential diagnosis : ARDS/Acute respiratory distress syndrome.

Gurd's criteria :

Gurd's major criteria (4) :

Axillary or subconjunctival petechia.

PaO_2 below 60 mm Hg.

CNS depression.

Pulmonary oedema.

Gurd's minor criteria (8) :

Tachycardia.

Fever.

Anemia.

Thrombocytopenia.

Fat globules in sputum.

Fat globules in urine (Gurd Test) : Lipuria : Earliest.

Increasing ESR.

Retinal emboli.

1 major + 4 minor = fat embolism.

Prevention : Immobilise & fix the fracture early.

Treatment : Supportive O_2 + IPPV/Intermittent positive-pressure ventilation.

Damage control orthopaedics in patient presenting with fat embolism syndrome :

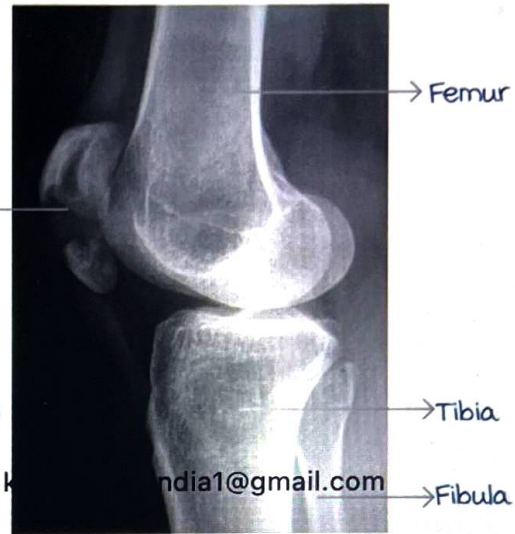- External fixation.
- Stabilisation in ICU.
- Definitive care (later after stabilisation).

Patellar fracture

00:11:08

X-ray for knee joint lateral view :

Transverse fracture of patella with proximal fragment displacing proximally & distal fragment staying.



Quadriceps muscle tendon attaches to the patella proximally.

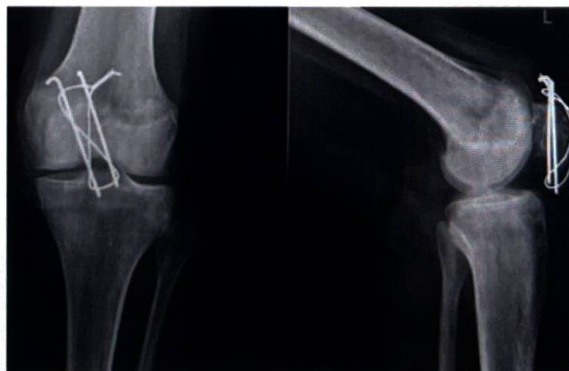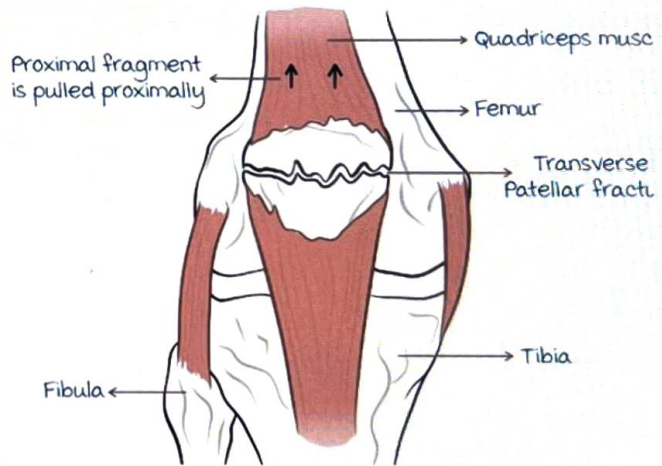
Hence in case of patellar fracture, proximal fragment is pulled away. These distractive forces acting on the patella, prevents it's healing.

Patellar fracture diagnosis :

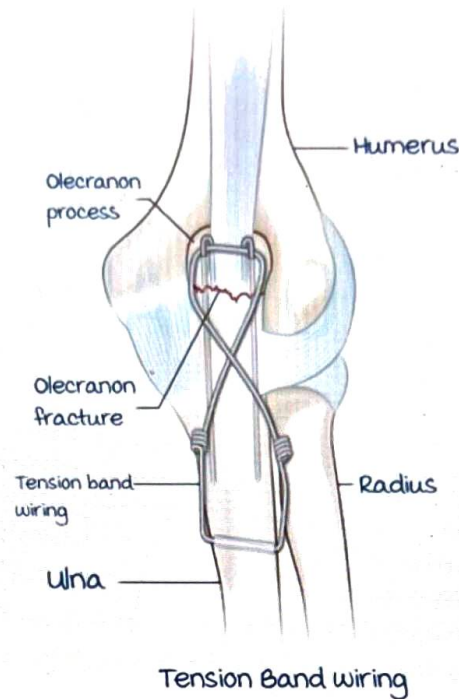
X-ray knee joint :
AP view, lateral view
And **skyline view.**

Treatment of patellar fractures :
Convert the distractive forces into compressive forces

Open reduction internal fixation with **tension band wiring.**
Use K Wires + Stain less steel wire.



Active space



Tension band wiring : Also used in **olecranon fracture**.

Sometimes, patellar fracture if undisplaced with no extension lag, can be managed conservatively by : **Cylinder cast/tube cast**.

kumarankitindia1@gmail.com

Here, the cast is applied like a cylinder or a tube to the whole length of the leg upto ankle.

Bumper fracture

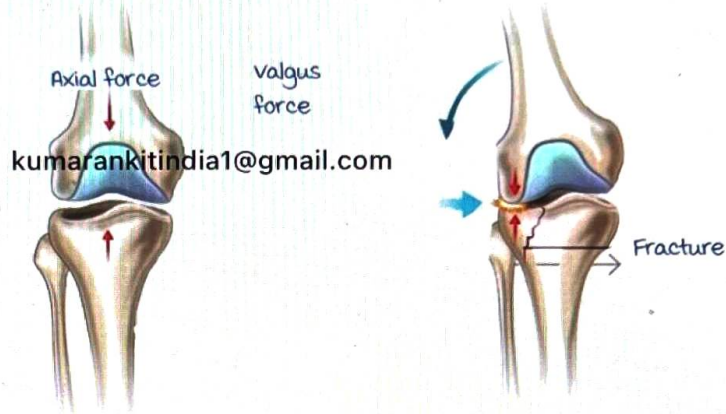
00:14:00

When a pedestrian gets hit on the medial side of the leg by the bumper of a car in an accident.



Fracture of lateral condyle of tibia :
Force : Axial loading and valgus force

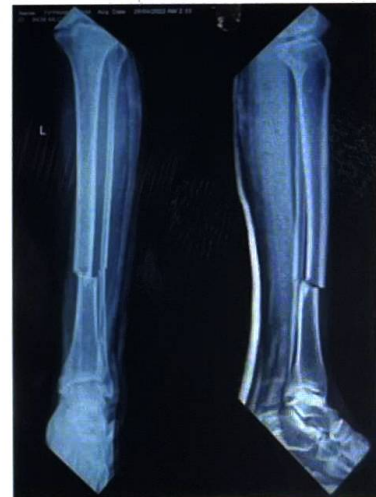
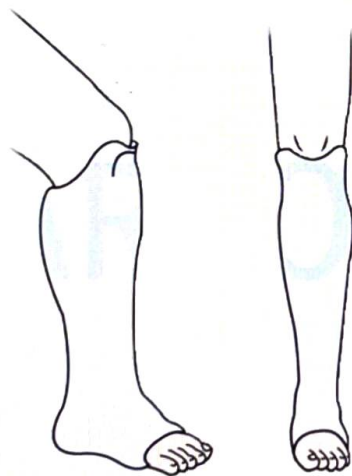
Intra articular : # of necessity.
Rx : Open reduction + internal fixation.
with plates.



Tibia shaft fracture

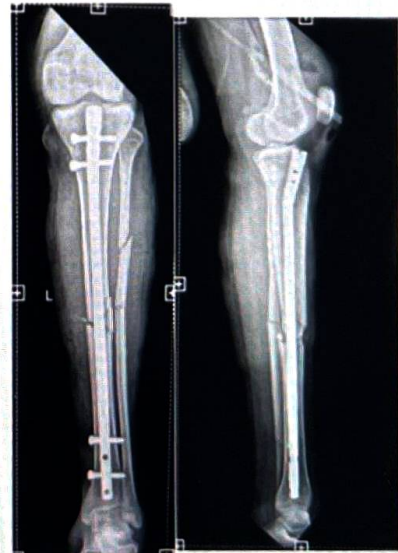00:15:08

Conservative managment : Patella tendon bearing cast.



Definitive treatment :

Closed reduction Internal fixation
with intramedullary interlocking
nail.

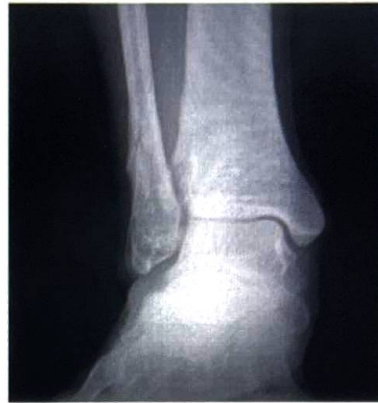

Active space

Runner's fracture

00:15:08

Stress fracture of the fibula :

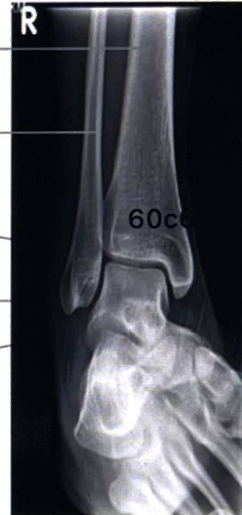
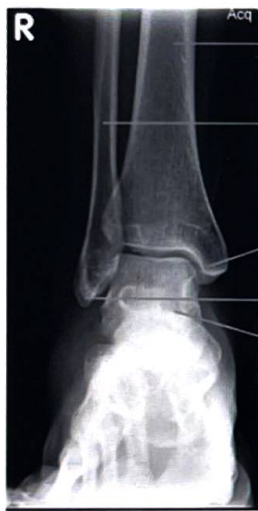
Ankle anatomy :

X-ray views :

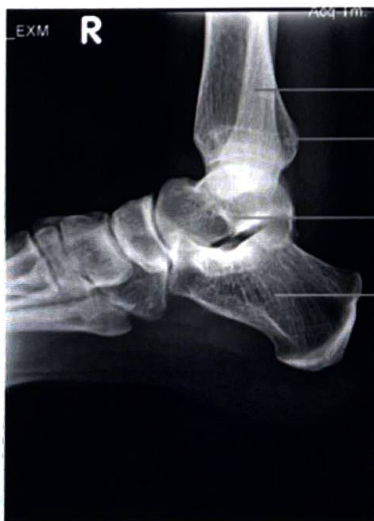AP view :

mortis view :



- Tibia ←
- Fibula ←
- medial malleolus ←
- Lateral malleolus ←
- Talus ←

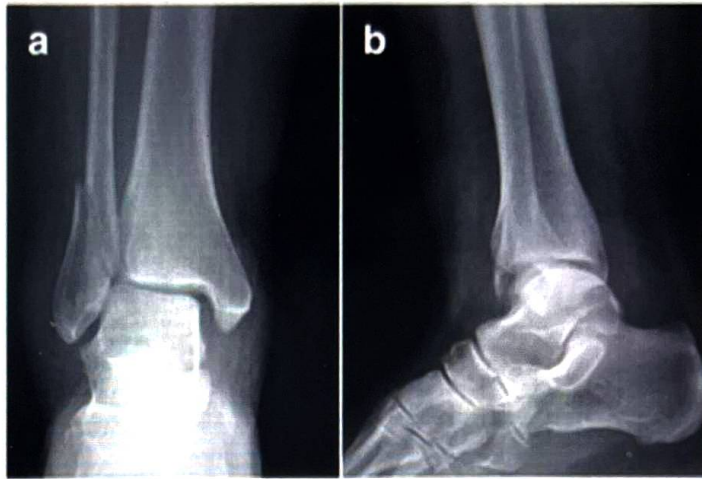
Lateral view :



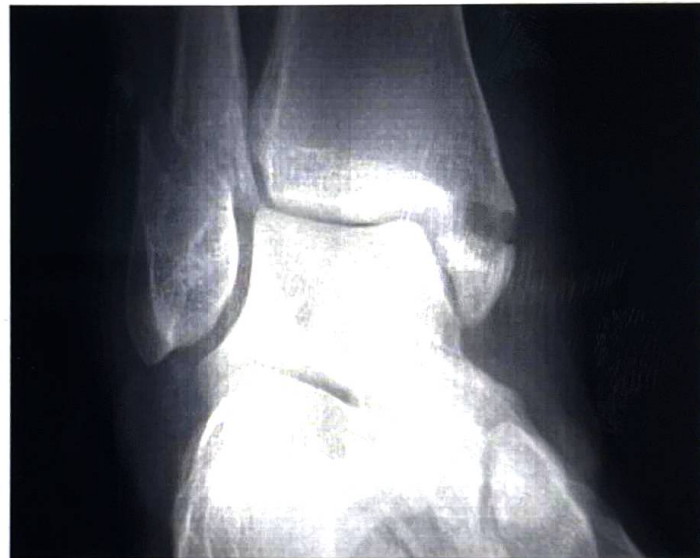- Tibia
- Fibula
- Posterior malleolus
- Talus
- Calcaneus

Active space

Lateral malleolus fracture :



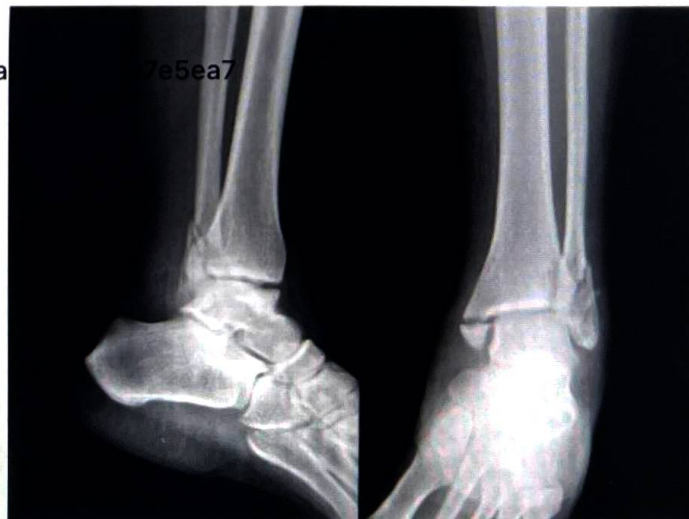Bimalleolar fracture/pott's fracture :
medial + Lateral malleolar fracture.



Trimalleolar fracture/Cotton's fracture : medial + Lateral +
Posterior malleolar fracture.

60c6b3eeaa

7e5ea7



Anterior inferior tibio
fibular ligament :

It attaches to bony
ridges :

On fibula : Lefort
Wagstaffe
tubercle.

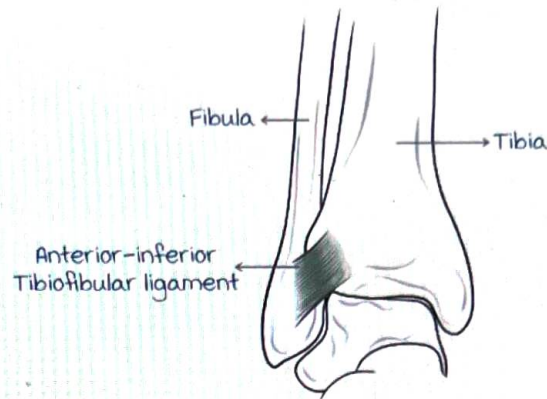
On tibia : Tillaux chaput
tubercle.

upon forces acting on ankle,
Anterior inferior tibio fibular
ligament gets torn in it's substance.

Get avulsed from :

Tibial tubercle : Tillaux chaput fracture.

Fibular tubercle : Lefort Wagstaffe fracture.



Ankle Sprain

00:15:08

Sprain usually occurs due to inversion of the foot and cause stretching of lateral ligaments.

most common ligament injured in body : **Anterior talofibular ligament.**

Rarely eversion of foot can cause stretching of medial ligaments. kumarankitindia1@gmail.com

Ottawa ankle rules :

An ankle X-ray series is only required if there is any pain in the malleolar zone and

Bone tenderness at the lateral malleolus or medial malleolus.

Or

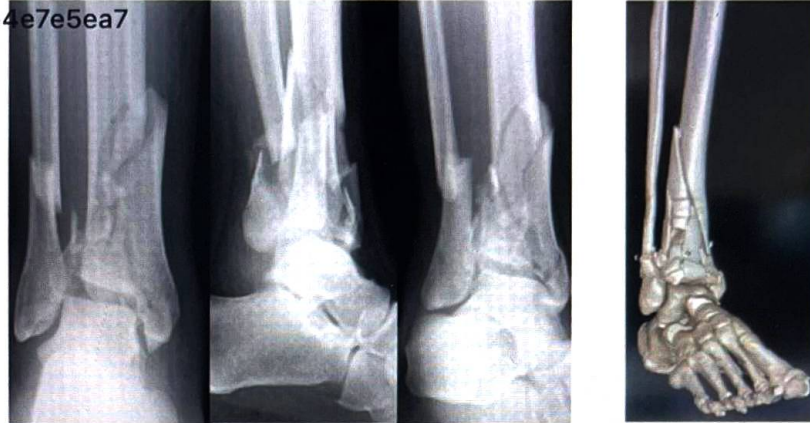An inability to bear weight both immediately and in the emergency department for four steps.

Pilon/Plafond/Ceiling fracture

00:21:38

Ceiling of ankle joint is at the distal end of the tibia.
 Fracture is caused due to axial loading/a fall from height.
 The talus forces into the distal end of tibia causing fracture.

60c6b3eaa8ded0e4e7e5ea7



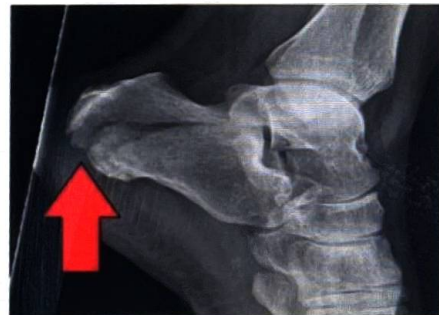Comminuted fracture of distal end of tibia.

Calcaneum fractures :

usually occurs due to fall from height.

most commonly fractured tarsal bone : Calcaneum.

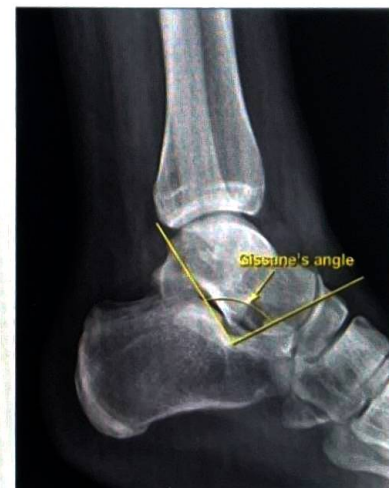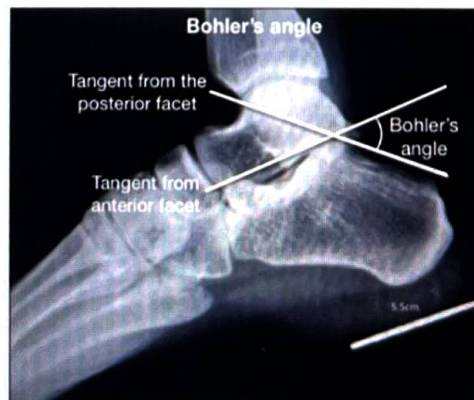
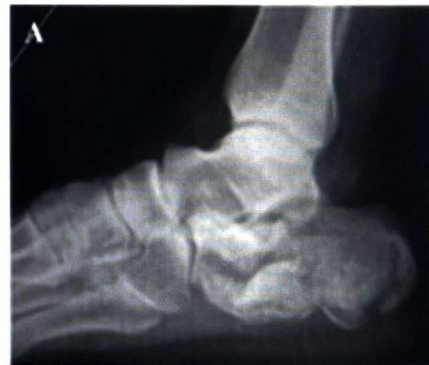most commonly dislocated tarsal bone : Talus.



In calcaneum fractures :

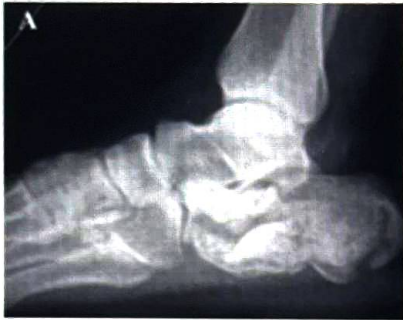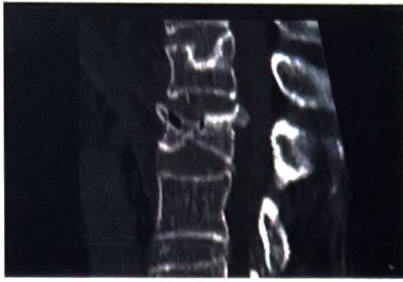Bohler's angle is reduced.

Gissane's angle is increased.



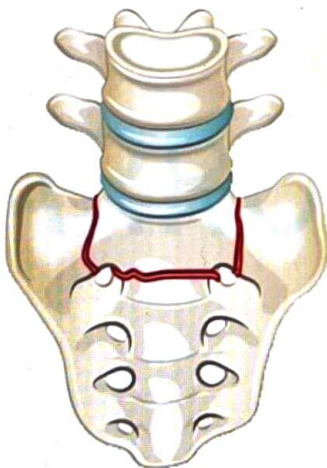
Active space

Lover's fracture : Bilateral calcaneum fracture with vertebral compression. fracture.

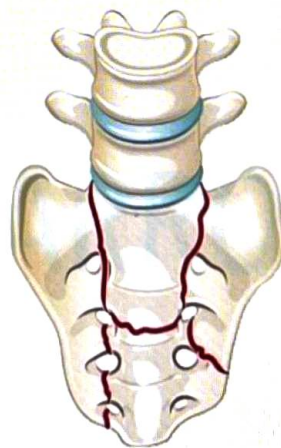


Caused due to fall from height and land on feet.

Jumper's fracture : Sacral U or H Shaped fractures seen in suicide jumpers.



u shaped fracture



H shaped fracture

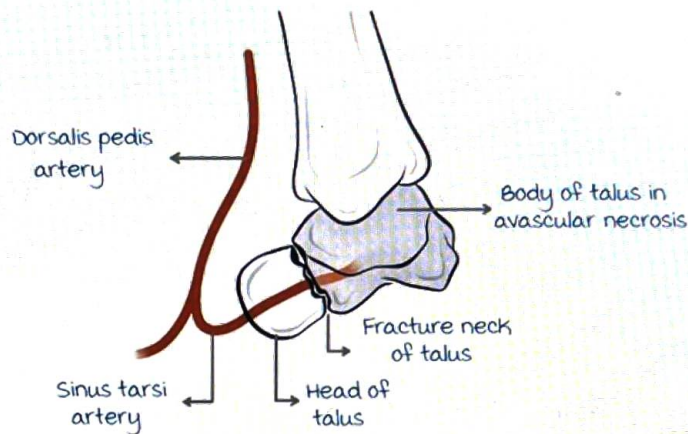
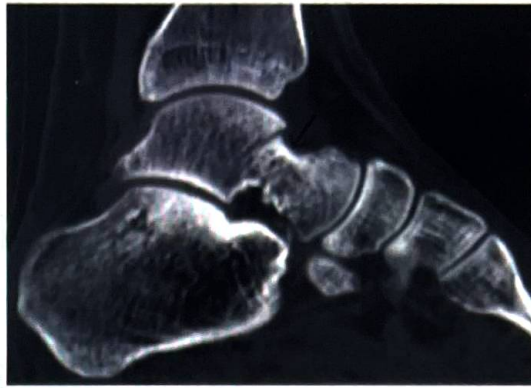Talus fracture

00:23:33

Blood supply of talus :
Dorsalis pedis.

Sinus tarsi artery : Goes retrograde.
Hence fracture neck of the talus results in avascular necrosis of the body of the talus.

Active space



Aviator fracture : Fracture of the neck of the talus, Aviators/pilots who use parachute for emergency escape land with a significant force resulting in fracture of the neck of the talus.

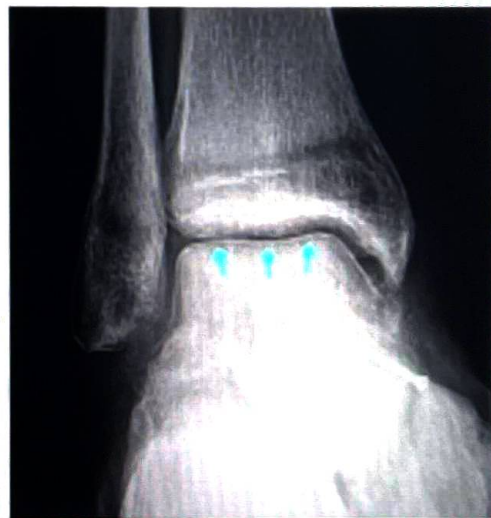most common complication : subtalar arthritis/avascular necrosis of body of talus (MRI for diagnosis).

Hawkin's sign on X-ray : Subchondral lucency suggests viability of talus.

If blood supply of the bone is good a live bone looks lucent on x-ray.

Dead bone is a dense bone/white on x-ray.

Because there is no blood, hyperemia, turnover or resorption of the bone.



Hawkin's sign was useful previously when MRI was not available. On repeated X-rays, viability of talus was detected by looking for subchondral lucency /Hawkin's sign.

Hawkin's classification of talar neck fractures :

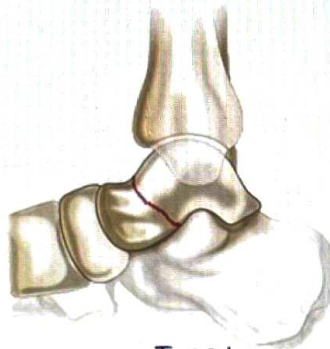
Type I : Undisplaced.

Type II : Subtalar dislocation.

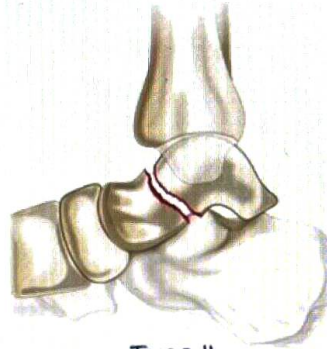
Type III : Subtalar and tibiotalar dislocation.

kumarankitindia1@gmail.com

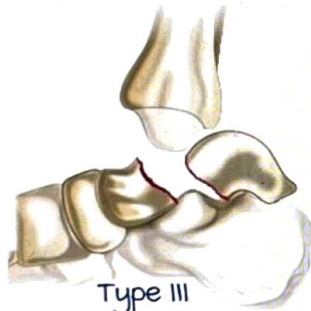
Type IV Subtalar, tibiotalar, and talonavicular dislocation.



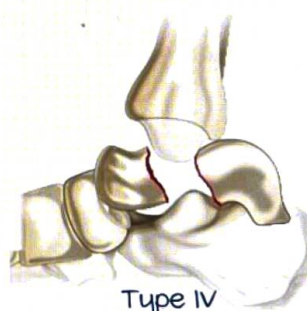
Type I
undisplaced fracture



Type II
Subtalar dislocation



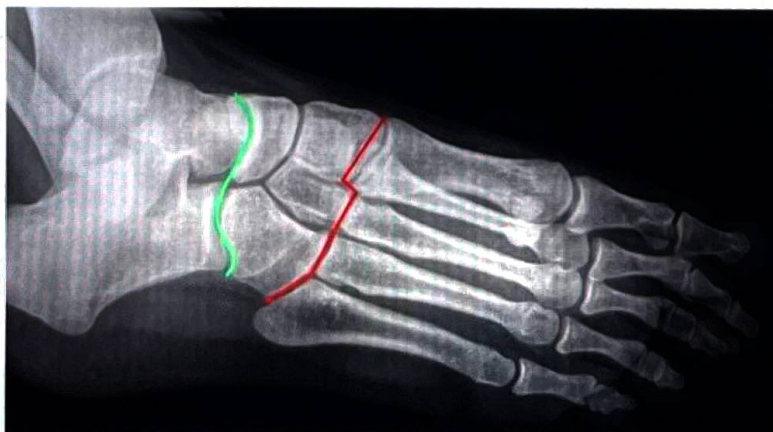Type III
Subtalar & tibiotalar
dislocation



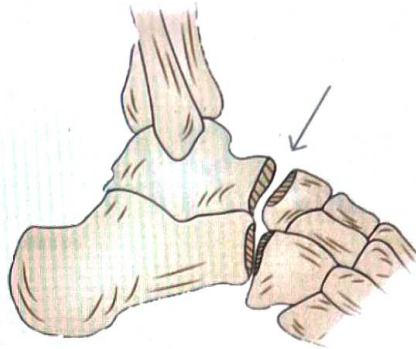
Type IV
Subtalar, tibiotalar
& talonavicular dislocation

Chopart's fracture : Intertarsal fracture between talus and navicular, calcaneum and cuboid.

Lisfranc's fracture : Tarsometatarsal fracture between tarsal and metatarsal bones.



Chopart's fracture : Fracture of intertarsal joint.



kumarankitindia1@gmail.com

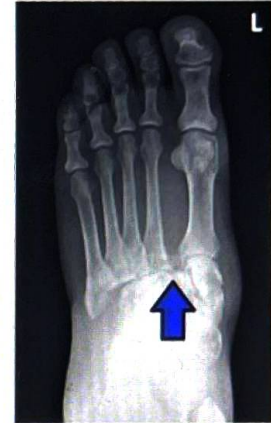Lisfranc fracture :

Increased gap between 1st and 2nd metatarsal.

Fleck sign :

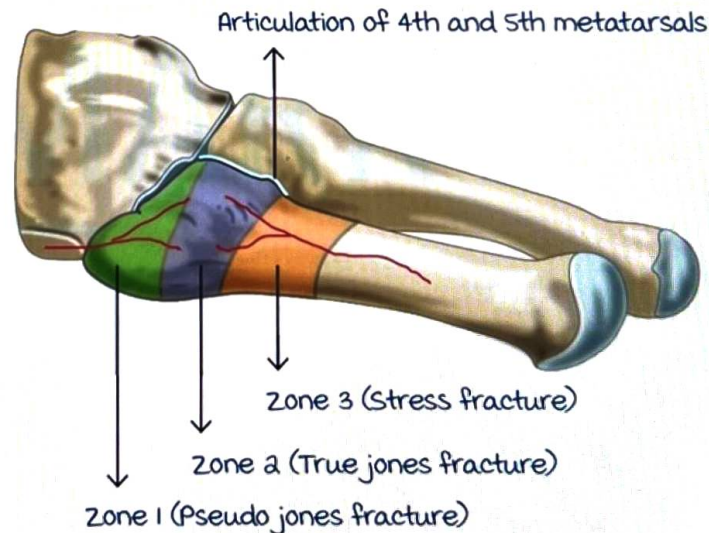
Injury to lisfranc ligament :

Holds 1st and 2nd metatarsal bones together.



Robert Jones fracture :

Fracture at the metaphyseal-diaphyseal junction of the 5th metatarsal at the level of the 4th-5th intermetatarsal articulation.



Zone 2 : Decreased blood supply, it is in watershed zone.

Fracture in this area usually results in non-union.

Peroneus brevis tendon attaches to the base of 5th metatarsal causing avulsion fracture.

Q. The most serious complication of a pelvis fracture is ?

- A. Neurogenic shock.
- B. Hypovolemic shock.
- C. Rupture of urinary bladder.
- D. malunion.

Answer : B. Hypovolemic shock.

Pelvic fracture results in loss of 1.5 to 2L of blood (4 to 8 units).

Q. Jumpers fracture & open book injuries are seen in ?

- A. Forearm
- B. Pelvis
- C. Femur
- D. Humerus

Answer : B. Pelvis.

Sacral U or H Shaped fractures seen in suicide jumpers.

Q. All of the following areas are commonly involved sites in pelvic fracture except ?

- A. Pubic rami
- B. Alae of ileum
- C. Acetabula
- D. Ischial tuberosities

Answer : D. Ischial tuberosities : Occurs rarely.

Q. main blood supply to the head of femur comes from ?

- A. Lateral circumflex femoral artery
- B. medial circumflex femoral artery
- C. Artery of ligamentum teres
- D. Popliteal artery

Answer : B. medial circumflex femoral artery

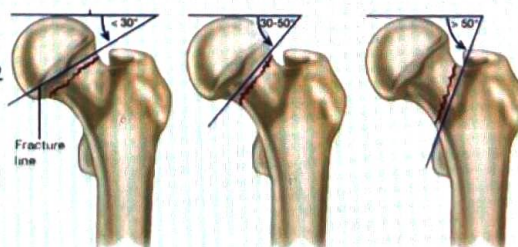
Q. True about Pauwels angle is all except ?

A. Between fracture line of femoral neck and horizontal plane

B. Increased angle indicates more chances of displacement

C. Grade I is 30°

D. Increase in angle



indicates impaction and good prognosis

Answer : D. Increase in angle indicates impaction and good prognosis.

more the angle, more vertical & unstable is the fracture.

Q. Which of the following describes grade 2 fracture neck femur ?

- A. Incomplete fracture, medial trabeculae intact
- B. Complete fracture with undisplaced neck
- C. Complete fracture with ischemic head
- D. Moderate displacement of neck, vascularity damaged

Answer : B. Complete fracture with undisplaced neck.

Q. Fracture neck of femur causes which of the following ?

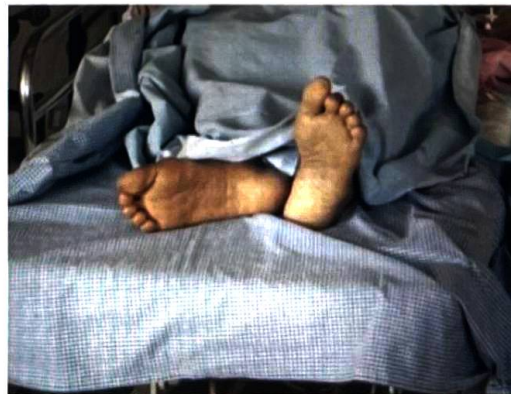- A. Flexion at hip and lateral rotation
- B. Flexion at hip abduction
- C. Shortening and lateral rotation
- D. Shortening and flexion

Answer : C. Shortening and lateral rotation

Q. A 60 yr old man fell in bathroom and was unable to stand. Ecchymosis noted on right buttock region with external rotation of the lower limb & foot touching the bed. What is the most probable diagnosis ?

- A. Extra capsular fracture neck of femur
- B. Anterior dislocation of hip
- C. Intracapsular fracture neck of femur
- D. Posterior dislocation of hip

Answer : A. Extra capsular fracture neck of femur.



Q. An old lady had a history of fall in bathroom and couldn't move. Her leg was in external rotation. There was tenderness

in scarpas triangle and limb movement could not be done due to pain. No hip fracture was noted on x-ray. What is the next step in her management ?

- A. MRI of hip
- B. Repeat x-ray hip after 1 week
- C. Hip Joint aspiration
- D. Give analgesic and ask her to review after 1 week

Answer : A. MRI of hip.

Q. All of the following can occur as complications of fracture of neck of femur except ?

- A. Shortening
- B. Non-union
- C. Mal-union
- D. Avascular necrosis

Answer : C. Mal-union.

Q. Treatment of choice for a 1 week old fracture neck femur at 65 yrs age is ?

- A. Hemi-replacement arthroplasty
- B. Closed reduction and internal fixation by cannulated cancellous screws
- C. Closed reduction and internal fixation by Austin more pins
- D. Total hip replacement

Answer : A. Hemi-replacement arthroplasty.

Q. Femoral neck fracture of 4 weeks duration in an young adult should be best treated by which one of the following ?

- A. Total hip replacement
- B. Prosthetic replacement of femoral head
- C. Reduction of fracture and multiple screw fixation
- D. Upper femoral displacement osteotomy

Answer : D. Upper femoral displacement osteotomy

Q. A 65 year old lady presents with a 1 week old fracture neck femur, she is a known case of Bilateral osteoarthritis of hip. What is the best treatment option for her ?

- A. Hemi-replacement arthroplasty
- B. Closed reduction and internal fixation by cannulated cancellous screws

C. Closed reduction and internal fixation by Austin more pins

D. Total hip replacement

Answer : D. Total hip replacement.

Q. mc murray's osteotomy is done for ?

A. malunited intertrochanteric fracture of femur

B. Nonunion transcervical neck fracture of femur

C. Nonunion lateral condyle fracture of humerus

D. malunited supracondylar fracture of humerus

Answer : B. Nonunion transcervical neck fracture of femur.

malunited supracondylar fracture :

malunion : Gunstock deformity.

modified french osteotomy is done.

Q. All are true regarding dislocation of hip except :

A. Posterior dislocation of hip (PDH) is commonest.

B. In PDH the limb is in flexion, adduction and medial (internal) rotation.

C. Sciatic palsy and vascular sign of Narath are noticed in PDH.

D. PDH is commonly managed by open reduction under GA

Answer : D. PDH is commonly managed by open reduction under GA

Q. Trendelenburg test or sign is positive due to injury of ?

A. Superior gluteal nerve

B. Inferior gluteal nerve

C. Obturator nerve

D. Tibial nerve

Answer : A. Superior gluteal nerve. It supplies gluteus medius minimus which is the principal abductor of thigh.

Q. A 30yr old man met with a road traffic accident and sustained femoral shaft fracture. Two days later he becomes mildly confused, develops fever, restlessness, tachypnoea & petechial rash. His chest x-ray shows widespread snow storm mottling throughout the lung. The most likely diagnosis is?

A. Chest contusion with haemothorax

B. Sepsis syndrome

- C. Pulmonary thromboembolism
- D. Fat embolism

Answer : D. Fat embolism.

Q. The classical example of muscular violence is ?

- A. Fracture of fibula
- B. Fracture of patella
- C. Fracture of clavicle
- D. All of these

Answer : B. Fracture of patella.

Treatment : Tension band wiring.

Q. Transverse fracture of the patella with displacement of fragments is best treated by ?

- A. Closed reduction with cylinder cast
- B. Open reduction & internal fixation of fragments
- C. Closed reduction & internal fixation with Kirschner wire
- D. Open reduction & internal fixation with Kirschner wire by tension band technique

Answer : D. Open reduction & internal fixation with Kirschner wire by tension band technique.

Q. What is the usual mechanism of injury of lateral condyle of proximal tibia ?

- A. Strain of valgus knee
- B. Strain of varus knee
- C. Strain of valgus knee with axial loading
- D. Rotational injury.

Answer : C. Strain of valgus knee with axial loading
medial collateral ligament is torn due to valgus force.

Q. The most commonly affected component of the lateral collateral ligament complex in an ankle sprain is ?

- A. Middle component
- B. Anterior component
- C. Posterior component
- D. Deeper component

Answer : B. Anterior component.

Q. True about eponymous fractures are all except ?

A. Monteggia fracture is fracture of the proximal third of ulna with radial head dislocation

kumarankitindia1@gmail.com B. Galeazzi fracture is fracture of the distal third of the

radius with dislocation of the distal radio ulnar joint

C. Colles fracture is fracture at cortico-cancellous junction of the distal end of radius with dorsal tilt

D. Potts fracture trimalleolar ankle fracture.

E. Bennets fracture is oblique intra articular fracture of the base of the 1st metacarpal.

Answer : D. Potts fracture trimalleolar ankle fracture.

Q. Which of the following is a false statement ?

A. Cotton's fracture is trimalleolar

B. Pott's fracture involve both malleoli

C. Lisfranc's is tarsometatarsal dislocation

D. Jefferson's is C2 fracture.

Answer : D. Jefferson's is C2 fracture.

Q. Pilon fracture is ?

A. Bimalleolar

B. trimalleolar

C. Distal femur intraarticular

D. Distal tibia intra articular

Answer : D. Distal tibia intra articular

Q. The attitude of the limb in Posterior dislocation of the hip joint is ?

A. Abduction, Flexion and External rotation

B. Abduction, Extension and Internal rotation

C. Adduction, Extension and Internal rotation

D. Adduction, Flexion and Internal rotation

Answer : D. Adduction, Flexion and Internal rotation.

Q. In the figure given below, the abnormality can be explained by weakness of

A. Side 2 gluteus medius

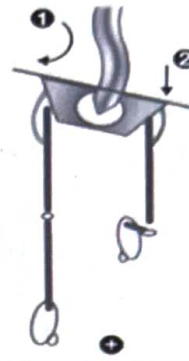
B. Side 2 gluteus maximus

C. Side 1 gluteus medius

D. Side 1 gluteus maximus

Answer : C. Side 1 gluteus medius.

Side 2 or sound side is sinking. Hence side 1 is the positive pathological side with weakness of Gluteus medius. Patient lurches towards side 1.



Q. What is the likely diagnosis of the injury to the left lower limb?

- A. Posterior dislocation of hip
- B. Anterior dislocation of hip
- C. Fracture shaft of femur
- D. Fracture neck of femur

Answer :

A. Posterior dislocation of hip.

Attitude of leg : Flexion, adduction and internal rotation.



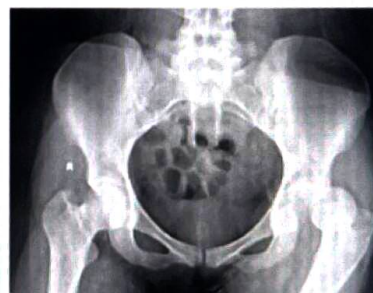Q. A patient was brought to the hospital with complaints of pain around the left hip joint following a road traffic accident. On examination, the affected limb was flexed, adducted and medially rotated with obvious shortening. What is the most likely diagnosis?

- A. Anterior dislocation of hip
- B. Posterior dislocation
- C. Transcervical fracture
- D. Intertrochanteric fracture

Answer : B. Posterior dislocation.

Q. A 15-year-old boy was brought to the ER following a motor vehicle collision complaining of pain over the hip. The x-ray is given below. What is the next step of management?

- A. Closed reduction and assessment of hip stability
- B. CT and 3D reconstruction
- C. High weight skeletal traction
- D. Open reduction and Posterior pillar of acetabulum reconstruction.



Answer : A. Closed reduction and assessment of hip stability.

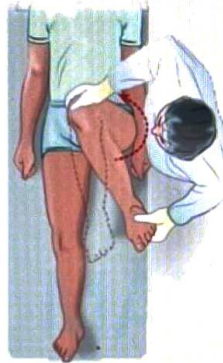
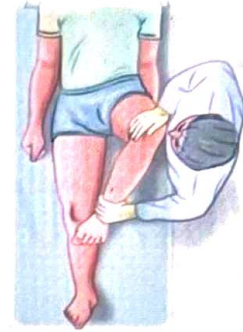Shenton's line is broken near in left side, showing adduction and internal rotation. Hence it is posterior dislocation of hip.

Q. Which of the position of hip is being tested in the picture given below ?

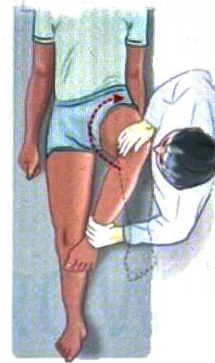- A. Internal rotation
- B. External rotation
- C. Abduction
- D. Flexion

Answer : B. External rotation

Examiner after flexing the knee is turning the leg in meaning he's testing for external rotation.



Internal rotation



External rotation

kumarankitindia1@gmail.com

SPORTS INJURIES

Sports injuries are usually low-velocity injuries.

Can be strain (tendon) or sprain (ligament).

MC injured tendon in the body →

Supraspinatus >> Tendo achilles.

MC injury → Ankle sprain.

MC injured ligament → Anterior talofibular ligament.

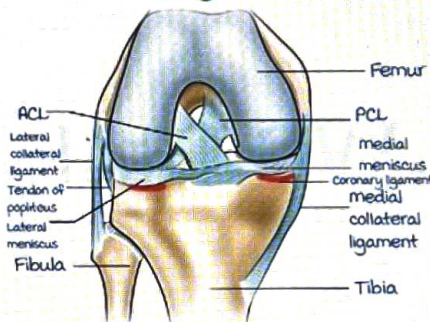
Knee

00:01:26

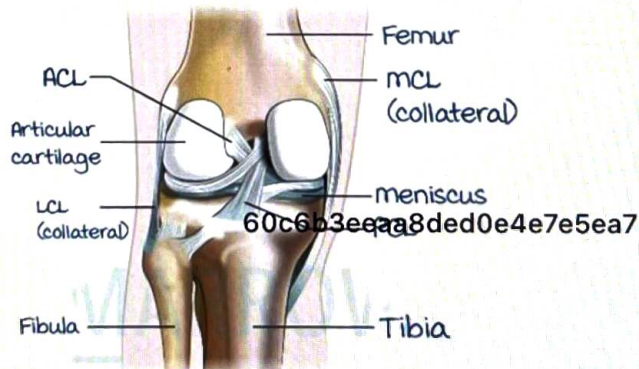
Ligaments around knee joint :

- medial collateral ligament /tibial collateral ligament (starting from medial condyle of femur & attaching to medial condyle of tibia).

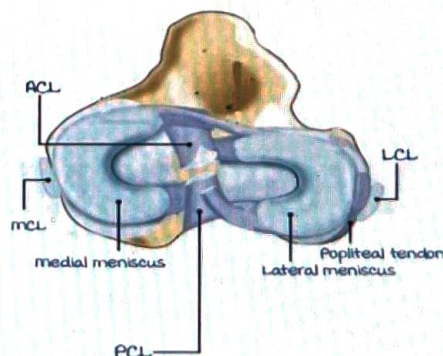
MCL is adherent to medial meniscus (more prone to injury).



- Lateral collateral ligament/fibular collateral ligament (starting from lateral epicondyle of femur & attaching to head of fibula).



Lateral meniscus is free.
Tendon of popliteus passes between lateral collateral ligament and lateral meniscus.

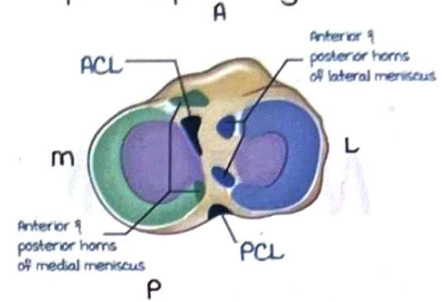


Active space

Both the menisci are attached to tibia by **coronary ligament**.

- ACL attaches to the **lateral condyle**.
Attaches to anterior tibial spine.

Superior aspect of right tibia



- PCL attaches to the **medial condyle**.
Attaches just behind articular surface of tibia.
Cruciate ligaments cross each other.

Collaterals are extracapsular structures.

menisci are intracapsular & intrasynovial structures.

Cruciates are intracapsular but extra synovial.

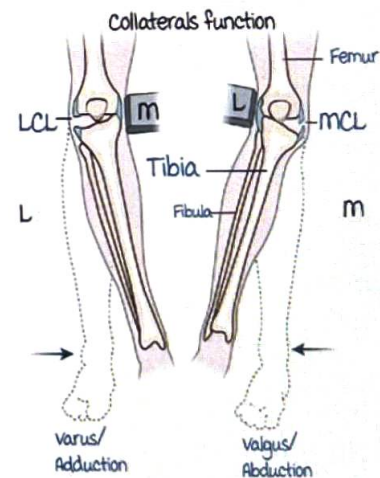
Collaterals

00:08:42

- MCL → **MC ligament injured** around knee.
- LCL.

Function

- Coronal plane stabiliser.
 - Prevent leg from going into varus and valgus deformity.
1. Resists varus & valgus force.
 2. Resist adduction and abduction force.



Menisci

00:11:22

Type I collagen.

Functions :

- Rotational plane stabiliser.
- Shock absorbers.
- Semi lunar structures keeping the knee stable to accommodate femur on tibia.

Injured on rotational force of the knee.

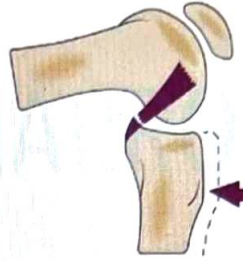
Cruciate

00:12:57

Functions : Sagittal plane stabiliser.

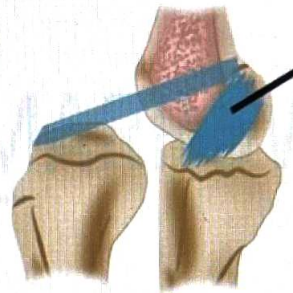
ACL :

- Prevent anterior translation of tibia.
- Prevent hyperextension of knee.



PCL :

- Prevent posterior translation of tibia.
- Prevent hyperflexion of knee.



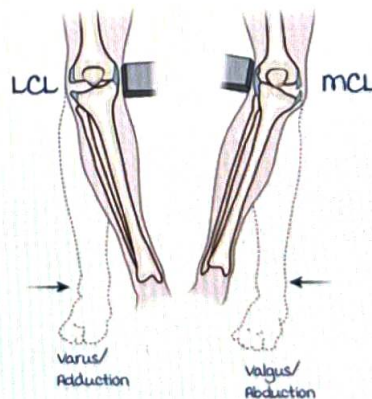
Group	Function	Structure	Injury force
Collateral ligaments	Coronal plane stabiliser. Varus/valgus plane.	medial collateral ligament	valgus force (Abduction)
		Lateral collateral ligament	Varus Force (Adduction)
meniscus	Rotational stabiliser. Shock absorbers.	medial meniscus	Rotational force/twisting injury/torsion force
		Lateral meniscus	
Cruciate ligaments	Sagittal plane stabiliser. Anterior/posterior plane.	Anterior cruciate ligament	Anterior translation/hyperextension of knee
		Posterior cruciate ligament	Posterior translation/hyperflexion of knee

mechanism of injury :

varus/valgus : Coronal plane force.

Twisting : Rotational force.

Flexion/extension : Sagittal plane force.



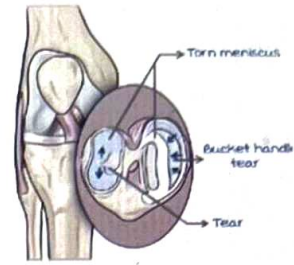
Active space

menisci :

Cushions of knee joint.

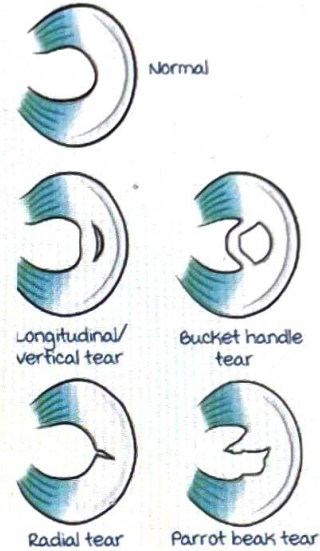
medial meniscus : more commonly injured.

MOI : Rotational/torsion/twisting of knee, when knee is flexed.



Clinical features :

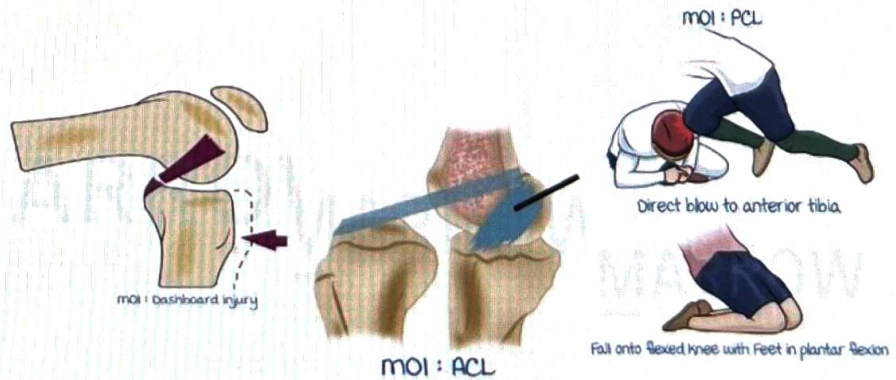
- Delayed effusion of knee : <15 to 20 ml of fluid : Bulge test.
- Pathological locking of knee or decrease of range of movements (ROM).
- Vertical tear progress into bucket handle tear (mc).

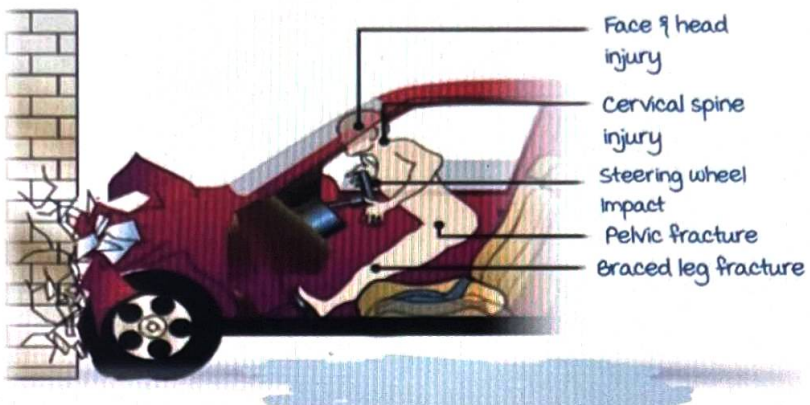


Cruciate ligaments :

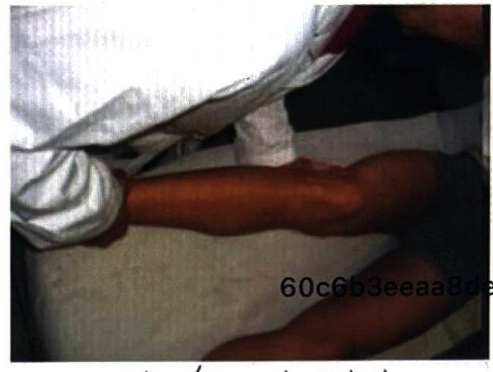ACL	PCL
	Thicker & longer
Prevents anterior translation of tibia	Prevents posterior translation of tibia (dashboard injury)
Prevents hyperextension of knee	Prevents hyperflexion of knee
Fracture of tibial eminence in intercondylar fracture of tibia	
Difficulty going downstairs	Difficulty going upstairs
Mid substance tear	Avulsion from bone (femur)

Active space





Clinical stress test :
 collaterals :
 valgus (MCL)/abduction
 & varus (LCL)/adduction
 stress test at 30° of flexion.



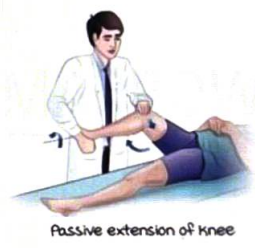valgus/varus stress test

menisci :

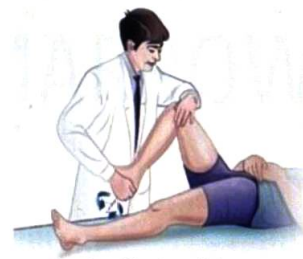mc murray's test : Pain/click on performing the test.

Apley's grinding test : Patient is prone with knee flexed to 90 degrees & ground on lower meniscus eliciting symptoms.

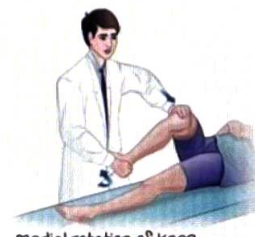
Thessaly test : Patient is made to stand on the injured knee slightly flexed & twist it to provoke the symptoms.



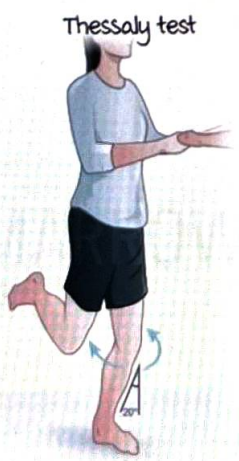Passive extension of knee



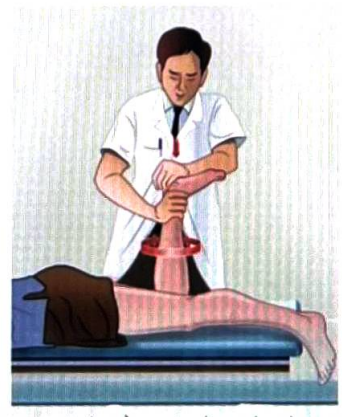
Passive flexion of knee



medial rotation of knee (Click heard in meniscal injury)



Thessaly test



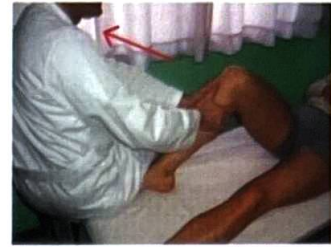Apley's grinding test

Active space

Edge's test : Joint line tenderness :

Best test.

Press the finger along the joint line eliciting a painful response from the patient.

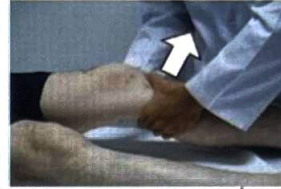

Anterior drawer test

Cruciates :

ACL :

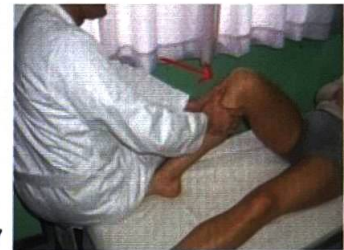1. Anterior drawer test:
Flex the knee at 90 degrees, slide 5-6 mm anterior glide.



Lachmann's test

Hamstring spasm : False negative.

2. Lachmann's test : Flex to 20 degrees.



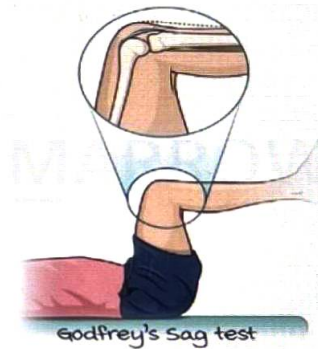
Posterior drawer test - PCL

No hamstring spasm → most sensitive/ best test.

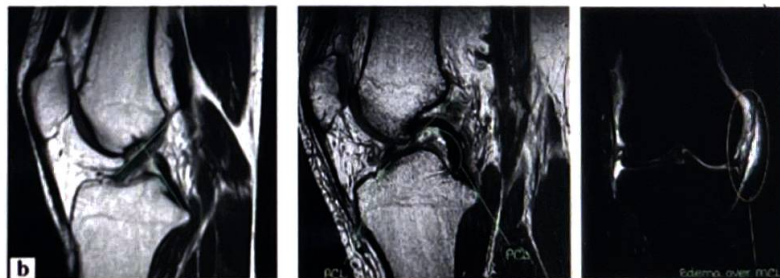
3. Pivot test (specific).
4. Lelli's test.

PCL :

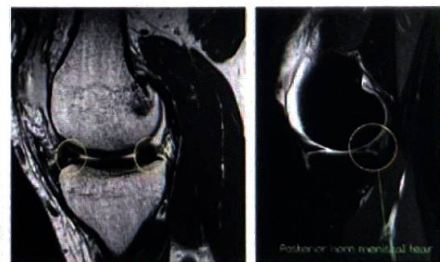
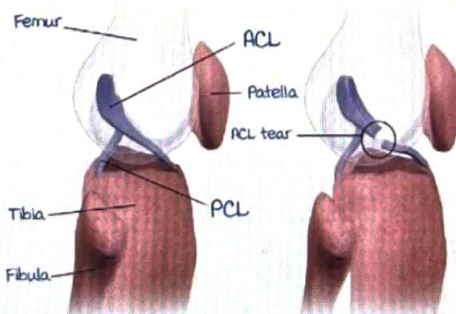
1. Posterior drawer test (PCL) : Flex the knee at 90 degrees, slide 5-6 mm posterior.



Godfrey's sag test




Cruciates kumarantia1@gmail.com Collaterals



menisci

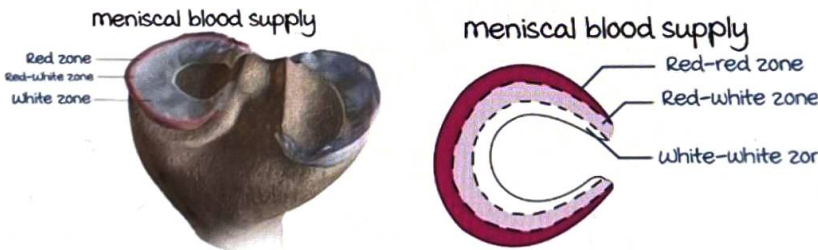
Active space

2. Godfrey's sag test : Both the hips & knees (bilaterally) will be flexed to 90 degrees , if PCL is torn, tibia will sag posteriorly.
3. Reverse pivot shift test.


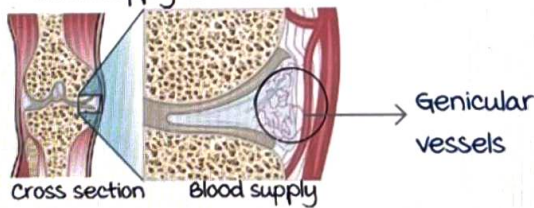


Investigation of choice for all ligament injuries : MRI.

- Collaterals : Edema over ligament suggestive of tear. No arthroscopy, as collaterals are extracapsular structures.
- menisci : Sagittal view. Gold standard is arthroscopy.
- Cruciates : Sagittal view. Gold standard is arthroscopy for intracapsular structures.



60c6b3eaa8ded0e4e7e5ea7 Blood supply to menisci



Active space

Treatment

00:33:37

Collaterals :

Conservative brace (90%).

Surgery only for 10% cases.

menisci :

Red zone/periferal part receives supply from genicular vessels (vascular zone) → If injured → Heals.

Repair : **meniscorrhaphy.**

White zone/central part receives nutrition from synovial fluid (avascular zone) → If injured → Doesn't heal.

Repair : **meniscectomy.**

Cruciates : Need Reconstruction.

Grafts :

1. Hamstrings : Semitendinosus, Gracillis.
2. Patellar tendon.

Arthroscope/portals

00:39:45

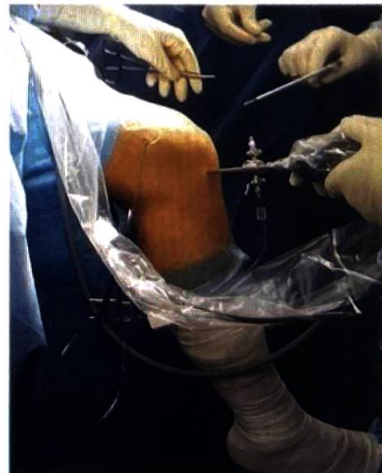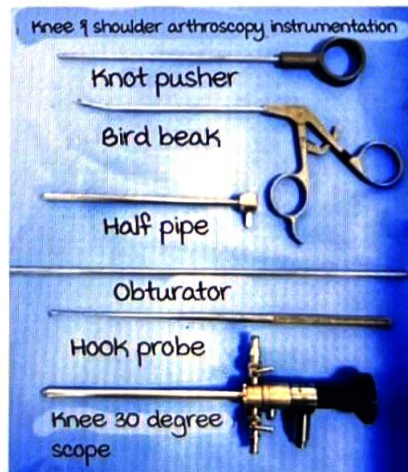
Knee :

Portals →

1. Antero-medial for instrumentation.
2. Antero-lateral for arthroscope.

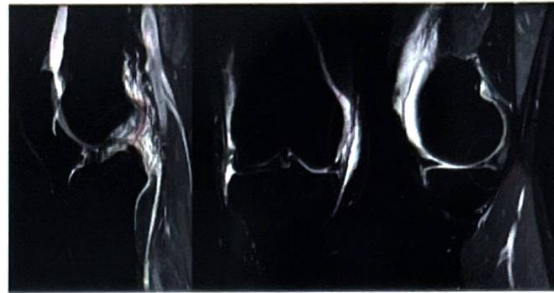
Arthroscope is the standard :

4 mm/30° scope.



ACL has 2 bundles :

1. Antero medial (Am) bundle : Stronger. Provides relative stability in **flexion**.
2. Postero lateral (PL) bundle : Weaker. more likely to be injured. Provides relative stability in **extension**.

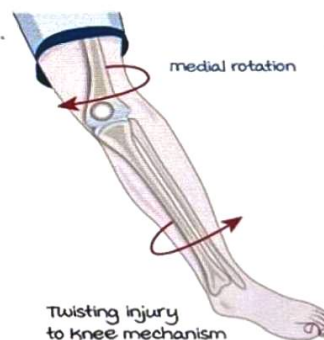
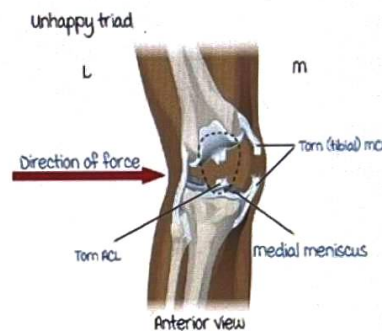


Antero-lateral rotatory instability
→ Injury to ACL + Anterolateral ligaments of knee → **Pivot shift test**.

Postero-lateral rotatory instability : Injury to PCL + Posterolateral ligaments (complex) of knee → **Dial test**.

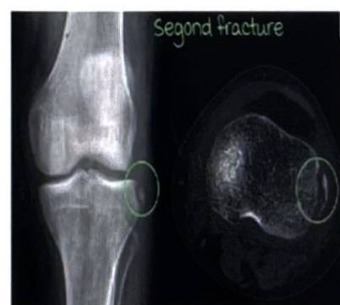Twisting injury to knee mechanism :

- Fixed leg on the ground
- Flexed knee.
- Internal rotation of femur.
- Tibia-valgus/abduction.



unhappy triad/O Donoghue triad/terrible triad/Painful triad due to twisting injury :

- medial meniscus (mc injured menisci).
- Anterior cruciate ligament (mc injured cruciate ligament).
- medial collateral ligament (mc injured ligament).



Second fracture :

Capsular avulsion in proximal lateral aspect of tibia (ACL).

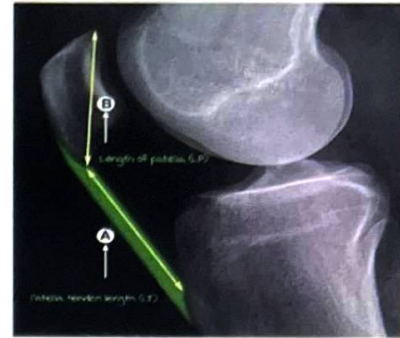
Insall-Salvati index :

This can be measured on a lateral knee x-ray, the knee is 30 degrees flexed.

Active space

A : Patellar tendon length (TL) :
Length from the lower pole of the patella to its insertion on the tibia.
B : Patellar length (PL) : Greatest pole - to - pole length.
Insall - Salvati ratio = A/B (or TL/PL).

Insall-salvati index of knee



The Insall-Salvati ratio (TL/PL) is normal between 0.8 - 1.2.

Patella baja \rightarrow < 0.8 (perhaps < 0.74)

Patella alta \rightarrow > 1.2 (perhaps > 1.5) : Recurrent patellar dislocation.

B \rightarrow Baja \rightarrow Below.

A \rightarrow Alta \rightarrow Above.

Clinical scenarios :

Q. Positive pivot shift test in knee is because of injury to

- Posterior cruciate ligament.
- Anterior Cruciate ligament. (most specific)
- medial collateral ligament.
- Posterior elbow ligament.

Lachman's test : most sensitive for ACL.

Q. What would be the most reliable & safest test for an acutely injured ACL in a knee of a 27 year old athlete?

- Anterior drawer test.
- Posterior drawer test.
- Lachman test.
- Steinmann test.

Q. Posterior cruciate ligament : True statement is

- Attached to the lateral femoral condyle.
- Intra synovial.
- Prevents posterior dislocation of tibia.
- Relaxed in full flexion & inserted on medial side of medial femoral condyle.

Explanation :

PCL is attached to the medial femoral condyle.
Intracapsular, extra-synovial.

Taut in full flexion & inserted on lateral side of medial femoral condyle.

Q. A 24 years old college student while playing hockey injured his right knee. This patient presents after 3 months with instability of knee joint in full extension without instability at 90 degree of flexion. The structure most commonly damaged is

- A. Posterolateral part of anterior cruciate ligament.
- B. Anteromedial part of anterior cruciate ligament.
- C. Posterior cruciate ligament.
- D. Anterior horn of medial meniscus.

Explanation : Anterior drawer test is negative but lachmann's test is positive.

Q. A twisting injury of knee in flexed position would result in injury to all except ?

- A. meniscal tear.
- B. Capsular tear.
- C. Anterior cruciate ligament.
- D. Fibular collateral ligament.

Q. Injury from lateral side of knee causes damage

- A. MCL.
- B. LCL.
- C. ACL.
- D. PCL.

Explanation : Lateral blow → valgus.

Q. Structural integrity of collateral ligaments are tested by :

- A. Varus/ valgus stress test in full flexion.
- B. Varus/ valgus stress test in full extension.
- C. Varus/ valgus stress test in 30 degree of flexion.
- D. Varus/ valgus stress test in 90 degree of flexion.

Q. A patient met with road traffic accident with subsequent injury to the left knee. Dial test was positive. What could be the cause

- A. medial collateral ligament injury.
- B. medial meniscal injury.
- C. Lateral meniscus tear.

D. Posterolateral corner injury.

Q. Which of the following statements about menisci is not true :

- A. Lateral meniscus covers more tibial articular surface than medial.
- B. Medial meniscus is more commonly injured than lateral.
- C. Menisci are predominantly made up of Type I collagen.
- D. Medial meniscus is more mobile than lateral.

Q. McMurray's test is positive in injury of :

- A. Anterior cruciate ligament.
- B. Posterior cruciate ligament.
- C. Medial meniscus injury.
- D. Popliteal bursitis.

Explanation : Joint line tenderness → Best test for medial meniscal injury.

Q. Which is the investigation of choice for a sport injury of the knee?

- A. Ultrasonography.
- B. Plain radiography.
- C. Arthrography.
- D. Arthroscopy.

Q. True regarding ligamentous injury of ankle is all except ?

- A. Ankle joint is the commonest site for ligamentous injury.
- B. Inversion of plantar flexed foot is the commonest mode.
- C. Anterior talofibular ligament is most commonly involved in ankle sprain.
- D. Posterior talofibular ligament is most commonly involved in ankle sprain.

Q. All are true about PCL except?

- A. It is extra synovial.
- B. Primary rotational stabilizer of knee.
- C. Originate from anterolateral aspect of medial condyle of femur in intercondylar region.
- D. Primary restraint to posterior movement of tibia.

Q. Insall-Salvati index is used for

- A. Olecranon.
- B. Patella.
- C. Talus.
- D. Scaphoid.

Q. In a case of a meniscal tear posted for repair, which of the following zones of meniscus shows best healing potential?

- A. Grey zone.
- B. White zone.
- C. Red zone.
- D. White + Red zone.

60c6b3eaa8ded0e4e7e5ea7

Active space

REGIONAL CONDITIONS

Cumulative injuries disorder

00:00:38

Repetitive minor trauma over time manifests as major condition.

For pain.

None of the conditions are same but always present with pain.

Pain exaggerated in one particular activity.

Example :

In Tennis elbow, extension of elbow leads to pain over lateral epicondyle.

In Golfer's elbow, flexion of elbow leads to pain over medial epicondyle.

Treatment is similar & includes :

Rest, immobilization, NSAIDs, physiotherapy, steroid injection or surgical intervention.

Frozen shoulder

00:02:26

AKA Adhesive capsulitis.

usually seen in diabetic with poor glycemic controls.

Capsulitis occurs → unknown cause but could be due to poor glycemic controls.

No bone involvement.

Inflammatory process causes fibroblastic proliferation of joint capsule.



Leading to thickening, fibrosis, and adherence of the capsule to itself and humerus .



Leads to Pain and restriction of all movements of the shoulder (global stiffness) : Active & Passive.

Restriction of movement present due to adhesion.

Usually, self limiting.

30 % is bilateral.

Associated Conditions :

- DM (Type 1 & 2).
- Thyroid disorders: Hypothyroidism or Hyperthyroidism.
- Hyperlipidemia.
- Cardiac problems.
- Hemiplegia (prolonged immobilization).
- Following Trauma or surgery to the shoulder.
- Idiopathic.

Stages :

- Pain (freezing stage) :
Increase in pain ; Night Pain.
- Stiffness (frozen stage)
Restriction of movement occurs.
Pain decreases, but stiffness increases.
- Resolution (thawing stage) :
movement regained (disease self limiting).
Pain & stiffness decreases.



60c6b3eaaa8ded0e4e7e5ea7

Diagnosis :

mainly clinical.

Suspect in diabetic.

No h/o trauma.

Restriction of movements :

Global → All movements.

Earliest movement restricted is rotation :

External > **Internal**.

Active & **passive** movement affected.

unilateral but later bilateral involvement.

X-rays : Normal (No bone involvement).

USG & MRI : **Detects capsulitis**.

management : Self resolving in few weeks to months.

Supportive : NSAIDs (for pain).

Physiotherapy : For maintaining movement.

Steroid injections :

Non-diabetics &

Diabetics with good glycemic control.

Use with caution in **diabetics** as it might **aggravate the glycemic level.**

Specific treatments if non-responsive.

manipulation under anesthesia (Adhesiolysis).

Arthroscopic capsular release :

Capsule is filled with fluid leading to lysis of adhesion (hydrotherapy).

Open capsular release.

Rotator cuff injuries

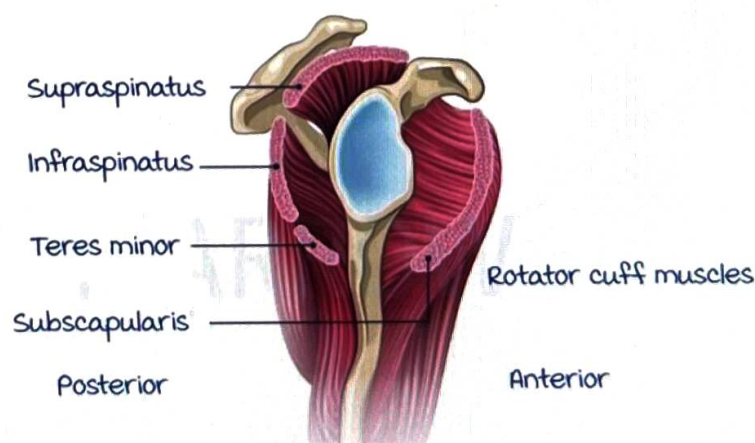
00:10:09

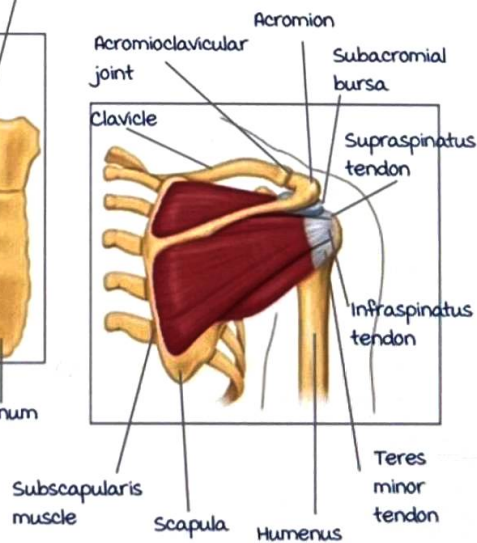
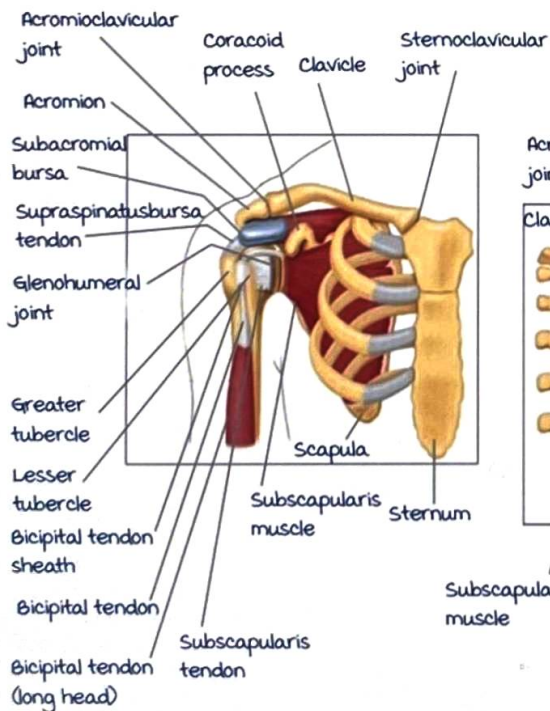
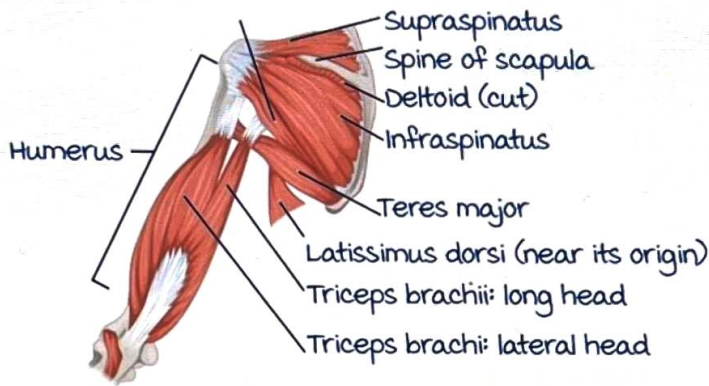
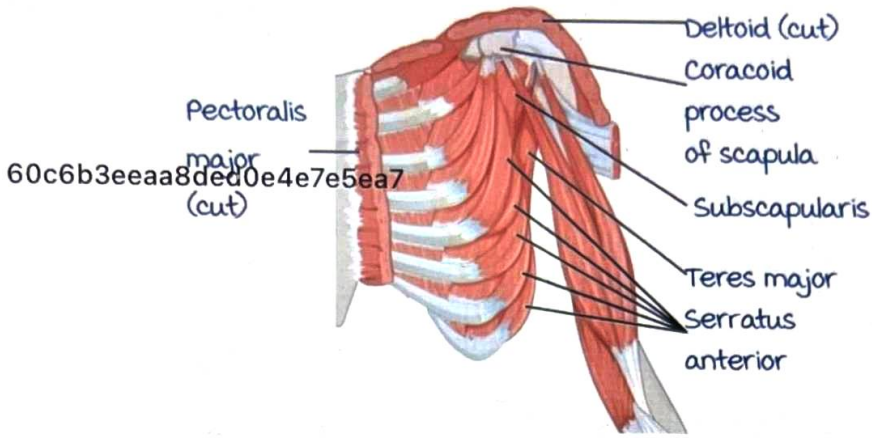
It includes :

Rotator cuff tear.

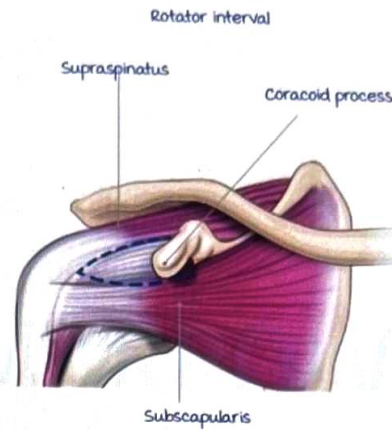
Impingement syndrome.

major muscles	Nerve supply	Actions (in shoulder)
Supraspinatus	Suprascapular nerve	Initiators of abduction
Infraspinatus	Suprascapular nerve	External rotation
Teres minor	Axillary nerve	External rotation
Subscapularis	upper & Lower Subscapular nerve	Internal rotation.



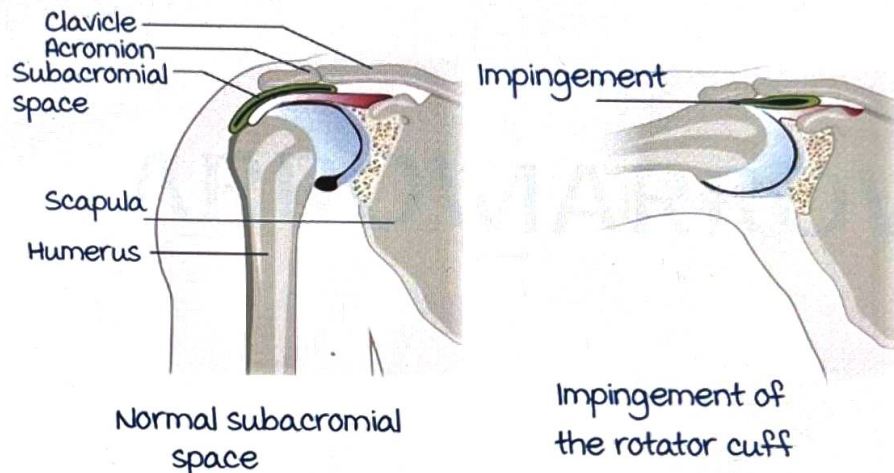


Active space



Impingement syndrome

00:12:27



60c6b3eaaa8ded0e4e7e5ea7

In predisposed patients :

Repetitive abductions.

Anatomical abnormality of acromion

On abduction of shoulder

↓
Inflammation of structures

↓
Pain is because of impingement of the rotator cuff muscle
Supra Spinatus between the acromion process and head of
humerus.

Structures under acromion :

Supraspinatus tendon → most important structure getting
impinged.

Sub acromial bursa.

Pathology :

Starts with sub acromial bursitis.

Inflammation leads to supraspinatus tendinitis.

Causes :

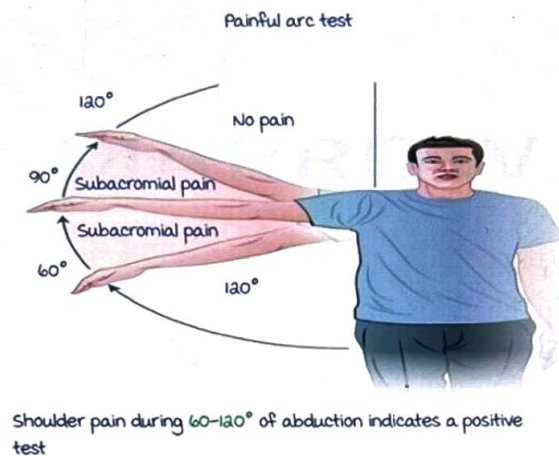
- **Supra spinatus tendonitis.**
- Calcification of Supra spinatus.
- Sub acromial bursitis.
- Abnormally shaped acromion.

Mid abduction pain:

0-15° : Supraspinatus tendon.

15-90° : Deltoid.

>90° : Serratus anterior + Trapezius.

**AKA Painful arc syndrome :**

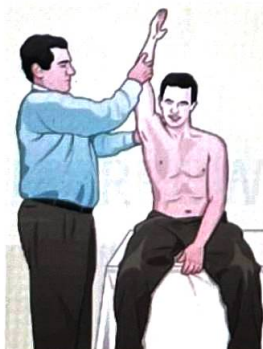On impingement maximal pain between 60-120° due to maximal compression in subacromial space (to supraspinatus tendon).

Diagnosis :

Clinically with provocative test.

Neer's impingement test :

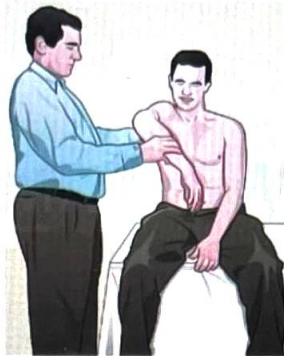Shoulder abducted so that head of acromion impinges. Passive elevation of the internally rotated arm in the sagittal plane (shoulder forward flexion).



Keeping the scapula stable, the affected arm is raised fully. In passive flexion, abduction, and internal rotation.

Hawkins' impingement test :

Flex elbow and press on wrist causing abduction.
with the elbow flexed to 90 degrees, the shoulder passively flexed to 90 degrees and internally rotated.



The affected arm is elevated 90 degrees in the scapular plane.
with the elbow in 90 degrees flexion.
The upper arm is then stabilized and rotated internally.

Treatment :**Conservative :**

Avoid painful and overhead activities.

Physiotherapy :

Stretching and range of motion exercises.

Strengthening exercises.

60c6b3eaa8ded0e4e7e5ea7

Medications : NSAIDs.

Intervention :

Steroid injection into the subacromial space : minimizes inflammation.

Arthroscopic subacromial decompression : Shave off part of acromion increasing the space.

Rotator cuff tear & RCT arthropathy

00:26:28

Rotator cuff (RC) tear, when unintervened, leads to **rotator cuff tear (RCT) arthropathy**.

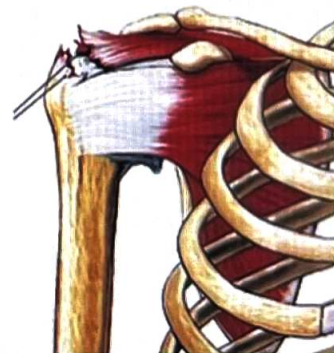
most common cause :

Young : Trauma.

Elderly (more common) : Degeneration.

MC injured tendon :

Supraspinatus (UL) > Tendo Achilles (LL).



Forgotten tendon of rotator cuff : Subscapularis.

Reason : It inserts to the lesser tuberosity & the other 3 RC muscles insert to the greater tuberosity.

Clinical features :

Shoulder pain.

Restriction of shoulder movement.

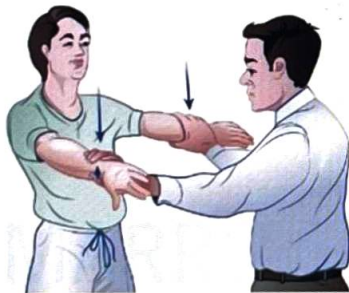Increased pain on movement against resistance.

Provocative tests :

major muscles	Nerve supply	Difficulty/pain in performing actions(in shoulder)	Test
Supraspinatus	Suprascapular nerve	Initiators of abduction	Beer can/Full can/ Empty can sign/ Jobe's Test
Infraspinatus	Suprascapular nerve	External rotation	Horn Blower's Test
Teres minor	Axillary nerve	External rotation	Horn Blower's Test
subscapularis	Upper & Lower Subscapular	Internal rotation.	Lift off, Belly press, Bear hug.

For supraspinatus :

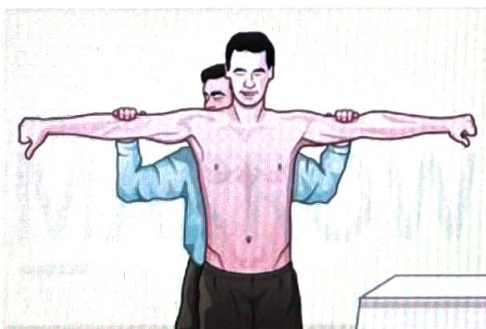
Beer can/empty can test :



The patient is asked to resist the downward force by the examiner when the arms are in the position of 90° abduction, 30° flexion, and complete internal rotation.

Pretend like emptying a can & abduct against resistance pain elicited suggests supraspinatus tendon affected.

Jobe's test : Abduct against resistance with thumb pointing downwards.

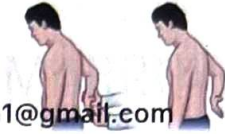

Arms elevated in the scapular plane, elbows extended with the thumb pointing downwards, while the examiner applies downward pressure.

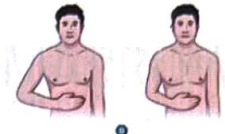For subscapularis : **Internal rotation against resistance.**

Lift off test

Patient asked to keep dorsum of hand on lower back & then lift it (further internal rotation).



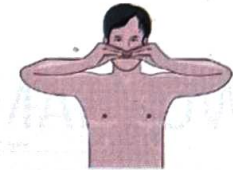Belly press : Pressing onto belly (self).



Bear hug : Bear hugging a person causes internal rotation of the shoulder.

For Infraspinatus & Teres minor :

Hornblower's test : Patient pretends to blow horn, pain elicited on doing so.



Treatment :

Avoid painful & overhead activities.

Physiotherapy.

NSAIDs.

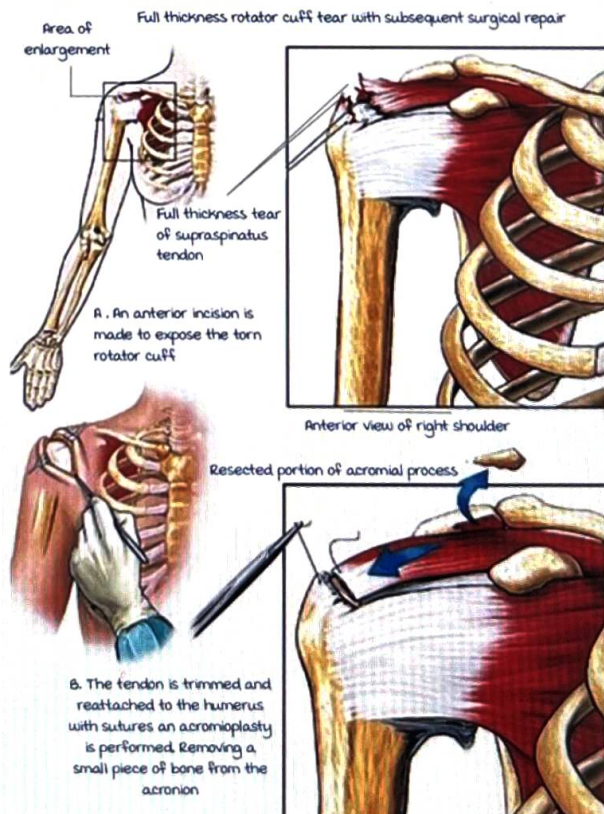
Steroid injection : Not advised as it can cause tendon rupture.

Arthroscopic repair if repairable.

Shoulder joint :

Stabilized by muscles like Deltoid & long head of biceps.

No bone stabilization. Hence, less stable & very mobile joint.



Active space

Rotator cuff tear arthropathy

00:38:20

Cause :

Neglected rotator cuff tear.

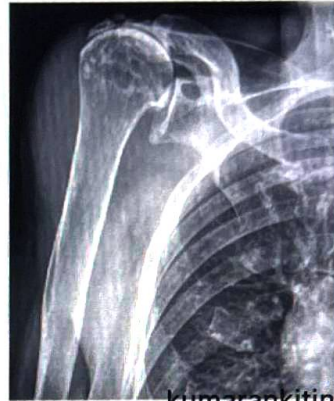If irreparable

Young patient

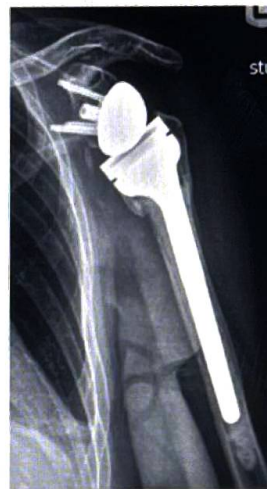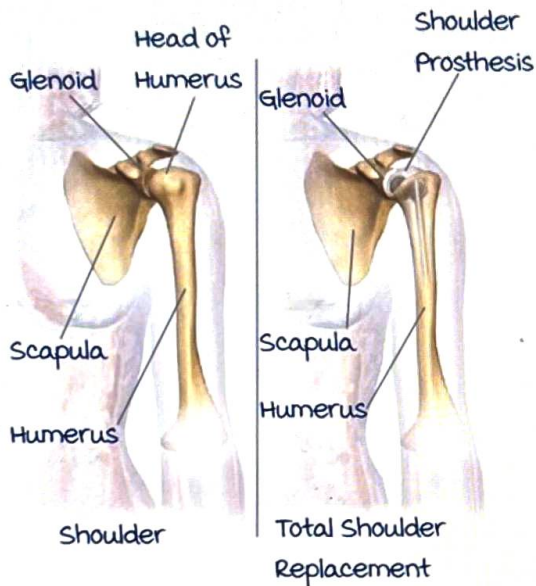
Elderly patient

Tendon transfer
(Latissimus dorsi)

Reverse shoulder
Arthroplasty



kumarankitindia1@gmail.com



Normal shoulder in arthroscopy :

Ball : Side of head of humerus &

Socket : Side of glenoid.

Reverse shoulder arthroscopy :

Ball : Side of glenoid.

Socket : Side of head of humerus.

Done to increase the length of deltoid.

This provides more power to the deltoid to compensate for the rotator cuff instability.

Shoulder instability effects :

Popeye sign :

A pronounced bulging muscle in the distal aspect of the biceps region of the arm.

Clinically apparent, with a complete long head of biceps region of the arm.

Active space

tendon tear causing distal migration of the long head of biceps muscle.

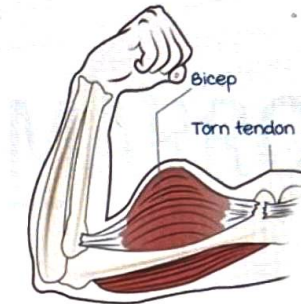
Long head of biceps tendon takes more weight.

60c6b3eeaa8ded0e4e7e5ea7

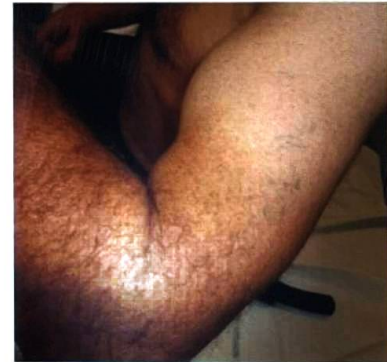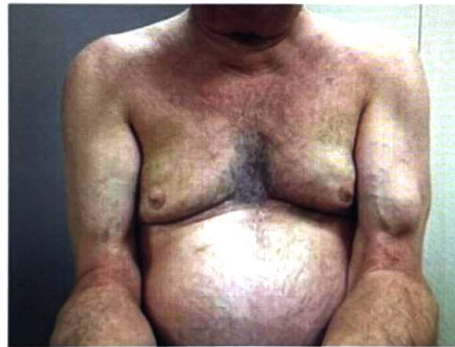Damage/degenerates long head of biceps tendon.

Rupture.

muscle will crumble & bulge.



Popeye sign



Injection of local anaesthetic agent :

Impingement syndrome	Rotator cuff tear & adhesive capsulitis
Pain decreases & range of motion increases.	No effect.

Impingement test :

Inject 10 mL of 1% lidocaine solution into subacromial space.

Repeat testing for an impingement sign.

Elimination or significant reduction of pain constitutes a positive impingement test.

Investigation of choice : MRI (as tendon involved).

Active space

Tennis elbow/ Lateral epicondylitis

00:45:03

Lateral epicondyle : Wrist extensors.
 medial epicondyle : Wrist flexors.

Tennis elbow : Cumulative trauma disorder.

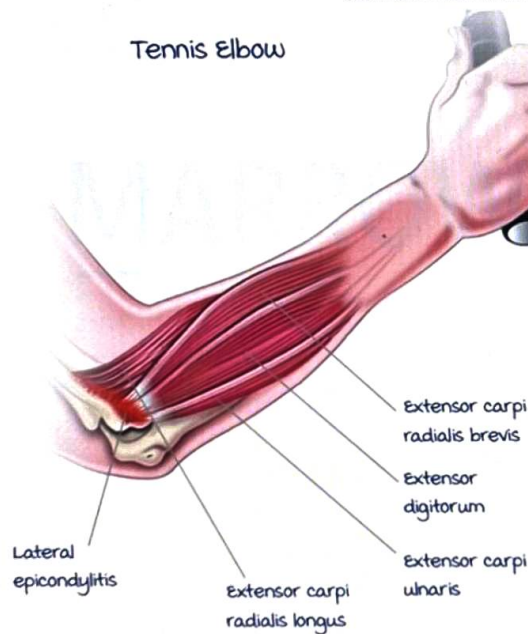
Due to frequent/chronic wrist extension.

Inflammation at the origin of wrist extensors causes pain at lateral epicondyle.

Seen in tennis players and people having wrist extension action in their work like carpenters, bike riders.



60c6b3eeaa8ded0e4e7e5ea7



Golfer elbow/Medial epicondylitis

00:47:33

Aka Swimmer's elbow.

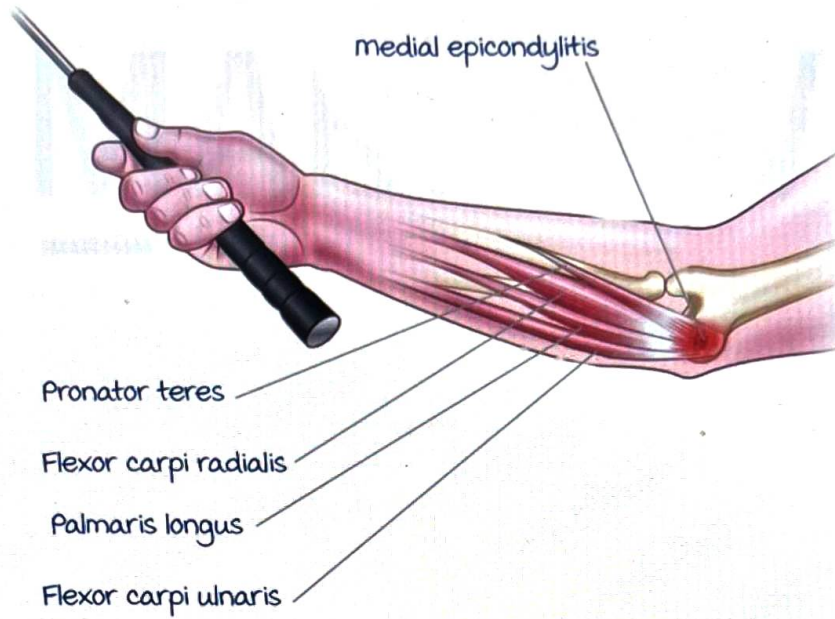
Pain at medial epicondyle due to repetitive injury (cumulative trauma disorder) to the wrist flexors.

Tennis elbow more common than golfers elbow.



Active space

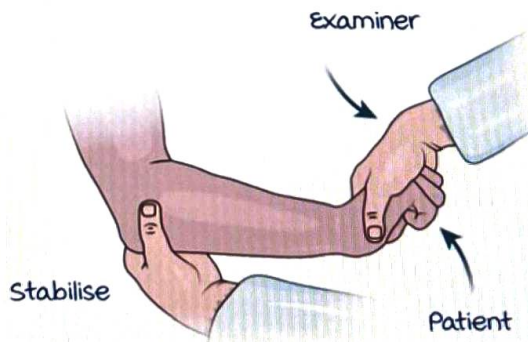
Golfer's elbow



Tennis elbow	Swimmers elbow
Common extensor origin.	Common flexor origin.
Extensor carpi Radialis Brevis (culprit muscle)	Flexor carpi Radialis (culprit muscle)
Cozen's test, maudsley's Test	Reverse Cozen's test.
Lateral epicondylitis	medial epicondylitis.

Cozen's test :

Extension of wrist against resistance → Extensors contract → Pain exaggerated at lateral epicondylitis.
 For diagnosis of Tennis elbow



Reverse Cozen's test :

Flexion of wrist against resistance → Flexors contract → Pain exaggerated at medial epicondylitis
 For diagnosis of Golfer's elbow.

Active space

Treatment :

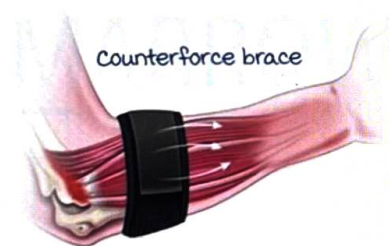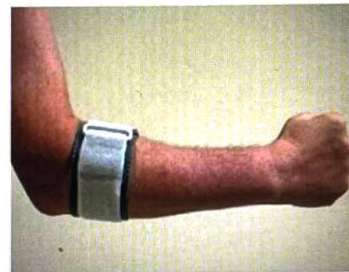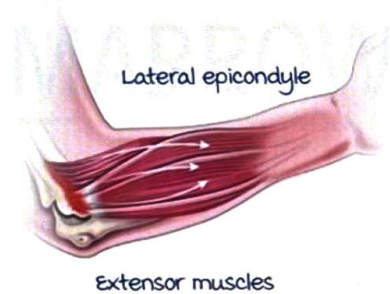
- Activity modification.
- Counter force braces :

Applied distal to lateral epicondyle which acts as new constriction band.

Prevents contraction of muscle reaching origin thereby relieving pain & providing time for healing.

Extensor muscles attach and pull on the lateral epicondyle, causing irritation and injury over time.

Counter force braces compress the extensor muscles, removing tension to prevent pulling on the lateral epicondyle.



60c6b3eaa8ded0e4e7e5ea7

- NSAIDs.
- Physiotherapy.
- Steroids.
- Debridement.
- Orthobiologics.
- Newer modalities : Helpful especially in tennis elbow.

Blood : Rich in all types of cells hence increase inflammation & healing.

Platelet Rich Plasma : WBC removed, hence only increases healing.

Stem cells : Helps in regeneration & healing.

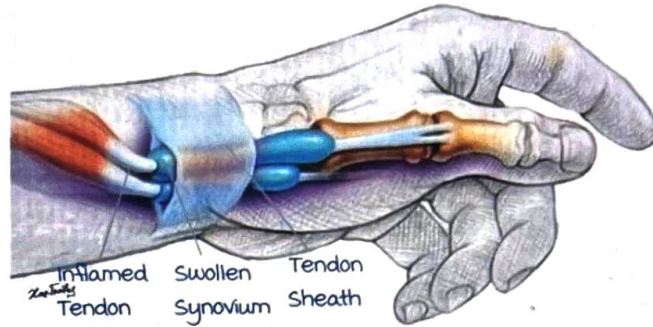
From adipose tissue, bone marrow, periosteum.

Active space

Dequervain's disease

00:55:39

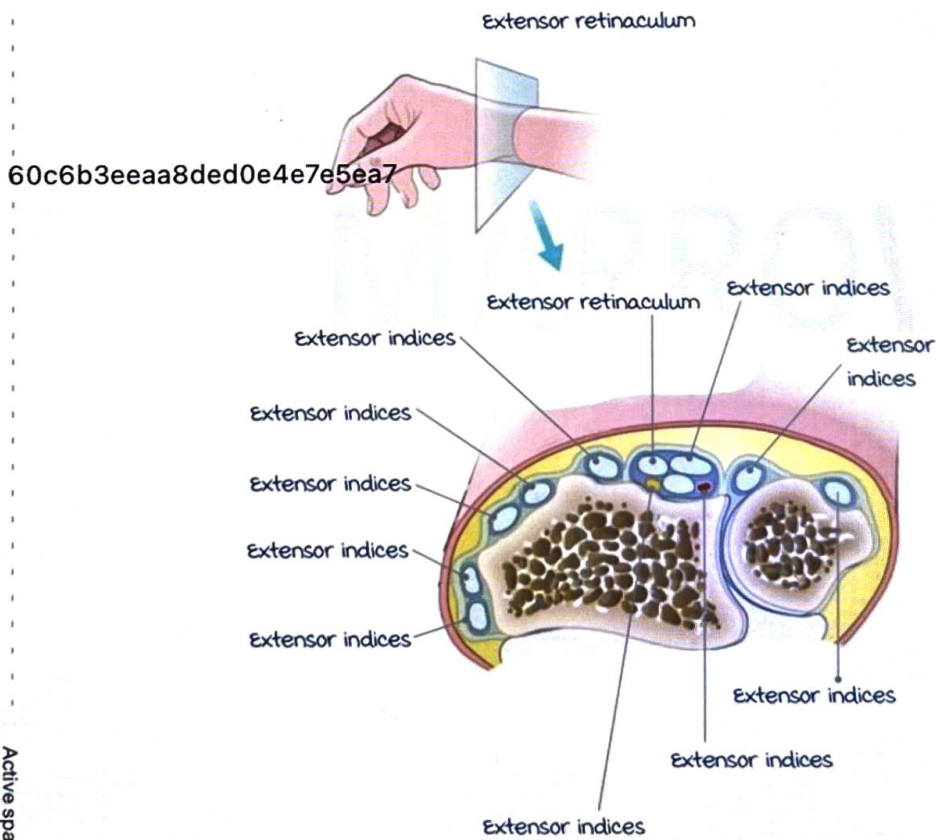
Stenosing tenosynovitis of abductor pollicis longus and extensor pollicis brevis at 1st Dorsal Compartment of wrist.



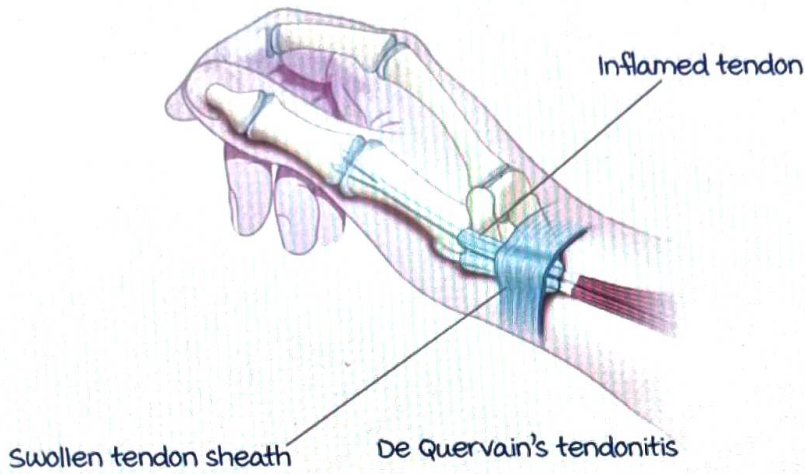
- Female > male
- Cause : Overuse, Rheumatoid Arthritis
- Test : Finkelstein's Test, Eichoff Test

Cumulative injury disorder.

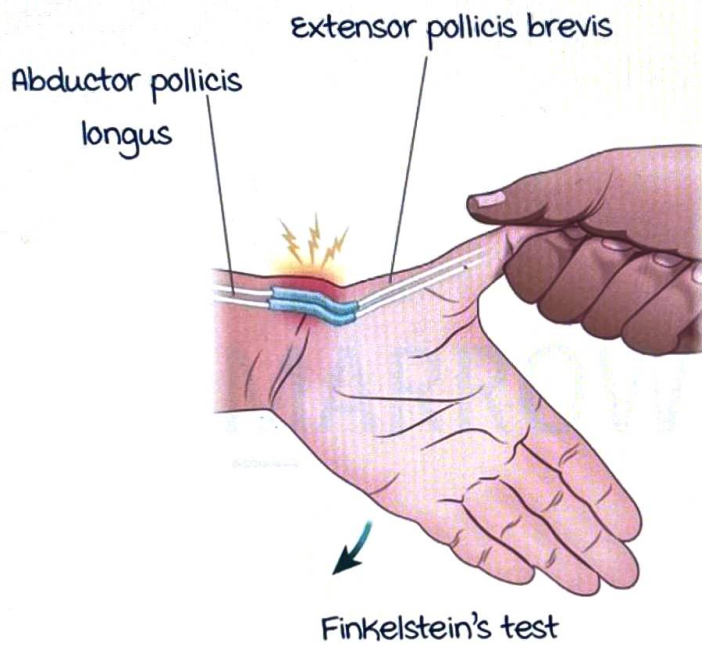
Stenosing tenosynovitis of Abductor Pollicis Longus & Extensor Pollicis Brevis tendons at 1st dorsal compartment of wrist .



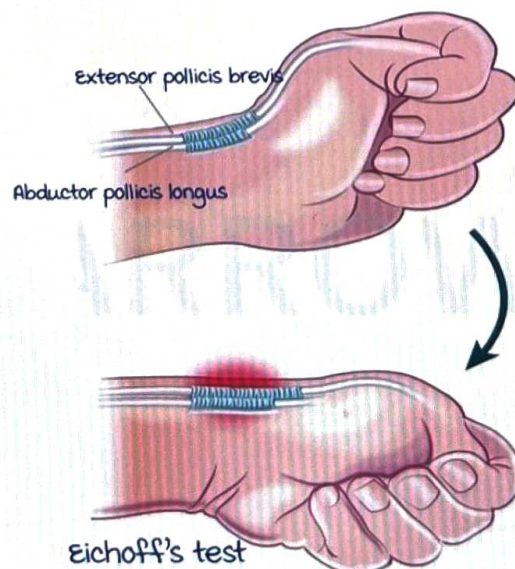
Active space



kumarankitindia1@gmail.com
Finkelstein's Test: Patient's thumb stretched and brought down.



Eichhoff's test: Thumb is kept in palm and fist closed in neutral position. Then deviate to ulnar, leads to severe pain.



Active space

Treatment :

Rest .

Immobilisation.

Physiotherapy.

NSAIDS.

Splint.

Steroid injection : Not advised as it can cause tendon rupture.

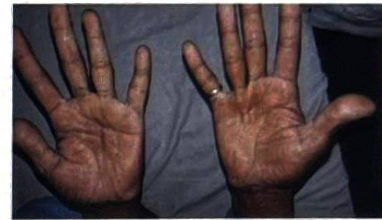Dupuytren's contracture

01:01:11

Idiopathic.

Not a cumulative injury disorder.

Abnormal fibrosis (Collagen 3) of palmar aponeurosis in the form of nodule / cord & finger starts to bend.



male > Female

Causes :

Idiopathic (mc).

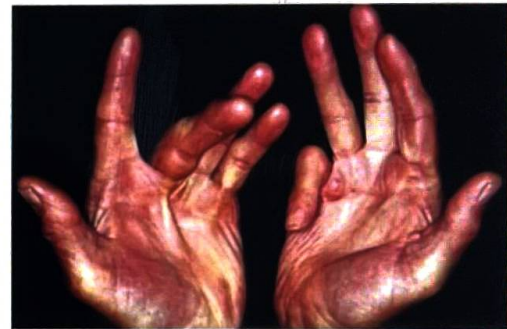Diabetes mellitus.

Alcoholics.

Idiopathic ::

CTEV/ TDH/

Carpel tunnel syndrome.



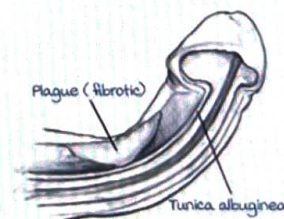
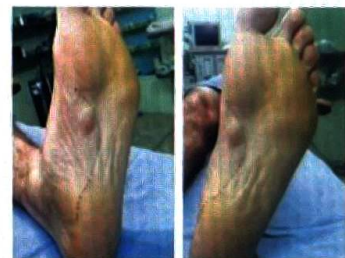mc finger involved : Ring finger.

mc joint involved : metacarpophalangeal joint.

Ectopic types :

Soles of feet : Ledderhose disease.

Penis : Peyronie's disease.



Diabetic cheiroarthropathy

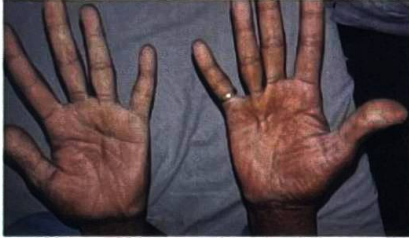01:49:36

Prayer sign.


Contractures in all fingers present.

Thickening of the skin.

Uncontrolled diabetes.



Dupuytren's contracture
(1/few fingers involved with
cause : idiopathic alcohol)



Diabetic Cheiroarthropathy
(uncontrolled diabetes)

Treatment :

Conservative.

To relieve contracture, collagenase used.

If significant contracture → Abnormal fascia removed.

If MCP contracture $> 30^\circ$ & PIP $> 15^\circ$ Fasciectomy done.

Zones of hand

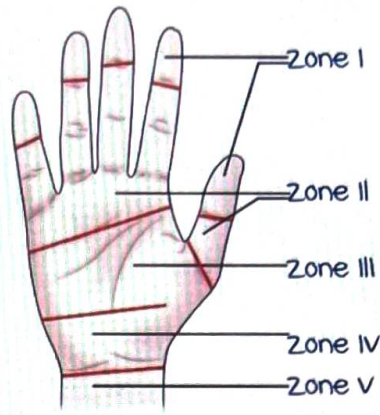
01:05:28

For ease of understanding /for classification & to understand structures

- I. Insertions of FDP.
- II. Insertions of FDS → No mans land of BUNNEL (as previously thought as area is difficult to operate).
- III. Lumbricals.
- IV. Carpal tunnel.
- V. Forearm.

kumarankitindia1@gmail.com

Active space



Pulley's of hand :

Flexor tendons as they pass through hand pass through pulleys.

Pulley's hold the tendon in place.

Types : Annular.

Cruciate.

A₅ → DIP joint.

A₄ → Distal phalanx.

A₃ → PIP joint.

A₂ → Proximal phalanx (most crucial).

A₁ → MCP → Trigger finger.

Trigger finger

01:07:30

Stenosing tenosynovitis of flexor tendon at A₁ pulley.

A₁ Pulley located on MCP joint.

Swelling of flexor tendon.

Tendon has to pass through sheath on flexion & extension.

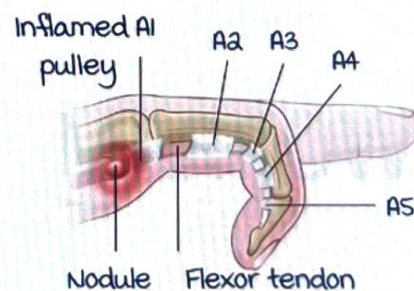
Flexors are strong hence movement not restricted.

Restriction at the time of extension on finger.



more force

Finger open like trigger.



Active space

60c6b3eeaa8ded0e4e7e5ea7

MC affected tendon : FDP

Female > male

MC involved finger : **Ring finger**

MC cause : Trauma, Rheumatoid arthritis, DM.

Gamekeeper's thumb/ skier's thumb

01:07:09

movements of thumb :

Flexion → Extension.

Abduction → Adduction

Opposition.

Avulsion of ulnar Collateral ligament (UCL) of thumb at 1st MCP joint.

might be due to hyperabduction.

Stener lesion : Entrapment of adductor pollicis muscle

between UCL

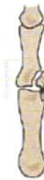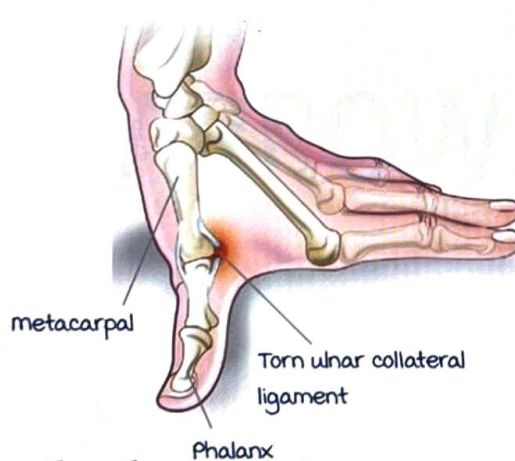
Prevents healing of UCL.

Treatment :

Thumb spica cast : For 4-6 weeks

Surgical repair : If complete tear /Stener Lesion.

Gamekeeper's thumb



Bowler's thumb

01:10:25

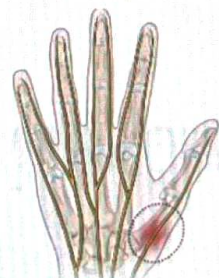
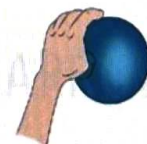
Seen in bowling alley bowlers.

Ring of thumb takes burden of ball due to constant compression as it bears majority of weight.

Nerves on radial & ulnar side

inflamed.

ulnar digital nerve neuroma of thumb due to **perineural fibrosis**.



Active space

Prevention : Use of protective gear, stop bowling.

Treatment : Rest, NSAIDs, splint, steroid injection.

Mallet finger/ Baseball finger

01:12:11

Avulsion of extensor digitorum communis.

Clinical features :

Flexion Deformity of DIP joint/
inability to extend.

mechanism of injury : **Hyper flexion injury.**

Passive extension possible but
inability of active extension as
tendon ruptured.

In X ray :

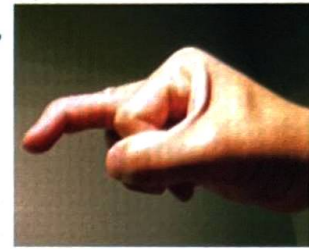
If no avulsion/only tendon rupture :

No changes seen.

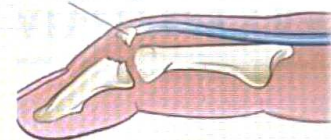
If avulsion present : Small bony
fragment on base of distal
phalanx on dorsal side

Treatment : mallet splint / Stax
Splint.

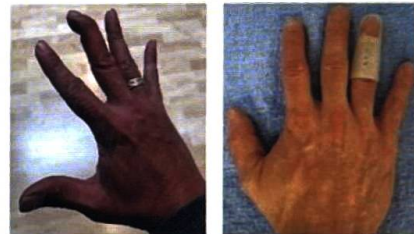In Rheumatoid arthritis, boot neck deformity, Swan neck
deformity : multiple fingers affected.



Avulsion injury of extensor tendon at DIP joint



mallet finger



Jersey finger

01:14:20

Avulsion of Flexor digitorum Profundus.
on volar side.

Clinical feature :

Extension Deformity of DIP
joint/inability to Flex

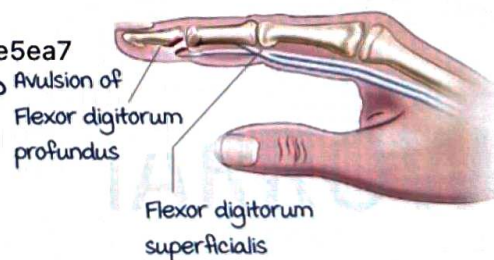
mechanism of injury :

Hyper extension Injury

Passive flexion possible but
inability of active flexion as

tendon continuity lost. Occurs in ring finger commonly.

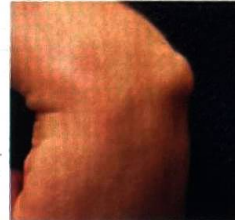Treatment : Splint.



Ganglion cyst

01:15:17

- m/c cause of swelling in hand/wrist.
- unilocular cystic swelling arising from the synovium with synovial fluid.
- Out pouching from synovium or the tendon sheath.
- Contains mucinous fluid.
- Due to degeneration, trauma etc.
- Can be seasonal.
- Painful/painless.
- m/c : Dorsal side > ventral side.

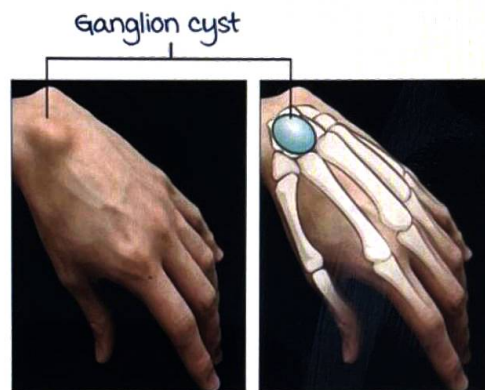

Treatment :

Conservative management.

No need for treatment.
Aspirate the contents of the cyst, followed by injection of steroids or sclerosants.

Surgical excision : In case of recurrence.



kumarankitindia1@gmail.com

Compound palmar ganglion

01:17:00

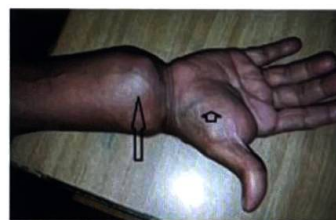misnomer : Neither compound nor palmar.

Chronic inflammation of flexor sheath in forearm & hand

Seen in patients of TB & Rheumatoid arthritis.

Flexor retinaculum divides the swelling into the shape of an hourglass.

It does not undergo inflammation but acts as a constriction band.



Photograph of the patient's wrist demonstrates bilobed swelling both proximal (larger arrow) and distal (smaller arrow) to the proximal wrist crease.



Active space

Chondromalacia Patellae

01:18:35

Softening of articular cartilage of patella.

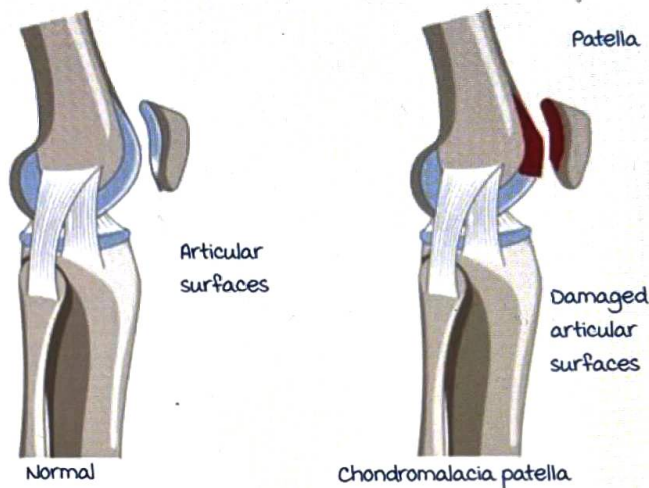
Causes anterior knee pain (**most common cause**).

movie sign :

Severe pain on getting up from sitting position (especially for prolonged time).

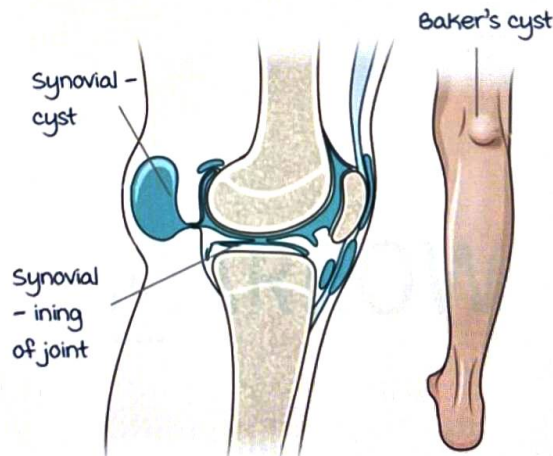
Seen in athletes.

Aetiology : Idiopathic



Baker's cyst

01:20:08



Baker's Cyst / Popliteal Cyst / marrant Baker Cyst.

60c613eeaa8ded0e4e7e5ea7
It's a pressure/pulsion diverticulum of synovium.

In posterior aspect.

Occurs :

From bursae.

From joint.

Swelling becomes prominent on knee extension disappears on flexion.

Causes :

- Osteoarthritis.
- Rheumatoid arthritis.
- PVNS (Pigmented villo nodular synovitis).
- TB (sometimes).

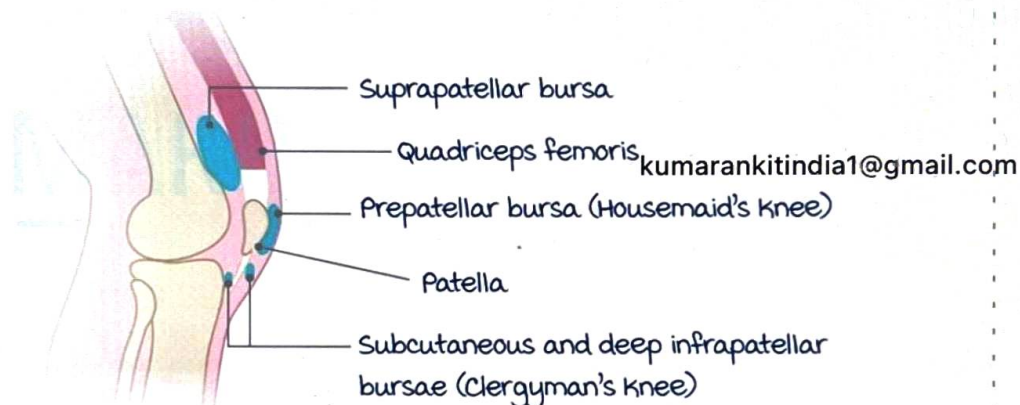
Diagnosis → USG

Treatment → Aspiration possible but **due to high recurrence**
Excision .

Bursitis

01:21:37

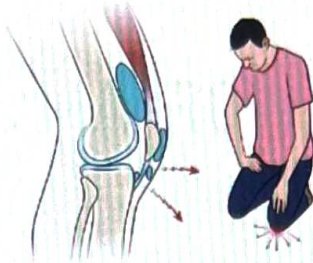Bursae around knee joint



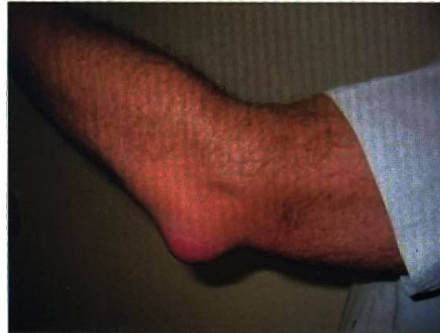Bursa → Allows gliding of bones & prevents friction when tendon glides on bones.

Condition	Pathology
Housemaid's Knee	Pre Patellar bursitis
Clergy man's Knee	Infra Patellar bursitis
Students elbow	Olecranon bursitis
Haglund Deformity	Retro Calcaneal bursitis
Weavers Bottom	Ischial bursitis
Tailors Ankle	lateral aspect of 5th metatarsal

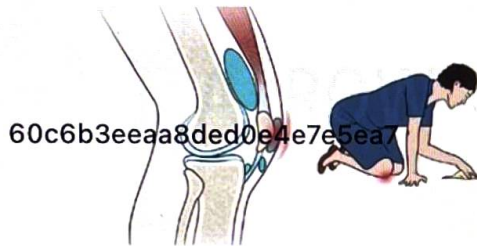
Active space



Clergyman's knee : Infra Patellar bursitis



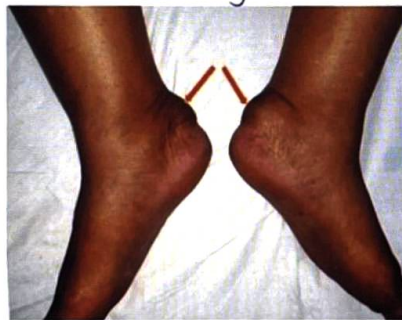Olecranon bursitis



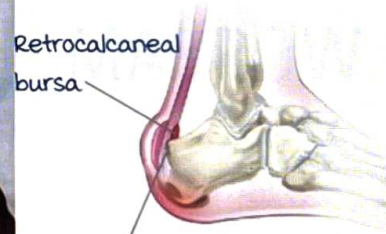
60c6b3eeaa8ded0e4e7e5ea

Housemaid's knee : Pre-Patellar bursitis

Haglund, pump bump deformity



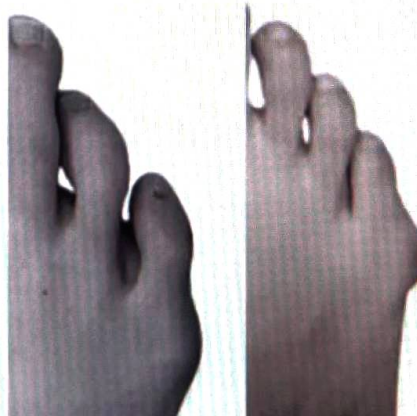
Haglund deformity



Bony enlargement

Seen when wears abnormal footwear like heels/pumpshoes → Inflammation → Calcification → Swelling

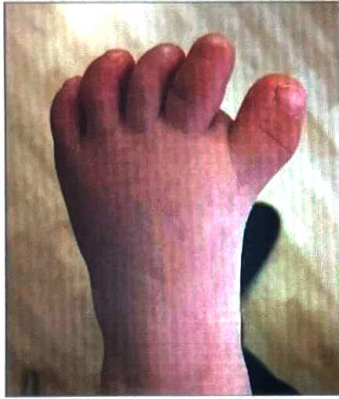Tailor's Bunion : Bony swelling in lateral aspect of 5th metatarsal



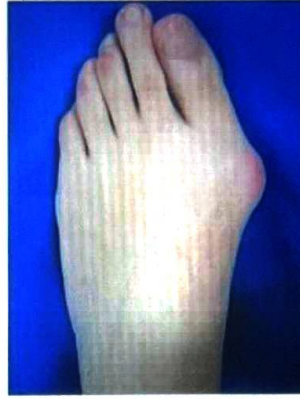Active space

Hallus varus & Hallus valgus

01:25:18



Hallux Varus

Hallux valgus with
medial Bunion

Hallux valgus :

Lateral deviation of great toe.

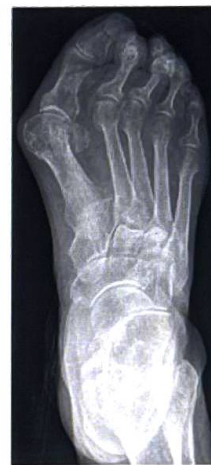Overcrowding & overriding of fingers.

Treatment :

Deformity : No treatment needed but treated for pain.

Conservative : Fillers between fingers.

Surgery for pain relief : Chevron or Keller osteotomy.



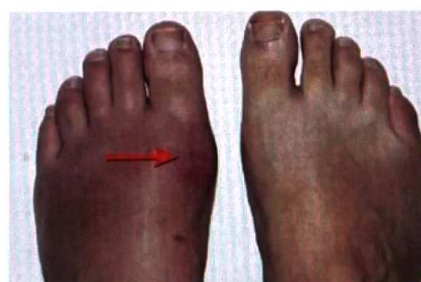Gout

01:26:44

Another differential diagnosis of medial Bunion.

Gout	Hallus valgus
Inflammation present.	Inflammation absent unless due to trauma.
Associated with redness, local rise of temperature, warmth.	Not associated with redness, local rise of temperature, warmth.
In X ray → Destruction of bone seen.	In X ray → Deformity of bone

Aspirated content from 1st MTP shows monosodium urate crystals (negatively birefringent crystals).



Active space

Clinical scenarios

01:27:45

Q. An elderly diabetic patient comes to you with gradual painful limitation of shoulder movements. There is no history of trauma. All are true of her possible diagnosis except?

- A. Periarthritis is most probable diagnosis
- B. All movements are restricted
- C. Internal rotation affected last
- D. Both active and passive movements are affected.

Q. Most common muscle damaged in rotator cuff?

- A. Supraspinatus.
- B. Infraspinatus.
- C. Subscapularis.
- D. Teres minor.

Q. A 40yr old man was repairing his wooden shed on a Sunday morning. By afternoon, he felt that the hammer was becoming heavier and heavier. He felt pain in lateral side of elbow and also found that squeezing water out of sponge hurt his elbow. Which of the muscles are most likely involved?

- A. Biceps brachii and supinator.
- B. Flexor digitorum superficialis.
- C. Extensor carpi radialis longus and brevis.
- D. Triceps brachii and anconeus.

Q. Finkelstein's test is used for?

- A. CDH.
- B. De Quervain's tenovaginitis.
- C. Trigger finger.
- D. Tennis elbow.

60c6b3eaa8ded0e4e7e5ea7 Q. About De Quervain's disease. All are true except?

- A. Involves EPB and AbPL.
- B. Positive Finkelstein test.
- C. Steroid used to relieve pain.
- D. Involves extensor pollicis longus.

Q. All are true about Dupuytren's contracture except ?

- A. Thickening fibrosis of palmar fascia.
- B. Much more common in males.
- C. Associated with alcohol consumption & diabetes.
- D. Rarely bilaterally and mostly starts in index finger.

Q. What is the most common cause of trigger finger?

A. Trauma

B. Alcohol.

C. Smoking.

D. Drug abuse.

Q. All are true about trigger finger except ?

A. Thickening of fibrous tendon sheath mainly A1 pulley at MCP joint.

B. Stenosing tenovaginitis of flexor tendon of finger.

C. Follows local trauma.

D. mainly involves A₂ pulley of finger.

Q. Housemaid's knee is bursitis of which of the following ?

A. Prepatellar bursa.

B. Infrapatellar bursa.

C. Olecranon bursa.

D. Ischial bursa.

Q. Ischial bursitis is also known as?

A. Clergyman's knee.

B. Housemaid's knee.

C. Weaver's bottom.

D. Students elbow.

Q. In hallux valgus surgery, the patients who are likely to be most satisfied are?

A. Those with more pain.

B. Those with hammer toe.

C. Those with no pain.

D. Patients with young age.

Q. Counterforce brace is used in which of the following condition ?

A. Tennis elbow.

B. Ankle sprain.

C. Ulnar claw hand

D. Foot drop.

Explanation :

kumarankitindia1@gmail.com

Ulnar claw hand : Knuckle bender splint.

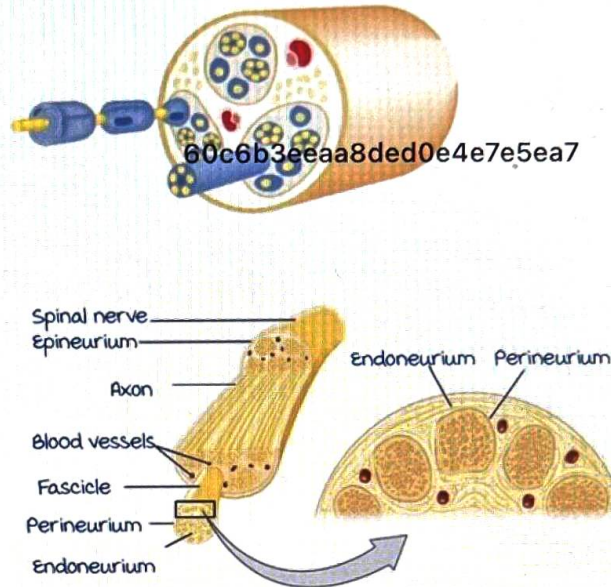
Foot drop : Foot drop splint/Ankle drop orthosis/Toe raising splint.

Common Peroneal Nerve > Sciatic Nerve.

NERVE INJURIES FUNDAMENTALS

Ultrastructure of the nerve

00:02:10



Cross-section of typical nerve :

Each axon surrounded by sheath called **endoneurium**.

Axons with their respective endoneurium are surrounded by **perineurium** to form a **fascicle**.

Fascicles together surrounded by a sheath called **epineurium**.

When the nerve is injured, the distal limb undergoes **wallerian degeneration**.

The proximal limb attempts to regenerate by sprouting naked nerve endings called **neuroma**.

Neuroma in continuity :

If at least one **sheath around the axon is intact** it leads the neuroma towards the receptor.

Regeneration is at the rate on 1 mm/day.

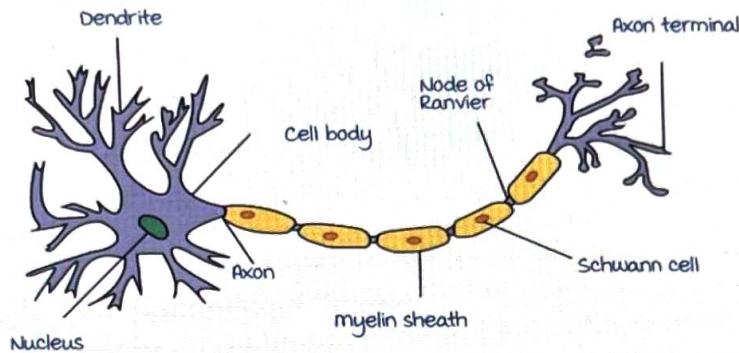
Hence, **neuroma when covered with sheathes is a neuroma in continuity**.

This will completely regenerate.

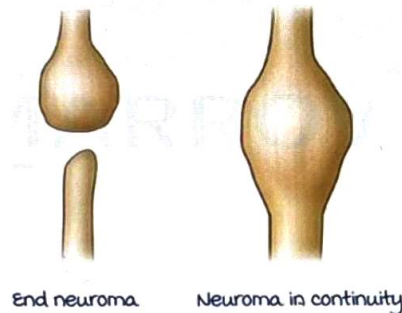
End neuroma :

If all sheathes are injured, it forms an end neuroma.

This will **not regenerate**.

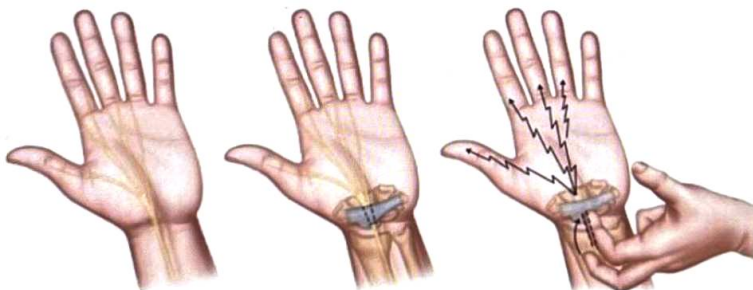


Types of neuroma



Tinel's sign

00:09:21



60c6b3eeaa8ded0e4e7e5ea7

Since the normal nerve is sheathed, tapping on the surface marking of the nerve will not stimulate it.

Neuroma consists of free nerve endings, hence sensitive to stimulus.

Therefore, tapping on it will produce sensation distal to the tap, this is a **positive Tinel's test**.

Since a neuroma in continuity is regenerating, the location keeps changing.

Therefore, Tinel's test is **positive and progressive** in a neuroma in continuity.

End neuroma doesn't regenerate, hence tinel's is **positive and non-progressive**.

The sensations are distal to the neuroma due to **law of projection**.

Which states that if we stimulate the sensory pathway along its course to the sensory cortex, the conscious sensation produced is perceived to be from the location of receptors.

Motor march

00:15:00

Progressive recovery of muscles from **proximal to distal** in a nerve injury when there is a **neuroma in continuity**.

High vs low nerve injury :

Higher/proximal the injury more the disability and deformity since more muscle groups are involved.

Lower/distal the nerve injury, **less the disability or deformity**.

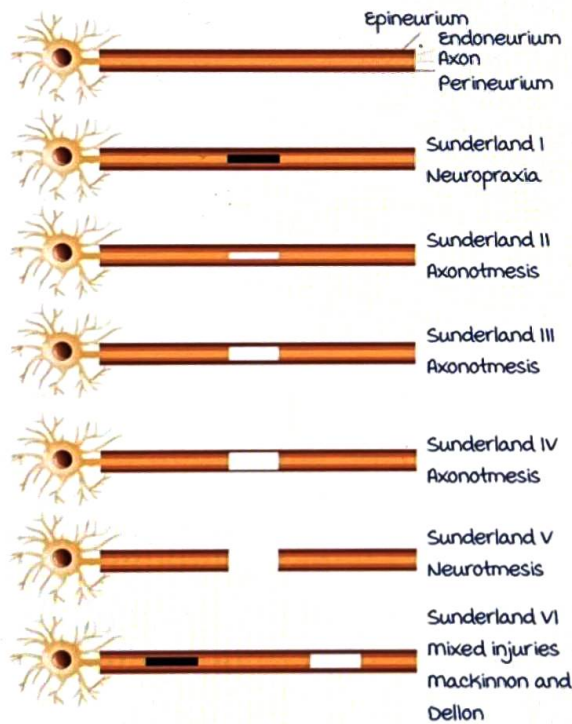
Classification of nerve injuries

00:18:32

Seddon	Sunderland
<p>Neuropraxia :</p> <p>Temporary physiological, reversible conduction block due to compression.</p> <p style="text-align: center;">↓</p> <p>Slow conduction under the compressed segment.</p> <p>Recovery : Spontaneous and full (3-6 weeks).</p> <p>Examples :</p> <ol style="list-style-type: none"> 1. Tourniquet palsy. 2. Saturday night palsy (wrist drop due to radial nerve compression at arm). 3. Crutch palsy (wrist drop due to radial nerve compression at axilla). <p>Treatment : Splints to prevent contracture of the muscles.</p>	1

kumarankitindia1@gmail.com

<p>Axonotmesis :</p> <p>Only axons injured but nerve continuity intact.</p> <p>↓</p> <p>Neuroma in continuity.</p> <p>Positive and progressive Tinel (1 mm/day).</p> <p>Recovery : <100%.</p> <p>motor march present.</p> <p>Example : Fracture, dislocations.</p>	<p>II. Axon injury.</p> <p>III. Axon + endoneurium injury.</p> <p>IV. Axon + endoneurium + perineurium injury.</p>
<p>Neurotmesis :</p> <p>Axons and all sheaths injured.</p> <p>↓</p> <p>End neuroma is formed.</p> <p>Tinel positive , but non progressive.</p> <p>No recovery.</p> <p>Examples : Laceration, cut and incised wound.</p> <p>Treatment : Repair + graft.</p>	<p>V</p> <p>60c6b3eaaa8ded0e4e7e5ea7</p>



Management of nerve injury

00:26:22

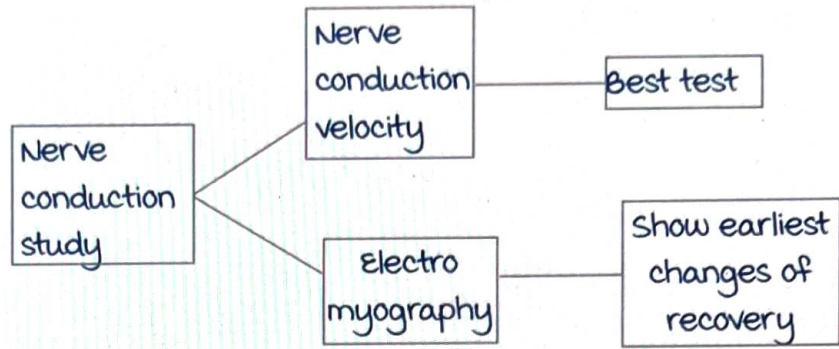
Clinical test :

Tinel's test :

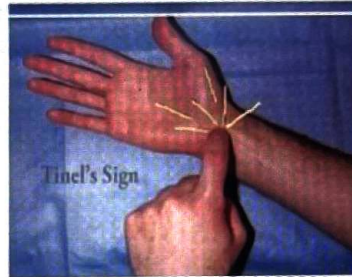
Helps only in assessment of nerve recovery.

Investigation of choice : Nerve conduction study.

Active space



Clinical test : Tinel's test helps in assessment of recovery.



Treatment/intervention :

most injuries are neuropraxia.

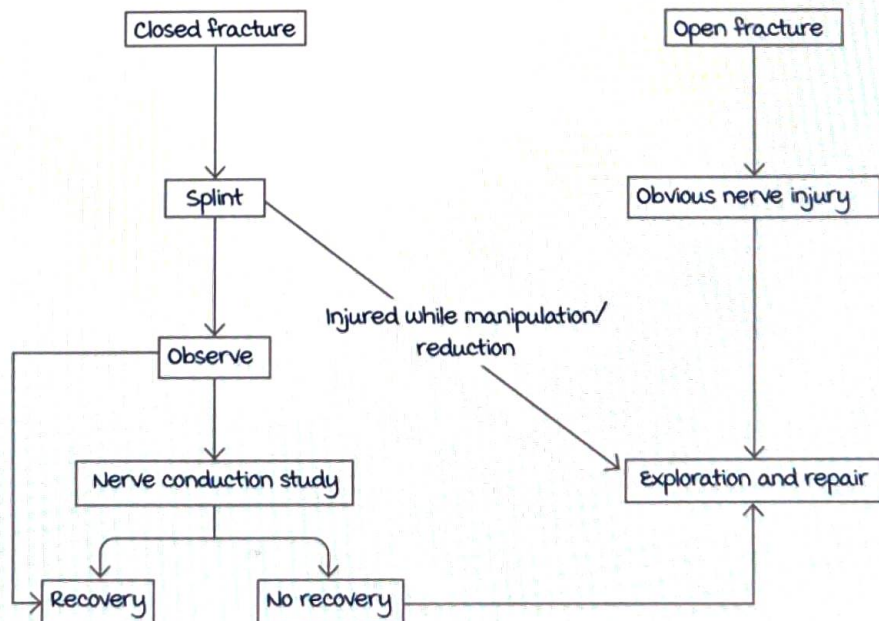
Therefore management is conservative.

usually a splint is used.

For example :

- Wrist drop : Cockup splint.
- Claw hand : Knuckle bender splint.

For injuries more than a neuropraxia, management varies from expectant to exploration.



Active space

Exploration is done if there is :

- Open fracture.
- Obvious nerve injury like sharp injuries, incised wound.
- Nerve injury while manipulation, since it is iatrogenic.

Types of repair

00:31:58

- Primary repair (<6 hrs) : usually done in clean cut injuries.
- Delayed primary repair (7-18 days) : If the cut is not clean.
- Secondary repair (>18 day) : Done when other issues are present that have to be managed first.

Nerve repair can be done in the following ways :

1. End to End repair (preferred).
2. End to side repair.
3. Nerve graft : If cut ends cannot be approximated.

kumarankitindia1@gmail.com

Nerves used for grafting :

1. Sural nerve.
2. Saphenous nerve.

Prognosis :

Better prognosis seen in (mnemonic : NERVE is growing).

- Neuropraxia.
- Early repair.
- Radial nerve injuries.
- Vasculature intact.
- End to end repair (no graft).
- Growing children.

Radial nerve has the best prognosis of recovery, because it's mostly a pure motor nerve.

Mixed nerves produce axonal confusion, for example gustatory tears.

Sciatic and ulnar nerves have poor prognosis of recovery, since they are mixed nerves.

Active space

NERVE INJURIES : PART 1

Injury to nerve affects both the sensory and motor component. If, the motor component is lost or weakened the antagonistic group of muscles will overpower the action of the muscle that is paralysed which causes the deformity.

Axillary nerve

00:01:36

Root value : C5 - C6 (C5 > C6).

motor supply :

1. Deltoid muscle :

Abduction of shoulder (15-90°).

2. Teres minor : External rotation.

Sensory :

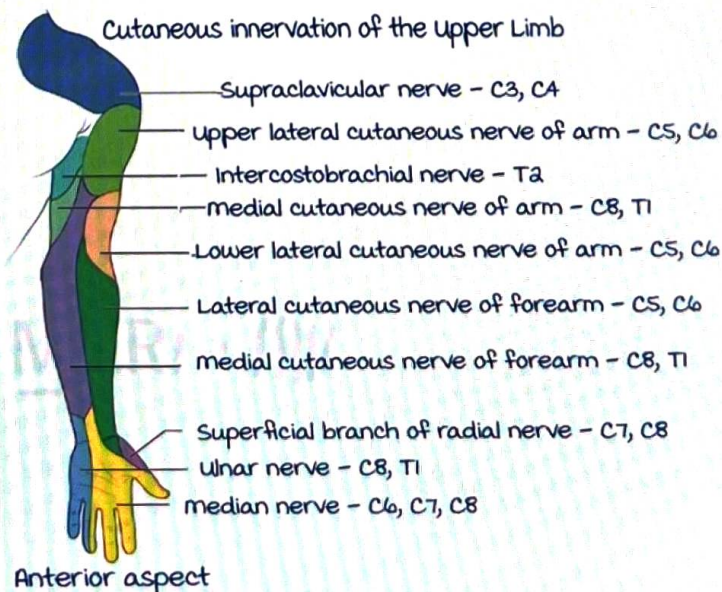
Regimental badge area : Upper and lateral part of arm.

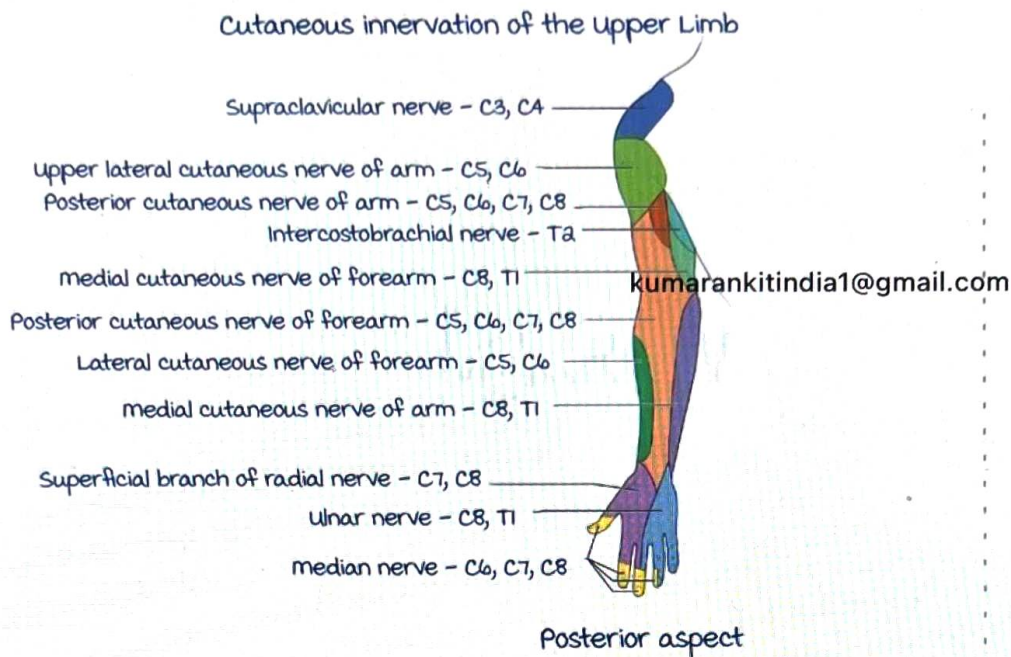
Shoulder abduction :

- Supraspinatus : 0 to 15.
- Deltoid : 15 to 90.
- Serratus Anterior & trapezius : Overhead abduction.



Regimental badge area :





Deformity :

- Adducted.
- Internally rotated.
- Loss of sensation at the proximal shoulder (Regimental badge sign).
- MOI :
 1. Shoulder dislocation (mc).
 2. Proximal humerus fracture.
 3. Iatrogenic.

Splint : Abduction splint.

In a case of a shoulder dislocation with an axillary nerve injury, the attitude of the limb will be, abduction and external rotation. In such cases, to assess axillary nerve involvement, we need to look for paresthesia over the regimental badge area. If the shoulder is reduced and the axillary nerve injury still persists, the attitude of the limb will be, adduction and internal rotation.

Hence, if there is a dislocation associated with a nerve injury, the attitude of the dislocation will manifest and once the dislocation is reduced, the attitude of the nerve injury will manifest.

Musculocutaneous nerve

00:07:15

Innervation :

motor :

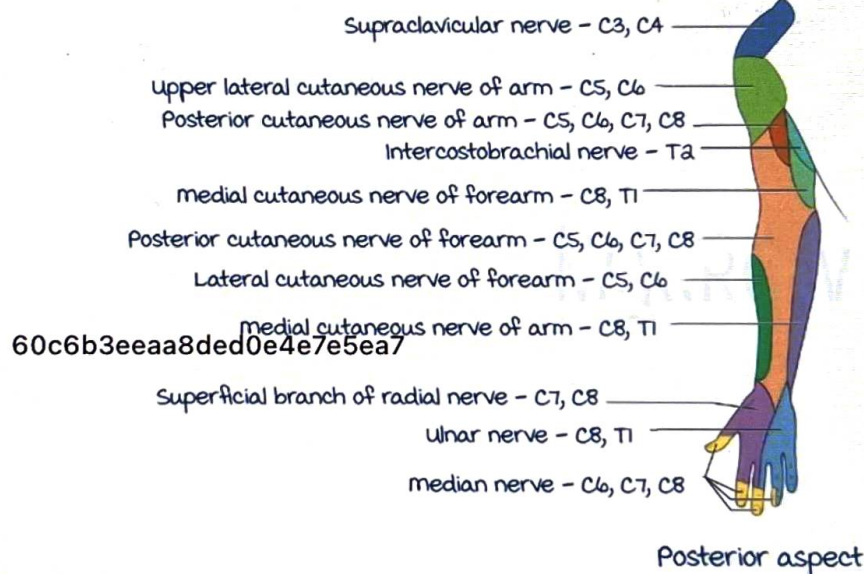
- Coraco Brachialis.
- Biceps Brachii :
 1. Supination of forearm.
 2. Flexion of elbow.
- Brachialis.
 1. Flexion of elbow.

Sensory : Lateral aspect of forearm.

Deformity : Elbow extension and forearm pronation.

Patient will have paraesthesia/tingling/numbness/lack of sensation in the lateral aspect of forearm.

Cutaneous innervation of the upper limb



Median nerve

00:12:34

Laborer's nerve (supplies the forearm muscles which is important for laborer).

Sensory Supply :

- Lateral 3 and half fingers in the palmar aspect & tips of lateral 3 and half fingers in dorsal aspect.
- At the flexor retinaculum :
 1. Deep branch supply the thenar muscles & the finger sensations.
 2. Superficial branch supply the sensations over the thenar eminence.

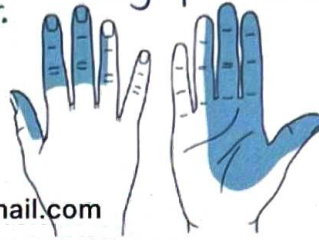
Autonomous zone : Independent zone supplied by a single nerve.

↓
median nerve : Tip of index finger.

ulnar nerve : Tip of the little finger.

Radial nerve : Dorsum of the first web space.

Lateral
3 1/2 : Palmar
Only tips : Dorsal



kumarankitindia1@gmail.com

motor Supply :

Forearm :

- Flexor carpi radialis, pronator teris, palmaris longus, lateral half of flexor digitorum profundus, flexor digitorum superficialis, flexor pollicis longus, pronator quadratus
- All anterior compartment of forearm except : Flexor carpi ulnaris and medial half of flexor digitorum profundus.

Hand :

- Abductor pollicis brevis.
- Flexor pollicis brevis.
- Opponens pollicis.
- Lumbricals 1 & 2
- All thenar muscles except **adductor pollicis**.

Simplification :

- In Arm : No Supply.
- In forearm : All anterior compartment of forearm except, flexor carpi ulnaris and medial half of flexor digitorum profundus.
- In hand : All thenar muscles except adductor pollicis.
- **Anterior interosseous nerve (AIN)** : Flexor pollicis longus (action : Flexion of interphalangeal joint of thumb) and lateral half of flexor digitorum profundus (action : flexion of DIP of index and middle finger).

AIN is purely motor, can be injured without injury to median nerve

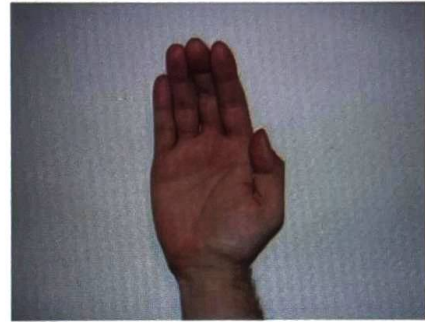
median Nerve Injuries :

At Wrist :

- Loss of thenar muscle tone → wasting.
 Thumb abduction
 Thumb flexion
 Thumb opposition } Lost



Opponens Splint



Ape hand deformity

- Abductor pollicis brevis action lost (predominant abductor of thumb).
 Pen test : Palm facing upwards and touch a pen held above it with the thumb, without moving the hand.

At Elbow :

- Wrist lesion.

+

- Flexor pollicis longus.
- Flexor digitorum profundus.
- Flexor digitorum superficialis. } Lost

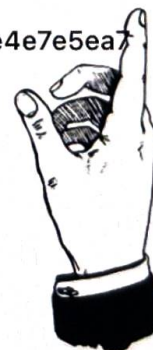- Index finger does not flex on making a fist.

Pointing index.

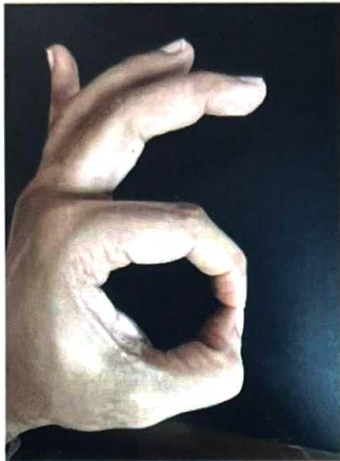
Benediction sign.

Ochsner clasp Sign.

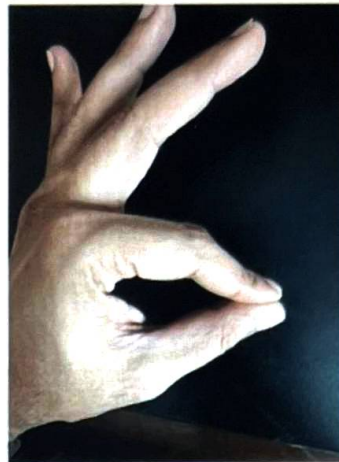Pope sign.



Kiloh Nevin Sign - Weak OK Sign : AIN palsy

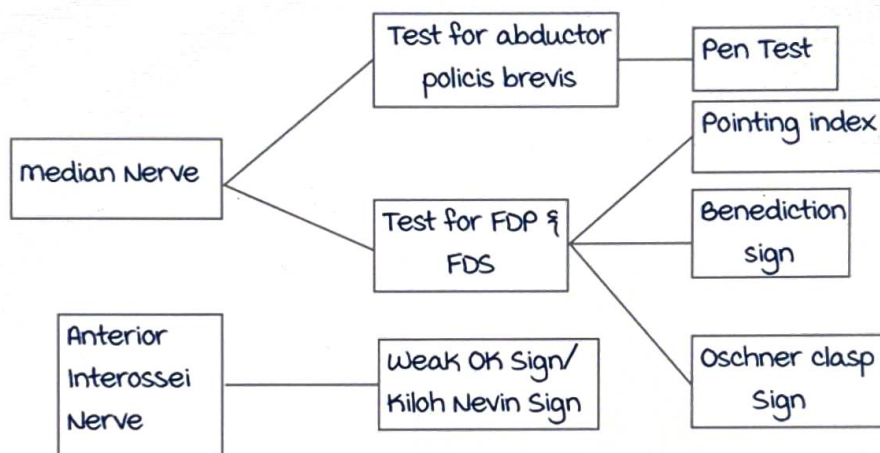


Normal



AIN Palsy

Test for median nerve injury assessment :



Ulnar nerve (C8-T1)/musician's nerve

00:36:18

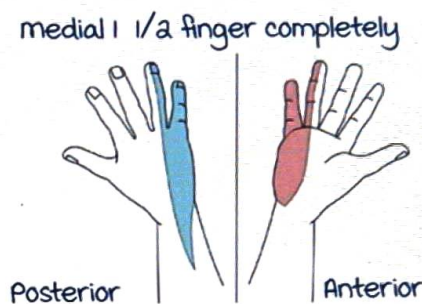
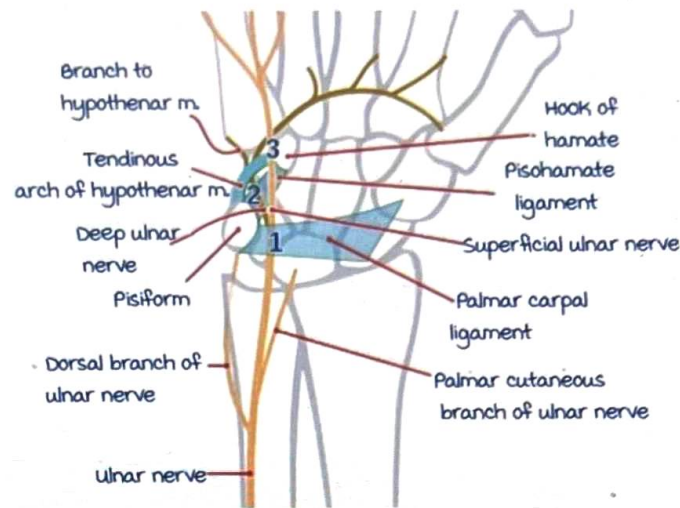
Sensory Supply : medial one & half fingers volar & dorsal aspect.

At the flexor retinaculum :

- Deep branch supply the hypothenar muscles & intrinsic muscles of the hand and sensation over the fingers.
- Superficial branch supply the sensations over the hypothenar eminence.
- Autonomous zone : Independent zone supplied by a single nerve.

60c6b3eaaa8ded0e4e7e5ea7
↓
ulnar nerve : Tip of little finger.

Active space



motor supply :

Forearm :

- Flexor carpi ulnaris.
- medial $\frac{1}{2}$ flexor digitorum profundus.

Hand :

- Adductor pollicis.
- Lumbricals 3,4 : Flexion of metacarpophalangeal joint & extension of interphalangeals = **CLAW HAND (Partial)**.
- Interossei.

Palmar : Abduction.

Dorsal : Abduction.

- Hypothenar muscles.

Simplification :

- In Arm : No Supply.
- In forearm : FCU & medial $\frac{1}{2}$ of FDP.
- In hand :

ALL Hypothenar muscles.

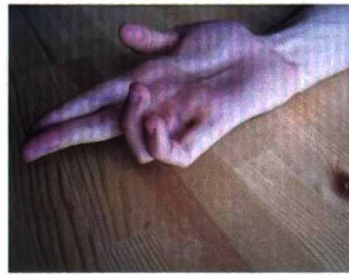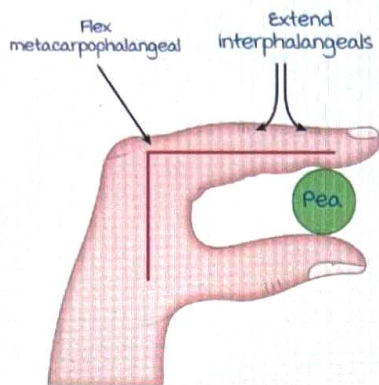
Thenar : Adductor pollicis.

Lumbricals 3 & 4.

Interossei (Palmar & dorsal).

Action of Lumbricals :

Lumbricals



Partial claw hand

Flexion : metacarpophalangeal joint.

Extension : Interphalangeal joints.

Deformity :

MCP extension, PIP & DIP flexion in 4th & 5th fingers.

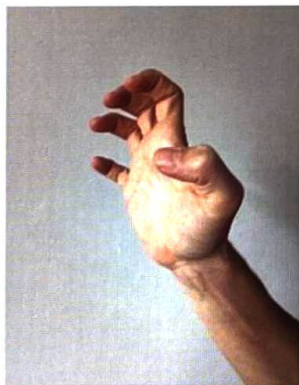Partial clawing of hand (resting deformity) with wasting of hypothenar muscles.

Sensation is lost in the medial one and half fingers.


Splint : Knuckle bender splint.

Ulnar + median nerve involvement :

Complete claw hand



Complete claw hand



Knuckle bender splint.

Interossei function :

Palmar interossei, action : Adduction.

Card test positive if action is lost.


Dorsal interossei, action : Abduction.

Fan the fingers : Egawa test. 60c6b3eaa8ded0e4e7e5ea7

Card Test :

This is for palmar interossei (adductors) of the fingers. In

this test, the examiner inserts a card between two extended fingers and the patient is asked to hold it as tightly as possible while the examiner tries to pull the card out. The power of adductors can thus be judged.



Since, middle finger is the axis of hand, movement of it in any direction is considered as abduction of finger.

Adductor pollicis function : Adduct thumb.

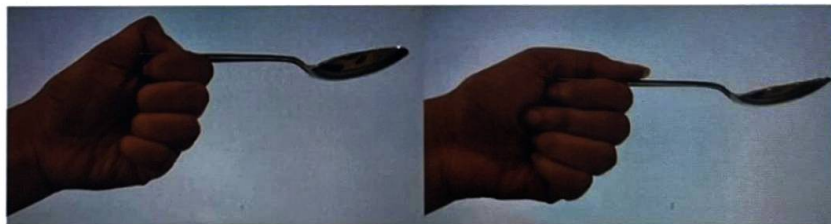
Book test: kumaranjitindia1@gmail.com

- Hold book between thumb and index finger.
- Flexion of thumb (due to lack adduction).

Froment sign :

If the ulnar nerve is injured, the adductor pollicis will be paralyzed and the patient will hold the book by using the flexor pollicis longus (supplied by median nerve) in place of the adductor.

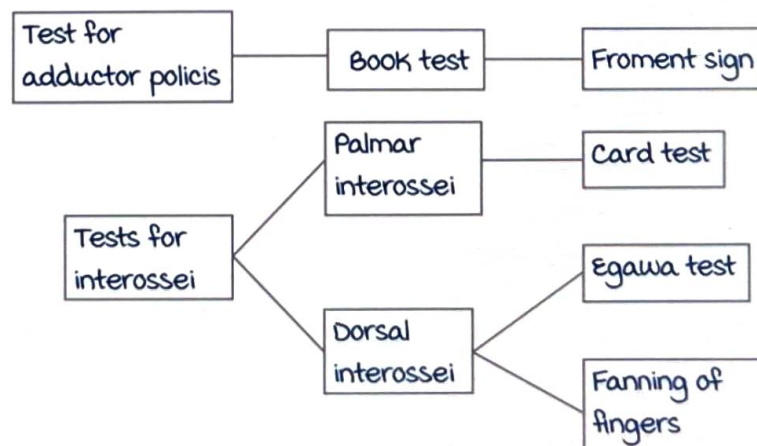
This produces flexion at the inter-phalangeal joint of the thumb.



Froment's positive

Adductor pollicis normal

Tests for ulnar nerve assessment :



Active space

Ulnar paradox :

High ulnar nerve palsy : Less clawing/less deformity.

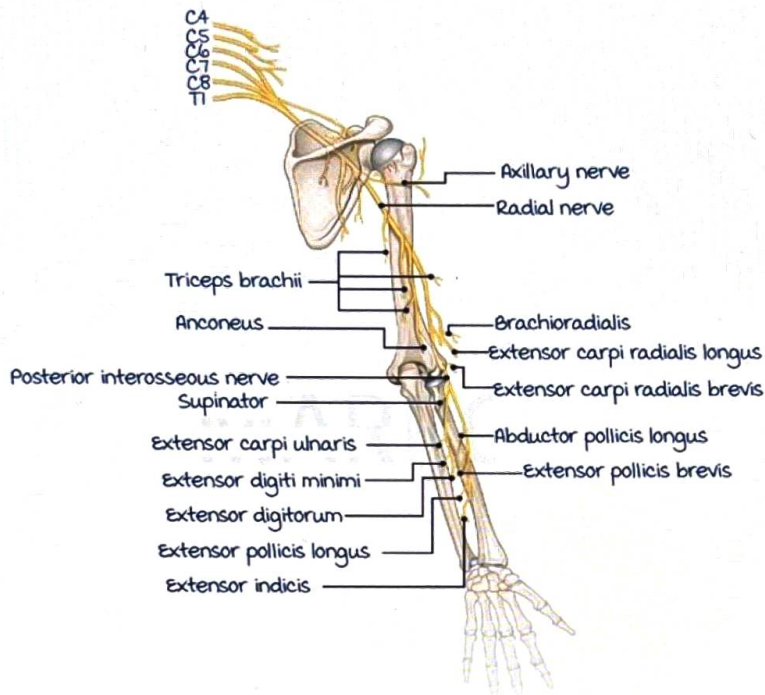
Ulnar nerve injury at wrist : Flexor digitorum profundus spared (significant clawing).

v/s

Ulnar nerve injury at elbow : Flexor digitorum profundus paralyzed (less clawing).

Radial nerve

00:51:10



Posterior compartment of arm and forearm
Radial nerve - Course and distribution

mc injured nerve, but **best prognosis**

extensors of elbow, wrist & fingers.

Radial nerve supplies :

- Long head of triceps.
- Lateral, medial head of triceps, anconeus at spiral groove.
- Extensor carpi radialis longus (ECRL).

Posterior interosseous nerve : Extends thumb and fingers.

Supplies : Superficial extensors.

- Extensor digiti minimi.
- Extensor carpi ulnaris.
- Extensor digitorum communis.
- Extensor carpi radialis brevis (ECRB).

60c6b3eaa8ded0e7e5ea7

Active space

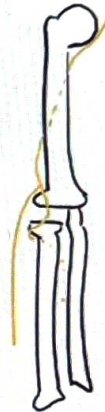Deep Extensors :

- Extensor indicis.
- Extensor pollicis brevis.
- Extensor pollicis longus.
- Abductor pollicis longus.
- Supinator.

Radial nerve motor supply :

Radial nerve supplies :

- Axilla : Long head of triceps (first elbow extensor).
- Spiral Groove : Lateral, medial head of triceps, anconeus.
- After perforating the intermuscular septum : Extensor carpi radialis longus (ECRL) (first wrist extensor).



Posterior interosseous nerve :

- Extensors of thumb & fingers.

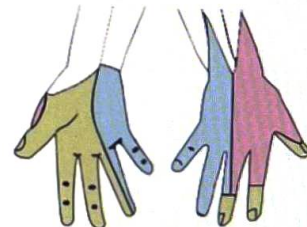
Autonomous zone : Independent zone supplied by a single nerve.

60c6b3eeaa8ded0e4e7e5ea7

ulnar nerve : Tip of little finger.

median nerve : Tip of fore finger.

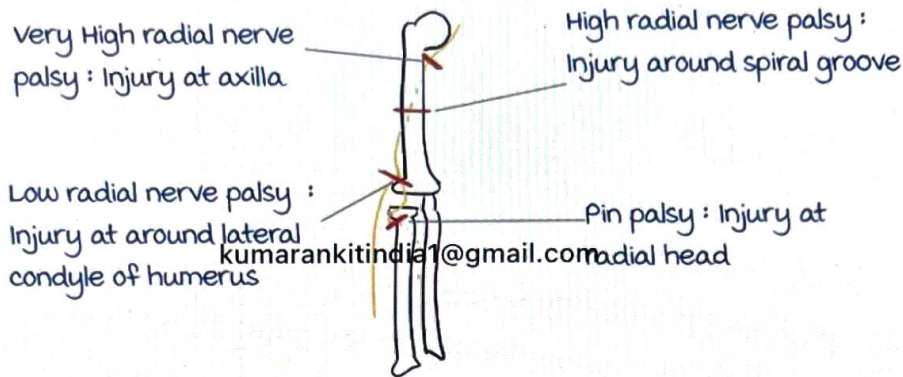
Radial nerve : First dorsal web spaces.



Radial nerve palsy :

- very high radial nerve palsy :
Loss of function of Triceps → Inability to extend the elbow.
- High radial nerve palsy :
Thumb drop, finger drop, sensory loss and wrist drop.
- Low radial nerve palsy :
Finger drop, thumb drop and sensory loss .
- Posterior interosseous nerve /pin palsy : Finger drop and thumb drop.
unable to extend the fingers at metacarpophalangeal joint.

- Injury is proximal to ECRL → **Wrist drop.**
- Injury distal to ECRL → **No wrist drop.**

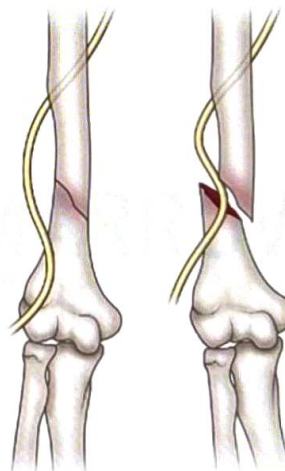
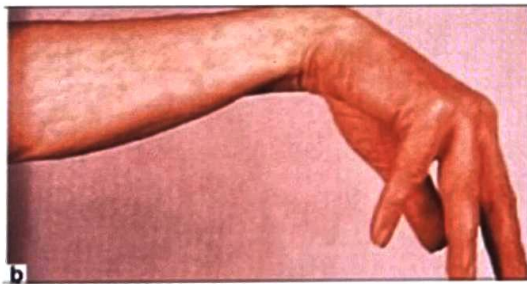


MC cause of radial nerve injury → **Holstein Lewis fracture.**
Lower 1/3rd humerus fracture, radial nerve comes from the posterior compartment to anterior compartment perforating the lateral intermuscular septum.

Nerve gets tethered before ECRL



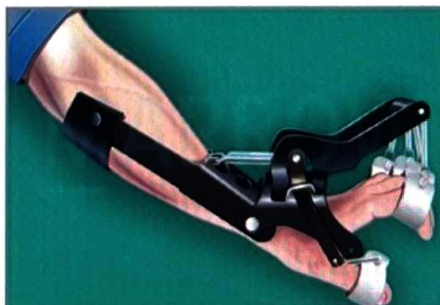Wrist drop, sensory loss, thumb drop, finger drop



Holstein Lewis fracture

Splint : Cock up splint.

- Static cock-up splint.
- Dynamic cock-up splint.



Active space

modified jones tendon transfer :

wrist drop (paralyzed ECRL/ECRB) : Pronator teres used

Finger drop (paralyzed extensor digitorum communis) : Flexor carpi ulnaris used.

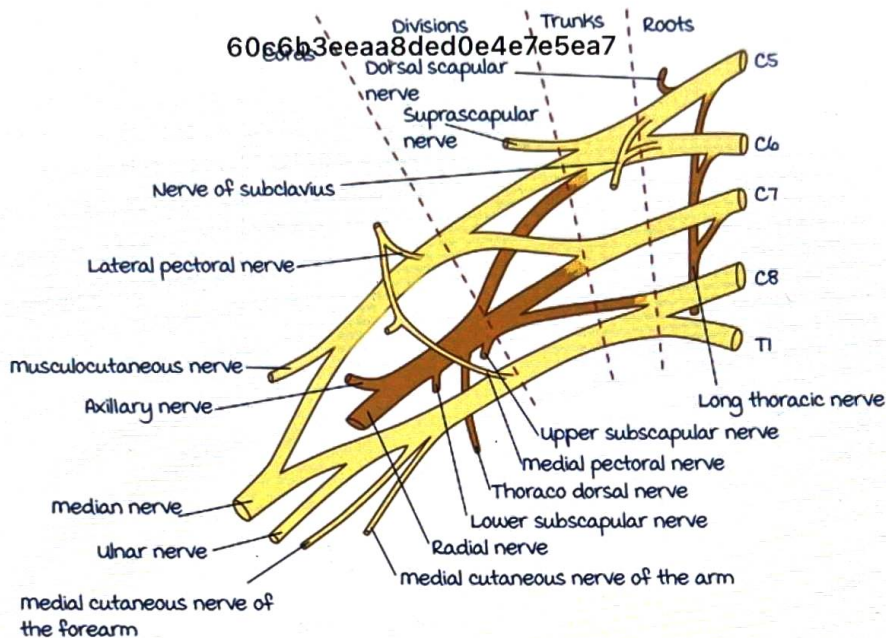
Thumb drop (Paralyzed extensor pollicis longus) : Flexor carpi radialis used.

Nerve	Test / Sign	muscle
Ulnar	Book test	Adductor Pollicis
	Froment's sign	Flexor pollicis substitutes for adductor pollicis
	Card test	Palmar Interossei
	Egawa test	Dorsal Interossei
Median	Ape thumb	Thenar muscle wasting
	Pen test	Abductor pollicis brevis
	Kiloh Nevin sign/ Pincer grasp	Flexor digitorum profundus + Flexor pollicis longus (AIN)
	Pointing Index/ Benediction Sign/Ochsner's Clasp	Flexor digitorum superficialis + Lateral half of flexor digitorum profundus
Radial	Finger & thumb drop	Extensors (PIN)
	Wrist Drop	Extensors of wrist ECRL

NERVE INJURIES : PART 2

Brachial plexus

00:00:22



Brachial plexus has roots, trunks, divisions and cords.

Roots : C5, C6, C7, C8 & T1.

Sometimes branches arise from C4 (pre set brachial plexus) & T2 (post set brachial plexus).

Trunks : upper, middle and lower trunks.

Divisions : 3 anterior & 3 posterior.

Cords : Lateral, posterior & medial cords.

Clinically significant branches :

- Long thoracic nerve : Arises from the roots C5, C6 & C7, supplies the serratus anterior muscle.

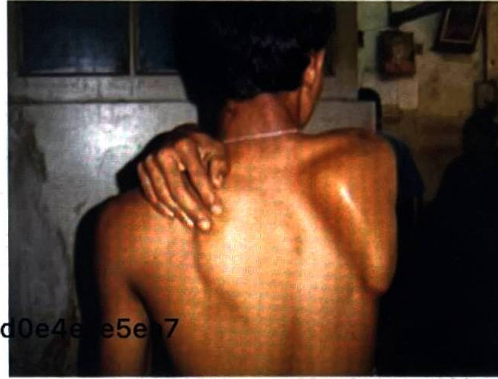Injury → **winging of scapula** (ask patient to push against the wall).

Pseudo winging : Winging of scapula due to any other cause other than serratus anterior weakness caused by long thoracic nerve palsy.

Active space

Example :

- Weakness of trapezius/rhomboids.
- Tumor.
- Malunion.
- Osteochondroma.



60c6b3eeaa8ded0e4e4e5e17

Winging of scapula

Brachial plexus injuries :

Classified with respect to the clavicle.

Supra clavicular : Brachial plexus injuries above the clavicle.

Erb's palsy, most common type of brachial plexus injury and has the best prognosis.

Infra clavicular : Brachial plexus injuries below the clavicle

Klumpke's paralysis.

Combined type : Brachial plexus injuries at both parts. Has the worst prognosis.

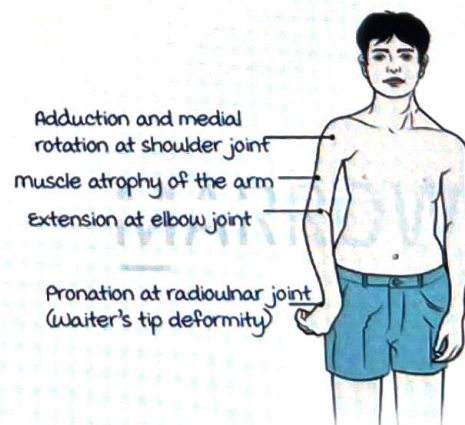
Erb's palsy

00:03:16

Erb's point is the point of confluence between C5, C6 & suprascapular nerve.

Injury at Erb's point leads to loss of function distal to it.

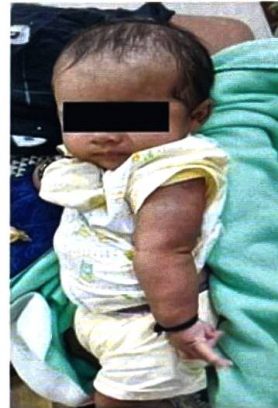Erb's Palsy




Functions and nerves affected due to injury at Erb's point :

- Suprascapular nerve : Supplies **supraspinatus (abducts the shoulder)** and **infraspinatus (externally rotates the shoulder)**. Hence, when injured shoulder goes into adduction and internal rotation.
- Axillary nerve : Supplies **deltoid (abducts the shoulder)** and **teres minor (externally rotates the shoulder)**. Hence, when injured shoulder goes into adduction and internal rotation.
- musculocutaneous nerve : Supplies **biceps (forearm supination and flexion)** and **brachialis (flexion)**. Hence, when injured elbow goes into the extension and the forearm goes into pronation.

Combined manifestation : Shoulder is adducted and internally rotated, elbow is extended and the forearm is pronated. This deformity is called policeman's tip/waiter's tip/porter's tip deformity.



Injury occurs when the head is moved away from the shoulder stretching the upper roots and trunks. Usually seen at the time of birth and in road traffic accidents.

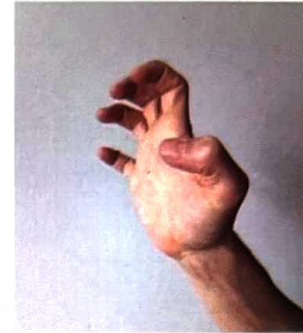

Treated with aeroplane splint.

Klumpke's palsy

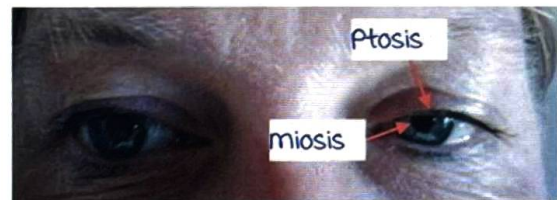
00:08:16

Injury of the brachial plexus at the lower roots C8 & T1 (predominantly ulnar nerve).
 Mechanism of injury: **Hyperabduction** (Shoulder movement towards the head).
 Seen during **fall from height, birth injury**.
 Involves median and ulnar nerve and presents with complete claw hand.



Claw hand

Involvement of T1 nerve (ipsilateral sympathetic supply to the eye).



Hence patients with Klumpke's palsy present with **complete claw hand** with **Horner's syndrome** (ptosis, myosis, anhidrosis & loss of ciliospinal reflex).

Treated with aeroplane splint.

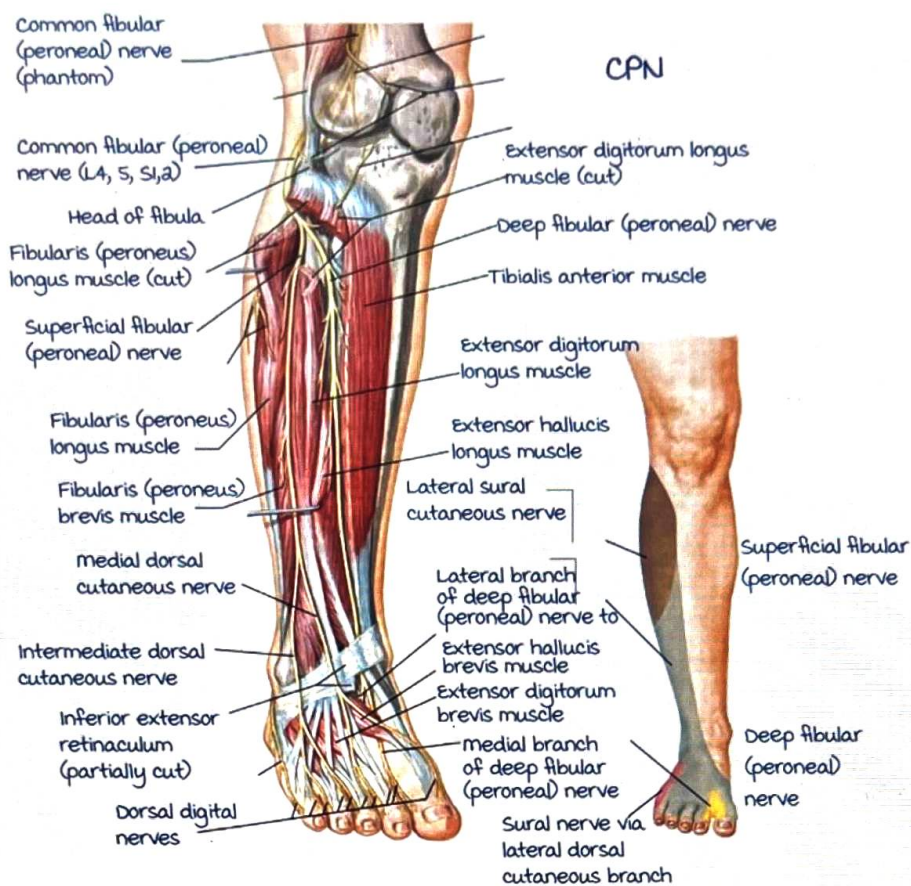


kumarankitindia1@gmail.com

Sciatic nerve injury

00:11:56

Peripheral component is common peroneal nerve.
 Deep component is tibial nerve.
 Injury to sciatic nerve usually **affects** the superficial part of the nerve. Hence, symptoms of common peroneal nerve palsy predominates.



kumarankitindia1@gmail.com

Site of injury : Around **head of the fibula**, where it divides into superficial and the deep branch.

Superficial branch supplies the lateral compartment, whose **muscles evert the foot**. It is also the sensory supply for **dorsum of foot**.

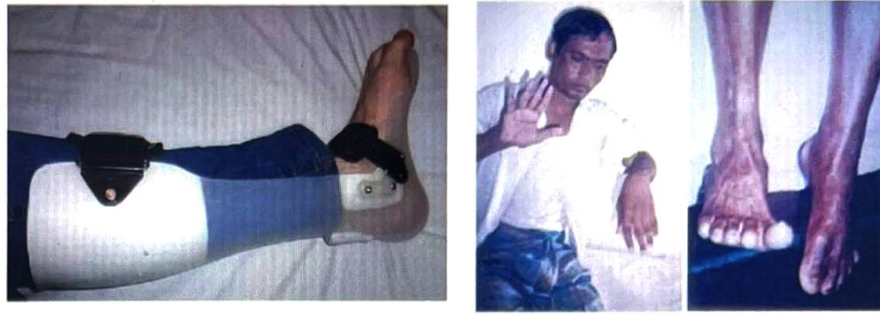Deep branch supplies the anterior compartment of the leg, which helps in **dorsiflexion of the ankle**. It is also the sensory supply for **1st web space of foot**.

Injury to common peroneal nerve leads to **equino varus deformity** i.e **plantar flexion and inversion of the foot**. This is known as **foot drop**.

High stepping gait/foot drop gait : Patient walks by dragging foot along the floor.

In order to lift the dragging foot, patient exaggerates the hip & knee flexion.

Treated with foot drop splint.
This splint prevents plantar flexion.



Entrapment neuropathies :

Nerve gets trapped under a structure.

most common : median nerve in carpal tunnel syndrome.

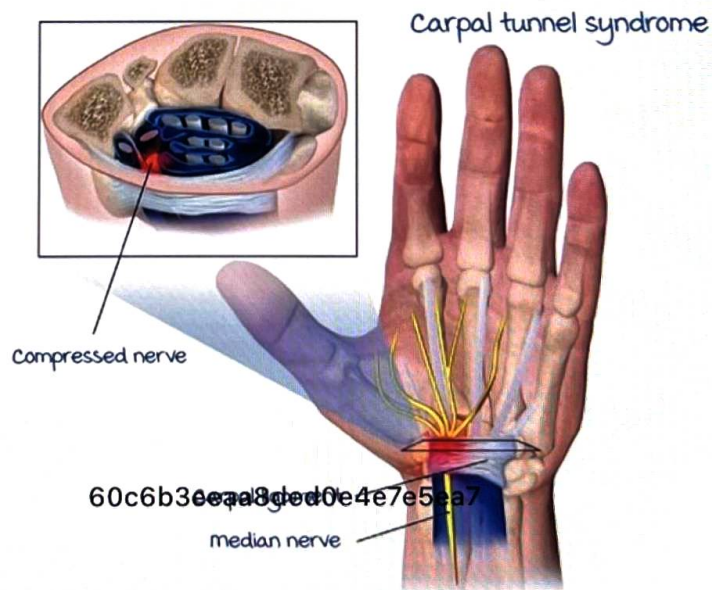
Distal parts supplied by nerve gets affected. velocity of stimulus under the entrapped part is decreased.

Carpal tunnel syndrome

00:16:43

Females > males.

Commonly presents with burning, tingling, numbness & paraesthesia in the middle of the night, involving the region of median nerve distribution. Patient hangs the hand over edge of bed or shakes it for relief from pain.



median nerve passing under the flexor retinaculum, gets compressed in the carpal tunnel.

Early manifestations : only sensory.

Late manifestations : motor + sensory (poor prognosis).

Etiology :

- m/c cause is **idiopathic**.

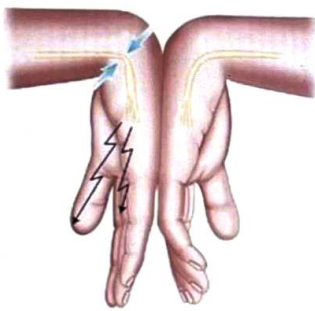
Pathology that increases pressure in tunnel :

- Colle's fracture.
- Amyloidosis.
- Acromegaly.
- Gout.
- Rheumatoid arthritis.
- Hypothyroidism.

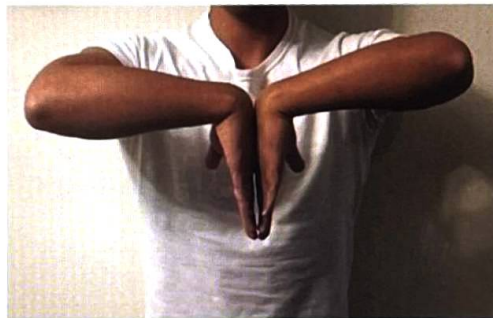Diagnosis :

Phalen's test : Patient is asked to hold their wrist in position as shown for 60 seconds. Causes compression of the median nerve and reproduces the symptoms.

kumarankitindia1@gmail.com



Phalen's test



Phalen's test

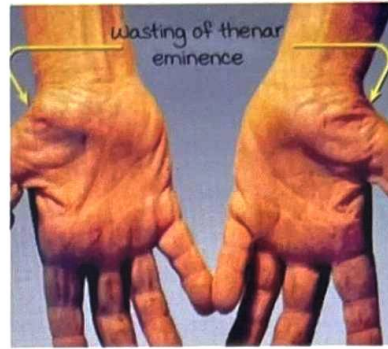


Reverse Phalen's test

Tourniquet test : Symptoms are reproduced on inflating the tourniquet.

Durkan's test : Direct median nerve compression by pressing over the nerve with the thumb (best clinical test).

Investigation of choice : **Nerve conduction study** (decreased velocity of impulse under carpal tunnel due to compression).



Treatment :

Early : Conservative, splint, improved ergonomics.

Late : Surgical, decompression by cutting the flexor retinaculum.

Thenar wasting is seen in later stages and is a poor prognostic sign.

60c6b3e88a8ded0e4e7e5ea7

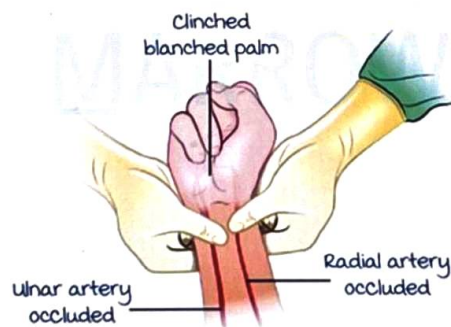
Allen's test : Done to assess the patency of ulnar & radial arteries before performing an arterial line.

Obstruct radial & ulnar artery → ask patient to continuously open & close the fist → hand becomes pale.

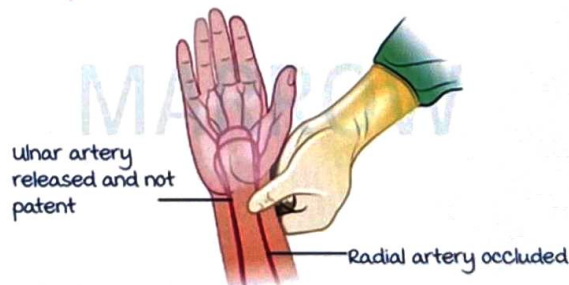
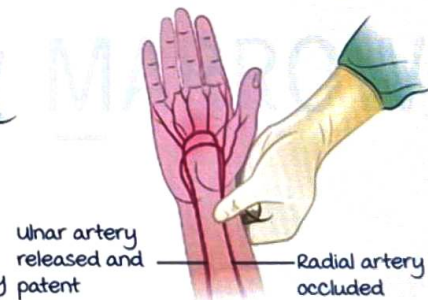
Release obstruction → vascularity returns.

If any one artery is not patent → flow will not resume.

modified Allen's test



modified Allen's test - Positive



modified Allen's test - Negative

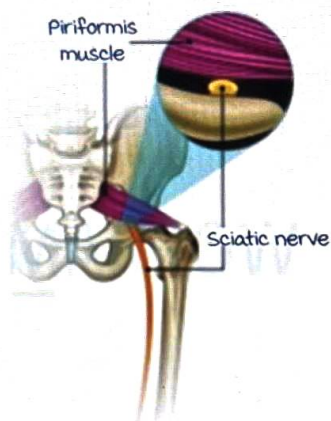
meralgia parasthetica : Entrapment of lateral cutaneous nerve of thigh under inguinal ligament.

Patient presents with burning sensation over the anterolateral

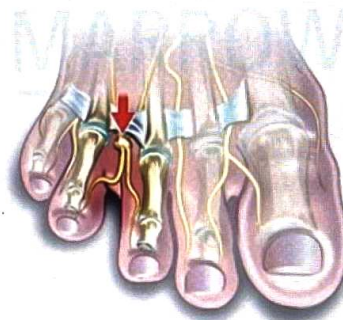
aspect of thigh. Seen in males who wear tight jeans and tight belts.

Piriformis syndrome : Entrapment of sciatic nerve under piriformis muscle.

morton's neuroma : Digital neuroma forming between the 3rd and 4th digits of the foot.

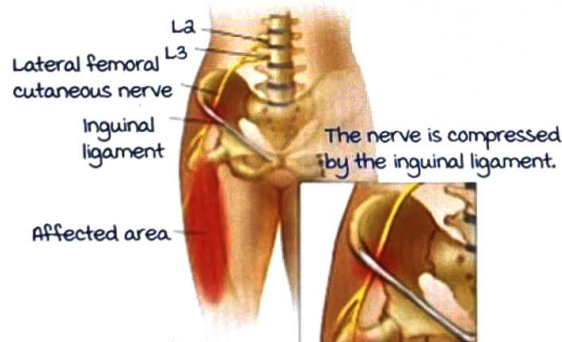


Piriformis syndrome



morton's neuroma

60c6b3eaa8ded0e4e7e5ea7



meralgia parasthetica

Entrapment neuropathies :

Syndrome/ pathology	Nerve	Site of compression/ injury
Carpal tunnel syndrome (mc)	median	At wrist
Cubital tunnel	ulnar	Behind the medial epicondyle of humerus
Guyon's canal	ulnar	Under the PISO-hamate ligament
Pronator syndrome	median Nerve	Heads of Pronator Teres

Active space

Kiloh - Nevin Syndrome	AIN	Supracondylar humerus #
Cheralgia parasthetica	Superficial radial nerve	Radial styloid, insertion of Brachioradialis (wrist watch, cuffs, bangles)
meralgia parasthetica	Lateral Cutaneous Nerve of thigh	Under inguinal ligament (tight Belt)
Pyriformis syndrome	Sciatic Nerve	Pyriformis & Obturator internus muscle
Tarsal tunnel syndrome	Posterior tibial Nerve	Behind medial malleolus below the flexor retinaculum of foot (RA)
morton metatarsalgia	Interdigital nerve of foot	Between 3 rd & 4 th toe

Popliteal artery entrapment syndrome (exercise induced claudication):

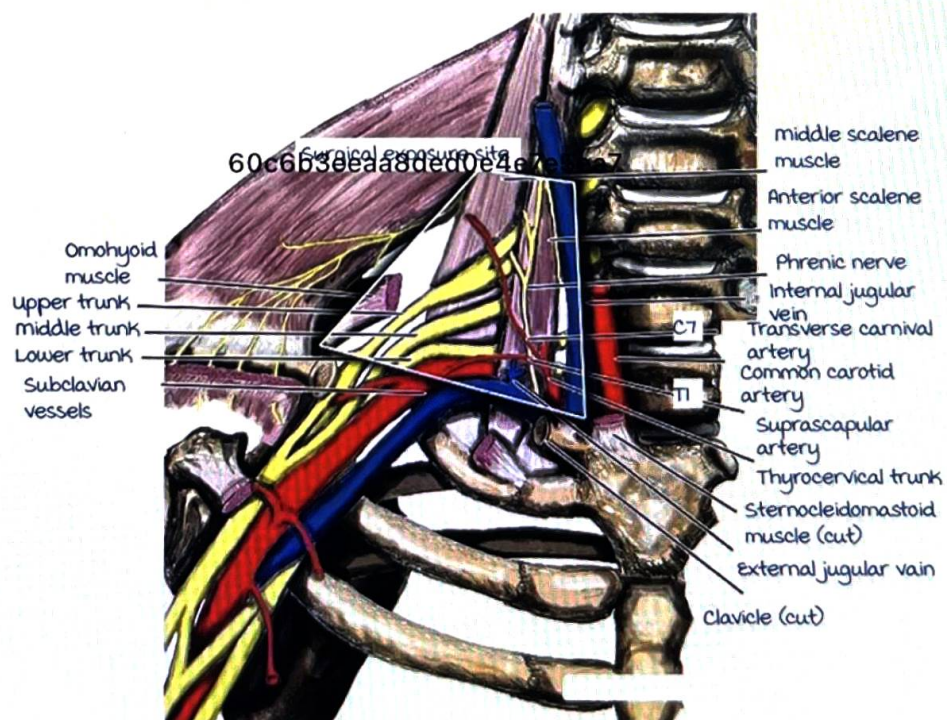
Certain individuals → medial head of gastrocnemius wraps around the popliteal artery → hypertrophied calf muscles (due to exercise) → kinking of popliteal artery → claudicatory pain in the posterior aspect of the leg. It is a congenital condition.

m/c injured artery: Popliteal artery (due to knee dislocation/distal femur fracture).

m/c injured artery in upper limb: Brachial artery (m/c cause is supracondylar humerus fracture).

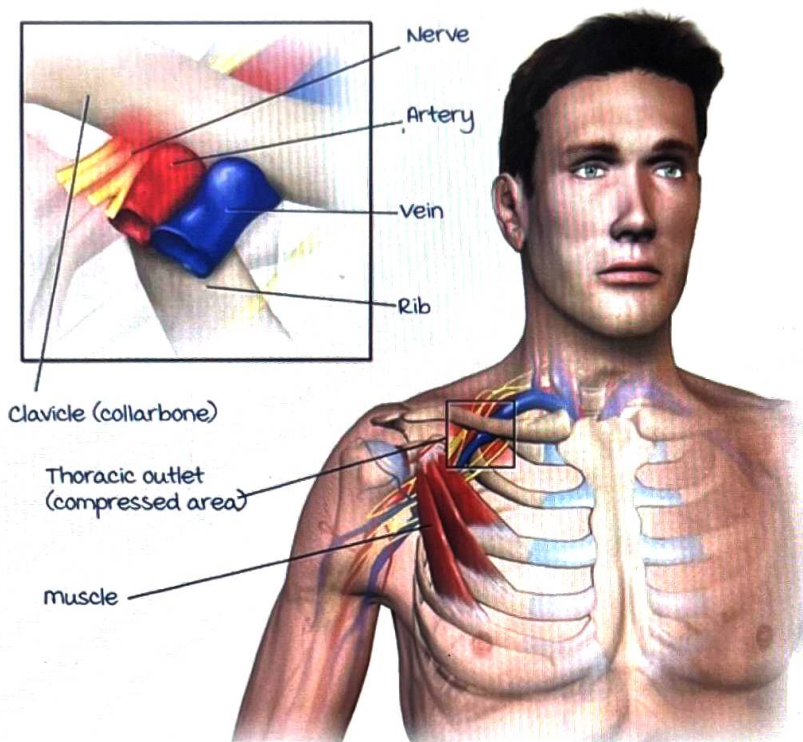
Thoracic outlet syndrome

00:28:14



Active space

Thoracic Outlet Syndrome



Boundaries of thoracic outlet :

1. Anterior scalene.
2. Posterior scalene.
3. Clavicle.
4. First rib.

Structures involved : Brachial plexus > artery/vein
Neuropathic manifestations > arterial/venous manifestation.

Cause : Abnormal 1st rib, hypertrophied scalene muscle or tumor.

Diagnosis : **Clinical diagnosis** .

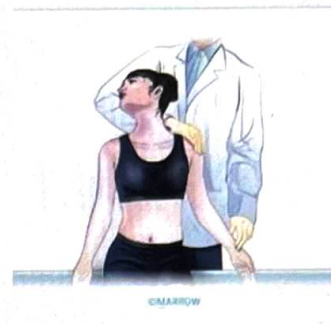Patient comes with upper limb pain (neuropathic/ claudication), pain is on particular posturing.

Adson's test : Abduct + externally rotate shoulder, while the pulse is being palpated, the patient is asked to turn the head towards the affected site, symptoms will be reproduced (decreased pulse/ claudication pain).

If patient is asked to turn the head in opposite direction it is called **reverse adson/halstead**.



Adson's test



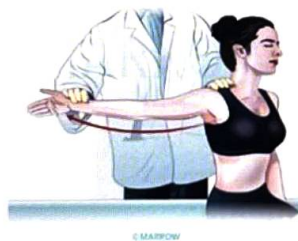Reverse adson/halstead

Wright's hyperabduction test : Hyperabduct elbow and shoulder with neck extension. Decrease in pulsation or increase in pain will be seen.

Roo's test : Abduct the shoulder & flex the elbow, open and close the hand for 3 mins.

Symptoms of claudication are seen.

Wright's hyper abduction test Roos test (Abduction with exercise)



Treatment :

Conservative management (rest, splint & physiotherapy).

Surgical excision of 1st rib.

MCQs :

Q. Tinel sign is used for which one of the following?

- A. To assess the severity of nerve damage.
- B. To classify the type of nerve injury.
- C. To locate the site of nerve injury.
- D. To assess the recovery of nerve injury.

- Q. A 17 yr old boy fell from motor bike on his shoulder and was diagnosed to be a case of Erb's palsy. All are true about the condition except?
- It is the commonest brachial plexus injury & involves upper trunks.
 - Erb's point is at the junction of anterior primary rami of C5 & C6.
 - Loss of shoulder abduction and lateral rotation with loss of elbow flexion and forearm supination.
 - Radioulnar joint pronation is lost, and supination is normal. (Supination is lost)
- Q. A 20 yr old male patient was involved in a single vehicle rollover accident. He presented with inability to abduct the shoulder and flex the elbow. On examination there was wasting of the supraspinatus, deltoid and biceps muscle. Which of the following is the most likely diagnosis?
- Shoulder dislocation.
 - Upper trunk injury of brachial plexus.
 - Lateral Cord Injury.
 - Musculocutaneous nerve injury.
- Q. All are true about median nerve injury except?
- Lunate dislocation causes its compression injury.
 - Anterior interosseous is its branch.
 - Hypoesthesia & wasting of thenar eminence.
 - Loss of adduction of thumb. (Adductor pollicis - ulnar nerve)
- Q. Compression of a nerve within the carpal tunnel produces inability to :
- Abduct the thumb. (Radial nerve)
 - Adduct the thumb. (Ulnar nerve)
 - Flex the distal phalanx of the thumb. (Anterior interosseous nerve before carpal tunnel)
 - Oppose the thumb.
- Q. Which of the following is a branch of ulnar nerve given in the arm?
- Branch to FCU.
 - Branch to FDP.
 - Branch to FCR.
 - None.

60c6b3eaaa8ded0e4e7e5ea

Active space

- Q. Which nerve is injured in a case of fracture medial epicondyle of humerus?
- Anterior Interosseous nerve.
 - Median nerve.
 - Ulnar nerve.
 - Radial nerve.
- Q. A boy presents with an injury to the ulnar Nerve at the medial condyle of humerus. All will be true about his presentation except?
- Paralysis of 3rd, 4th lumbricals and all Interossei.
 - Paralysis of FCU and Partial Flexor Digitorum profundus.
 - Hypothenar eminence atrophy and Hypoesthesia.
 - Complete paralysis and loss of sensation of 4th and 5th finger.
- Q. A patient comes to the emergency department after bingeing alcohol the previous night. He had fallen asleep on the chair at the bar. Since morning he has been unable to move his hand. A diagnosis of ulnar nerve palsy was made by the examining physician. What is the next line of management?
- Wait & watch.
 - Knuckle Bender splint.
 - Immediate exploration of nerve.
 - Do EMG study after 2 days.
- Q. Injury to radial nerve in spiral groove results in all except ?
- Spare long head of triceps.
 - Triceps lateral and medial head and anconeus are spared.
 - Involves muscles supplied by PIN.
 - Weakness in wrist, thumb & extension.
- Q. A person is not able to extend his metacarpophalangeal joint. This is due to injury of which nerve?
- Ulnar nerve.
 - Radial nerve injury.
 - Median nerve injury.
 - Posterior interosseous nerve injury.
- Q. A policeman found a person lying unconscious on right lateral position on the road with bruises on right arm and

60c6b3eeaa8ded0e4e7e5ea7

a bony injury to lateral aspect of right knee. Nerve most probably injured?

- A. Femoral nerve.
- B. Radial nerve.
- C. Common peroneal nerve.
- D. Trigeminal nerve.

Q. Carpal tunnel syndrome can be caused by all the following except?

- A. Diabetes mellitus.
- B. Amyloidosis.
- C. Addison's disease.
- D. Hypothyroidism.

60c6b3eeaa8ded0e4e7e5ea7

Q. A patient can make a fist but can't flex his index finger. Which nerve is affected?

- A. Radial nerve.
- B. Ulnar nerve.
- C. musculocutaneous nerve.
- D. median nerve.

Q. A patient met with a RTA, following which he cannot abduct his right arm. On examination there is tenderness at right upper arm. X-ray shows a fracture surgical neck of humerus. Which of the following muscle is also supplied by the involved nerve?

- A. Subscapularis.
- B. Suprascapularis.
- C. Infrascapularis.
- D. Teres minor.

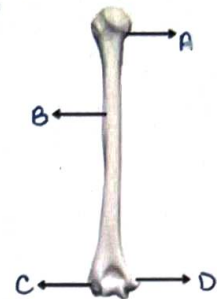
Q. A patient came with complaints of inability to move his 4th and 5th digit, cannot hold pen and he was not able to hold paper between fingers. Which of the following site given below is the probable cause of injury to the nerve in question?

- A. A
- B. B
- C. C
- D. D
- E.

Active space

Q. A Patient came with supracondylar fracture of humerus. On examination patient is unable to flex the interphalangeal joint of thumb. Which nerve is likely injured?

- 6063
 A. Deep branch of radial.
 B. Superficial branch of ulnar.
 C. PIN.
 D. AIN.

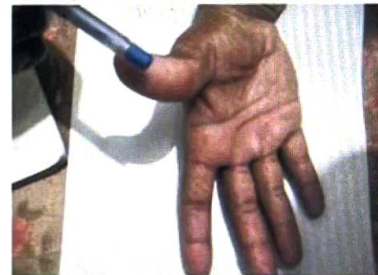

Q. The following test is performed to assess :

- A. Posterior interosseous nerve.
 B. median nerve.
 C. Ulnar nerve.
 D. musculocutaneous nerve.

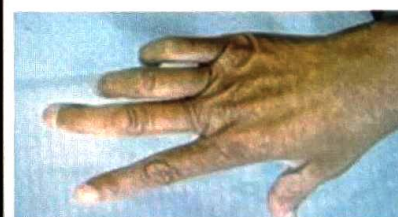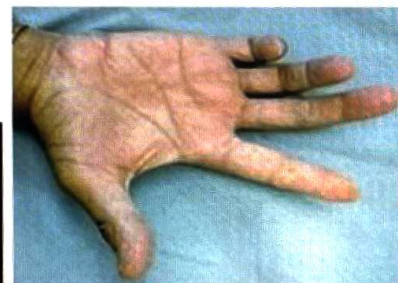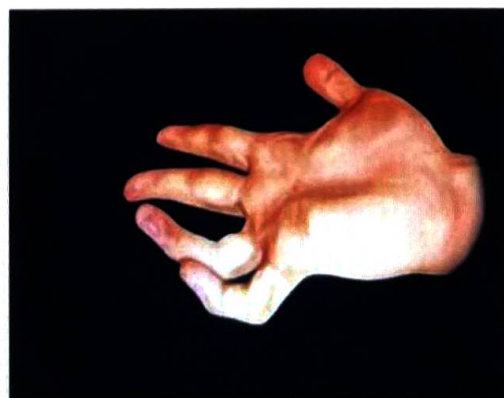Q. If the outer sheath and nerve fiber remains intact, but the inner axon is damaged, which type of nerve injury is it known as?

- A. Neuropraxia.
 B. Axonotemesis.
 C. Axonpraxia.
 D. Neurotemesis.



Q. Which nerve injury causes the deformity shown in the image?

- A. Ulnar Nerve.
 B. Radial Nerve.
 C. median Nerve.
 D. Musculo Cutaneous Nerve.



BONE TUMORS : PART 1

History of orthopedic oncology

00:02:16

William Enneking : Father of orthopaedic oncology.

Staged Bone tumours :

- Benign.
- malignant.



60c6b3e6aa8ded0e4e7e5ea7

Enneking classification :

Benign	malignant	
1. Latent	I - Low grade	A - Intracompartmental B - Extracompartmental
2. Active	II - High grade	A - Intracompartmental B - Extracompartmental
3. Aggressive	III - metastasis	

(Intra compartmental : Tumours grows within the bone.

Extra compartmental : Tumour grows beyond bone and soft tissue)

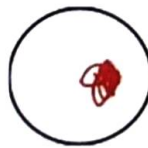Latent : Thick Capsule eg., Non ossifying fibroma.

Active : Thin Capsule eg., Aneurysmal bone cyst.

Aggressive : Capsule is breeched eg., Giant cell tumour.



Latent



Active



Aggressive

WHO classification of bone tumors :

Tumor like lesions :

- Fibrous cortical defect/Non-ossifying fibroma.
- Fibrous dysplasia.
- Bone cysts : Simple bone cysts and aneurysmal bone cysts.

Ambiguous :

Osteochondroma : Can grow and develop into malignancy.

Active space

True tumors : Stops to grow when skeleton matures.

Cell type	Benign	malignant
Chondrocytes	Enchondroma	Chondrosarcoma
	Chondroblastoma	
Osteoblasts	Osteoid Osteoma	Osteosarcoma
	Osteoblastoma	
Osteoclasts	Osteoclastoma	

miscellaneous tumors	
Hemangioma	Ewing sarcoma
Benign	malignant
Vascular tumor	Endothelial lining of bone marrow

Appearance on X- ray

00:12:40

Cell type	On X-ray
Chondrocytes	Lucent or hazy with calcification.
Osteoblasts	Dense or sclerosed.
Osteoclasts	Bone destruction.

Location in the bone :

Diaphysis :

- Ewing's Sarcoma.
- Osteoid osteoma.
- Adamantinoma (Soap bubble).
- Fibrous dysplasia (Diaphysis > metaphysis).

metaphysis :

- Osteosarcoma.
- Osteochondroma.
- Aneurysmal bone cyst.
- unicameral bone cyst.
- Non-ossifying fibroma / Fibrous cortical defect (metaphysis > Diaphysis).

Epiphysis :

- Giant cell tumor (after skeletal maturity) : Soap bubble on X ray.
- Chondroblastoma (before skeletal maturity) : Stippled calcification on X ray.

Nature of tumor :

Benign	Benign +++	malignant
Osteoid osteoma	Giant cell tumor	Chondrosarcoma
Simple bone cysts	Osteoblastoma	Osteosarcoma
Aneurysmal bone cysts	Osteochondroma	Ewing sarcoma
	(At risk of turning malignant)	Adamantinoma
		Chordoma

Age groups :

Age	Tumors
5 - 25 years	Ewing sarcoma (2 nd decade > 1 st decade).
10 - 20 years	Primary osteosarcoma.
20 - 40 years	Giant cell tumor.
40 - 60 years	Secondary Osteosarcoma, Chondrosarcoma.
>60 years	metastasis, multiple myeloma, adamantinoma, chordoma.

m/c malignant bone tumors of 1st decade : Ewing sarcoma.

Ewing sarcoma : most commonly seen in 2nd decade of life.

m/c malignant bone tumor in children : Osteosarcoma (m/c in 2nd decade).

Causes of Secondary osteosarcoma : Paget's disease (very important).

Periosteal reaction

00:23:34

60c6b3eeaa8ded0e4e7e5ea7

Reaction of periosteum.

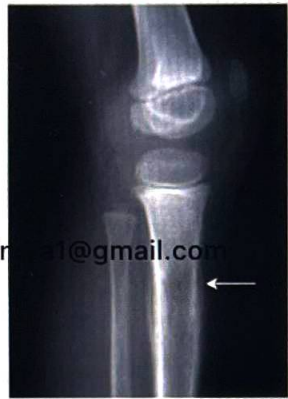Functions of periosteum :

- Provide nutrition.
- Bone growth.

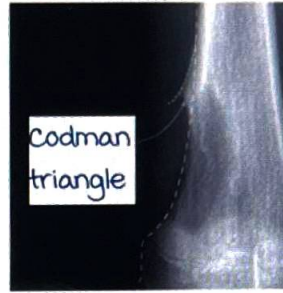Any insult to bone → Periosteum reacts → Contains spread
→ Periosteal reaction.

Active space

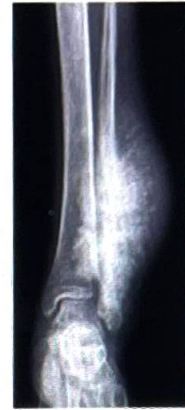Periosteal reaction	Tumor/Lesion
Onion peel	Ewing sarcoma
Sunburst	Osteosarcoma
Codman's triangle	Osteosarcoma
Solid	Osteomyelitis



Onion peel : Ewing's sarcoma



Codman triangle



Sunburst : Osteosarcoma

kumarankitir@gmail.com

Pulsatile bone tumors :

- Osteosarcoma.
- Aneurysmal bone cysts.
- Giant cell tumor.
- METS from kidney.
- METS from thyroid.

Polyostotic lesions (multicentric) :

- Fibrous dysplasia.
- Giant cell tumor.
- Enchondroma.
- Osteochondroma.

Fibrous cortical dysplasia (FCD)/ non-ossifying fibroma

00:29:19

Eccentric cortical lesion.

Part of cortex replaced by fibrous tissue.

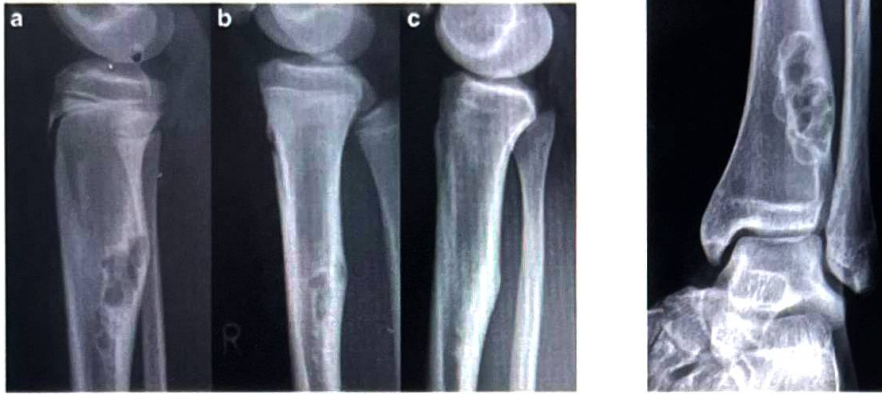m/c at distal femur.

m/c lesion of the bone.

usually occurs in the first decade.

Occurs in metaphysis.

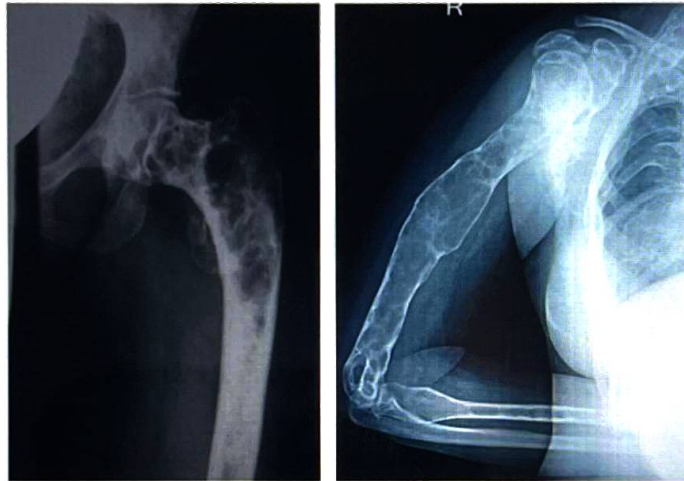
Self-resolving and asymptomatic.



Fibrous dysplasia :

Developmental anomaly of the bone.

Bone tissue replaced by fibrous tissue + woven bone (immature).



Types :

- monostotic (femur) : most common type - affecting one part of bone.
- Polyostotic (maxilla > femur) - affects multiple parts of bone.

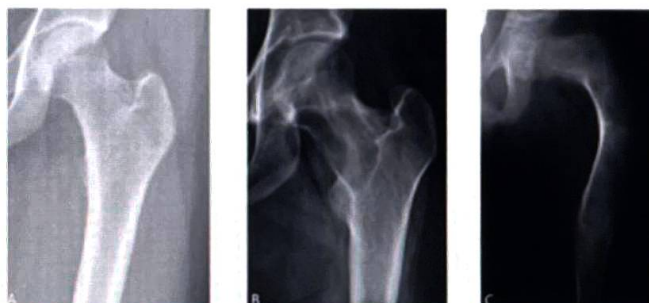kumarankitindia1@gmail.com

X ray :

Ground glass appearance (lucency and haziness).

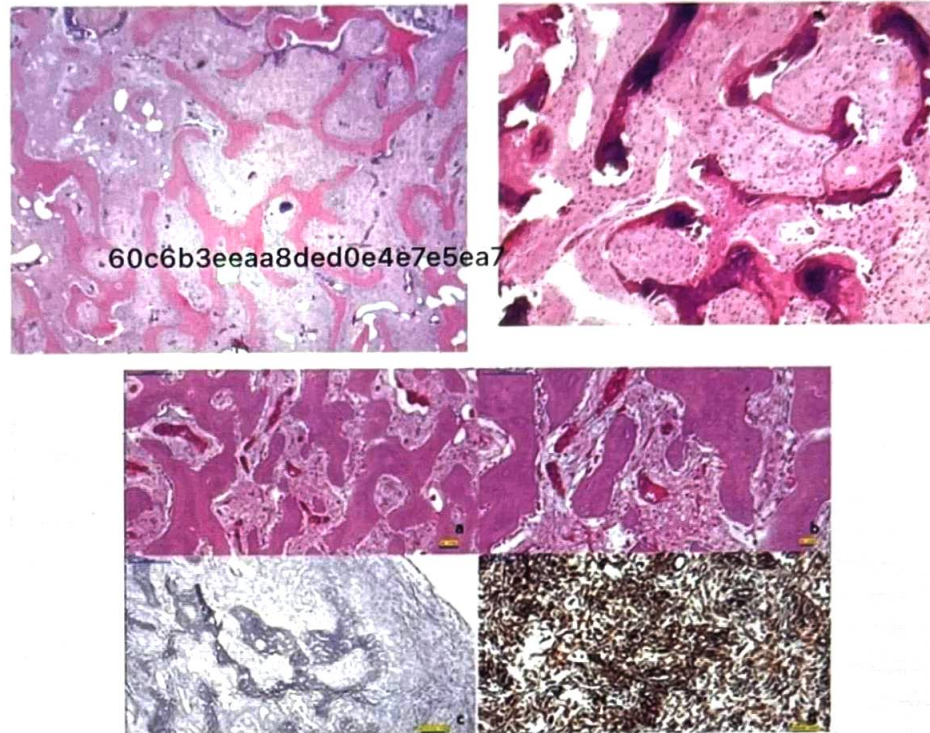
RIND sign (dense sclerotic area around lucency).

Shepherd crook deformity.



Active space

Biopsy : Chinese letter pattern.



Treatment : Bisphosphonates.

Syndromes associated with fibrous dysplasia :

McCune's Albright syndrome :

3 P's :

- Polyostotic fibrous dysplasia (multi-centric not metastatic).
- Pigmentation : Café au lait spots → (Coast of maine/irregular).
- Precocious puberty.

Mazabraud syndrome :

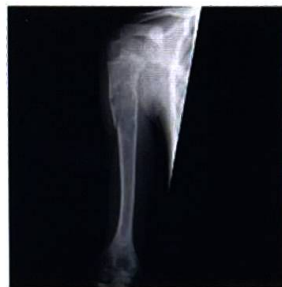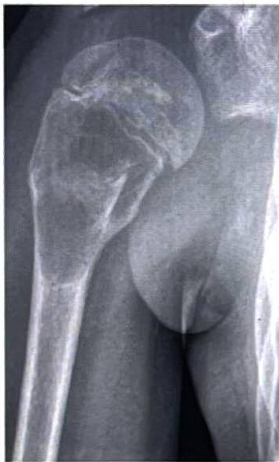- Polyostotic fibrous dysplasia.
- Intramural (muscular) myxoma.

Bone cysts

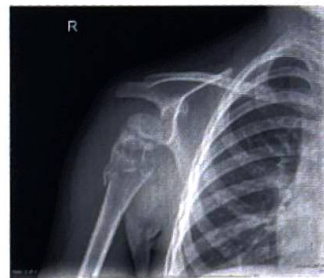
00:36:39

Simple bone cyst / unicameral bone cyst	Aneurysmal bone cyst
Benign, unilocular.	Benign, multiloculated.
Symmetrical expansion.	Asymmetrical expansile / ballooning.
Centric	Eccentric

metaphyseal	metaphyseal
10 - 20 years (younger)	10 - 20 years (older)
Proximal humerus	Around knees
Clear/straw colored	Blood
Treatment : Aspiration +/- injection. • Steroids/sclerosants. Excision and curettage + Autologous bone graft (ABG).	Treatment : Extended curettage. To kill residual tumour cells • Liquid nitrogen (minimize recurrence), bone cement, phenol. Embolization (pelvis).



Trap door sign

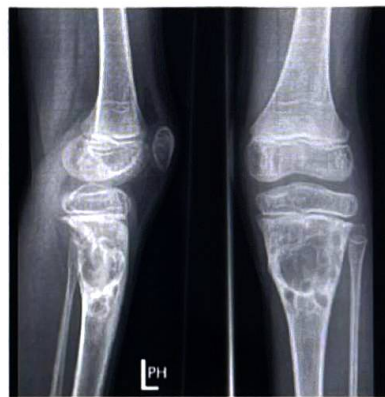

Fallen fragment/
Fallen leaf

Simple bone cyst

How to identify the cysts on X ray :

- Part of the body.
- Part of the bone.
- Skeletal maturity.
- Description of the lesion.
- Other classical findings.



Aneurysmal bone cysts.

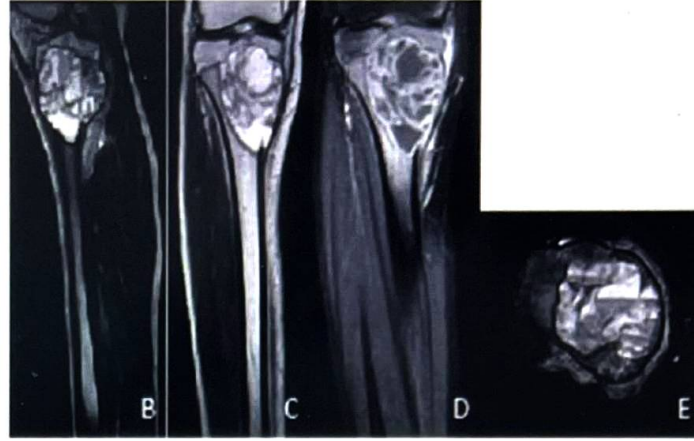
Correlate with clinical history .

multiple fluid levels in a lesion : multiloculated, fluid -filled level containing bone lesions are best seen on MRI.

1. Aneurysmal bone cyst.
2. Giant cell tumor.
3. Telangiectatic osteosarcoma.

kumarankitindia1@gmail.com

Active space



Cysts like lesions in bone

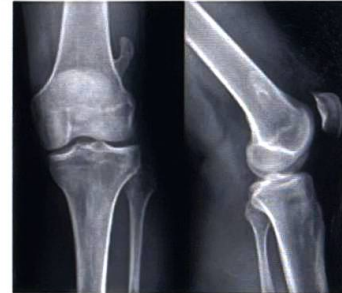00:46:39

60c6b3eeaa8ded0e47c5eb7

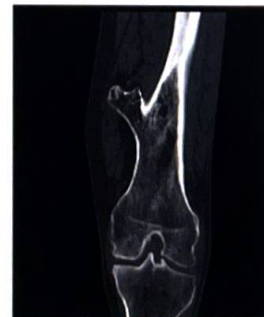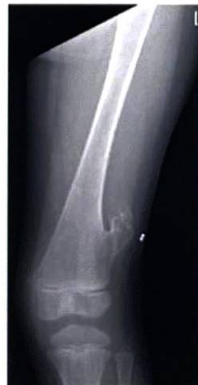Centric	Expansile/Eccentric
Simple bone cyst	Giant cell tumor
Enchondroma	Aneurysmal bone cyst
Brodie's abscess	Non ossifying fibroma / FCD (m/c)

Osteochondroma / Exostosis :

- m/c benign bone tumor.
- Developmental malformation of growth plate.
- Can be sessile / pedunculated.
- Stalk grows away from joint line.
- Large to feel but small on X-ray.
- Cartilage cap < 2cm.
- Stops growing after skeletal maturity.
- m/c site : Distal femur.



Exostosis : Architecture matches normal bone.



Active space

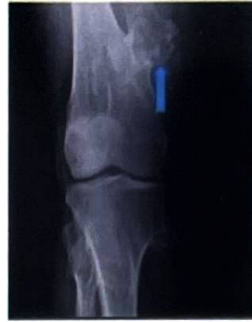Clinical features :

Asymptomatic, grows with skeleton.
Stops with skeletal maturity.

Causes of pain :

- Bursitis (m/c).
- Nerve compression.
- Fracture.
- malignant transformation : Chondrosarcoma (rarely)
 - a. > 2cm cartilagenous cap.
 - b. Heavy calcification.
 - c. Persistence of growth after skeletal maturity.

Rx : Extra periosteal excision after skeletal maturity.



Hereditary multiple exostosis / Diaphyseal aclasis

00:54:56

60c6b3eaaa8ded0e4e7e5ea7

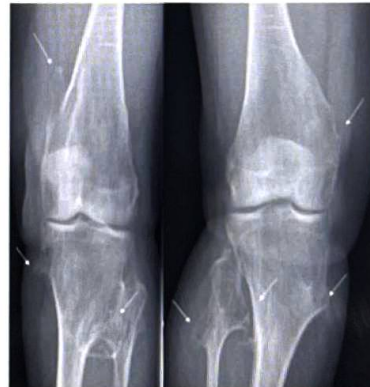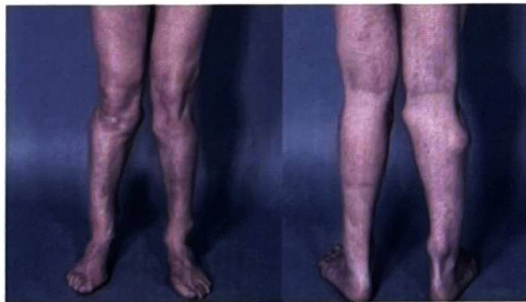Autosomal dominant.

EXT 1, 2 gene mutations.

5% can progress to chondrosarcoma.

Diaphysis is misnomer.

multiple exostosis : Swelling around joints



Chondroma :

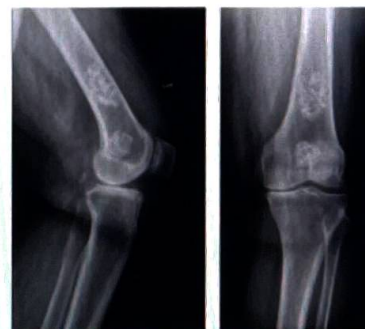Tumors of hyaline cartilage.

Enchondroma : Arise from medullary cavity.

Calcifications in cartilaginous lesion :

Popcorn calcification/ring and arc calcification / O ring sign :

- Chondroma.
- Chondrosarcoma.
- Pulmonary hamartomas.
- Fibroadenoma of breasts.



Active space

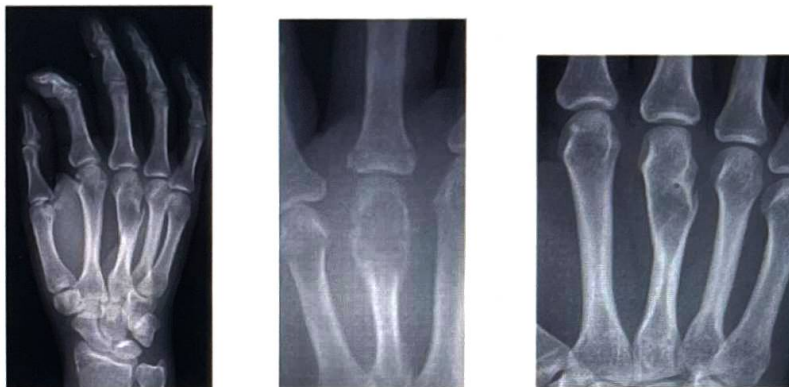Enchondroma :

m/c tumors of bones of **hand/feet**.

m/c tumors of hand : **Squamous cell carcinoma**.
metaphyseal.

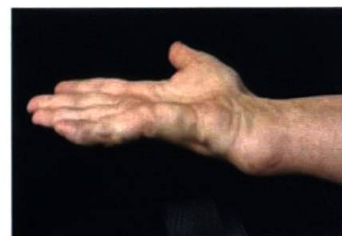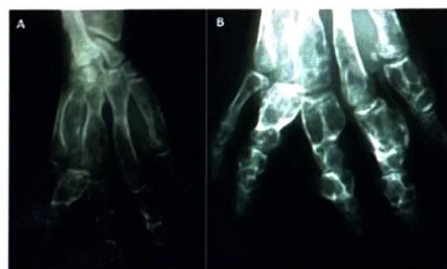Treatment : Excision curettage + ABG.

D/D metacarpal swelling : **Spina ventosa** (TB of phalanges).



Associated syndromes (Sporadic) :

Ollier's syndrome	Maffucci's syndrome
Multiple enchondromas. 30% cases are premalignant.	Multiple enchondromas. Cavernous hemangiomas. Lymphangiomas, phleboliths. 100% cases are premalignant.



Maffucci Syndrome

Chondroblastoma

01:01:06

AKA **Codman's tumor**.
60c6b3eeaa8ded0e4e7e5ea7
epiphyseal lesion.

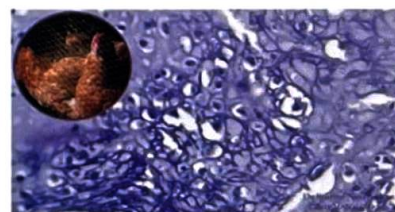
(10-25) years : **Before skeletal maturity**.

Distal femur > Proximal tibia, proximal humerus.

X-ray : Punctate/Stippled calcification.

Treatment : Excision curettage + ABG.

Biopsy : **Chicken wire calcification**.



Active space

Osteoid osteoma : Benign osteoblastic tumour, abnormal osteoid surrounded by osteoma.

m/c true benign tumor.

Children (particularly adolescents).

Diaphysis.

Femur.

Eccentric/cortical lesion.

Classically causes night pain that is relieved by salicylates analgesia. Eg, Aspirin.

X ray findings :

Central nidus (< 2 cm).

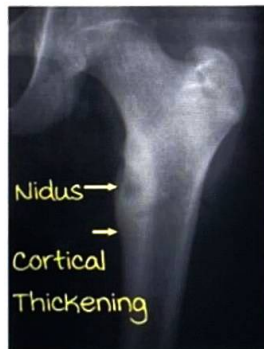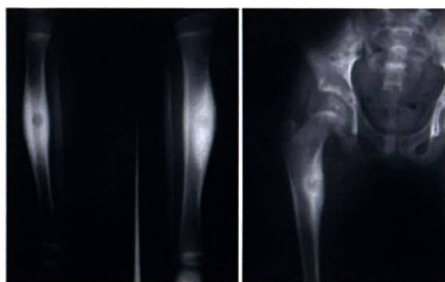Dilated blood vessels.

Osteoblasts.

Osteoclasts/woven bone.

Dense sclerotic rim around central nidus.

Central nidus releases prostaglandins causing pain.



Treatment :

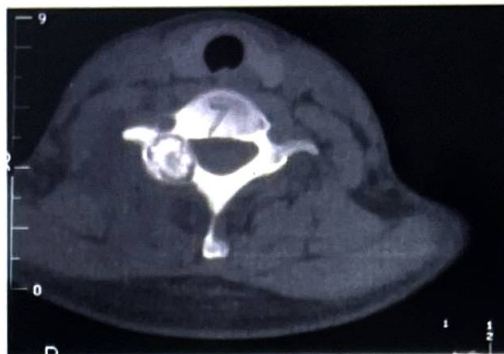
- NSAIDs.
- Radio frequency ablation.
- Excision curettage.
- MRgFUS.

kumarankitindia1@gmail.com

Osteoid osteoma vs Osteoblastoma :

Central nidus > 2cm is osteoblastoma.

- Spine.
- Does not respond to aspirin.
- Risk of becoming malignant osteoblastoma → Osteosarcoma.
- Treatment : Excision.



Giant cell tumor / osteoclastoma

01:08:03

Locally aggressive.

Epiphysio-metaphyseal : Can grow up to cartilage or joint (upto 1 - 1.5 cm).

Females > males.

20-40 years (after skeletal maturity) kumarankitindia1@gmail.com

Location :

Knee lower end of femur (m/c).

upper end of tibia.

Distal end of radius.

Clinically : Egg shell cracking (thin cortex)

X-ray : Soap bubble appearance.

Biopsy :

multinucleated osteoclast like giant cells surrounded by mononuclear cells.

Nucleus of the mononuclear cell and giant cells are the same.

Tumor cells are the stromal mononuclear cells (**RANK +**).

< 5% risk of malignant transformation & metastasis to lungs.

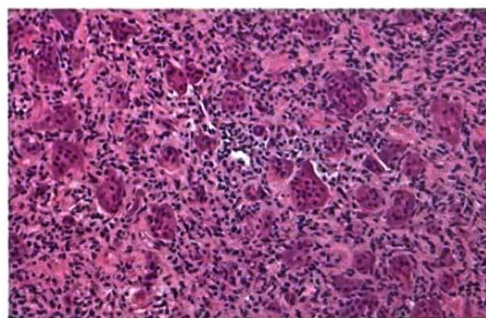
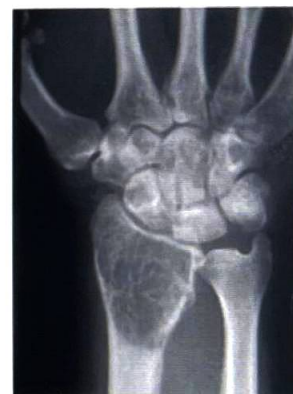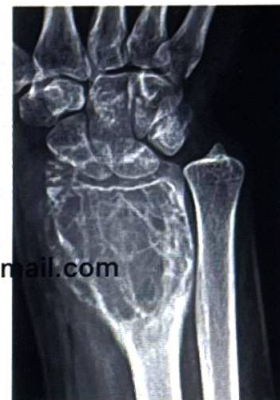Treatment :

Extended curettage :

- Liquid nitrogen.
- Bone cement.
- Phenol.

ε for GCT :

- Epiphysis.
- Epiphyseal fusion.
- Eccentric.



- Expansile.
- Egg shell crackling.
- Extended curettage.

more common in females.

GCT variants

01:14:19

- Non ossifying fibroma (m/c).
- Aneurysmal bone cyst (closest resemblance).
- Chondro myxoid fibroma.
- Chondroblastoma.
- Fibrous dysplasia.
- Simple bone cysts.
- Brown's tumor.
- Osteosarcoma (telangiectatic).

Hemangioma :

Elderly population.

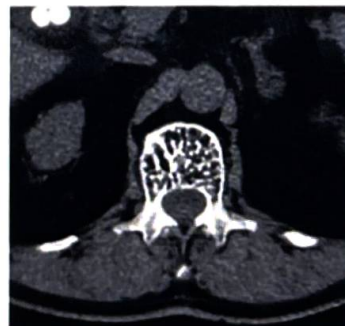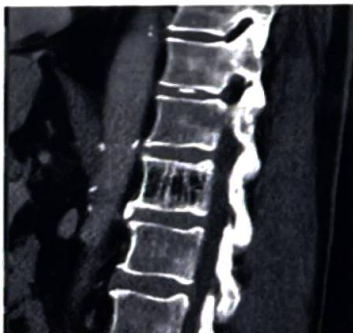Benign, asymptomatic, vascular tumor of the bone.

Spine > Skull > Pelvis.

X ray : Vertical striations giving a jail bar/jail house appearance.

- Striations.
- Corduroy appearance.

CT scan : Polka dot sign.



Treatment :

Conservative.
+/- radiotherapy.
vertebroplasty.

Active space

BONE TUMORS : PART 2

Malignant tumors

00:00:13

Chondrosarcoma :

Best prognosis among the malignant tumors of the bone.

metaphyseal.

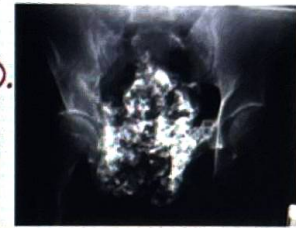
40 to 50 years.

Calcified tumor in pelvis, proximal femur (Popcorn/ring & arc calcification).

Radio & chemoresistant

Hyperglycemia (para neoplastic syndrome).

Rx : Surgery.



Osteosarcoma :

Osteoblastic malignant tumor.

m/c bone tumor in children.

m/c bone tumor in children occurring in 2nd decade (Primary osteosarcoma).

Primary osteosarcomas : Occurs in 10 to 20 years of age group).

Secondary osteosarcomas :

In older population (occurs in 40 to 60 years of age group).

mcc : Paget's disease.

Fibrous Dysplasia.

Exposed to Radiation.

Primary osteosarcoma is more common than Secondary osteosarcoma.

metaphyseal tumor (distal end of femur).

most radioresistant tumor.

mc radiation induced bone tumor.

(most common radiation induced tumor : Blood tumors).

It is a bone forming tumor forming with abnormal osteoid & matrix.

15% will have micro metastasis to lungs during presentation & can present as pneumothorax.

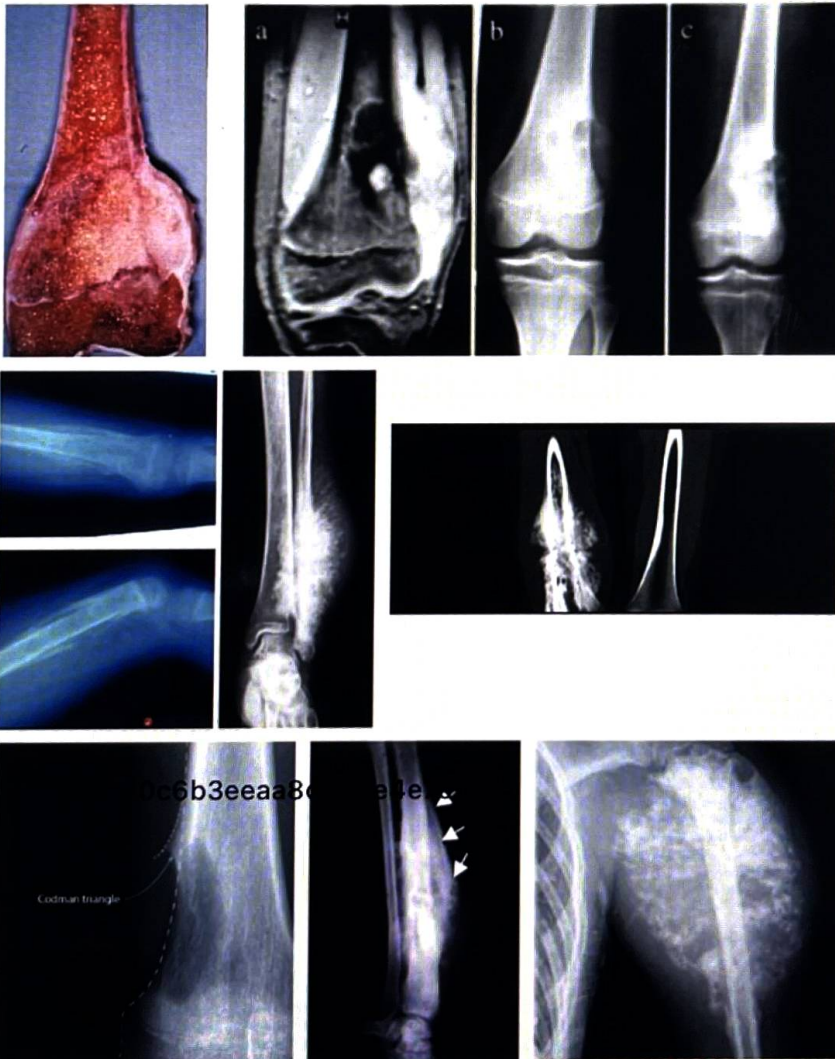
Radiation induced osteosarcoma usually occurs after 10 years of exposure.

most commonly occurs at skull.

Paget's disease can cause 2° osteosarcoma of pelvis.

Xray :

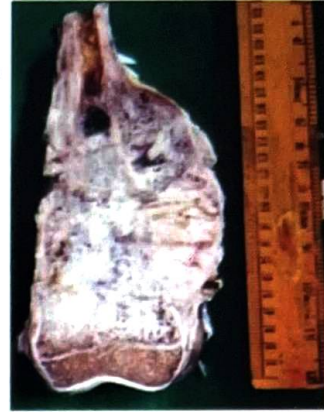- Sunray/sunburst appearance : Calcification of Sharpey's fibres.
- Elevated periosteum : **Codman's triangle** (bone will form under the periosteum that is elevated in the shape of a triangle).



Active space

Types :

1. Classical / Intramedullary (m/c).
2. Periosteal.
3. Parosteal (Favorable prognosis).
 - Posterior femur.
4. Telangiectatic.



Rx :

Neoadjuvant chemotherapy (chemotherapy before surgery) for metastasis.

Surgery / Limb ablation.

Adjuvant chemotherapy (chemotherapy after surgery) to prevent recurrence.

Chemotherapeutic agents of TIO Protocol (Committee) :

- Actinomycin, Bleomycin, Cyclophosphamide, Doxorubicin, High dose methotrexate, Vincristine.

70% : 5 year survival.

Ewing sarcoma

00:06:14

kumarankitindia1@gmail.com

m/c Tumor of 1st decade.

m/c occurs in 2nd decade.

- Always high grade.
- 5-20 years.

Femur & diaphysis.

male > Female.

Poor Prognostic Factors :

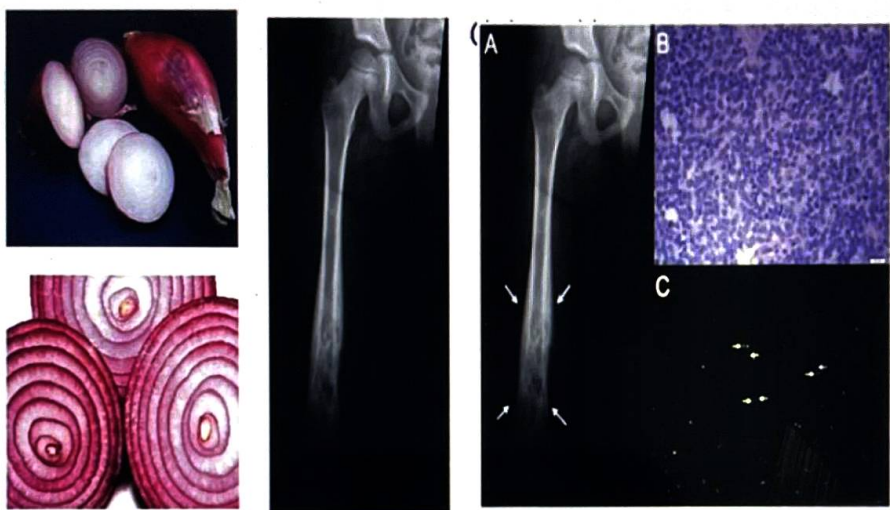
- Metastasis.
- Size of lesion.
- Fever, anemia.
- Leukocytosis.
- Male, Age > 12.
- Elevated ESR.
- Chemoresistance.
- Relapse.

Clinical features :

- Can present like infection (also Osteosarcoma).
- Swelling in the middle of thigh or leg.
- Signs of inflammation.
- Clinical and labs.
- Incidental history of trauma.

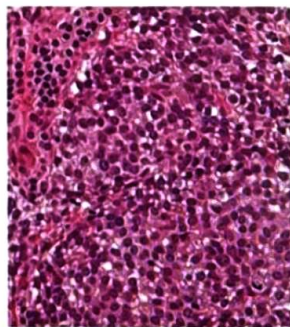
Xray :

Onion peel appearance or lamellated appearance (periosteal reaction to a very rapidly growing aggressive malignant tumor).



Biopsy :

- Investigation of choice.
- Variable consistency.
- Small blue round cells with pseudo rosette.
- Staining :
PAS positive & diastase digestible.
MICA (CD99) : Specific marker.



Arises from the endothelial lining of bone marrow : mesoderm, but biopsy that is ectodermal, due to :

Translocation :

- t (11 : 22) : m/c
- 21 : 22
- 7 : 22
- Trisomy 8.
- Trisomy 21.

Active space

Other primitive neuroectodermal tumors / small round blue cell tumors :

Neuroblastoma
medulloblastoma
Retinoblastoma

Treatment :

- Radiosensitive.
- Trend is towards surgical resection/away from RT because of morbidity associated with radiation and risk of secondary malignancies.
- Rx : **Chemotherapy** + limb salvage/**resection** ± adjuvant radiation.

Chordoma

00:12:36

MC location :

- Sacrum.
- Base of skull.
- vertebrae.

2nd MC : Primary malignancy of spine after multiple myeloma.

Vacuolated **physaliferous cells** of primitive notochord.

Rx : Surgery, Radiation.
60c6b3eaa8ded0e4e7e5ea7

Adamantinoma :

malignant (low grade).

Aberrant epithelial cells grow into the bone (epithelial tumors move into the bone).

MC bone : **Tibia** (subcutaneous bones).

MC feature : Pain.

xray : multiple radiolucent lesions

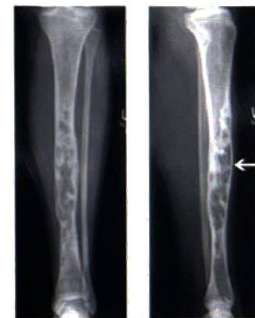
Honeycomb / Soap Bubble appearance (only in diaphysis).

Rx : Wide resection / amputation.

Radio / chemo resistant.

Ameloblastoma : mandible (m/c Tumor of mandible is SCC).

Aberrant epithelial cells around the mandible.



Synovial Sarcoma (misnomer) :

Does not arise from synovium.

Arises from joint capsule, bursae, tendon.

Around knee or elbow.

T(X:18) gives rise to SYT : SSX fusion genes.

Biphasic tumor : Epithelial + mesenchymal.

Rx : Surgery.

most commons in orthopedic oncology :

m/c malignant bone tumor : metastasis.

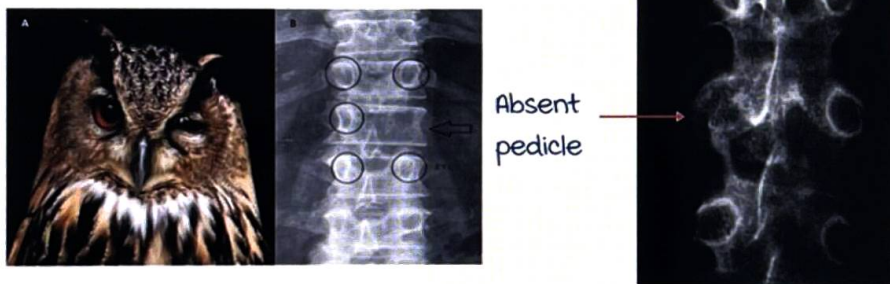
Secondaries to bone :

m/c Source is Breast > prostate > Lungs.

mC cause in children : Neuroblastoma

most commonly affects : Lumbar vertebrae > Thoracic vertebrae.

xray of spine in metastasis shows Winking owl sign due to destruction of pedicle.



Characteristics of secondaries :

Purely blastic :

- Prostate.
- medulloblastoma.
- Carcinoids.

Purely lytic :

- Kidney (RCC).
- Thyroid (Follicular carcinoma).

kumarankitindia@gmail.com

Breast : Lytic, mixed

Bone tumors that metastasize to other bones (Bone to bone metastasis) :

- Ewing Sarcoma.
- Osteosarcoma.

Most commons in orthopedic oncology

00:19:45

- m/c malignant bone tumor : metastasis.
- m/c Primary malignant bone tumor :
multiple myeloma > Osteo Sarcoma.
- m/c Primary non-hematological malignant bone tumor :
Osteo Sarcoma > Chondrosarcoma.
- m/c Benign bone tumor : Osteochondroma.
- m/c True benign bone tumor : Osteoid osteoma.
- most common bone lesions : Fibrous cortical defect.

Q. Tumor that produces maximum bone matrix.

- A. Osteoid osteoma.
 - B. Chondrosarcoma.
 - C. Enchondroma.
 - D. None.
- } Cartilage producing

Q. Which is not a metaphyseal tumor?

- A. Osteosarcoma.
- B. Chondrosarcoma.
- C. Giant cell tumor. (occurs only after growth plate fusion)
- D. Aneurysmal bone cyst.

Explanation : 2 epiphyseal tumors- GCT, Chondroblastoma.
2 diaphyseal tumors- Ewing sarcoma, osteoid osteoma.
All others are metaphyseal.

Q. All are true regarding locations of bone tumor

60c6b3eeaa8ded0e4e7e5ea7 except :

- A. Osteoclastoma, chondroblastoma are epiphyseal.
- B. Osteosarcoma, chondrosarcoma, osteomyelitis & bone cyst are metaphyseal.
- C. Ewing's sarcoma, osteoid osteoma is metaphyseal.
- D. Fibrous dysplasia is diaphyseal but osteochondroma metaphyseal.

Explanation : Ewing's sarcoma, osteoid osteoma is diaphyseal.

Q. Which of the following is the most common mutation seen in Ewing's sarcoma?

- A. Translocation X : 18.
- B. Translocation 11 : 22.
- C. Mutation of G5 alpha surface protein.
- D. Missense mutation in EXT1.

Explanation : Translocation 11 : 22 (that's why a neuroectodermal tumor rises at the mesodermal location).

Q. An 11 year old boy presented with the complaints of pain in the right arm near the shoulder. X ray examination revealed an expansile lytic lesion in the upper third of humerus. The most likely diagnosis is :

- A. Giant cell tumor. (occurs after growth plate fusion)
- B. Unicameral bone cyst.
- C. Osteochondroma. (no mention of lesion growing in size)
- D. Parosteal osteosarcoma.

Q. Ramu, a 16 year old boy presented with pain in the arm. On X ray his upper end of humerus demonstrates an expansile lesion in the metaphysis with breach of the overlying cortex. Most likely diagnosis is?

- A. Aneurysmal bone cyst.
- B. Unicameral bone cyst.
- C. Chondroblastoma.
- D. Osteoclastoma.

Osteoclastoma occurs after growth plate fusion.

Chondroblastoma is epiphyseal.

Slightly older & breach in cortex : Aneurysmal bone cyst.

Q. All are true about aneurysmal bone cyst except :

- A. Eccentric.
- B. Expansile and lytic.
- C. Treated by simple curettage.
- D. Metaphysis of long bones.

Explanation : Aneurysmal bone cyst : Treated by extended curettage (with liquid N₂ or bone cement). Extended

600684e6d5d054e75547 GCT.

Q. A 12 year old boy presents with a symmetric, expansile cystic lesion in the proximal humerus. All the following can be done for his treatment except :

- A. Curettage.
- B. Intralesional steroids.
- C. Intralesional sclerosing agents.
- D. Radiotherapy.

Explanation : Symmetric- Simple bone cyst.

Radiotherapy is not required for simple bone cyst.

Q. Paget's disease after 10 years of presentation can develop into?

- A. Osteosarcoma.
- B. Fibrous cortical defect.
- C. Osteoid osteoma.
- D. Ankylosing spondylitis.

Explanation : Paget's disease → long term → increased risk of osteosarcoma (secondary).

Q. 8 year old child has fever with pain and swelling in mid thigh. X ray reveals lamellated appearance and Codman's triangle. Histopathology shows small round cell tumor positive for MIC-2. The diagnosis is?

- A. Osteosarcoma.
- B. Ewing's sarcoma.
- C. Chondroblastoma.
- D. Multiple myeloma.

Explanation : mid thigh is diaphysis.

Ewing's sarcoma : Diaphyseal.

Osteosarcoma : metaphyseal.

Chondroblastoma : Epiphyseal

Questions (continue)

00:27:25

Q. A 7 year old boy with h/o trauma 2 months back, presents with fever and acute pain over thigh. On X ray femoral shaft shows lesions with multiple laminated periosteal reaction. What is the next line of management?

- A. CRP measurement.
- B. Core biopsy.

C. Tc99 MDP scan.

D. MRI.

Explanation : Diagnosis : Ewing sarcoma.

Next step : MRI (to see extent of spread of disease).

Best investigation : Biopsy.

Q. A 10 year old boy presents with a cortex based radiolucent lesion surrounded by reactive sclerotic margins in the middle of the shaft of tibia. The most likely diagnosis is :

A. Osteoid osteoma.

B. Osteosarcoma.

C. Fibrous cortical defect.

D. Fibrous dysplasia.

Explanation : middle of the shaft of tibia : Diaphysis.

Q. A 14 year old boy presented with painful swelling over the left shoulder. Radiograph of the shoulder showed an osteolytic area with stippled calcification over the proximal humeral epiphysis. Biopsy of the lesion revealed an immature fibrous matrix with scattered giant cells. Which of the following is the most likely diagnosis?

A. Giant cell tumor.

B. Chondroblastoma.

C. Osteosarcoma.

D. Chondromyxoid fibroma.

Explanation : Osteosarcoma & chondromyxoid fibroma : Both are metaphyseal.

Young patient → Growth plate must be open →

Chondroblastoma.

Q. A 45 year old male presented with an expansile lesion in the center of femoral metaphysis. On X ray The lesion shows endosteal scalloping and punctate calcifications. most likely diagnosis is?

A. Osteosarcoma.

B. Chondrosarcoma.

C. Simple bone cyst. } No calcification

D. Fibrous dysplasia. }

Explanation : Chondrosarcoma – Punctate calcifications.
 Endosteal scalping.
 Popcorn calcifications.
 Ring/arc sign.

Q. Commonest malignant tumor of the skeletal system is?

- A. Multiple myeloma.
- B. Metastasis.
- C. Osteosarcoma.
- D. Chondrosarcoma.

Q. Metastasis is usually not found in?

- A. Femur.
- B. Humerus.
- C. Fibula.
- D. Spine.

Explanation : Metastasis doesn't occur in small bone.
 Mostly occurs in spine (lumbar > thoracic).

Q. All the following statements about synovial cell sarcoma, are true, except :

- A. Originate from synovial lining.
- B. Occur more often at extra articular sites
- C. Usually seen in patients less than 50 years of age.
- D. Knee and foot are common sites involved.

Questions (continue)

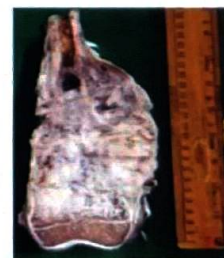00:36:56

60c6b3eeaa8ded0e4e7e5ea7

Q. A 10 year old male child presents with pain around the left knee joint. On X ray, there is a lesion at the distal femur.

Following is the clinical image, what is the most probable diagnosis ?

- A. Giant cell tumor.
- B. Osteosarcoma.
- C. Osteoblastoma. (not so aggressive)
- D. Chondrosarcoma. (occurs in older population)



Q. Which statement is incorrect about the pathology shown in the image ?

- A. Tumor has distinct margins.
- B. Is eccentric.
- C. Arises from epiphysis.
- D. Chemotherapy is treatment of choice.

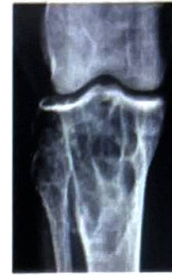
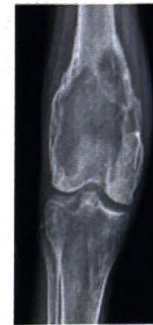
Image indicates mature patient with multiloculate expansile lesion in metaphysis moving into the epiphysis, GCT.

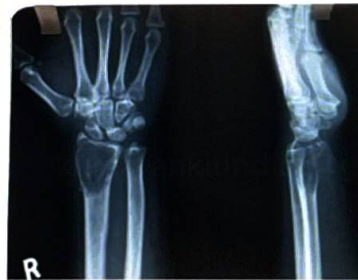Q. The treatment for the condition given below is :

- A. Extended curettage with allograft.
- B. Bone biopsy.
- C. Curettage.
- D. Extended curettage with autograft.



Q. A 30 year old male patient presented with complaints of a gradually progressive swelling around his wrist joint for 3 months. Given below is the image of swelling & Xray film. what is the most likely diagnosis ?

- A. Ewing's sarcoma.
- B. Osteosarcoma.
- C. Osteoclastoma.
- D. Osteochondroma.



Q. match the following with the best mode of management.
management :

- A. Wide Excision.
- B. Curettage.
- C. Radio frequency ablation.
- D. Intra lesional Steroid.

Pathology :

- 1. Osteosarcoma.
- 2. Simple bone cyst.
- 3. Giant cell tumor.
- 4. Osteoid Osteoma.

- A. A-1, B-2, C-4, D-3.
- B. A-1, B-4, C-2, D-3.
- C. A-1, B-3, C-2, D-4.
- D. A-1, B-2, C-3, D-4.

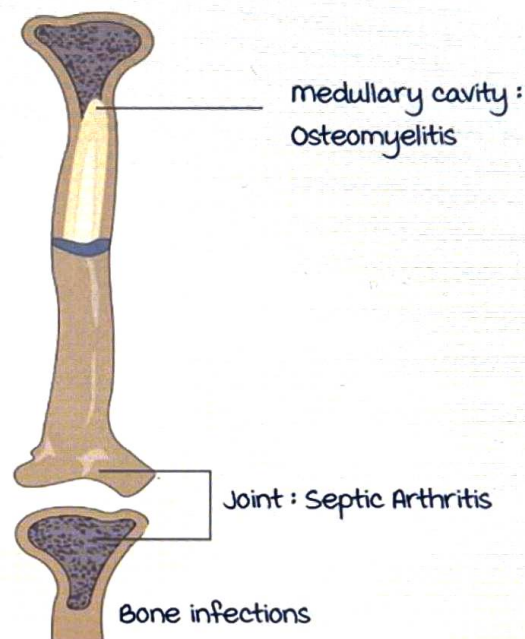
Active space

ORTHOPAEDIC INFECTIONS - PYOGENIC

Broad ideas of infection :

Osteomyelitis : Infection of the bone and medullary cavity.
Usually occurs in the **metaphysis** of long bone.

Septic arthritis : Infection of the joints.



Pyogenic (bacterial) vs TB :

Pyogenic infections causes severe local reaction/periosteal reaction. X-ray findings more **evident** pyogenic > TB.

Limited local reaction in TB.

TB of the short bones (hand & feet), local reaction is severe.

Osteomyelitis

00:03:22

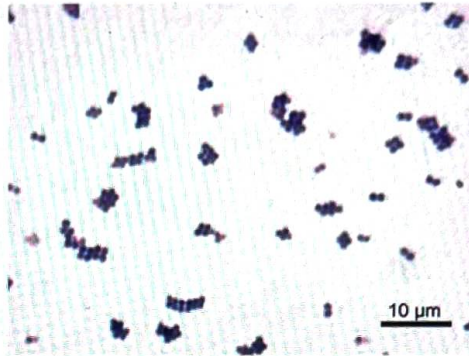
Occurs in young children/elderly population : Due to relatively low immunity.

Route of infection :

- **m/c Hematogenous** (pre existing infection).
- Direct contact/post-surgical (contaminated sources).
- Open fracture.
- Septic arthritis (from a joint to a bone).

Staphylococcus aureus is the m/c cause of osteomyelitis :

- Overall.
- Acute infection.
- Chronic infection.
- Developed countries.
- Developing countries.
- HIV/AIDS.
- Immunocompromised.
- Open fracture.
- Post surgical/iatrogenic.



Special cases of osteomyelitis

- Sickle cell disease patient : *Salmonella*.
It is usually diaphyseal but if same patient has osteomyelitis in metaphysis, it is by *Staph aureus*.
- IV drug abusers : *Pseudomonas*.
- Following animal bite : *Pasteurella*.
- Following human bite : *Eikenella*.
- Prolonged parenteral therapy : Fungal organisms.

m/c site of osteomyelitis : *metaphysis of long bone*.

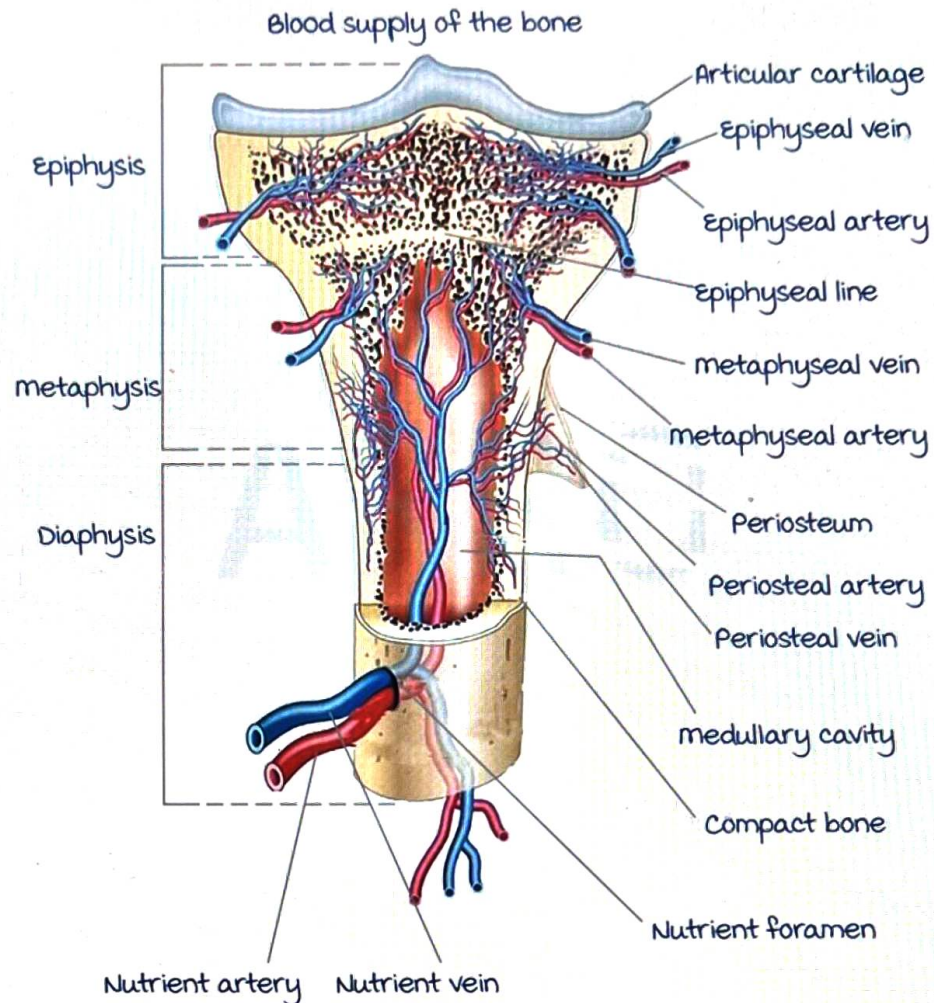
Overall most commonly affected bone :

Infants/children : Femur > tibia (distal femur > proximal).

Adults : *vertebrae*.

metaphysis is most common location of osteomyelitis because :

1. most vascular region of bone/highly nutritious.
2. Hair pin loop arrangement of blood vessels : Sluggish blood flow (venous stasis). Allows movement of organisms.
3. Few monocytes and macrophages.



Pathophysiology of osteomyelitis

00:11:16

Acute osteomyelitis → Chronic osteomyelitis.

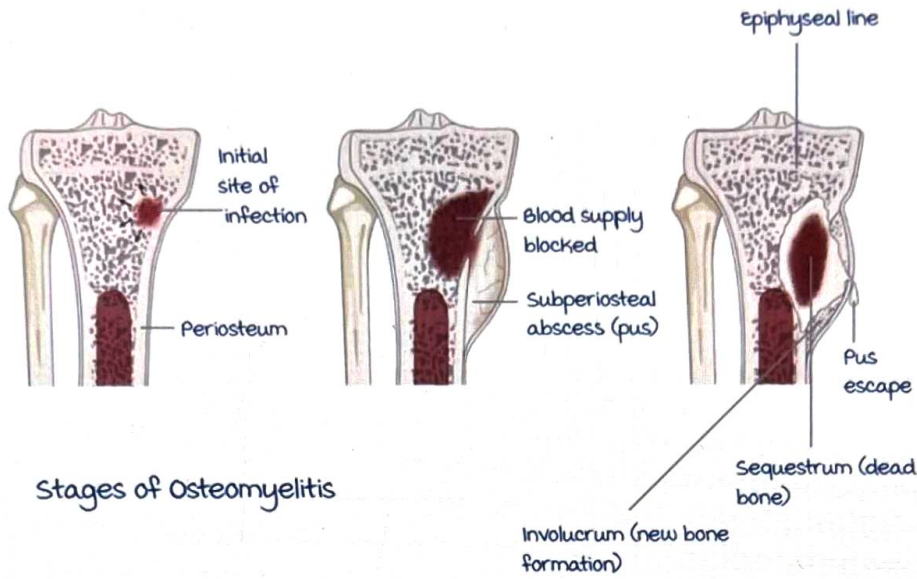
Chronic osteomyelitis → Acute exacerbation.

Spectrum of the disease is such.

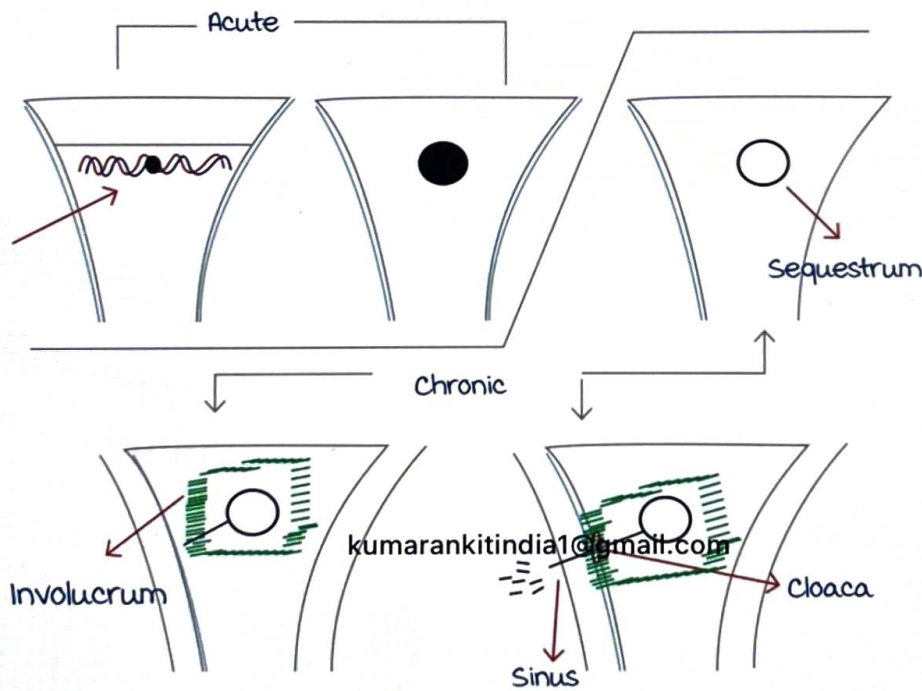
Bacteria enters metaphysis → hematogenous route → abscess formation (less monocytes & more vascularity) → dead bone → nutrient depleted → sequestrum → helps organism grow & more pus produced.

Periosteum synthesizes new bone → contain infection spread → periosteal reaction → osteoprogenitor cells triggered → new bone formed called involucrum.

more abscess/pus → perforates involucrum → through the bone, enters soft tissue → cloaca → skin also perforated → sinus.

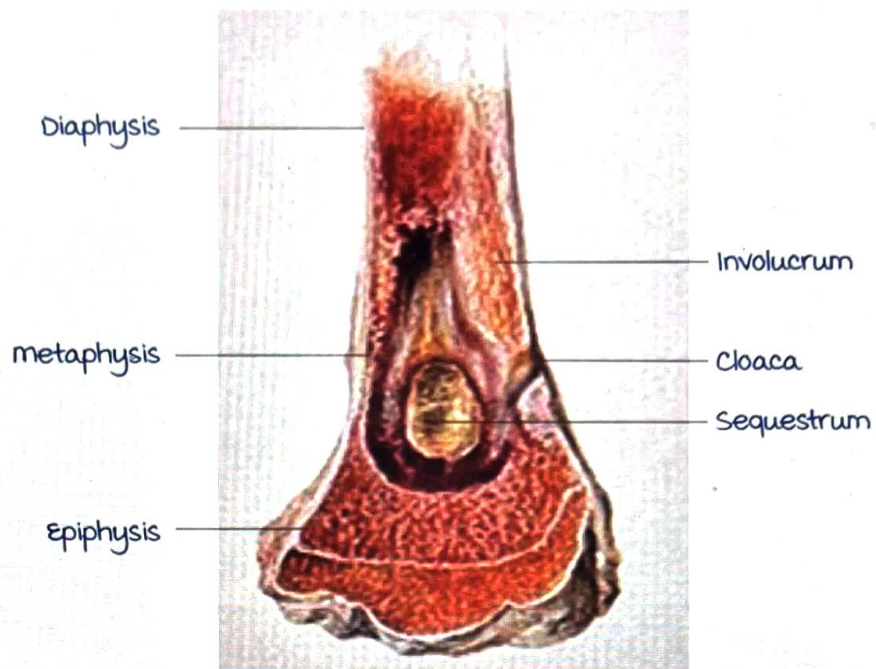


Acute osteomyelitis : Before the formation of sequestrum.
 Chronic osteomyelitis : After the formation of sequestrum.



Schematic representation of the stages of the disease

Active space



60c6b3eaaa8ded0e4e7e5ea7

- < 24 hours : Systemic manifestations (fever, pain). minimal pus formation. Antibiotics will help.
- > 24 hours : Abscess formation. Incise & drain the pus.
- Periosteal reaction starts around 7 to 10 days.
- Sequestrum starts to form in the contents of the abscess.
- Abscess perforates the involucrum (new bone) as cloaca.
- Pus drains through the involucrum and discharges out of the skin through a sinus.

Clinical features :

Young Child with high grade fever, swelling & pain.

Pseudoparalysis due to pain (child does not want to move the limb). Also seen in septic arthritis, scurvy, sub periosteal hemorrhage.

Pathological hallmarks :

- Acute osteomyelitis : (< 2 weeks) presence of **abscess**.
- Chronic osteomyelitis : (> 4 weeks) formation of **sequestrum**.

Clinical hallmarks :

- Acute osteomyelitis : **Fever & Pain**.
- Chronic osteomyelitis : **Sinus**.

management :

Collect blood sample to check for :

WBC : Increased neutrophils.

ESR : Increased.

CRP : Increased.

Blood culture : Only 50% positive for (MC) Staph aureus.

Serum procalcitonin is a sensitive and specific marker in the diagnosis of septic arthritis & acute osteomyelitis.

- Antibiotics : Broad spectrum as empirical therapy.
Change as per culture report.
- Analgesics : For pain.
- Antipyretics : For fever.
- Rest & Splint : To prevent movement as it causes pain.
- Ice and limb elevation for swelling.

Radiology :

MRI	Bone scan	X-ray
<p>Picks up earliest changes in < 24 hrs</p> <ul style="list-style-type: none"> • marrow edema 	<ul style="list-style-type: none"> • Technitium 99 • Gallium 67 • Indium III WBC labelled (Best) 	<ul style="list-style-type: none"> • Shows changes > 24 hours • Within 48 hrs, Soft tissue lucency/shadow around bone (Earliest X ray change). • Earliest bony change on X-ray : Periosteal reaction by (7-10 days)

Gold standard investigation : Biopsy (tissue from the site).

Treatment :

kumarankitindia1@gmail.com

< 24 hours : Antibiotics ± Drain the abscess.

> 24 hours : Antibiotics + Drain the abscess (surgical drilling).

Duration :

- 2 weeks of Parenteral antibiotics followed by 4 weeks of oral antibiotics (assess response with CRP).

Provisionally osteomyelitis of < 2 weeks is considered acute and > 4 weeks is considered chronic, between 2 to 4 weeks is sub-acute osteomyelitis.

Complications :

- Chronic Osteomyelitis (m/c).
- Septic Arthritis (growth plate/physis prevents the spread of infection).

Seen in before the growth plate formation (< 2 years) & after growth plate fusion (in mature adults), between 2-14 years less chance of infection spreading from the metaphysis.

- Septicemia.
- Growth disturbance.

Chronic osteomyelitis

00:33:36

usually, > 4 weeks following the infection (arbitrary).

Clinical Hallmark : Sinus.

Pathological Hallmark :

Sequestrum :

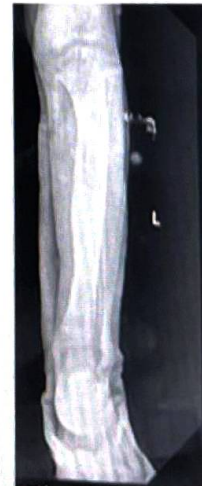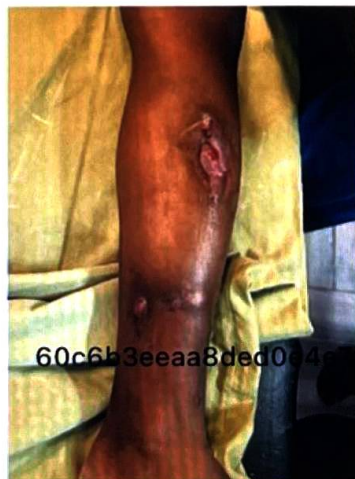Dead.

Dense.

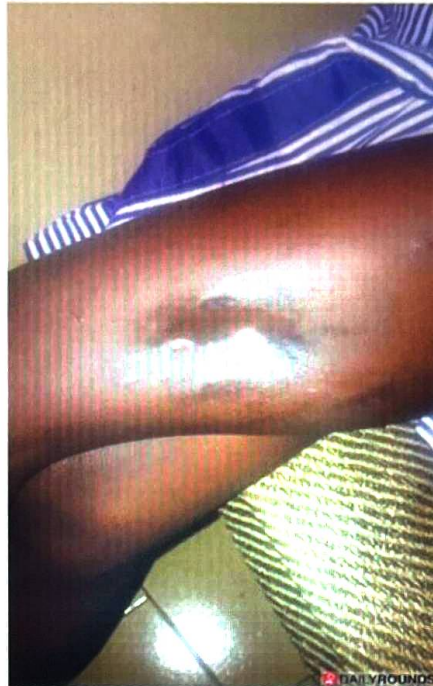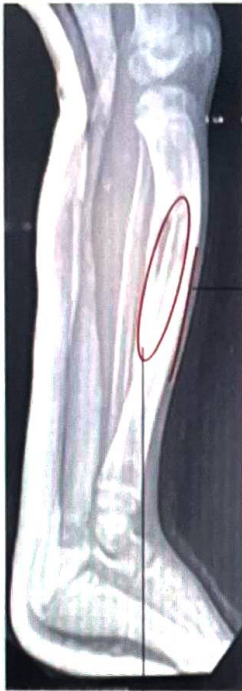Devascularized.

Surrounded by granulation tissue and involucrum.

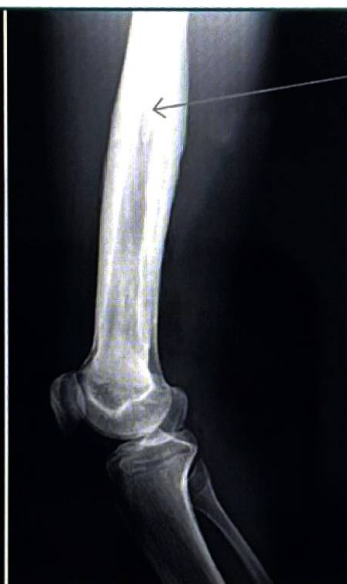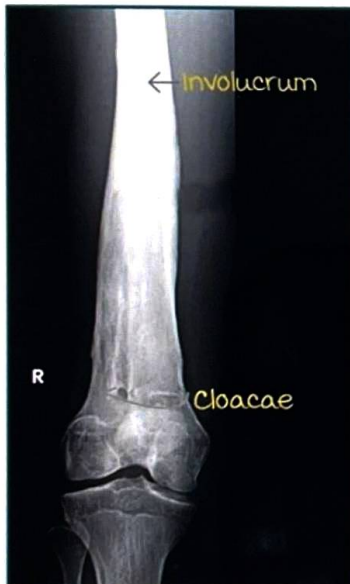microscopic destruction of the haversian system.



Discharging sinus in tibia



Sequestrum Involucrum



Involucrum

Sequestrum

R

Cloacae

kumarankitindia1@gmail.com

Chronic Osteomyelitis

Types of sequestrum :

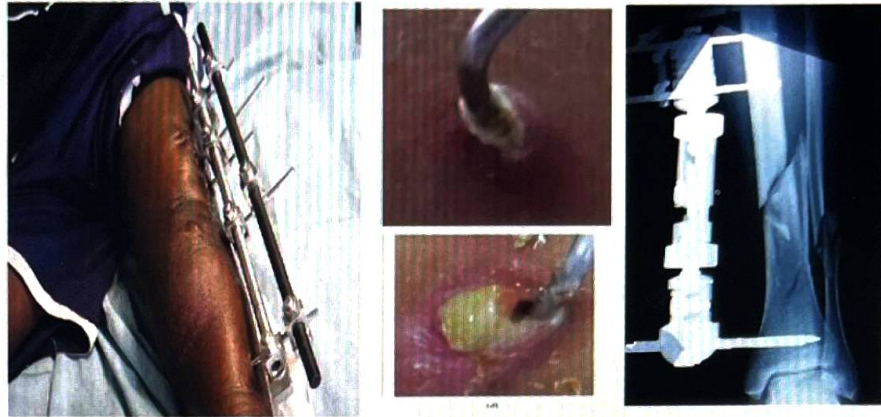Sequestrum	Associated condition
Coralliform	Perthe's
Annular/ring	Amputation stump/pin tract sites
Tubular/diaphyseal	Acute pyogenic Om
Feathery / flake / coarse sandy	TB
Fine sandy	Viral Om
Bombay	HAS/Pollution
Coke	Cancellous Bone
Buttonhole	Post Radiation

Active space

Black	Fungal, Actinomycosis
Ivory	Syphilis

Ring sequestrum :

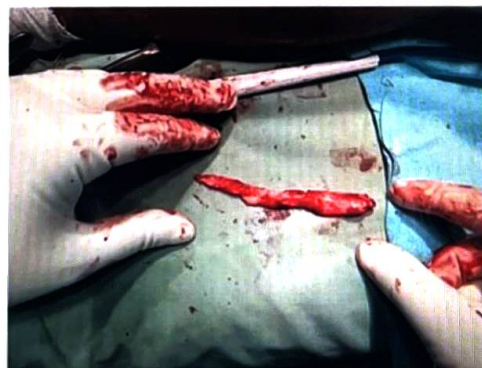
Sequestrum seen around the pin tract sites.



Management of chronic osteomyelitis

00:38:31

- Blood Sample
- Broad spectrum antibiotics, analgesics.
- Sinogram : A radio opaque dye injected through sinus → to know the tract & plan treatment.
- Gold Standard Investigation : Biopsy
60c6b3eeaa8ded0e4e7e5ea7

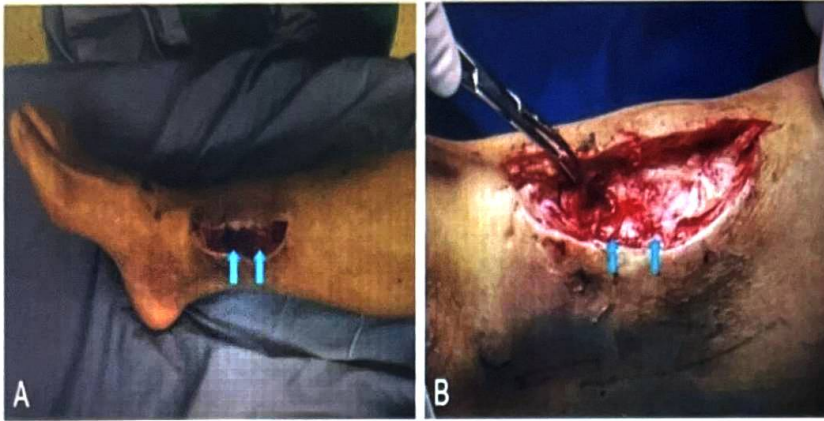


Sequestrum

Treatment : Always surgical.

Under antibiotic Cover

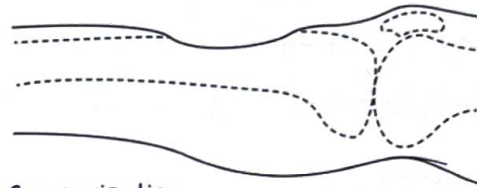
- Sinus tract excision.
- **Sequestrectomy.**
- Debridement : **Saucerization** (wide mouth cavity).
- Curettage : Till fresh bleed (**paprika sign**) - fresh bone.



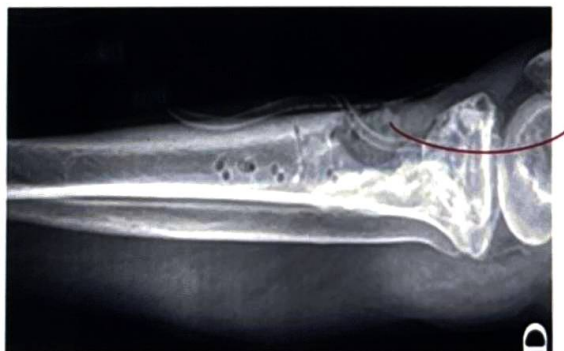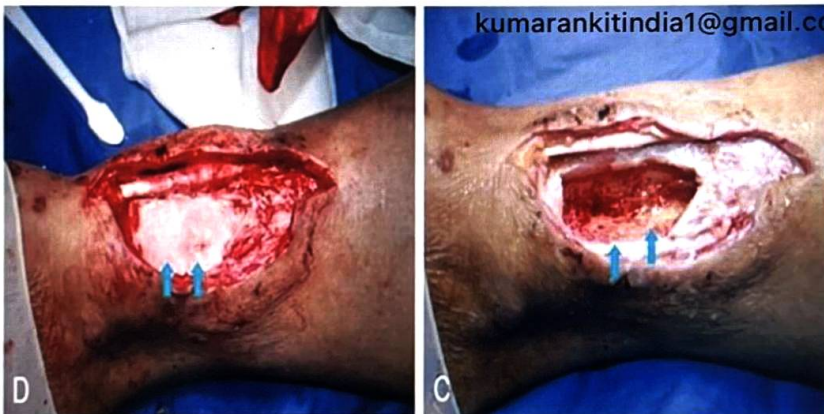Paprika sign

Dead space is closed with :

- Bone graft
- Bone Cement



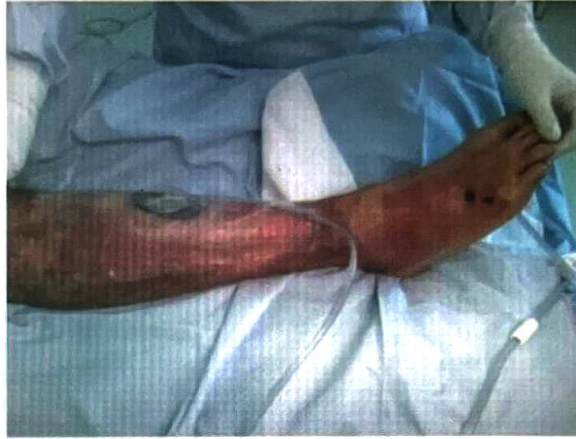Saucerization



Skin is covered with

- Skin Flap.
- muscle Flap.
- vaccum assisted covering/negative pressure wound therapy (-75 to -120mm hg) : Better healing by promoting more granulation tissue formation.

Contraindicated if there is eschar tissue or tumor.



Complications :

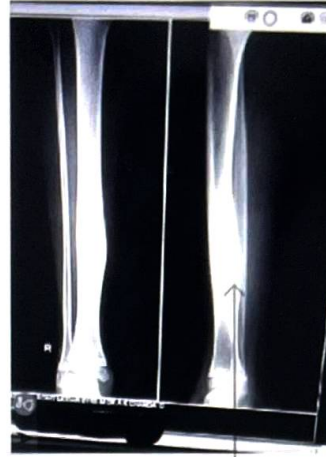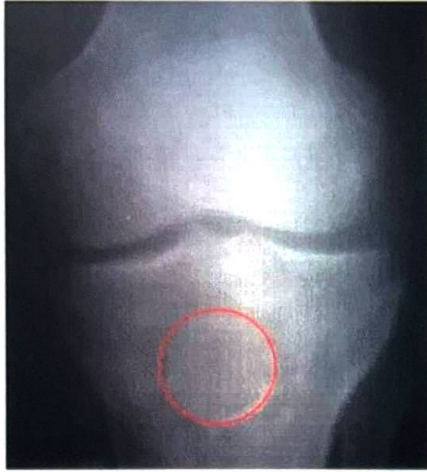- Pathological fracture → bone destruction by abscess → weakened bone.
- Acute exacerbation of disease.
- Neoplastic change of the sinus tract → Squamous cell carcinoma
- Amyloidosis (because of chronicity).

Variants of osteomyelitis :

- No sinus.
- No sequestrum.
- Patients have good immunity and organism has low virulence.

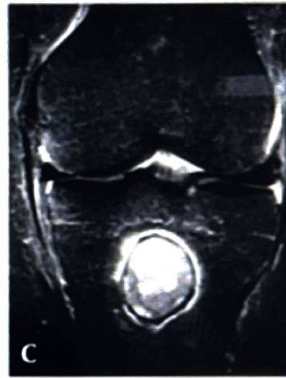
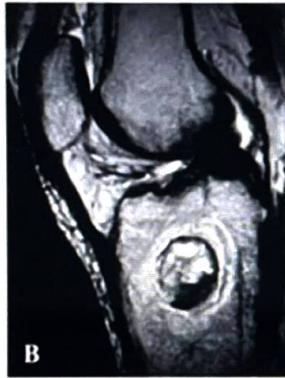
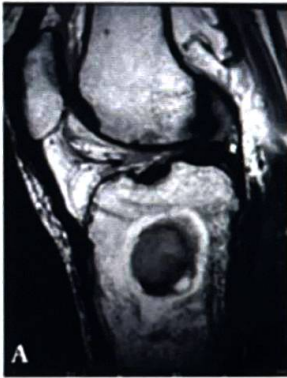
The organism cannot grow in the body, will be destroyed leaving a thick layer of bone and pus.

Brodie's abscess	Garre's sclerosing osteomyelitis
Subacute (2-4 weeks)	Chronic osteomyelitis >4weeks
most common site : Tibia (Proximal end)	most common site : mandible > Tibia
Pus present	No pus
Acute dull aching pain	Bony swelling
No periosteal reaction (central lucency), thick sclerotic rim	Excessive periosteal reaction (sclerosing)
Treatment : Antibiotics ± Debridement	Treatment : Antibiotics



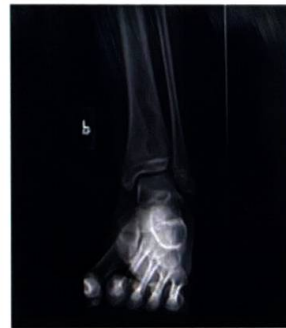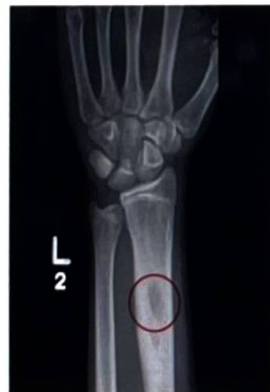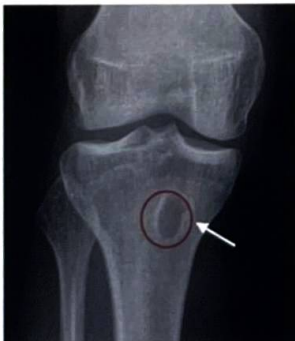Thick dense bone

MRI findings of Brodie's abscess : Pneumbra sign.
Central lucency surrounded by thick sclerotic rim.



Brodie's abscess : Patients present with slight-moderate pain,
low grade fever, slightly elevated ESR, CRP.

X ray showing Brodie's abscess in metaphysis :



Septic arthritis

00:49:06

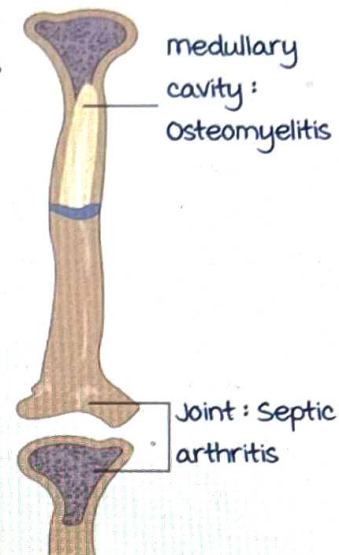
kumarankitindia1@gmail.com

- Surgical emergency
- Bacterial arthritis.

Active space

- Seen in children/elderly
- MC organism : Staph aureus.
IV drug abuser : Pseudomonas.
Sexually active : Gonococcus.
- MC joint : Knee (Infants : Hip).
- Route : Hematogenous.

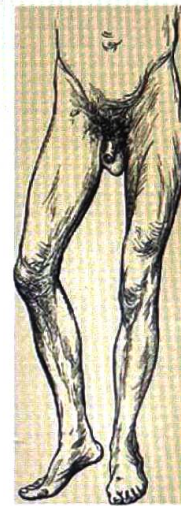Septic arthritis



Clinical features :

Young Child with

- High grade fever.
- Inflammatory signs (swelling, pain and redness).
- No joint movement : Due to pain of stretch of capsule due to effusion.
- Capsule is sensitive to pain
- Cartilage is avascular, aneural, alymphatic structure with no sensation of pain.
- Positions leg such that volume in the capsule increases, stretch decreases.
- Patellar tap sign positive (when pressed the patella goes down due to effusion).



Position of ease

- Joint in position of ease : To minimize pain.
Hip : Flexion, abduction & external rotation.
Knee : 5-30 degrees of flexion.

60c6b3eaa8ded0e4e7e5ea7

Management of septic arthritis

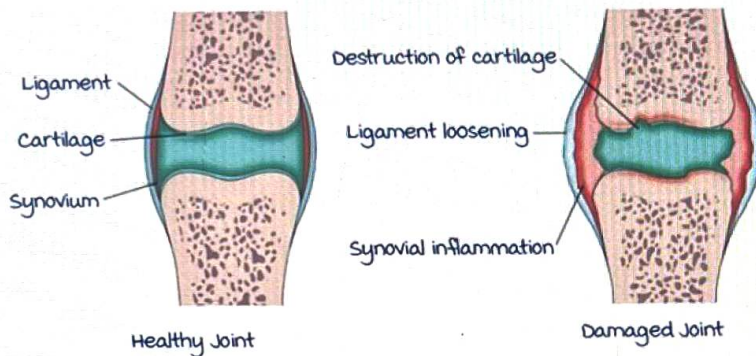
00:55:28

- Blood sample : CBP, ESR, CRP, TLC - Suggestive of infection
Culture the collected sample.
- X ray :
Early : Shows no changes ± widening of joint space due to collection.
Late : Destruction of joint.
- MRI : Synovial thickening

- USG guided aspiration → Arthrocentesis (removing joint contents). Both diagnostic & therapeutic.

Emergency treatment : To get the contents out of the joint
Best is **arthrotomy** : Irrigation and debridement of joint under antibiotic cover.

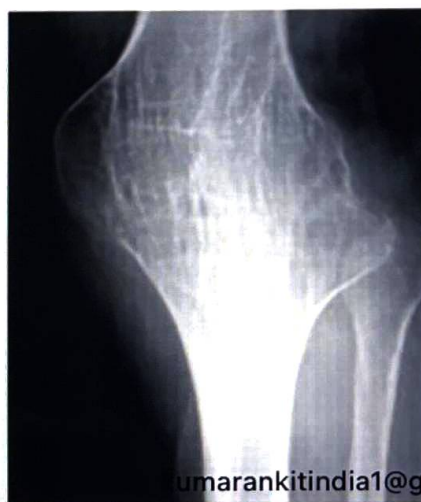Normal Vs Damaged Joint



Pathogenesis of destruction :

Organism releases **proteolytic enzymes** like collagenases, metalloproteinases, elastases → articular cartilage damage
→ fusion of two raw bony ends → Bony ankylosis → end squeale of neglected septic arthritis.

Pyogenic organism → septic arthritis → bony ankylosis.

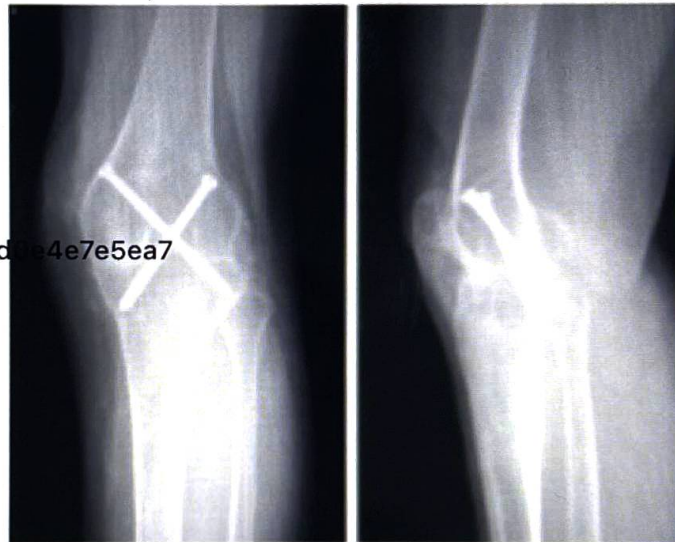

Bony ankylosis

umarankitindia1@gmail.com

Types of ankylosis :

Fibrous ankylosis	Bony ankylosis
Fusion of raw bony ends with fibrous tissue	Fusion of raw bony end with bone
TB Arthritis (less reaction)	Pyogenic septic arthritis, TB-Spine (spondylitis).
Rheumatoid arthritis + +	Ankylosing spondylitis, Rheumatoid arthritis
movement present	No movement
Pain present	No Pain
unstable joint	Stable joint



Arthrodesis : Surgical fusion of joints.

Triple arthrodesis in neglected CTEV to ensure a stable foot.

Tom Smiths arthritis

1:02:51

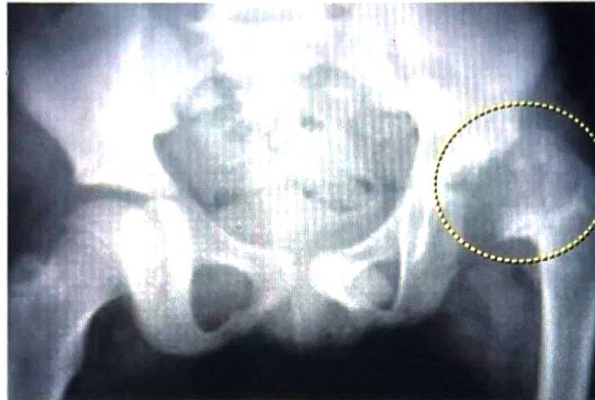
- Septic arthritis of hip in infancy (< 1yr)
- Since the capital femoral epiphysis is cartilaginous, disease process destroys head leading to **chondrolysis**.
- Destruction of hip :

Hypermobility of hip joint (destroyed head).
Limb shortening.

Telescoping test positive (as head of femur & acetabulum are not connected).

It is a **surgical emergency** to preserve hip function.

Septic arthritis : Destruction of left femoral head



Transient synovitis

01:05:49

- Self-limiting inflammation of synovium.
- Pre existing viral infection → Antigen and antibody reaction → synovitis → overproduction of synovial fluid → capsular stretching → pain.
- **most common** cause of limp in child.
- Followed by Septic arthritis & Perthe's disease.

Age : 6-12 yrs (septic arthritis < 5 yrs).

Clinical Features : Pain & limp ± mild fever, Position of ease.

Best investigation : Aspiration.

Treatment :

- Observation (follow up with ESR & CRP)
- Transient synovitis is also known observation hip.

Kocher's criteria
Non-weight bearing
Temp > 38.5°C (101.3 F)
ESR > 40 mm/hr
WBC > 12,000 cells/mm ³

Kocher's criteria is used to differentiate between transient synovitis and septic arthritis.

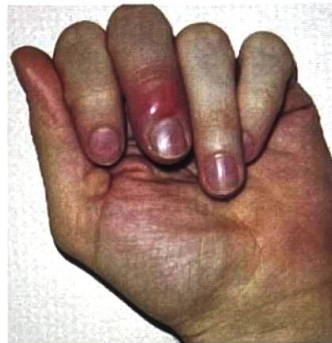Each criteria gets a point, as the point increases chance of disease being septic arthritis increases.

Infections of hand

01:08:36

Paronychia (running around the nail) :

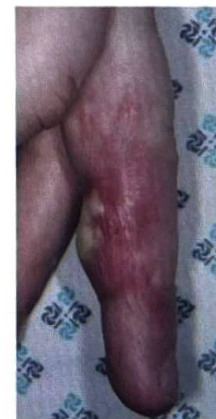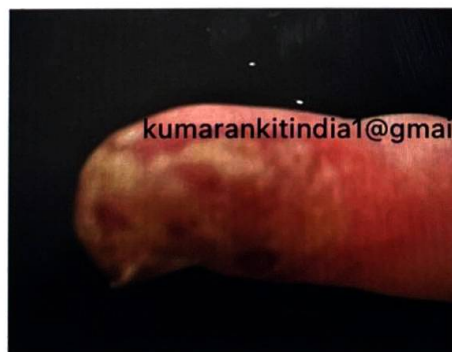- It is the MC infection of hand
- Infection around the nail and sometimes enters the nail bed.
- most common organism is *Staphylococcus aureus*.
- Treatment :
Antibiotics and drainage of abscess ± removal of a part of nail.



Paronychia

Felon/Whitlow :

- Infection of subcutaneous tissue (pulp) of the finger (mostly distal phalanx).
- most commonly affected finger : Thumb > Index.
- most common organism : *Staphylococcus aureus*.
- most common complications of Felon :
Osteomyelitis of phalanx.
Tenosynovitis.



Felon/Whitlow

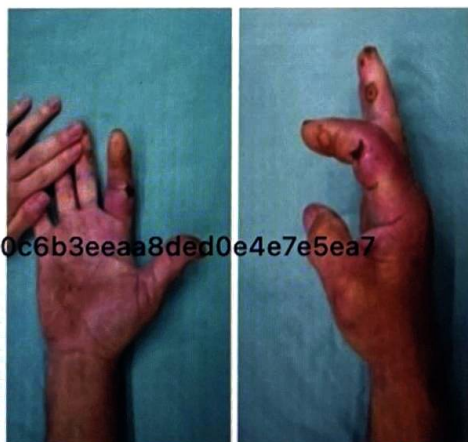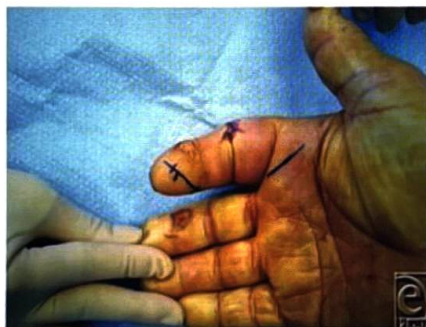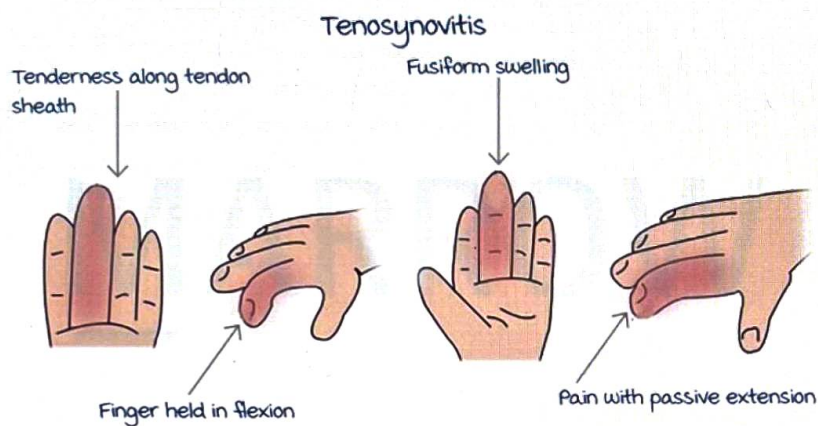
Treatment : Antibiotics + I & D with **vertical** incision to break adhesions/septae to ensure absence of residual infection.

Tenosynovitis :

- Infection of tendon/tendon sheath.
- most common organism : *Staphylococcus aureus*.

Clinical features :

- Pain on tapping the tendon (tenderness on percussion)
Known as **Kanavel sign**.
- Fusiform swelling of finger in flexed attitude.
- Pain on extension.



60c6b3eeaa8ded0e4e7e5ea7

Treatment : Antibiotics, incision & drainage.

ORTHOPAEDIC INFECTIONS - TUBERCULOSIS

Introduction

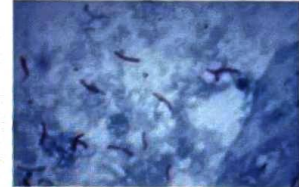00:00:38

Tuberculosis / Caries / Koch's Disease :

Organism → mycobacterium tuberculosis.

most common site :

1. In the body → Pulmonary TB.
2. In musculoskeletal system →
Spine TB spondylitis > Hip
TB arthritis > Knee Arthritis.
3. In spine → Dorso lumbar > Dorsal > Lumbar.
4. In children → Cervical spine.

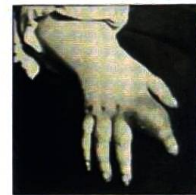

Route → Hematogenous.

Paucibacillary infection by Koch's weak bacillus.

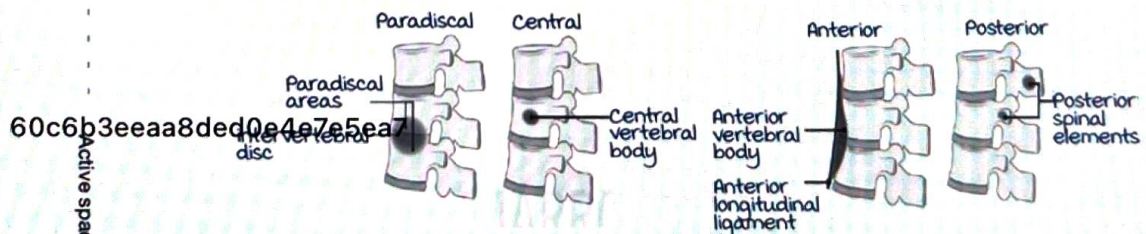
Variants :

1. Caries sicca : TB shoulder.
Dry / non exudative TB.
2. Spina ventosa : TB dactylitis.
"Filling up of air" appearance of
fingers.



TB spine/TB spondylitis :

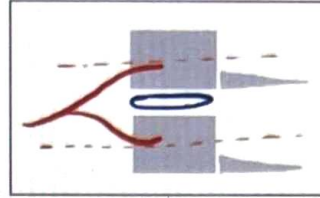
1. Para discal (most common).
2. Central.
3. Anterior/ wet/exudative : Seen in children.
4. Posterior (rarest as facet joints are least involved).



Paradiscal is most common :

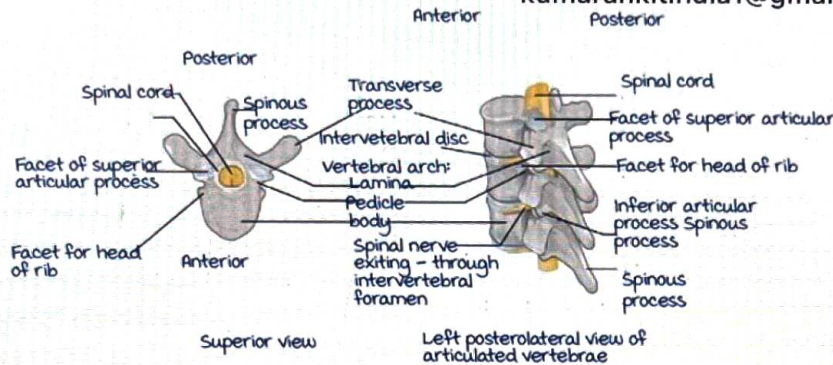
Area of disc & contiguous $\frac{1}{2}$ vertebrae above & below are involved as they are developed from one common somite/sclerotome and have a common blood supply.

Involves bone & cartilage (disc) in front of neural element.



Anatomy of vertebrae

kumarankitindia1@gmail.com



TB limited to the bone → TB spondylitis/ Pott's spine.

But if the infection extends and **compresses the spinal cord from behind**, producing neurological symptoms :

Pott's Paraplegia.

Clinical features :

Constitutional symptoms

1. Low grade fever.
2. Malaise.
3. Night pains.
4. Evening rise of temperature.

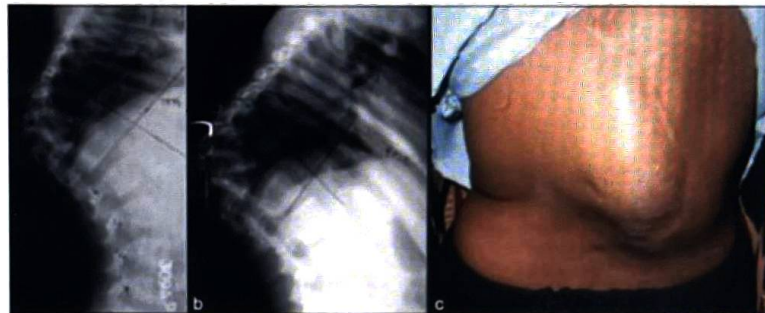
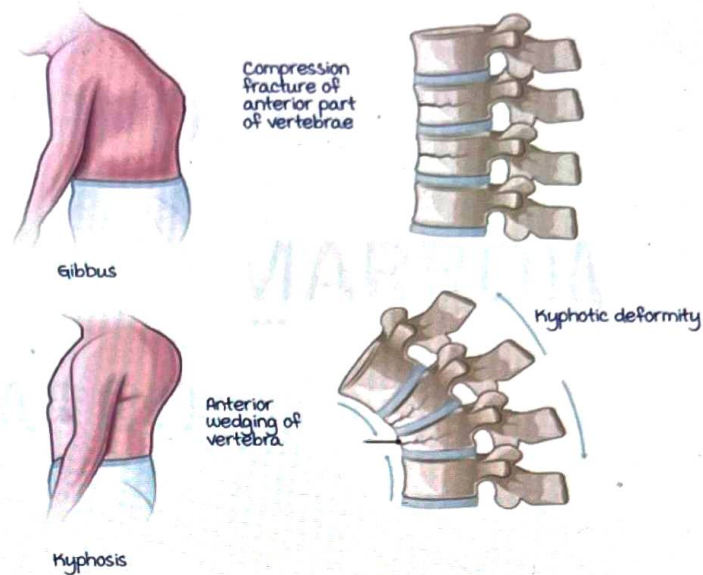
Local findings :

1. Earliest symptom → Pain.
2. Earliest sign → Paraspinal muscle spasm/tenderness.
3. Gait → Cautious gait.
4. Military attitude.
5. Cold abscess.
6. Deformity → vertebral destruction leads to collapse of the vertebrae which causes deformity.
On palpation of the spinous process is felt prominently.

Knuckle : Prominence on one spinous process.

Gibbus : Prominence of 2-3 spinous processes.

Angular Kyphosis : Prominence of >3 spinous processes.



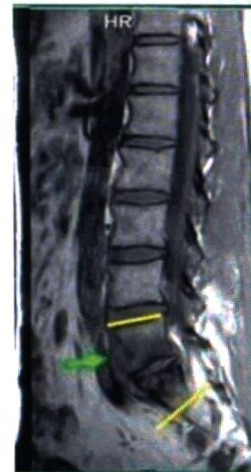X-Ray findings :

Earliest X-ray finding : Triad
 kumarankitindia@gmail.com narrowing due to
 destruction or desiccation
 of disc.

2. Para vertebral abscess.
3. Vertebral Lysis.

Investigation of Choice → MRI spine.

Disc involvement and involvement
 lower half of upper vertebrae and
 upper part of lower vertebrae.



Gold standard investigation → CT guided biopsy.

End sequelae of Pott's spine :

TB everywhere else causes fibrous ankylosis but in spine it's
 bony ankylosis.

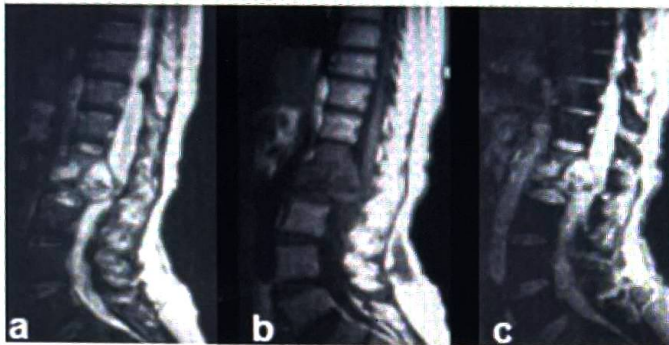
Pott's paraplegia

00:10:50

Due to compression of spinal cord by TB spine disease process, patient will have neurological symptoms.

Causes of cord compression :

1. **Mechanical cause :** Due to granulation tissue.
2. **Cord oedema :** Due to inflammation.
3. **Thrombosis of spinal artery.**



Earliest neurological sign : upper motor neuron lesion type of lesion

1. Ankle clonus / DTR ++
2. Extensor plantar.

Prognostic factors for Pott's spine		
Feature	Better prognosis	Poor prognosis
Degree of cord involvement	Partial (e.g., only sensory or motor)	Complete (grade IV)
Duration of cord involvement	Shorter history	Longer (> 12 months)
Speed of onset	Slow	Rapid
Type	Early onset	Late onset
Age	Younger	Older
General Condition	Good	Poor
Vertebral disease	Active/exudative/wet	Healed
Kyphotic deformity	<60	>60
Cord on MRI	Normal	myelomalacia/syrinx (Cord changes)
Intra-operative	Wet lesion	Dry lesion

Last → Bowel or Bladder involvement → Prognosis is poor.

Important prognosis factors for Pott's spine :

1. Age → Younger have better prognosis.
2. Early onset of the disease has better prognosis (Early onset compression is usually due to the granulation tissue, hence treatable ; Late onset compression is due to the body deformity).
3. Slow onset has better prognosis → Since rapid onset paraplegia is due to spinal artery thrombosis.
4. Short history has better prognosis.

Treatment

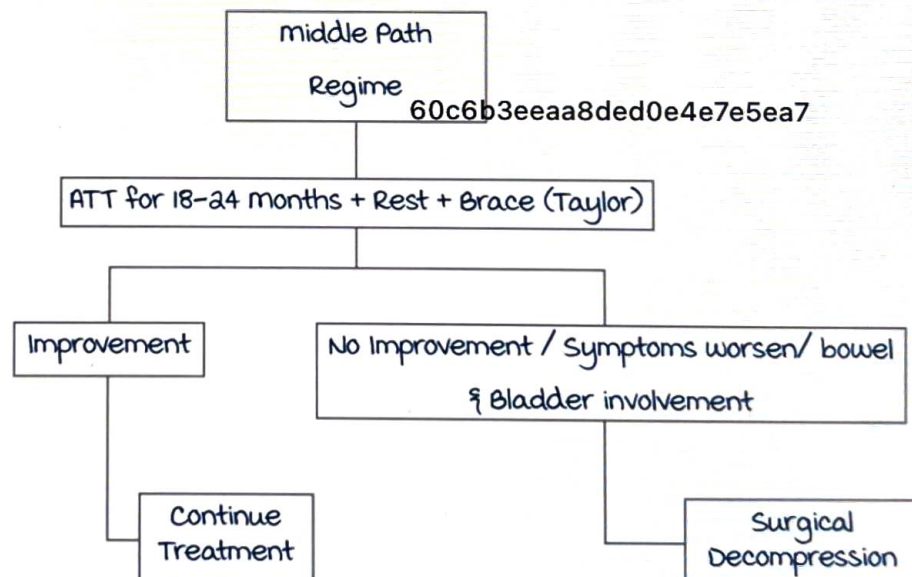
00:14:48

India being a developing country treated TB conservatively with anti-tubercular drugs.

Developed countries treated TB spine aggressively thought surgery.

In 1970s, a **Middle Path Regime** was created.

Treatment

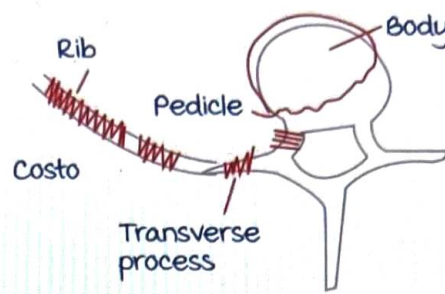


The brace used is called **Taylor's Brace**.

Surgical Decompression :

Approach → **Left Anterolateral decompression + Autologous bone grafting (+/-) stabilization of spine.**

Since TB spine is already weak anteriorly, a posterior approach would also weaken the posterior part of the spine. Hence a posterior approach, which is generally done in other spinal conditions is not done for TB spine.



Antero lateral decompression

Left anterolateral side is preferred as aorta is much easily reparable as compared to IVC.

Parts removed

1. Rib.
2. Transverse process.
3. Pedicle.
4. Vertebral body.
5. Affected Disc.

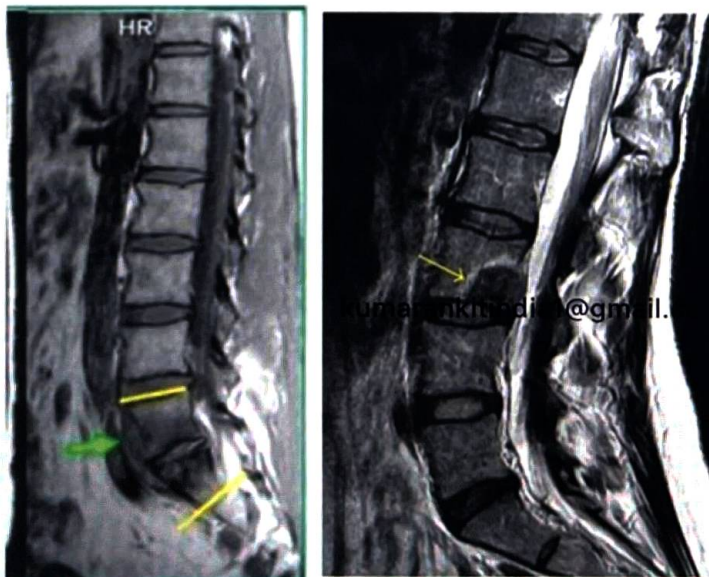Differential diagnosis of central TB is metastasis.

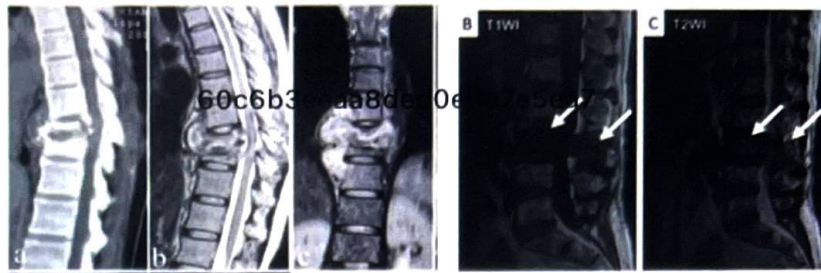
To differentiate do a MRI.

TB → Disc is involved.

mets → Disc is spared.

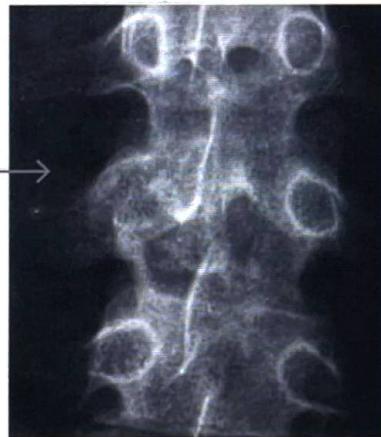Tubercular v/s Tumour



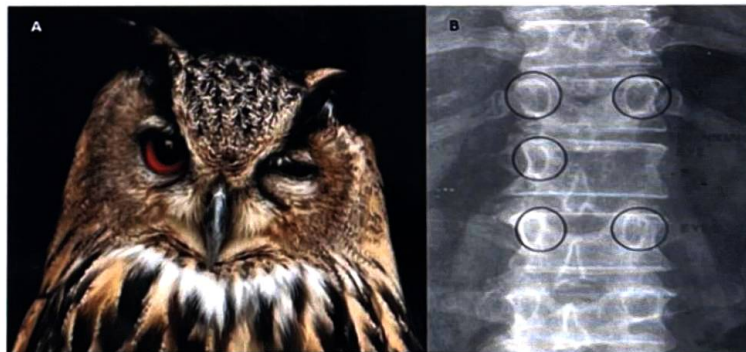


There's a special X-ray sign in mets spine → **winking owl sign**.
Due to destruction of pedicle.

Absent pedicle →



winking owl sign



TB Hip (TB arthritis)

00:21:19

Route → Hematogenous.

First focus of appearance :

1. Acetabulum.
2. **Babcock's triangle** → It is the area in the neck of femur which is deficient in monocytes & macrophages, therefore TB grows easily.

Clinical features :

1. Constitutional symptoms.
2. Painful limb/ antalgic gait.
3. Shortening of limb.
4. Deformities.



Stages

60c6b3eaa8ded0e4e7e5ea7

- I. Synovitis : Stage of apparent lengthening.
- II. Early arthritis : Stage of apparent shortening.
- III. Late arthritis : Stage of true shortening.
- IV. Wandering acetabulum/advanced arthritis : Pestle and mortar deformity.
- V. Fibrous ankylosis.

Stage of TB Hip

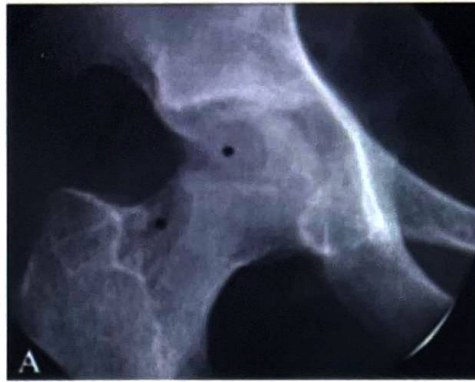
Stage	Name	Pathology
I	Synovitis	Inflamed Synovium leads to excessive synovial fluid secretion. This causes Distension of capsule and pain (patient keeps hip in position of ease)
II	Early Arthritis	Flexion, Adduction, Internal Rotation, apparent shortening < 1 cm
III	Late arthritis	Flexion, Adduction, Internal Rotation, true shortening > 1 cm
IV	Wandering Acetabulum/ advanced arthritis	Destruction of acetabulum, Head of femur moves freely in acetabulum, limb' shortened, hypermobile, telescoping +ve (pestle & mortar deformity)
V	Fibrous ankylosis	Painful hip with limited movement

X-ray findings :

Earliest sign → Juxta-articular osteopenia/osteoporosis due to infection inflammation leading to hyperaemia.

Phemister triad in tuberculous arthropathy :

1. Juxta-articular osteopenia/osteoporosis.
2. Peripheral osseous erosions.
3. Gradual narrowing of joint space.



Treatment :

Early → ATT + Rest + Traction.

Late → ATT + Correct the Deformity.

1. Excision arthroplasty → Girdle stone. Remove the fibrosed head and interpose with a muscle. This muscle will not allow the bones to grow into each other.
2. Arthrodesis → Fusion of the hip.
3. Arthroplasty → Total hip replacement. It is the best treatment but to be performed only after 10-15 years. Since it has high recurrence if done early.

TB Knee (TB arthritis)

00:27:53

Clinical features :

1. Constitutional symptoms.
2. Painful limb / antalgic gait.
3. Shortening.
4. Deformities.

Investigation of choice → MRI (Synovitis).

Gold Standard Investigation → Biopsy.

Early stage :

Synovitis → Slight flexion (5-30)° which is the position of ease for the knee.

Late Stage : Deformity → Triple deformity.

1. Post subluxation.
2. External rotation of tibia.
3. Flexion of knee.

Treatment :

1. ATT and traction.
2. Arthrodesis.
3. Arthroplasty.

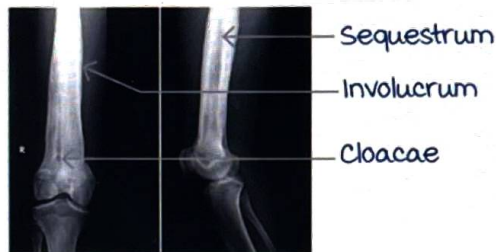Clinical scenarios

00:29:33

1. Felon is ?

- A. Infection of nail fold. B. Infection of ulnar bursa.
 C. Infection of pulp space. D. Infection of DIP joint.

Chronic Osteomyelitis



Answer : Infection of pulp space.

Paronychia is infection nail fold.

Felon is infection of pulp space.

2. True about chronic Osteomyelitis is All except?

- A. Nonhealing sinus is most frequently d/t presence of sequestrum.
- B. Sequestrum is heavier than live bone & trabeculated.
- C. Involucrum is live dense sclerotic periosteal bone formation around sequestrum.
- D. Complications include amyloidosis and sepsis.

Answer : Sequestrum is heavier than live bone & trabeculated.

Explanation :

Sequestrum :

Dead

Dense.

Devascularized

Surrounded by granulation tissue and involucrum.

microscopic destruction of the haversian system.

3. Cloacae is located in

- A. Sequestrum. B. Involucrum.
- C. Normal bone. D. myositis Ossificans.

Answer : Involucrum.

4. Brodie's abscess is a type of?

- A. Acute osteomyelitis. B. Subacute osteomyelitis.
C. Chronic osteomyelitis. D. Septic arthritis.

Answer : Subacute osteomyelitis.

5. Which of the following is not true regarding tubercular osteomyelitis?

- A. It is a Secondary TB. B. Periosteal reaction is seen.
C. Sequestrum is uncommon. D. Inflammation is minimum.

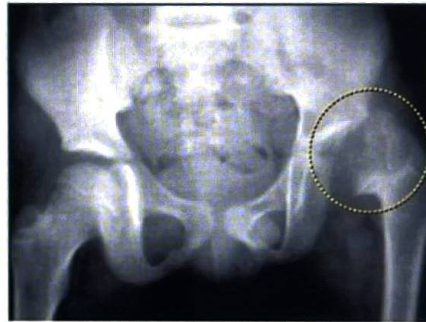
Answer : Periosteal reaction is seen.

6. Chondralysis occurs commonly in which type of pathology?

- A. TB arthritis. B. Syphilitic arthritis.
C. Chondrosarcoma. D. Septic arthritis of infancy.
E. Septic arthritis in adults.

Tom Smith's Arthritis

Septic Arthritis → Destruction of Left Femoral Head



Answer : Septic arthritis of infancy.

Explanation :

Destruction of head of femur which is made up of cartilage
Presents with positive telescoping.

7. Most common joint involved in septic arthritis?
- A. Knee joint. B. Hip.
C. Shoulder. D. Elbow.

Answer : Knee joint.

Children → Hip

Adults → Knee.

8. What is the most common site of TB in the musculoskeletal system?

- A. Spine. B. Knee.
C. Hip. D. Shoulder.

Answer : Spine.

Children → Cervical spine.

Adults → Dorso-lumbar spine > Dorsal spine > Lumbar spine.

9. All are true about spinal tuberculosis except?

- A. Back pain is the earliest symptom.
- B. Dorso-lumbar spine is the commonest site.
- C. Exaggerated lumbar lordosis is a prominent clinical feature.
- D. It is usually Secondary to a pulmonary infection.

Answer : C

It is the loss of lumbar lordosis is the feature.

10. Tuberculosis of spine least likely involves which part of the vertebrae?

- A. Body.
- B. Lamina.
- C. Spinous process.
- D. pedicle.

Answer : Spinous process.

11. All are True about spinal TB and Paraplegia Except?

- A. Paraplegia is commonest in TB of the upper thoracic region.
- B. Paraplegia is caused by spinal cord edema.
- C. most common sequelae is bony ankylosis.
- D. most common sequelae is fibrous ankylosis.

Answer : most common sequelae is fibrous ankylosis.

Bony ankylosis → TB spine.

Fibrous ankylosis → Everywhere else.

12. In TB thoracic spine the earliest sign of cord compression is?

- A. Bladder dysfunction.
- B. motor weakness.
- C. Extensor plantar.
- D. Sensory loss.

Answer: Extensor plantar.

13. Poor prognostic indicator of Pott's Paraplegia is?

- A. Early onset
- B. Active disease.
- C. Healed disease.
- D. Wet lesion.

Answer: Healed disease.

Prognostic Factor of Pott's Spine

Feature	Better prognosis	Poor prognosis
Degree of cord involvement.	Partial (e.g., only sensory or motor).	Complete (grade IV).
Duration of cord involvement.	Shorter history.	Longer (> 12 months)
Speed of onset.	Slow.	Rapid.
Type.	Early onset.	Late onset.
Age.	Younger.	Older.
General Condition.	Good.	Poor.
vertebral disease.	Active/exudative/wet.	Healed.
Kyphotic deformity.	< 60	> 60
Cord on MRI	Normal.	myelomalacia/syrinx (Cord changes).
Intra-operative.	Wet lesion.	Dry lesion.

14. The first radiological sign of TB spine is?

- A. Narrowing of intervertebral space.
- B. Rarefaction of vertebral bodies.
- C. Destruction of laminae.
- D. Fusion of spinous processes.

Answer: Narrowing of intervertebral space.

Types of Ankylosis

Fibrous ankylosis	Bony ankylosis
TB-Arthritis.	Pyogenic Septic Arthritis, TB-Spine (Spondylitis).
Rheumatoid Arthritis + +	Ankylosing spondylitis, Rheumatoid Arthritis.
movement present.	No movement.
Pain present.	No pain.
Unstable joint.	Stable joint.

15. A 50 yr. old known alcoholic presented with pain in dorsal spine. On examination there is tenderness in Dorso lumbar junction. Radiograph shows destruction of the 12th dorsal vertebrae with loss of disc space between D12-L1 vertebrae with a hazy paravertebral shadow. The most probable diagnosis is?

- A. metastatic spine disease.
- B. Pott's spine.
- C. missed trauma.
- D. multiple myeloma.

Answer : Pott's spine.

Loss of disc space = TB.

PAEDIATRIC ORTHOPAEDICS : PART 1

Fractures

00:02:26

Characteristics of pediatric bones :

- more water content :
It is more flexible, so when force is applied it bends rather than break.
It is more amenable & resilient to stress.
- Thick periosteum :
It is protected by the soft, fibrous tissue around it.
Even if the bone breaks, the periosteum will keep the fracture in its place.
- more remodelling potential (metaphyseal bone) :
Even if there is a fracture & the bone breaks, as it heals it will remodel /correct itself as the child grows.

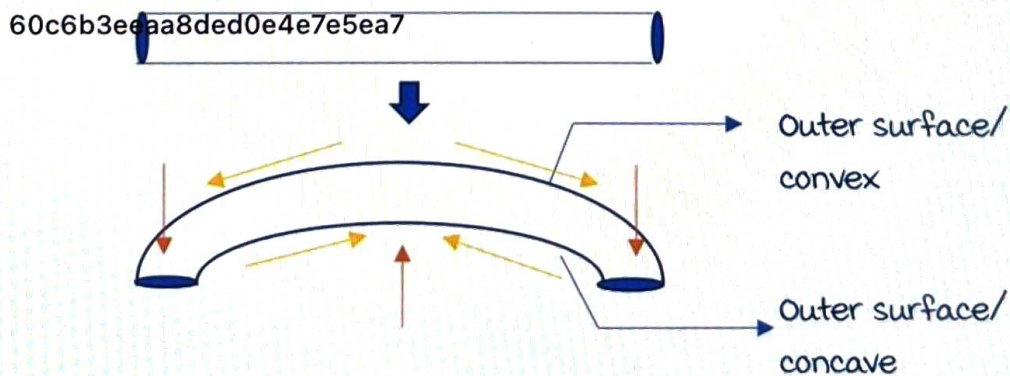
What happens when we apply force on the bone ?

Bone has an outer surface and an inner surface.

Force applied bends the bone.

Outer surface takes a convex shape.

Inner surface takes a concave shape.



The force acting on the outer surface is **distractive force** as it goes away from the center.

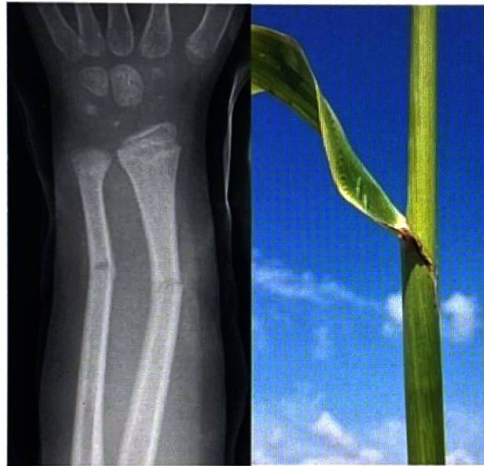Also called as **tension force**.

The force acting on the **concave side** is going towards the center and is called the **compression force**.

Two types of fractures may occur beyond a certain physiological bending limit of the bone :

Green stick fracture :

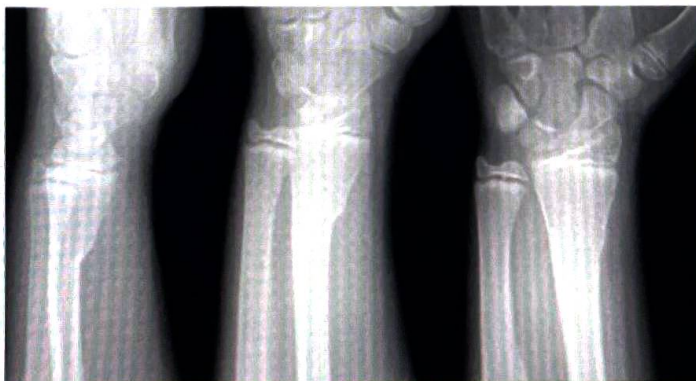- If the force is beyond the capacity of the bone to bear, the **outer surface/tension/distraction side** breaks & the fracture line goes inside, causing a **unicortical fracture**.
- Seen in the forearm of a child, i
- Identified on X ray based on **visible growth plate/physal plate** seen only in children.
- Like in a green stick, the **shear is 75%** in one cortex.



Green stick fracture

Torus fracture :

- Also seen in children.
- **Bulge on the compression side/inner surface/concave side** causing torus fracture.



Torus fracture

most common fracture in children is the green stick fracture which occurs in the forearm (radius > ulna).

most common fracture at birth : Fracture of clavicle.

most common fracture in children following fall on an outstretched hand : Supra condylar fracture of humerus.

most common fracture overall : Clavicle fracture.

Treatment modalities :

Torus fracture :

- Plaster Of Paris/POP application.

Greenstick fracture :

- Only a single cortex is fractured the other cortex has to be iatrogenically broken known as osteoclasis.
- Done to ensure that both sides heal together without deformity.
- Plaster of Paris/POP is applied only after this.

Toddler's fracture

00:13:07

Commonly occur in children following accidents.

Spiral fracture of tibia.

pain on walking/limp.

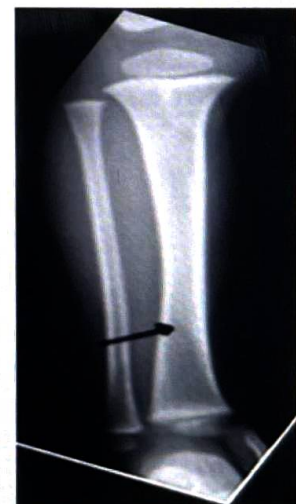Fracture line usually missed on x-ray

- undisplaced due to thick periosteum in children.

Fibula is intact & only tibia is fractured.

Child continues to walk bearing weight on the fibula.

Treatment : POP cast is applied.



kumarankitindia1@gmail.com
Toddler's fracture

Battered baby syndrome

00:14:31

Fractures in children dealt keeping this in mind

Factors that should arouse the suspicion of battered baby syndrome in children are :

- Inconsistency in history.
- Different fractures in different stages of healing.
Do X ray scanogram (full body X ray) to rule out fractures in the whole body.
- Usually, fractures occur in the metaphysis.
- Long bone fracture in non ambulatory children must raise suspicion : Particularly spiral fracture.

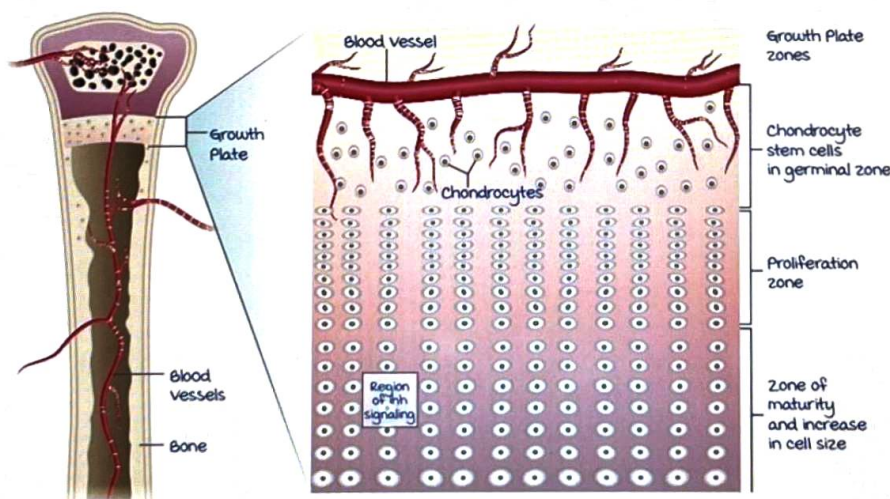
Long bone fractures are common in toddlers and older children once they start walking.

Growth plate injuries

00:16:39

The growth plate or physis is seen between the epiphysis and metaphysis.

magnified view of the growth plate



Layers of physis/growth plate from epiphysis to metaphysis :

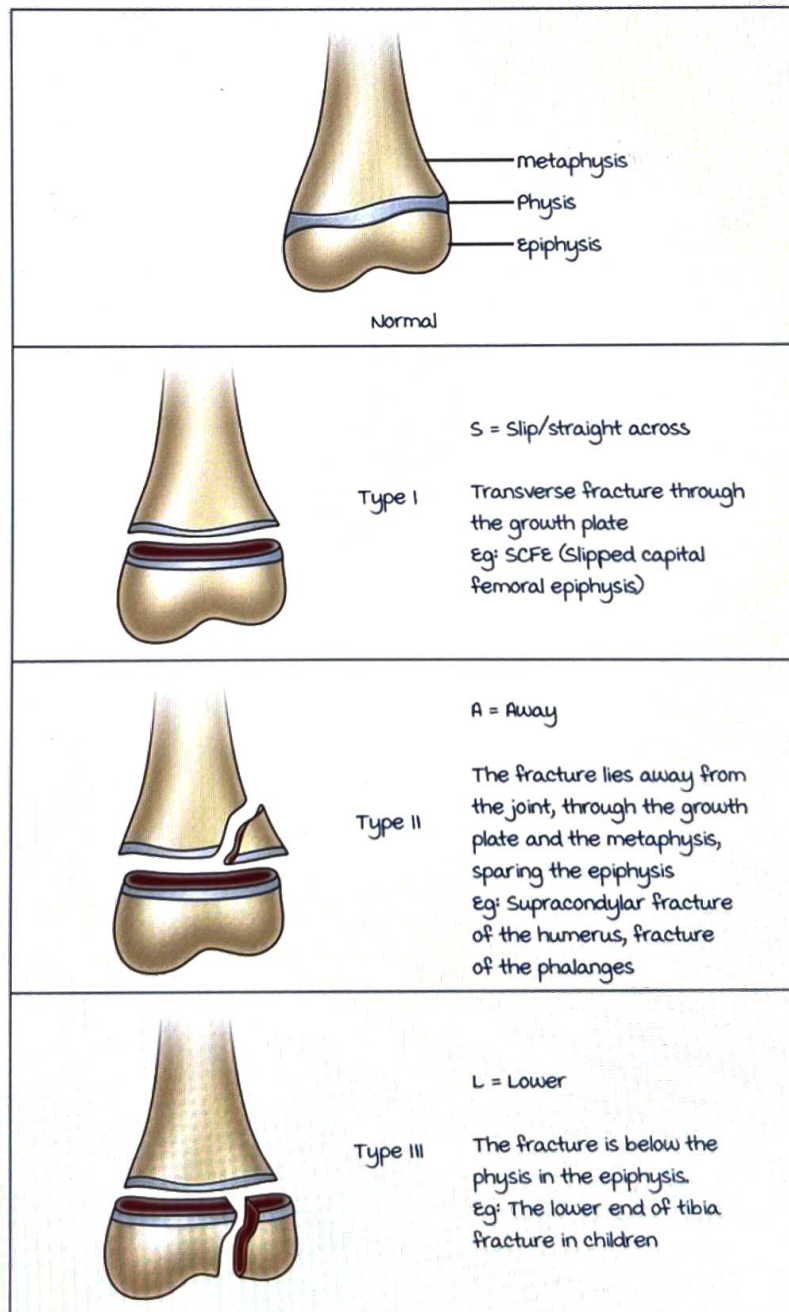
- Germinal :
Layer where cells take rest.
most important layer.
Injury leads to inhibition of growth.
- Proliferative :
Layer where cells start to multiply.

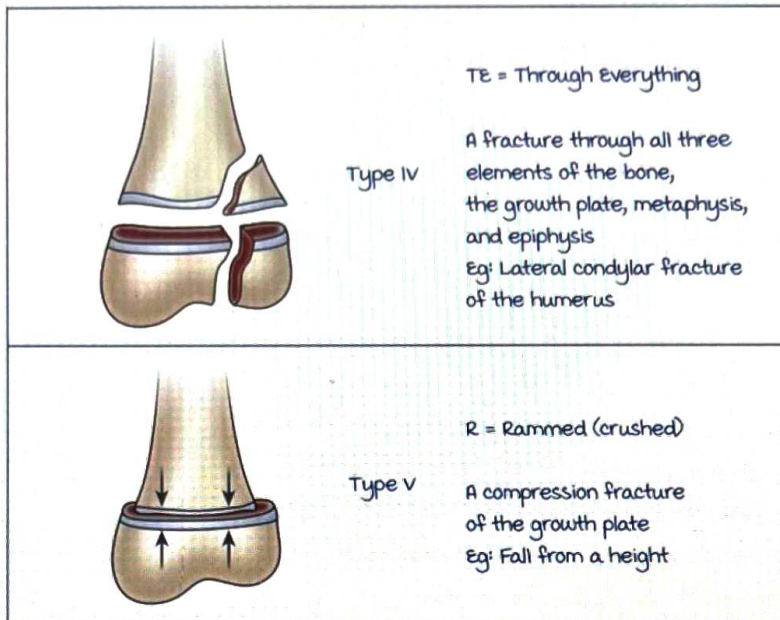
Active space

- Hypertrophic :
Layer where cells grow in size.
Weakest layer.
- Calcification :
Layer where calcium gets in to the cells.
- Ossification :
Layer where calcified cells become a part of the bone.

Growth plate is **not visible on X ray** as it is mostly cartilaginous.

60c6b3eeaa8ded0e4e7e5ea7
Salter Harris classification of physal injuries :

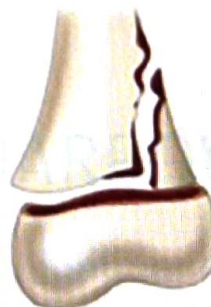



Basic 5 types following which it was modified to add types from 6 to 9.

Mnemonic: **SALTER**.

- Type 1: Fracture line splits the growth plate (split fracture) → good prognosis (best).
- Type 2: Fracture line goes above towards metaphysis → good prognosis. a.k.a Thurston Holland (most common).
- Type 3: Fracture line goes towards epiphysis (low) → injures germinal layer → poor prognosis.
- Type 4: Total/through: Fracture passes through all 3 layers of bone → poor prognosis.
- Type 5: Impaction/rammed/crushing of growth plate (WORST).



Type 2 Salter Harris classification

kumarankitindia1@gmail.com

Classical history of Type 5:

Child presents with a limb length discrepancy/deformity following history of trauma/fall few months/years back. X ray revealed no fracture.

Previous history of trauma led to growth plate injury, however

it was not detected on X ray as it is predominantly cartilaginous.

Child will present with growth arrest.

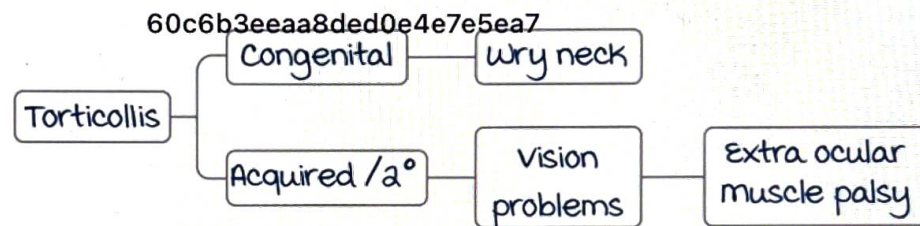
Hence type 5 is retrospective diagnosis.

Examples of Salter Harris Classification :

- Type 1 : Slipped capital femoral epiphysis (SCFE).
- Type 2 : Supracondylar humerus fracture, phalanges of hand
- Type 3 : Lower end of tibia fracture (Tillaux Chaput fracture).
- Type 4 : Lateral condyle of humerus fracture.
- Type 5 : Compression fracture, fall from height.

Congenital anomalies in paediatrics

00:26:46



Acquired can be due to neuromuscular problems.

Congenital muscular torticollis/wry neck :

Also called as Cock Robin appearance.

Tilting of head to one side leads to chin pointing to opposite side.

This is due to sternocleidomastoid (SCM) contracture due to birth trauma.

Birth trauma to SCM → Ischemia of SCM → Fibrosis → Contracture.

Occurs at the junction of 2/3rd and lower 1/3rd.

most commonly on the right side.

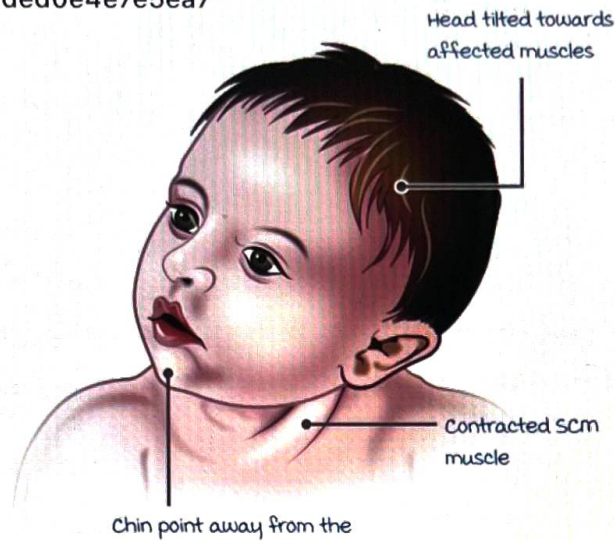
Clavicular head is most commonly affected.

Baby is normal at birth and tilt of neck becomes apparent after a few weeks to months (latest by 3 months).

Parents on examination may feel swelling at the SCM/fibrotic nodule due to fibrosis of the muscle.

Hence, also called SCM tumour.

most cases are self limiting.
may lead to **plagiocephaly** (abnormal development of the head), if the **contracture persists for > 1 year**.
60c6b3eaa8ded0e4e7e5ea7



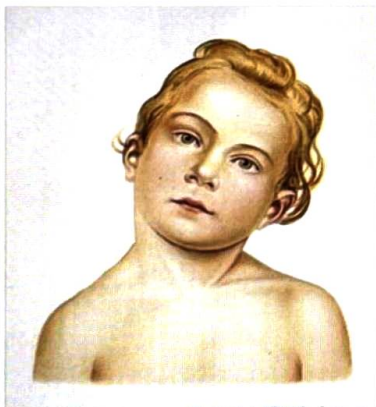Congenital muscular torticollis

Treatment :

usually **conservative**.

Surgical release if persistent beyond 1 year.

Optimum age for surgery is 1 to 4 years.



Cock Robin appearance

Birth trauma is due to :

- **Breech baby**.
- **Shoulder dystocia**.
- **Intra uterine packaging defect :**

Group of conditions that occur due to abnormal pressure on the intrauterine baby :

DDH/Developmental dysplasia of hip.
meta tarsus adductus.

Congenital Dislocation of Knee : most common is hyper extension type.

Sprengel's deformity

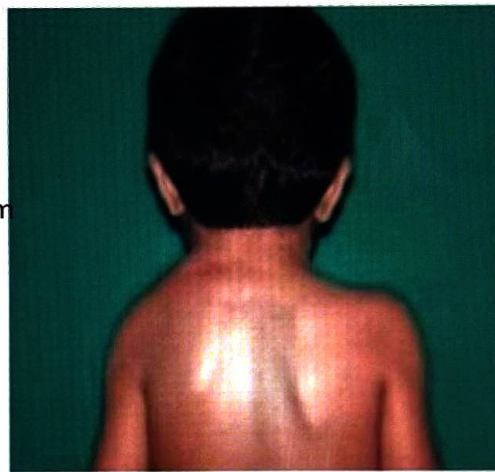00:33:21

Congenital deformity with undescended, hypoplastic scapula. It occurs due to persistent omovertebral bar.

Presents with restriction of shoulder movements.

Treatment :

- Release the omovertebral bar and bring the scapula down. The surgery is also known as Woodward operation.
- Usually done between 3 to 8 years of age.
- If delayed brachial plexus will require more stretching and hence associated with poor prognosis.



Sprengel's deformity

most commonly associated with :

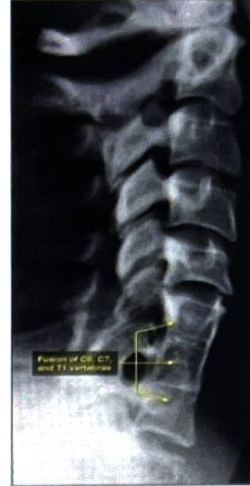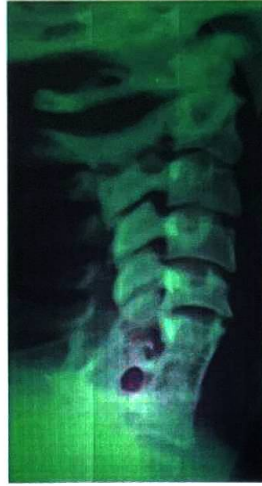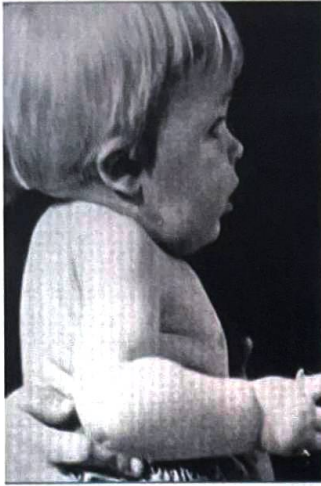- Klippel Feil syndrome/KFS.
- Scoliosis & other congenital anomalies.

Klippel Feil syndrome/KFS :

It is a segmentation defect of the cervical spine. This will cause a triad of symptoms :

- Short webbed neck.
- Low set hair line.
- Restriction of neck movements.

kumarankitindia1@gmail.com



Klippel feil syndrome

Therefore Sprengel shoulder patients will have KFS, but KFS patients need not always have Sprengel shoulder as the most common association of KFS is scoliosis.

Other anomalies associated with KFS :

- Genito Urinary anomalies.
- Ocular defects.
- Hearing defects.
- Cardiac defects.

Advised to avoid contact sports to prevent injury.

Madelung deformity

00:39:33

Defect :

Distal end of the radius growth plate fuses early ^{kumarankitindia1@gmail.com} → there is a defect in growth (but ulna continues to grow normally).

Deformity :

Ulna is more prominent than the radius.

Volar subluxation of hand : Dinner fork deformity in children.

50% cases are bilateral.

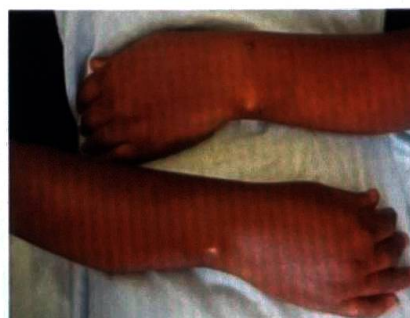Vickers ligament :

- Attaches carpal bones to distal end of radius.
- Pull on the ligament causes injury to the growth plate.

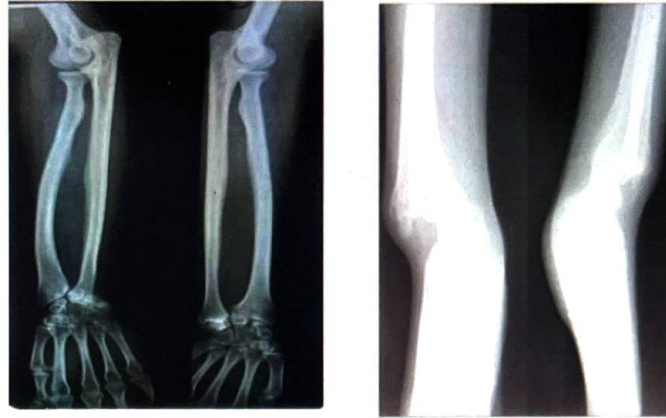Madelung is associated with

Turners syndrome.

Positive ulnar variance.



Active space



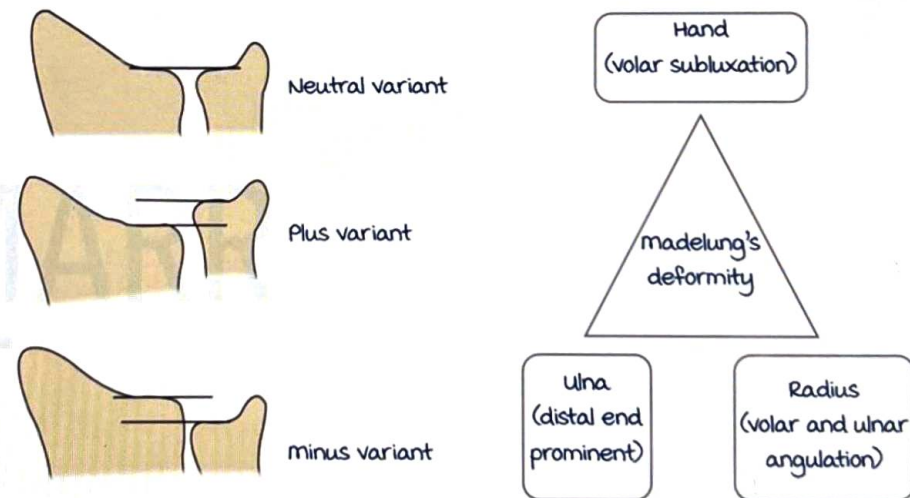
Madelung deformity

Ulnar variance is the differential length between radius and ulna.

Normally radius is slightly longer than ulna as it is articulating with carpal bones, however it is considered to be of the same length : Neutral/normal variant.

Ulna is longer than radius : Positive ulnar variance.

Ulna is shorter than radius : Negative ulnar variance.



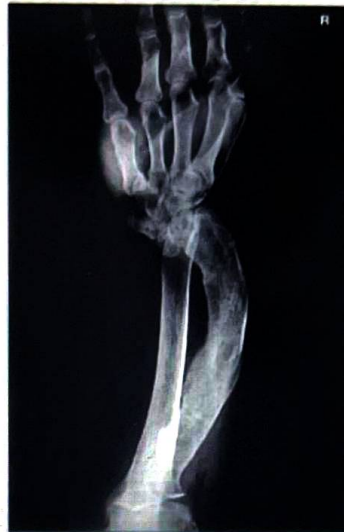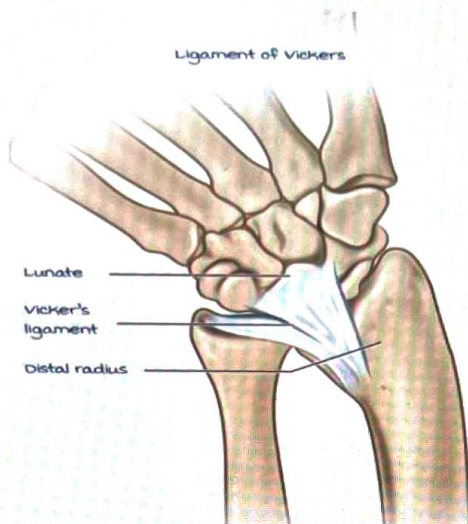
60c6b3eaaa8ded0e4e7e5ea7

Treatment :

Surgery done if patient has movement restriction at the wrist.

Darrach's procedure : Resection of the terminal end of ulna.

Active space



Ligament of Vickers

Madelung deformity

Types of limb deficiency

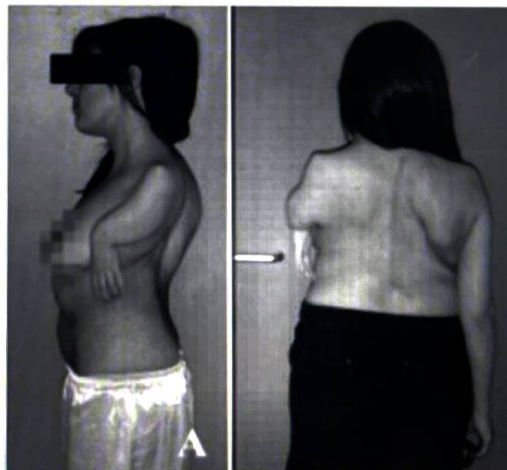00:43:46

Amelia :

Complete absence of limb/absence of both long and short bones.

Phocomelia :

Long bones are absent, short bones are present. Seal limb seen in thalidomide poisoning.



Phocomelia

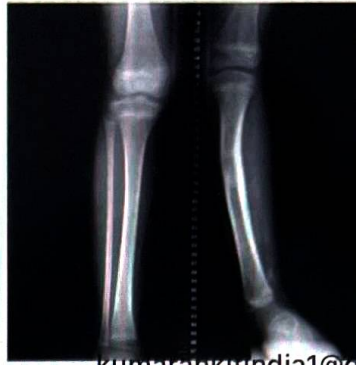Hemimelia :

Longitudinal deficiency of limb.

most common is fibular hemimelia, where fibula is absent.

In these cases, the other bone turns towards absent bone.

Active space



Kumarankitindia1@gmail.com
Fibular hemimelia

Radial hemimelia/radial club hand

00:46:05

Longitudinal deficiency of radial side of the limb, ulna will bend towards the radius.

Complete > partial deficiency.

Complete :

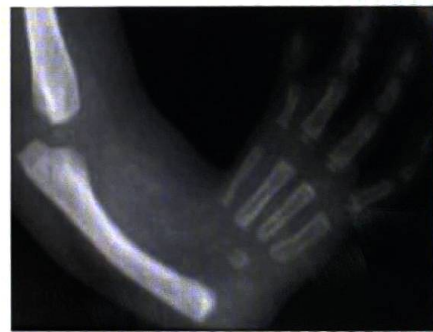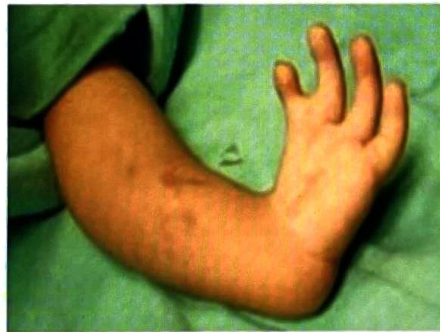Everything in the axis will be absent.

Radius, scaphoid, trapezium and thumb (40% of the hand) will be absent.

Partial hemimelia :

Some parts of axis will remain.

It is called club hand as it looks like a golf club.



Radial club hand

Associations :

Holt oram syndrome : Abnormalities of limb & heart.

Fanconi syndrome.

TAR syndrome : Thrombocytopenia & Absent Radius

VACTER syndrome.

Vertebral.

Anal.

Cardiac.

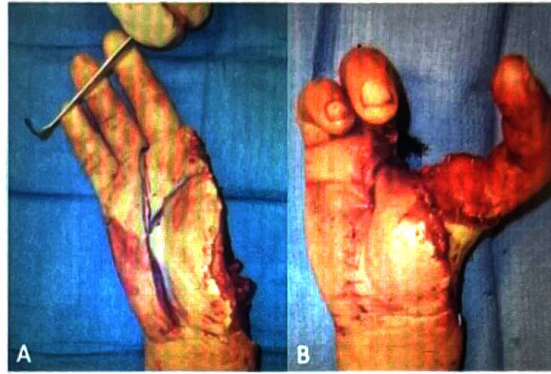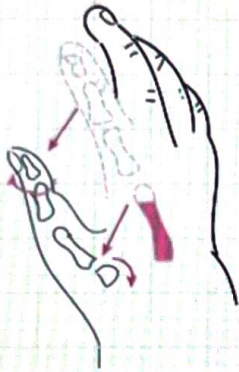
Tracheoesophageal fistula.

Esophageal atresia.

Renal & radial anomalies.

Treatment :

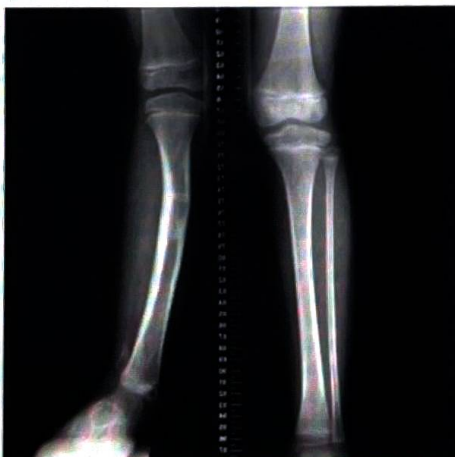Centralization of hand over ulna & pollicization of index finger/great toe.



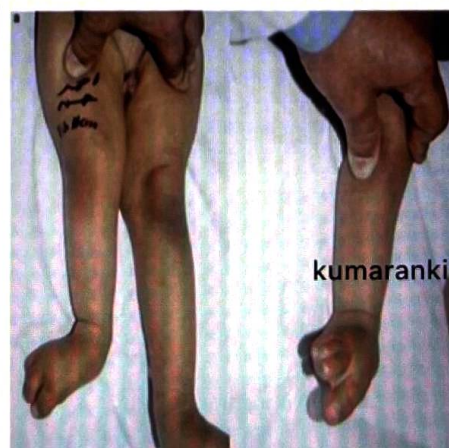Pollicization

Fibular hemimelia v/s pseudoarthrosis of tibia :

Fibular hemimelia	Pseudoarthrosis of tibia
Absent fibula on X ray.	No absent bones on X ray.
Angulation deformity of leg along with absent fingers due to axial deficiency.	Only angulation deformity
	Causes : most commonly seen in neurofibromatosis. Idiopathic. Congenital pseudo arthrosis of tibia due to intrauterine non union of tibia.



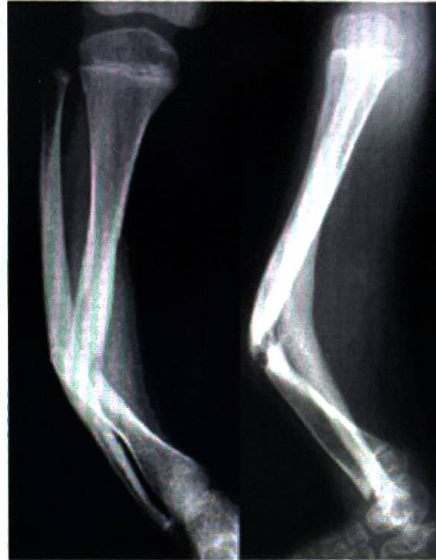Fibular hemimelia



Fibular hemimelia

kumarankiindia1@gmail.com

Active space

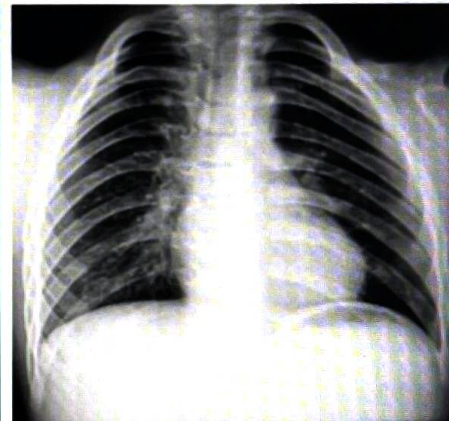
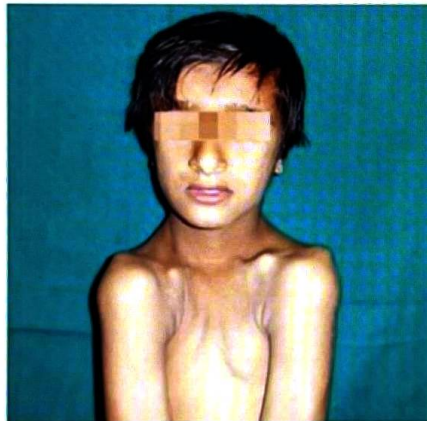


Pseudoarthrosis of tibia

Cleido cranial dysostosis :

Abnormality in the skull and clavicle.

60c6b3eaa8ded0e4e7e5ea7
 Congenital absence of clavicle (shoulder can be brought close to each other).

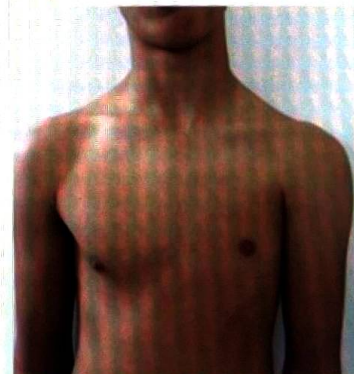
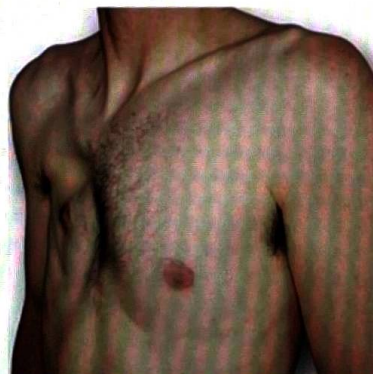
Cleido cranial dysostosis

Poland syndrome :

Congenital absence of muscle.

most common muscle to be absent is pectoralis muscle.



Poland syndrome

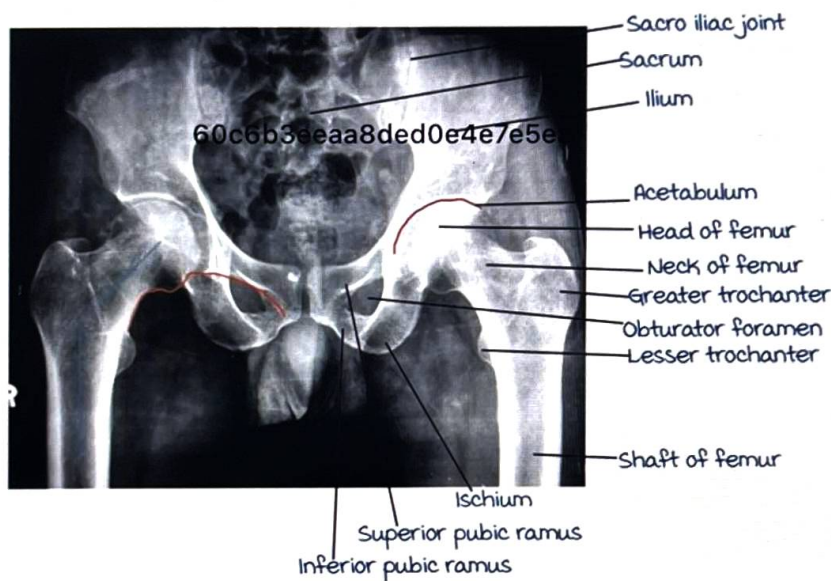
PAEDIATRIC ORTHOPAEDICS : PART 2

Normal pelvis and hip

00:00:34

Shenton's line/arch : Line drawn from inferior margin of superior pubic ramus running laterally towards the medial part of head and neck of femur, ending just before lesser trochanter.

Disruption of Shenton's line : Pathology of hip joint.



Neck shaft angle :

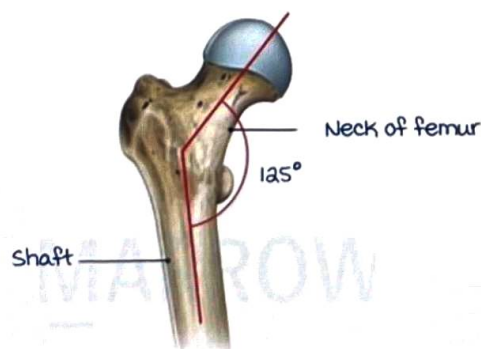
Normal neck shaft angle : 120° - 130° .

In children, angle is more and decreases with age.

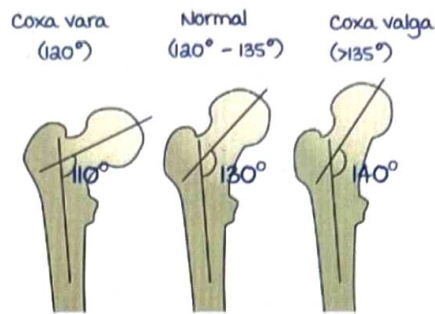
Coxa vara : $< 120^{\circ}$ (shaft moves towards the mid-line).

Coxa valga : $> 135^{\circ}$ (shaft moves away from the mid-line).

Femur neck-shaft angle



Active space



Physis in children : 5-7

In children - Hip has 2 growth plates :

- Below the head of femur.
- Below greater trochanter.

Epiphysis on the head of femur : **Capital femoral epiphysis.**

Blood supply of head of femur :

- metaphyseal.
- Foveolar.
- Bridge age group (4-10 years - where blood supply of femur shifts between metaphyseal & foveolar, increasing risk of Perthe's disease).

Coxa vara

00:06:28

Common features :

1. Decrease in neck shaft angle $< 120^\circ$.
2. Limitation in abduction & internal rotation :
3. So, every time hip flexes it goes into external rotation :

Obligate external rotators :

- Perthe's.
- SCFE.
- Congenital coxa vara.

4. Axis deviation :

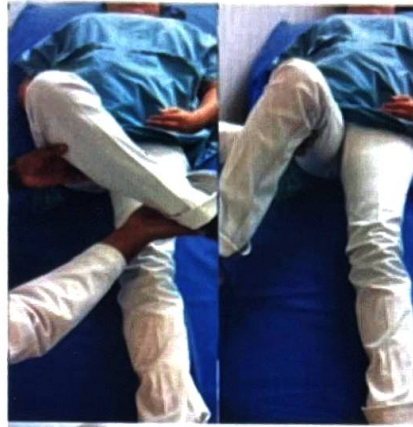Knee pointing towards the same side on flexion of knee & hip.

5. Trendelenburg gait : Failure of hip abduction.

Trendelenburg gait :

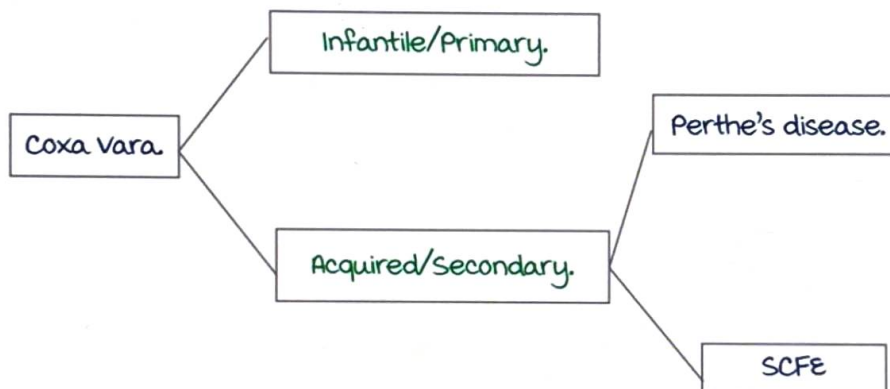
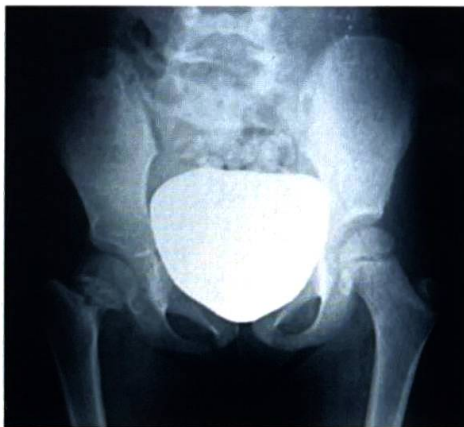- Principle abductors of Hip : **Gluteus medius & minimus.**
Supplied by superior gluteal nerve.
- Reduced neck shaft angle leads to proximal migration of greater trochanter, so the gluteus medius is shortened.

- According to Frank-Starling law, more stretch more the strength.
- So shortened or relaxed muscle is a **weak muscle**.
- Abductor failure : Trendelenburg gait.

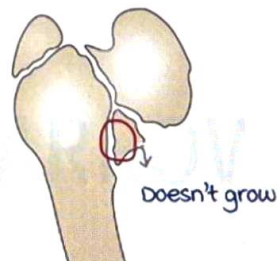


Axis deviation

Types of Coxa vara

Congenital (infantile) Coxa vara kumarankitindia1@gmail.com

Infantile coxa vara.

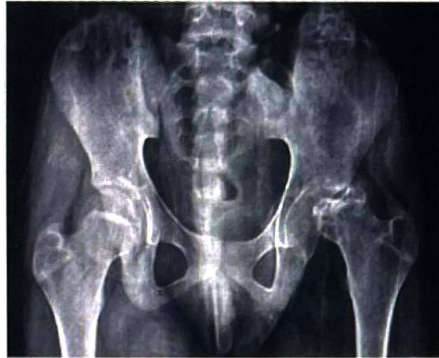

- Also known as infantile/primary Coxa vara.
- Developmental anomaly of a part of triangular part of neck of femur, neck stops growing : **Fair Bank's Triangle**.

- The greater trochanter grows more than neck.
- This leads to Coxa vara.
- Clinical features : Similar to Coxa vara.

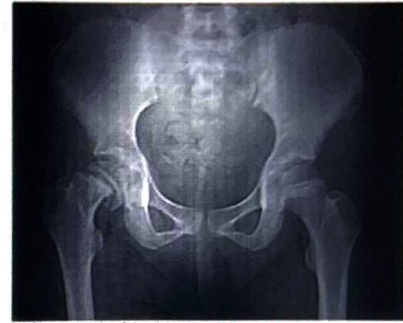Acquired Coxa vara :

- Perthe's Disease.
- SCFE.



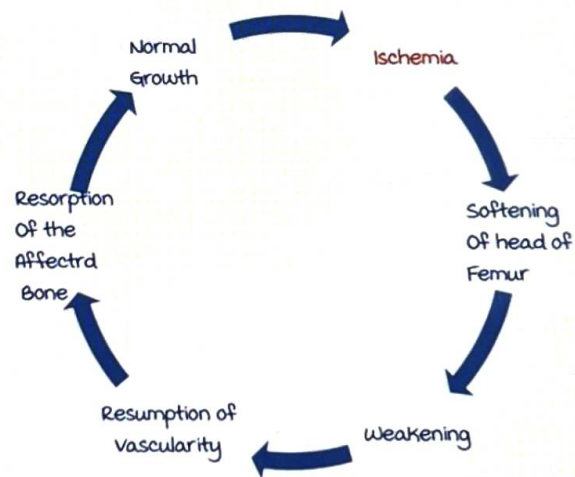
60c6b3eaaa8ded0e4e7e5ea7

Perthe's Disease



SCFE

- Perthe's Disease :



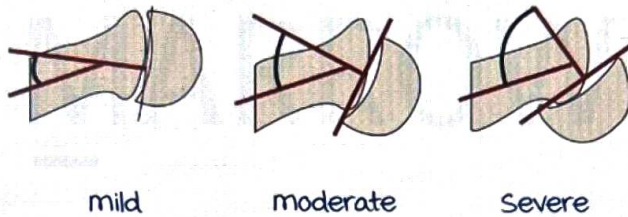
Features :

- Limitation in abduction & internal rotation.
- Obligate external rotators.
- Axis deviation.
- Trendelenburg gait.

Slipped capital femoral epiphysis

00:14:20

- Split fracture at the growth plate of capital femoral epiphysis (Type I Salter Harris fracture).
- Head (CFE) remains inside the acetabulum, whereas the neck of femur slips superolaterally (Hence SCFE is a misnomer).
- Bilateral : 40%.
- 60% cases are associated with endocrinopathy.



most common cause : Idiopathic.

most common endocrinopathy associated is :

- Hypothyroidism.
- Hypogonadism.
- Increased growth hormone.

male > Female

Risk factor : more weight for age in children.

Pathophysiology :

- Growth hormones helps the bone grow, whereas sex hormones help in fusion of growth plate.
- Decreased sex hormone and relatively increased growth hormone leads to abnormal growth of bone without adequate fusion of the growth plate.
- At puberty due to surge of growth hormone the weak and vulnerable growth plate undergoes a split fracture.

Clinical features :

- usual age of presentation is at puberty, males 13-17 years, females 11-14 years.
- Hypogonadism.
- Boys with girly voices.
- Gynecomastia.
- Coxa vara.

Restricted abduction and internal rotation.

Axis deviation of hip.

Trendelenburg Gait.

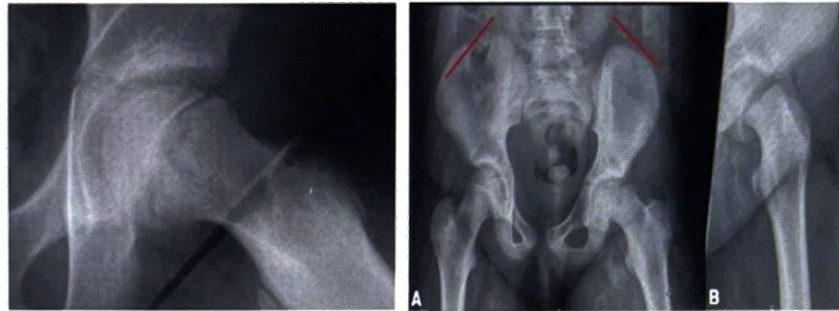
- Outward facing toe gait.

Investigations :

Investigation of choice : **MRI scan.**

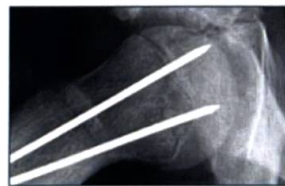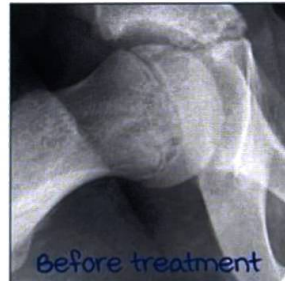X-ray : **Trethowan's sign :**

Klein's line - An extended line drawn from lateral part of femur, normally intersects at the lateral part of head of femur, in patient with SCFE it does not intersect at the head of femur.



Treatment :

Closed reduction + internal fixation with insitu pinning.
Slipped capital femoral epiphysis (SCFE)



Developmental Dysplasia of Hip

00:24:04

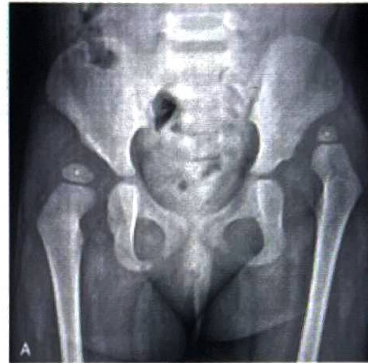Previously known as congenital dislocation of hip (CDH).

CDH is a misleading term as the condition occurs due to developmental anomaly of acetabulum/femur head where the head remains outside the acetabulum (was never dislocated).

DDH : Idiopathic spontaneous subluxation of femoral head.

Epidemiology :

- 1 : 1000 live births.
- Female > male.
- 20% cases are bilateral.
- Left side > bilateral > right side.
- Usually seen in first born female child with fetal malpresentation.
- (MC) breech : Frank breech with knee in extension.
- Positive family history.
- Usually, Caucasians.



Etiology :

Idiopathic (most common Cause).

Patho-anatomy

1. Acetabulum (most common) :

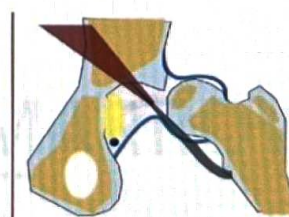
- Shallow. 60c6b3eaa8ded0e4e7e5ea7
- Flat.
- Convex.

2. Femoral head anomalies.

Aetiology & Pathology :

- Inverted limbus.
- Lax ligamentum teres.
- Interposed iliopsoas tendon (between head and acetabulum).
- Pulvinar fat pad (Excess fat pad).
- Capsular constriction : Shape of hourglass.
- Transverse acetabular ligament : Hypertrophy of ligament prevents head of femur going inside.

These prevent the head of femur from sliding into the acetabular cavity



Etiopathology of DDH

Clinical diagnosis :

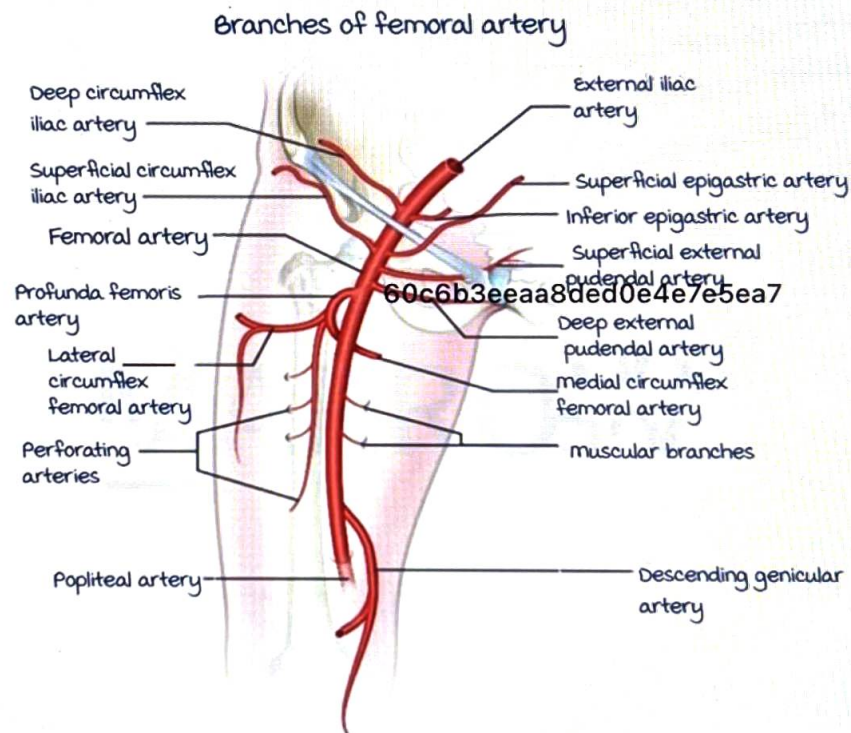
Female child :

- Short limb
- Asymmetrical thigh & gluteal folds
- **Vascular sign of Narath :**

Inability to feel the pulsations of femoral artery against the femoral head.

Sign is seen in :

1. Surgical excision of head of femur
2. Dislocation of Hip.
3. **Developmental dysplasia of Hip.**
4. Destructive pathology of head of femur.



- < 3-month child :

Barlow test :

Dislocatable Hip.

Barlow is a 'BAD' test.

Two step test.

1st step is **Adduction** : Dislocatable hip is dislocated. (first click)

2nd is **Abduction** : Dislocated hip is reduced. (second click)

In a normal hip, there is no dislocation on adduction.

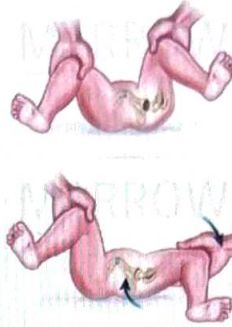
Ortolani test :

Dislocated Hip.

One step test.

On abduction of hip, relocation of a dislocated hip occurs.

Ortolani's Test

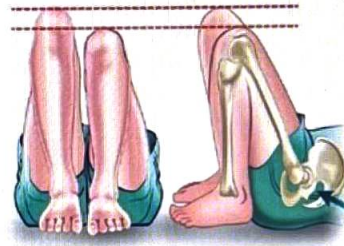


- > 3 month child :

Barlow's & Ortolani's test not done as soft tissue must have filled the space between acetabulum & femur head, preventing its reduction.

Allis / Galeazzi sign :

- Used in unilateral DDH.
- Flex both hips and knees.
- At side of DDH, knees will be at a lower level.

**Klispic test :**

For bilateral DDH.

Trendelenburg gait :

- Seen in unilateral DDH.
- Due to greater trochanter being at a proximal level due to dislocation.
- Attitude of hip : Flexion, adduction, internal rotation.

Waddling gait :

- Seen in bilateral DDH.

kumarankitindia1@gmail.com

Investigations

00:35:30

Screening investigation of choice :**Ultrasonography** for < 6 months.

- **Alpha angle** : Reduced in DDH.
- **Beta angle** : Increased in DDH.

Investigation of choice :

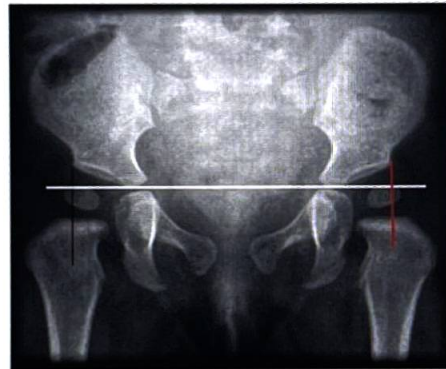
For confirmation of diagnosis : **MRI**.

For treatment planning : **MRI**.

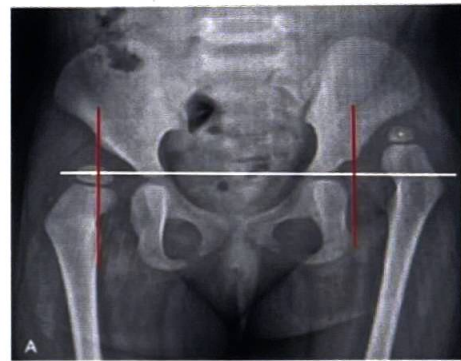X-ray findings :

- Acetabulum is a **triradiate cartilage**.
- Shenton's arch :
Normal and continuous.
- **Hilgenreiner's line** :
Horizontal line along inferior aspect of triradiate cartilages.
- **Perkin's line** :
Line drawn from lateral border of acetabulum perpendicular to the hilgenreiner's line.

Normal X-ray child



Hilgenreiner's and Perkin's line



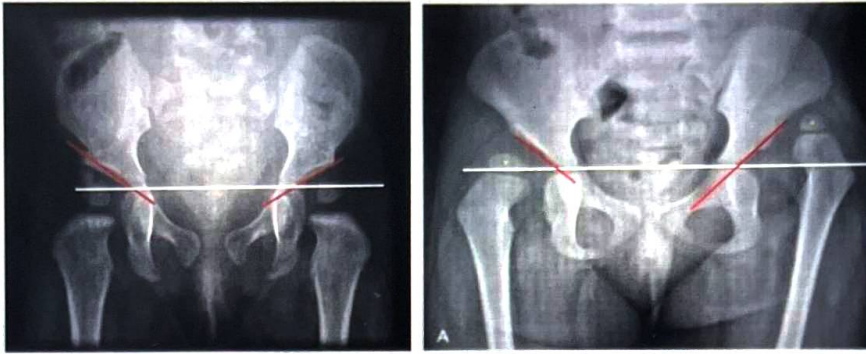
These 2 lines divides hip into 4 quadrants :

In normal child : Head of femur will be in Inner and lower quadrant.

In DDH : Head of femur will be in **upper and outer quadrant**.
Shows **femoral dysplasia**.

For acetabular dysplasia
kumarankitindia@gmail.com

- **Acetabular Index/angle** : Angle between the acetabular surface and the hilgenreiner's line.
If index/angle is more : Pathology in acetabulum.
Low index points to normal acetabulum.

Normal \neq DDH

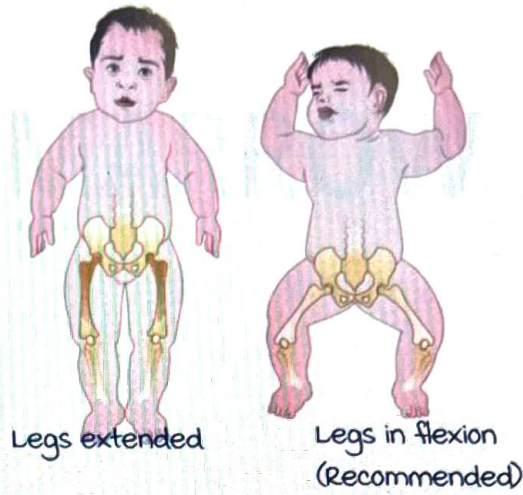
Incidence of DDH in Indian population

- Incidence is particularly low because of the way of holding babies.
- The hip of baby is **abducted**, and this will force head of femur into triradiate cartilage of acetabulum.
- Because of the constant force, triradiate cartilage remodels itself.



- DDH is more seen in certain ethnic group of people, who keep their babies in a **unique position**.
- Seen in **Native Americans, Red Indians** etc.
- Hip and knees extended with adducted hips, with no force on acetabulum.





Treatment

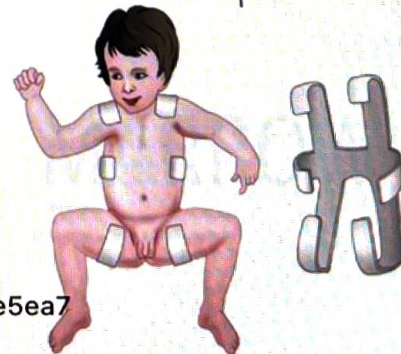
00:41:35

Age	Treatment
0 - 6 months	Pavlik Harness, von Rosen Splint. (Abducts the hip)
6 - 18 months	Reduction - Open/Closed - Cast (Bachelor) Smith Peterson Approach.
18 - 36 months	Femoral osteotomy : VDRO.
> 3 years	VDRO + Pelvic osteotomy (Salter : commonly done, Pemberton : Better results).
>10 years	Total Hip replacement after skeletal maturity.

Pavlik harness



Von Rosen Splint



Active space

After 18 months : Triradiate cartilage ossifies - osteotomy is required.

After 3 years : whole of pelvis ossifies, so pelvic osteotomy is required.

PAEDIATRIC ORTHOPAEDICS : PART 3

Genu : Knee Coxa : Hip

Valgus : Limb distal to knee away from midline.

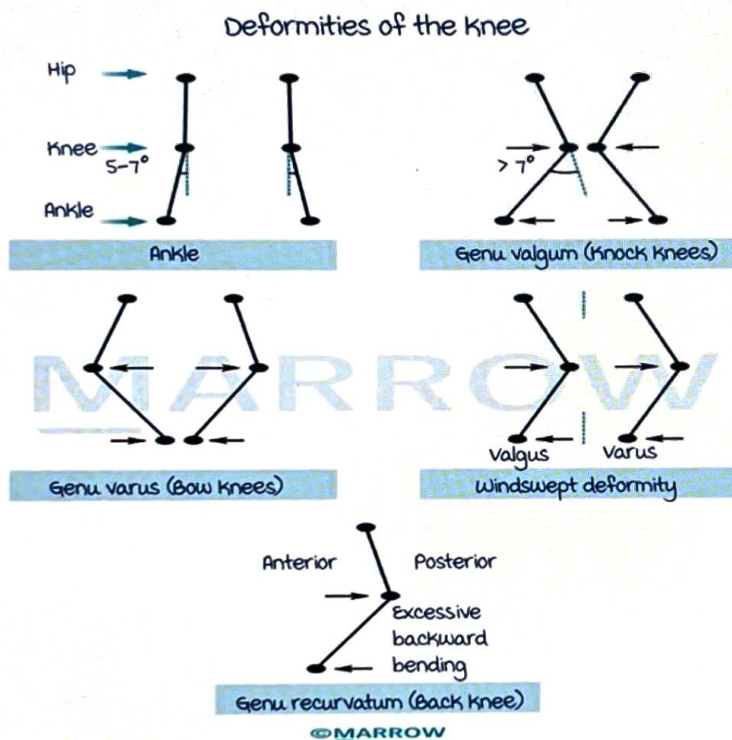
Knock knees.

Varus : Limb distal to knee towards midline.

Bow knees.

Genu recurvatum : Hyperextension occurs

Back knees.



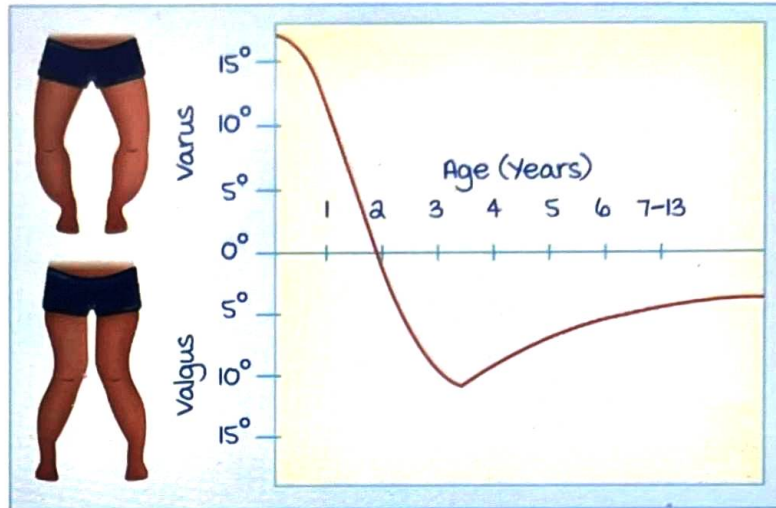
Physiological varus to valgus :

In children, attitude changes from varus to valgus.

- At birth : significant genu varus (15-20°).
- By 2 years : Correction occurs (physiological correction).
Beyond 2 years, if varus present → **Pathological**.
- Goes into valgus : Peaks at 3-4 years of age.

In normal child, valgus comes to **neutral with residual valgus (5-7°)**.

Residual valgus more in female > male.



- Tibial femoral angle is genu varum or bowing at birth, approximately 15 degrees.
- There is gradual spontaneous correction to zero degrees at one and one-half to two years of age.
- During the next year, a valgus of 10 degrees to 12 degrees develops which gradually corrects to the normal adult value of 5 to 6 degrees valgus at about age seven years. This process is identical in boys and girls

Pathological causes

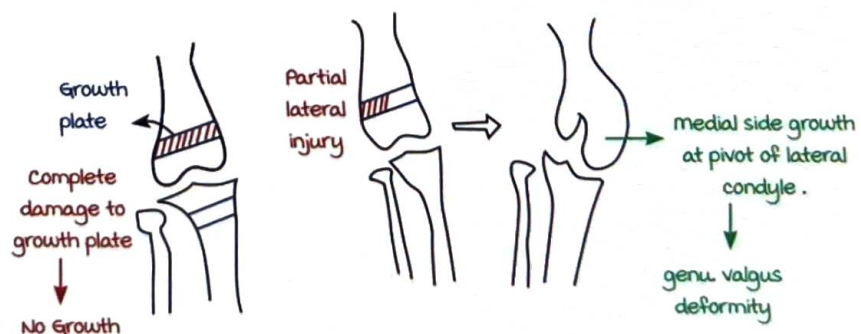
00:04:32

- Trauma to the growth plate : Leads to deformity.
Total injury : Limb length discrepancy.
Partial injury : Deformity like varus or valgus.
Lateral and medial growth plate injury manifestations in terms of varus and valgus.

If partial injury to lateral growth plate (GP) : medial GP continues to grow but not lateral part at pivot of lateral condyle → Genu Valgus.

If medial condyle damaged GP → Genu Varum.

- Deformity due to disease process :
 1. Congenital
 2. metabolic : Rickets



Management of deformity

00:06:32

If child has **growth potential**.

- Epiphysiodesis/stapling :

Intact part of GP manipulated such that its growth matches the growth of damaged part.

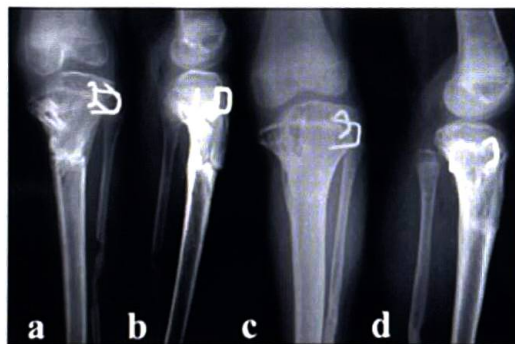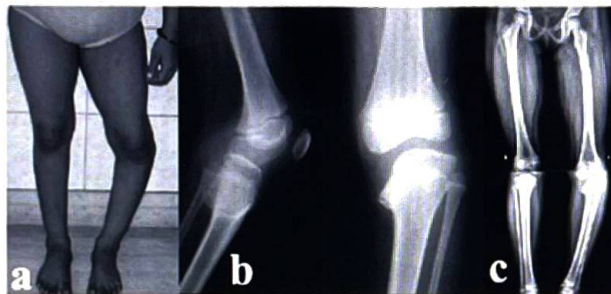
Normal GP grows at same pace as that of damaged GP.

Child with G. valgus :

Defective tibial proximal medial GP.

60c6b3eeaa8ded0e4e7e5ea7

staple the lateral side or fuse it to such extent that the growth of **normal growth plate is decreased** to match the growth of the damaged GP eventually deformity gets corrected.



Stapling done in lateral growth plate

If growth plate fused or completed growth potential.

- Osteotomy : Cutting of bone

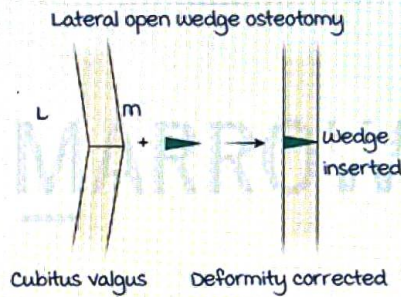
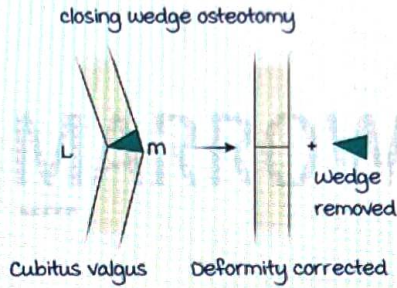
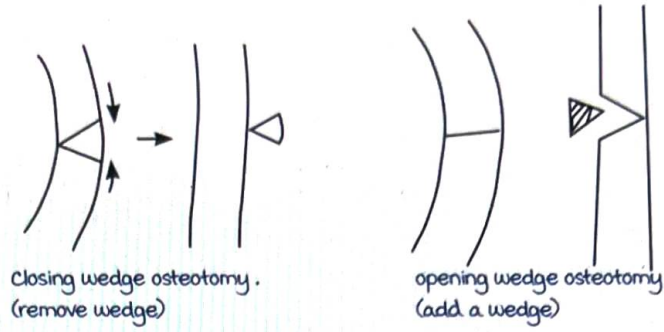
Closing : Remove a chunk of bone and close the bone.

Open : Cut out the bone and open the edges then insert a chunk of bone.

In cubitus valgus forearm goes laterally :

1. medial closed wedge osteotomy done, or
2. Open lateral side and insert a wedge of bone.
(Lateral open wedge osteotomy)

Active space

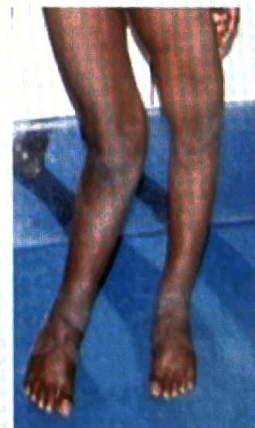
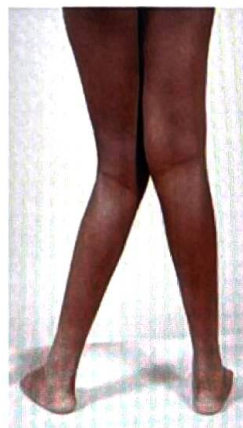
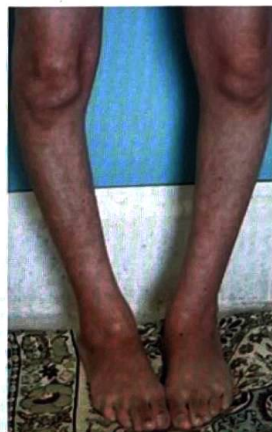most common(MCC)	Bilateral Genu Varum (Bow Legs)	Bilateral Genu Valgus (Knock Knees)	Wind Swept Deformity
MCC in Children	Rickets > Idiopathic	Idiopathic > Rickets	Rickets
MCC in adults	Osteoarthritis > Rheumatoid Arthritis	Rheumatoid Arthritis > Osteoarthritis	Rheumatoid Arthritis

Bow legs

Knock knees

Windswept deformity



Active space

MCC windswept of knee : Rickets.

MCC windswept of foot : Rheumatoid arthritis.

MCC windswept deformity : Rickets.

Blount's disease/ Infantile tibia vara

00:13:08

Defect at proximal medial tibial physis

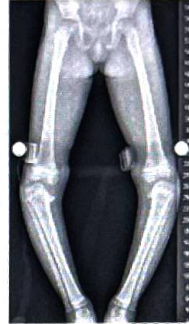
1. Bilateral idiopathic tibia/genu varum (lateral side will grow).
2. Genu recurvatum (hyperextension).
3. Internal rotation of tibia.

triad

Sign : Siffert-Katz Gait/Sign :

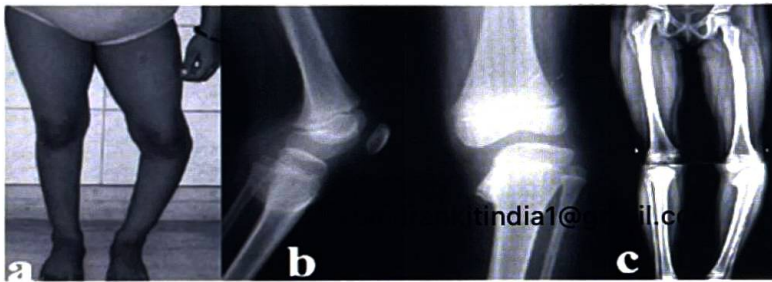
Because of defect, patient's knee becomes unstable. Varus instability at 15° of knee flexion

X-Ray : metaphyseal beak.



Blount's disease

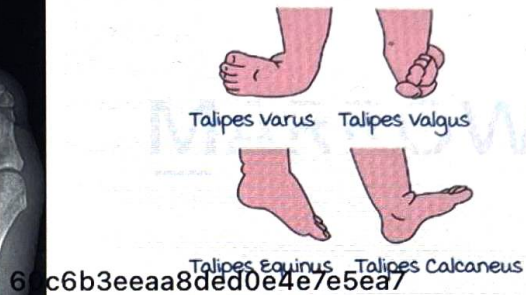
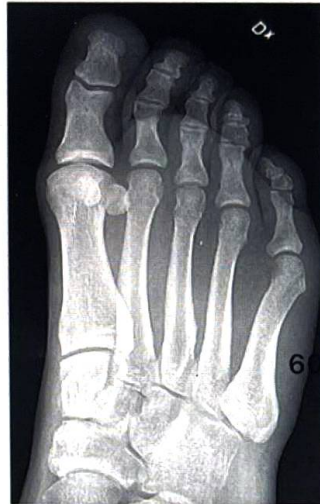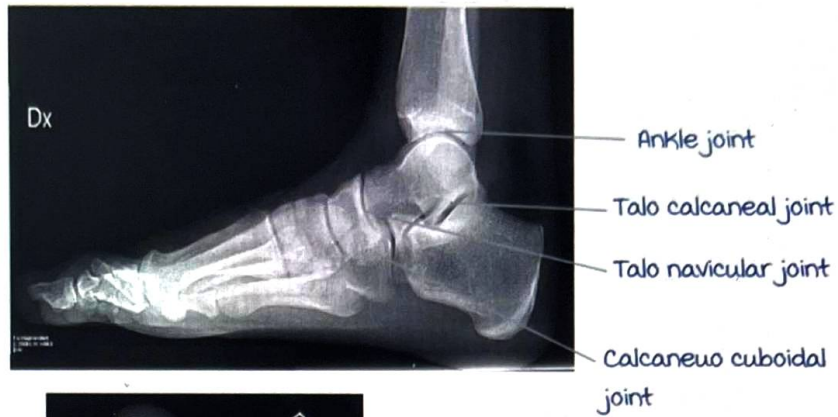
metaphyseal beaking

**Foot**

00:14:26

- Joints of the foot and its action :
 1. Tibio Talar /ankle joint : Ankle plantar/ dorsiflexion
 2. Talo-calcaneal/ subtalar joint : Inversion/ eversion of foot
 3. Talo navicular & Calcaneocuboid /mid Tarsal joint (better visible in AP view) : Fore foot adduction /abduction
 4. medial longitudinal arch of the foot : Cave of the foot.

Active space



Joint	Position Of Deformity	Term
Ankle Joint /Tibio talar Joint	Ankle plantar flexion	Equinus Deformity
Ankle Joint /Tibio talar Joint	Ankle dorsi flexion	Calcaneus deformity
Subtalar / talo calcaneal	Inversion of foot	varus deformity
Subtalar / talo calcaneal	Eversion of foot	valgus deformity

- Talipes : Congenital deformity in which the foot is twisted from its normal position.
- Talipes cavus : High arched foot.
- Talipes equinus : Plantar flexion.
- Talipes calcaneus : Foot dorsiflexion.
- Talipes valgus : Abduction and eversion.
- Talipes varus : Adduction and inversion.

Arch of foot maintained medially by ligaments and called medial longitudinal arch of foot.

- If it is not maintained → Pes planus.
- If it is exaggerated → Pes cavus.

Congenital Talipes Equinus Varus (CTEV)

00:19:37

Anomaly with foot (Talipes) in plantar flexion (Equinus) & inversion (Varus).

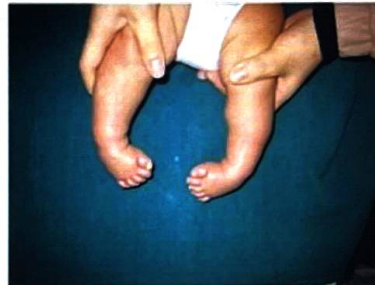Congenital abnormality of leg, ankle & foot.

Epidemiology :

- 50% is B/L.
- 1 : 1000 Live Births.
- male > female.
- First born child.
- Associated with breech & oligohydramnios .
- **Not associated with twin pregnancy.**

Etiology :

- Congenital / Primary. (mcc)
- most common cause : Idiopathic .
- Associated with :
 1. Spina bifida.
 2. Arthrogryposis multiplex congenita.



Spina bifida → Deformity in the neural elements of the spine
→ Neuromuscular imbalance → Imbalance between agonist and antagonist muscles of the foot and ankle → Deformity

Arthrogryposis multiplex congenita → Congenital abnormal fibrosis of muscles → Abnormal contracture of muscles. → Deformity.

Secondary causes / After birth / Acquired TEV :

- Neuromuscular disorders- Polio.

Poliomyelitis : The viral infection causes imbalance of agonist and antagonist muscles of foot/ankle.

Pathoanatomy :

- Hypo plastic talus → Talonavicular subluxation/ dislocation → unstable foot → Tendoachilles and tibialis posterior overpowers (pull) → Deformity.
- **Gastrosoleus through tendoachilles : Will cause equinus.**

Tibialis posterior : Will cause equinus, adduction and inversion deformity.

- Primary deformities of foot :

Cavus : Exaggeration of medial longitudinal arch.

Adduction : Forefoot adduction at Talonavicular & Calcaneo-cuboid joint/midtarsal joint.

Varus : Inversion at talocalcaneal/subtalar joint.

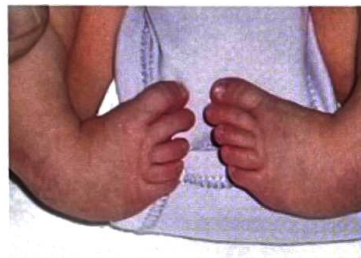Equinus : plantar flexion at tibio talar/ ankle joint.

Everything is pulled downwards & inwards :

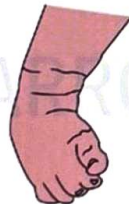
medial side of foot becomes concave & shortened .

lateral part convex and lengthened.

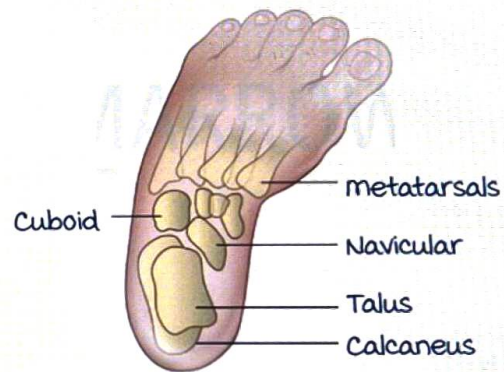
Internal rotation of tibia.



Pathoanatomy CTEV



Foot bones in CTEV



Kite's angle (talocalcaneal angle) :

Normal : 20-40°.

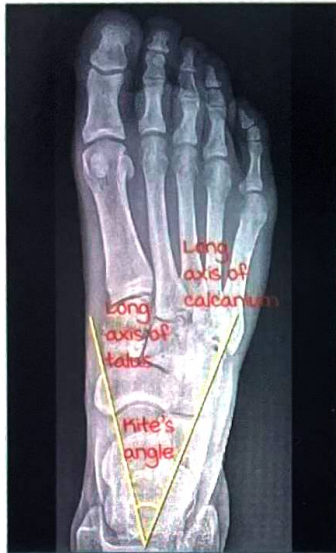In CTEV : Kite's angle / clubfoot angle is reduced or is almost parallel.

Normal : Calcaneum and talus face away from each other.

When lateral structures are pulled to medial side calcaneum will start to face medially.

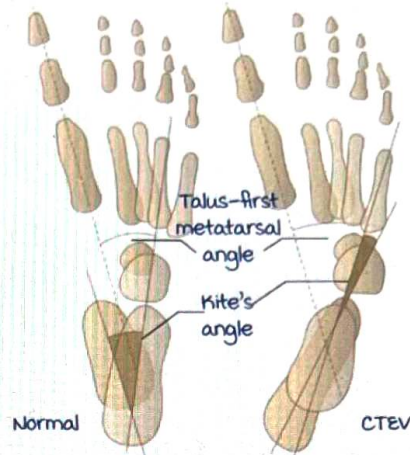
Calcaneum and Talus becomes parallel.

Not used for diagnosis.



Kite's angle

60c6b3eeaa8ded0e4e7e5ea7

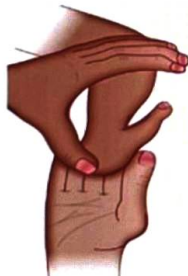**Dorsiflexion Test :**

Screening test & done right after birth.

In normal newborn, on **passive dorsiflexion of foot**, the **dorsum** of the foot will usually **touch** or closely approximate the anterior end of the **lower tibia**.

In clubfoot, **dorsiflexion is impossible** even when strong pressure is applied.

Dorsiflexion test

**Treatment :**

Improper treatment/**overcorrection** causes **rocker bottom foot**.

Treatment started by the doctor at least by 2 weeks.

manipulation and correction of the deformity.

manipulation held in position with POP for 1 week.

Remove cast.

Remanipulate the deformity.

maintained with cast again.

The above steps are repeated for atleast 8-9 weeks till deformity is corrected.

Correction achieved in 80-90% patients.



Ponsetti method :

Fulcrum of correction : Talar head.

Order of correction (CAVE)

- Cavus.
- Adduction & Varus.
- Equinus.

Then apply the POP

1) Above the knee.

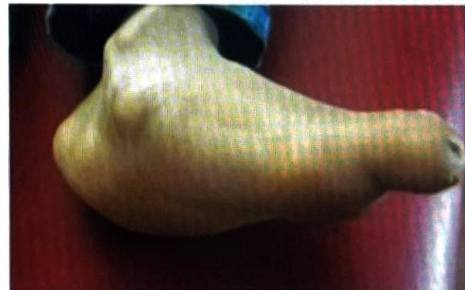2) Kept for 1 week.

Repeat after 1 week .

Process repeated for 8-9 weeks till deformity corrected in CTEV clinic.

Improper correction causes Rocker-bottom foot.

Other cause for Rocker-bottom foot : Congenital Vertical Talus.



Bones not completely ossified hence there is possibility of recurrence. 60c6b3eaa8ded0e4e7e5ea7

Denis brown splint for CTEV

00:29:59

To prevent recurrence in a corrected patient (by serial manipulation & casting).

Splint has to be applied till the child learns to walk (till 1 year of age).

Splint is designed such that when the baby moves the leg, the deformity keeps getting further corrected.

But due to low compliance → Recurrence occurs.



CTEV shoe :

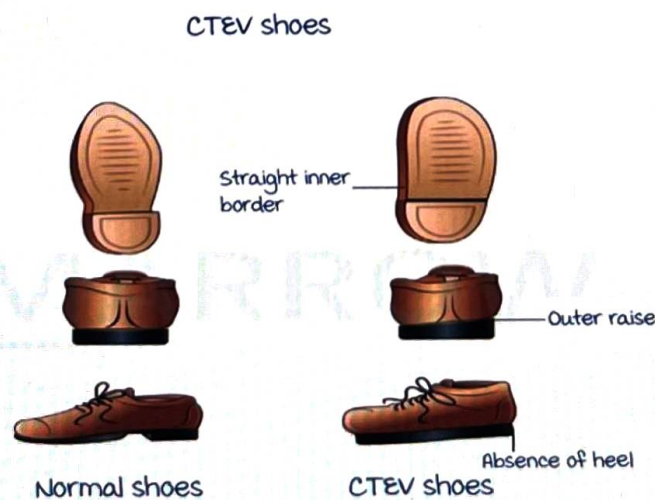
CTEV Shoes are used **after** the child starts walking .

Combination of Denis brown splint & CTEV Shoes advised :

- CTEV Shoes are used in daytime while child walks.
- During night when child sleeps Denis brown splint is used.
- To be used **upto 3-5 years of age** (till bones get ossified).

Characterstics of CTEV shoe :

1. Straight inner border to prevent adduction of fore foot.
2. Outer raise to prevent varus.
3. No heel to prevent equinus.



©Marrow

Active space

Modality of treatment as per age group

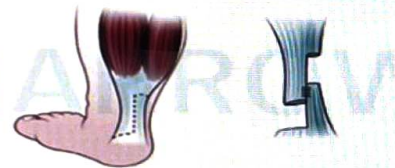00:33:05

- 0-1y :
Ponsetti serial manipulation & casting, Denis Brown splint, CTEV shoes (till 3-5 years).
- 1-3y :
By 1 year : Postero medial soft tissue contracture occurs.
Postero medial Soft Tissue Release (PmSTR) by Turco's Procedure → manipulation.
Structures released : Tendo Achilles.
Tibialis Posterior.
Flexor digitorum longus.

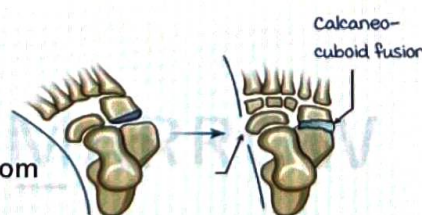
- By 1yr Soft tissue contracture occurs.
- By 3yr Forefoot adduction becomes bony.
- By 5yr Varus becomes bony.

- 3-5y :
Soft tissue contracture & forefoot adduction occurs.
PmSTR + Dilwyn Evan's Procedure done.
In Dilwyn Evan's Procedure, forefoot adduction is corrected by shortening of lateral column by calcaneo cuboid fusion.

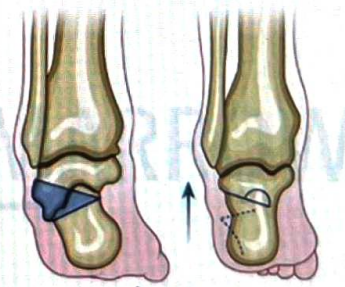
Postero-medial soft tissue release



- 5-8y :
Soft tissue contracture + forefoot adduction is bony + **bony varus** occurs.
PmSTR + Dilwyn Evan's + Dwyer's Osteotomy.
Dwyer's Osteotomy : a wedge is cut out (lateral closing wedge Osteotomy).



Dilwyn Evan's procedure

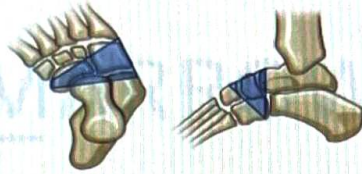


Dwyer's Osteotomy

kumarankitindia1@gmail.com

Active space

- 8-10 y : Wedge tarsectomy.



wedge tarsectomy

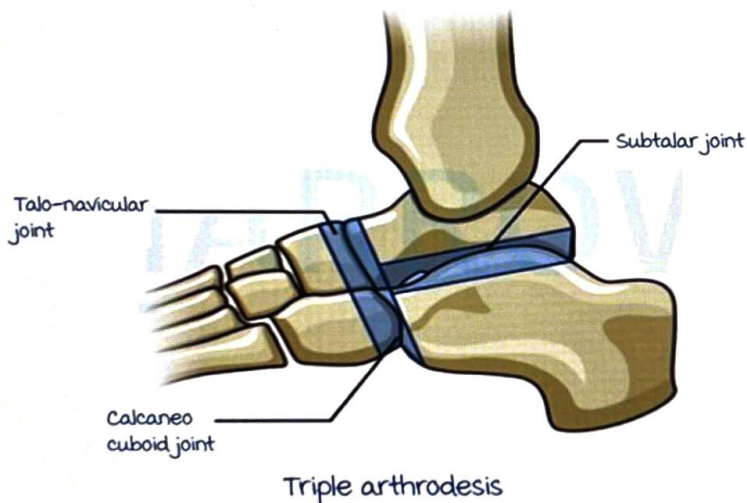
- > 10 y :

Triple arthrodesis :

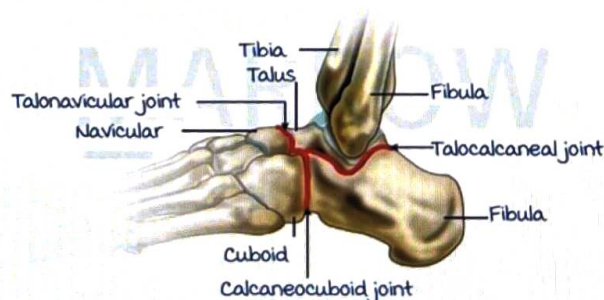
Fuse the foot in deformed position so as to provide stable foot to walk on.

Joints fused : 60c6b3eaa8ded0e4e7e5ea7

1. Talo-navicular (most important).
2. Talo-Calcaneal.
3. Calcaneo-Cuboid.



Triple arthrodesis



Triple arthrodesis (3 fusions)

Active space

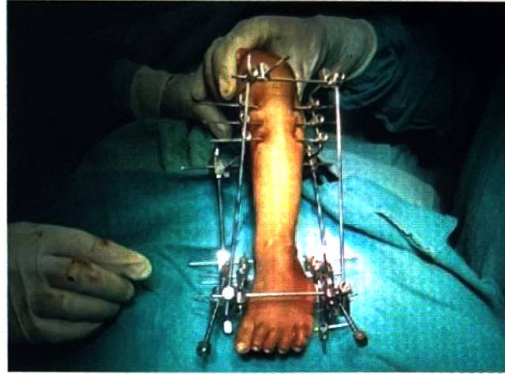
Other techniques :

- Ilizarov's method.
- Joshi's External Stabilization System (JESS) :

A modification of external fixator.

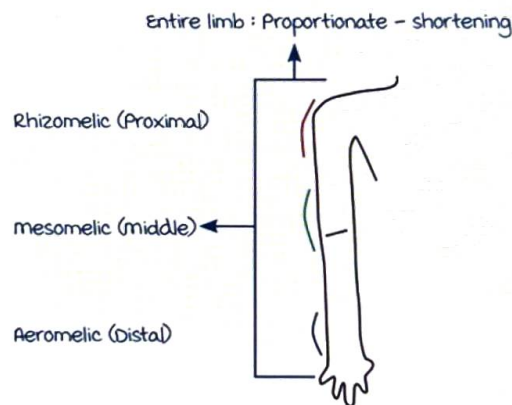
Frame applied to bone → causing stretching and deformity correction.

60c6b3eaa8ded0e4e7e5ea7



Achondroplasia

00:37:30



Proportionate dwarfism : Whole limb shortening.

Disproportionate : Parts of limb is shortened

- Acromelic : shortening of distal part.
- mesomelic: shortening of middlepart.
- Rhizomelic : shortening of proximalpart.

MC cause of disproportionate dwarfism.

Rhizomelic shortening present.

mutation in **FGFR3** gene on chromosome 4.

Autosomal dominant or sporadic.

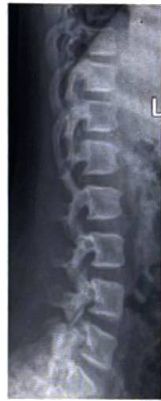
Enchondral ossification affected : Long bones affected

Intra membranous ossification is fine : Flat bones (skull & Clavicle) are unaffected

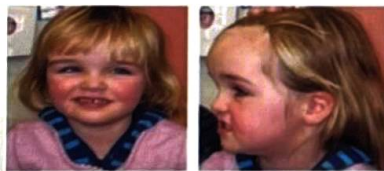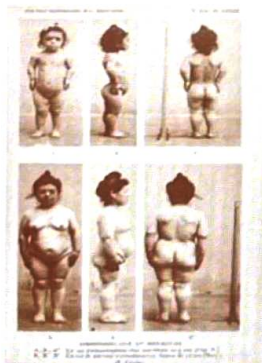
Normal IQ & Sexual development.

Deformities :

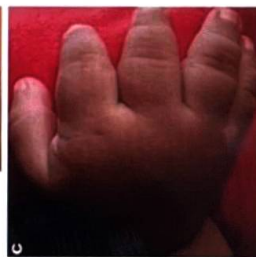
- Proximally migrated mid Point : As body is disproportionately shortened (trunk is larger).
- Brachydactyly : Short stubby fingers ,same length of fingers.
- Starfish hand.
- Trident hand : Exaggerated gap between middle and ring finger appearing in trident shape.
- Frontal bossing of skull.
- Saddle nose.
- Champagne glass pelvis.
- Bullet nose vertebra.
- Exaggeration of lumbar lordosis.



Bullet shaped vertebra



Frontal bossing



Brachydactyly

PEDIATRICS ORTHOPEDICS MCQS

Q. What is the commonest fracture seen in children ?

- A. Fracture clavicle.
- B. Supracondylar fracture.
- C. Green stick fracture of lower end of radius.
- D. All of the above.

Q. Thurston holland sign is seen in which type of injury ?

- A. Type 1.
- B. Type 2.
- C. Type 3.
- D. Type 4.

Q. An 8 year old boy with a history of fall from 10 feet height complains of pain in the right ankle. X ray taken immediately after the trauma showed no obvious fracture. 2 years after the trauma he developed a calcaneo-valgus deformity. what is the likely diagnosis ?

- A. Undiagnosed malunited fracture.
- B. Avascular necrosis talus.
- C. Tibial epiphyseal injury.
- D. Ligamentous injury of ankle joint.

Explanation :

A : A fracture would have been visible in the X-ray.

B. Avascular necrosis of talus would give rise to subtalar arthritis.

C. Fall from height can lead to crush injury (vertical loading) causing tibial epiphyseal injury.

D. Ligament injury would have immediate presentation.

Q. Phocomelia : Correct statement is ?

- A. Defect of short bones of limbs.
- B. Complete absence of extremities.

C. Defects of long bones of limbs.

D. Partial absence of extremities.

Explanation : Complete absence of limbs : Amelia.

Partial absence of limbs : Hemimelia.

Q. Madelung's deformity involves which of the following bones ?

A. Humerus.

B. Proximal ulna.

C. Distal radius.

D. Carpals.

Q. Which of the following is a cause of coxa vara?

A. Congenital defect.

B. Perthe's disease.

C. SCFE.

D. All of the above.

Q. Fairbank triangle is seen in which of the following conditions ?

A. DDH.

60c6b3eaaa8ded0e4e7e5ea7

B. Congenital coxa vara.

C. Perthe's disease.

D. SCFE.

Q. Which of the following movement is restricted in Perthe's disease of the bone ?

A. Adduction and external rotation.

B. Abduction and external rotation.

C. Adduction and internal rotation.

D. Abduction and internal rotation.

Q. Primary pathology in DDH ?

A. Large head of femur.

B. Shallow acetabulum.

C. Excessive retroversion.

D. Everted labrum.

Active space

Q. All can be seen in DDH except ?

- A. Real shortening with asymmetrical crease on the thighs.
- B. Spinal lordosis, broken Shenton's line.
- C. most common presentation is bilateral.
- D. Von Rosen splint is used.

Left > Bilateral > Right.

Q. In a dysplastic hip of a child, what is the investigation of choice ?

- A. X-ray.
- B. MRI.
- C. USG.
- D. CT scan.

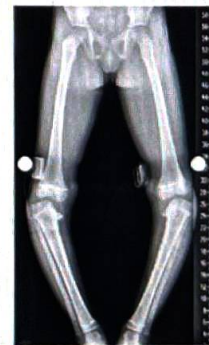Q. Raju, a 6 year old young boy, had a fracture of lateral condyle of femur. He developed malunion as the fracture was not reduced well. Which of the following deformity will the malunion likely produce ?

- A. Genu valgum.
- B. Genu varum.
- C. Genu recurvatum.
- D. Dislocation of knee.

medial epicondyle will grow more producing valgus deformity

Q. Blount's disease is associated with all of the following except ?

1. Genu varum.
2. Genu recurvatum.
3. Internal tibial torsion.
4. External tibial torsion.

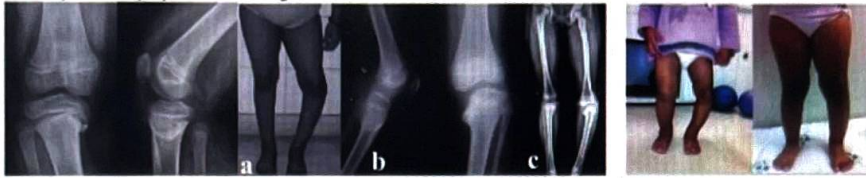

Blount's disease/infantile tibia vara :

- Defect at proximal medial tibial physis.
- Bilateral idiopathic genu varum.
- Genu recurvatum

(hyperextension).

- **Internal rotation** of tibia.
- Sign : Siffert-Katz sign
(varus instability at 15° of knee flexion).
- X-Ray : metaphyseal beaking.



Q. Following deformity of the foot can be caused by which one of the following ?

- A. Overcorrection of CTEV.
- B. malunited fracture calcaneus.
- C. Horizontal talus.
- D. Neural tube defect.

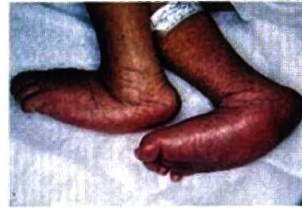

Image in picture is rockerbottom feet.

Q. Which of the following is not a cause of club foot in a newborn ?

- A. CTEV.
- B. Polio.
- C. Spina bifida.
- D. Arthrogryposis multiplex congenita.

E. A newborn child presents with inverted foot. On dorsiflexion the dorsum of foot cannot touch anterior tibia. What is the most probable diagnosis ?

- A. CTEV.
- B. Congenital vertical talus.
- C. Arthrogryposis multiplex.
- D. Flat foot.

Q. The ideal treatment of bilateral idiopathic club foot in a newborn is ?

- A. manipulation by mother.
- B. manipulation and Dennis Brown splint.

- C. Manipulation and casting.
- D. Surgical release.

Q. Block vertebrae is seen in ?

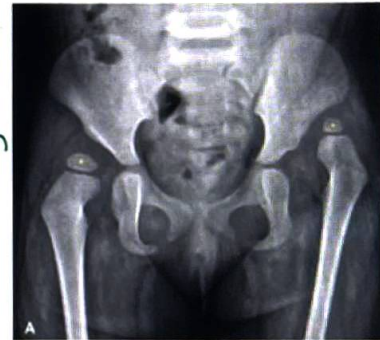- A. Paget's disease.
- B. Leukemia.
- C. Tuberculosis of spine.
- D. Klippel Feil syndrome.

Q. Which of the following is not true in case of congenital torticollis ?

- A. Seen only in cases of breech vaginal delivery.
- B. It can disappear spontaneously.
- C. It is also known as sternomastoid tumor.
- D. Neglected cases can result in plagiocephaly.

Q. A mother of a 6 month old baby complained that her child's legs do not open equally while changing the nappies. Given below is the diagrammatic representation of pelvic skeletal abnormality in the child. The abnormality is most likely :

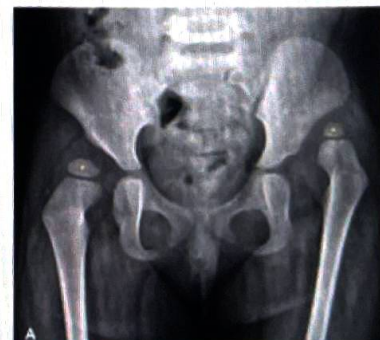- A. Perthes' disease.
- B. Rickets.
- C. Congenital dislocation of hip.
- D. Epiphyseal fracture.



Q. Below is X-ray pelvis of a one year old baby. In this child, all of the following tests will be positive except ?

- A. Narath's test.
- B. Ortolani's test.
- C. Gaenslen's test.
- D. Barlow's test.

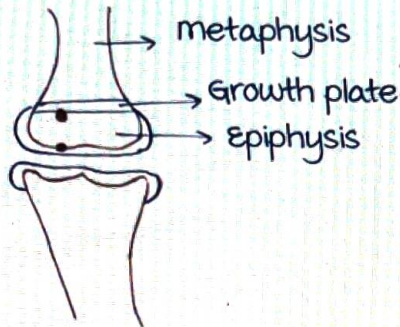
Gaenslen's is for Ankylosing spondylitis.



AVASCULAR NECROSIS AND OSTEOCHONDRITIS

Avascular necrosis (AVN) : Death of bone due to decreased blood supply.

Osteochondritis : Idiopathic bone necrosis, may be due to ischemia or repetitive bone trauma.



60c6b3eaa8ded0e4e7e5ea7

Osteochondritis

00:02:04

Avascular necrosis occurring at junction between bone & cartilage.

Osteochondrosis : Self-limiting developmental abnormality of bone growth.

Involves ossification centers in the epiphysis.

Usually begins in childhood as a degenerative or necrotic condition. Can also be self-limiting.

m/c cause is **idiopathic**.

Clinical and radiological evidence points to ischemic necrosis of the ossification center.

This process could be due to a primary vascular event, a traumatic event or multiple traumas overtime.

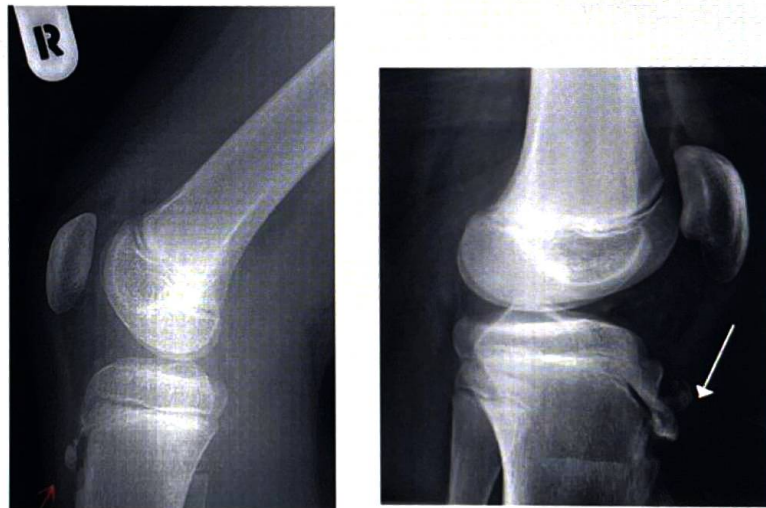
Osteochondritis	Bone involved.
Freiberg's disease	2 nd metatarsal head
Iselin's Disease	5 th metatarsal base
Kohler's disease	Navicular
Kienbock's disease	Lunate
Panner's disease	Capitulum

Active space

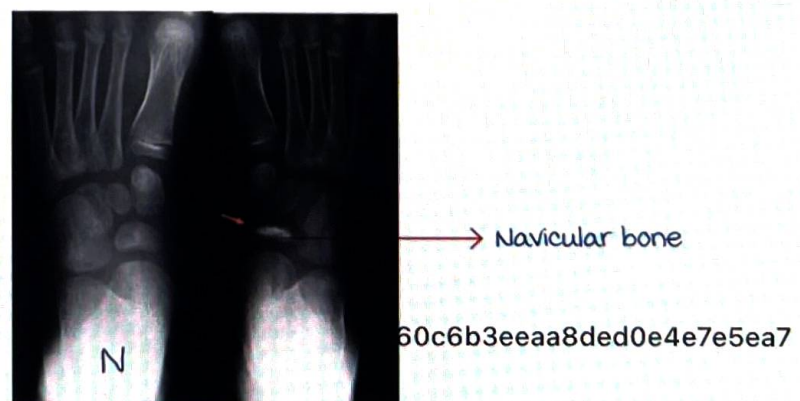
Scheuermann's disease	Ring epiphysis of vertebrae
Calves' disease	Central bony nucleus of vertebrae
Osgood-Schlatter's disease	Tibial tuberosity
Severe's disease	Calcaneal epiphysis
Johansen - Larsen syndrome	Inferior pole of the patella
Perthe's disease	Femoral epiphysis

Inflammation of cartilage and bone : Necrosis of bone.
Necrotic bone is visible as dense bone on X-ray.

Osgood-Schlatter disease :
Osteochondritis of tibial tuberosity.



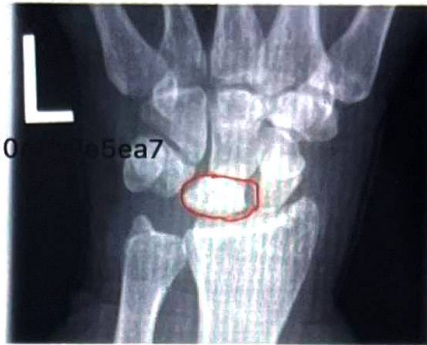Kohler's disease : Osteochondritis of navicular bone.



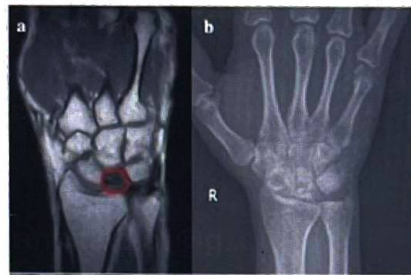
Kienbock's disease

00:05:49

60c6b3eaa8ded05ea7



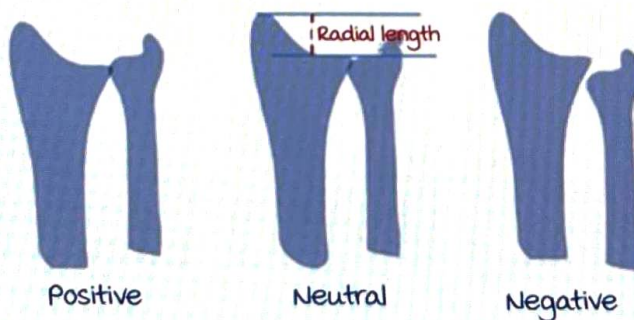
Osteochondritis of lunate



MRI

- Kienbock's disease is the **avascular necrosis** of the **lunate** which can lead to progressive wrist pain and abnormal carpal motion.
- Commonly occurs in elderly.
- Clinical presentation :
 - Pain and tenderness at the proximal end of **3rd metacarpal**.
 - Weak wrist extension → weak grip.
Particularly in manual labourers presenting with weak grip.

Kienbock's disease occurs due to **negative ulnar variance**.



Active space

Normal : Ulna is slightly shorter than radius ; distal ends of ulna and radius are at different levels. This difference is known as ulnar variance.

- Negative ulnar variance : When ulna is even shorter than radius.
- Positive ulnar variance : When ulna is taller than radius.

In **negative ulnar variance** :

- Increased radial-lunate contact stress.
- Loaded lunate bone → Necrosis.

Investigation of choice for osteochondritis/ischemia/necrosis of bone : **MRI** (picks up the changes in the bone very early). Lunate appears dark due to reduced vascularity.

Osteochondritis dissecans

00:09:53

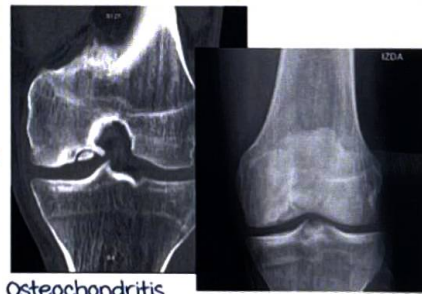Advanced stage of osteochondritis.

most commonly affected → **Knee joint** > **Elbow joint**.

Osteochondritis → Necrosis → Necrosed bone breaks off & freely moves in the joint space. (Acts as a loose body)

E.g. : Lateral part of medial femoral condyle in knee joint.

CT scan showing a small piece of bone broken from medial condyle of femur.



Osteochondritis

X-ray of knee joint showing osteochondritis dissecans.

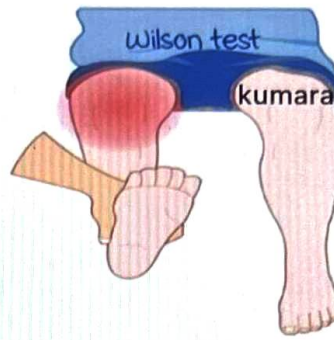
Clinical features :

- Limitation of movement : Freely moving loose body between femur and tibia → Obstructs flexion and extension.
- Pain in the knee : **wilson's test** is used to clinically diagnose.
- Internal rotation and extension of the knee → Lateral part of medial femoral condyle comes in contact with tibia can cause pain → Relieved on external rotation tibia and extension of knee.

X-ray : Tunnel view.

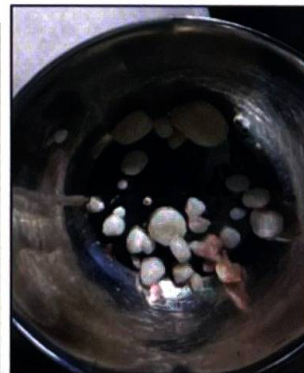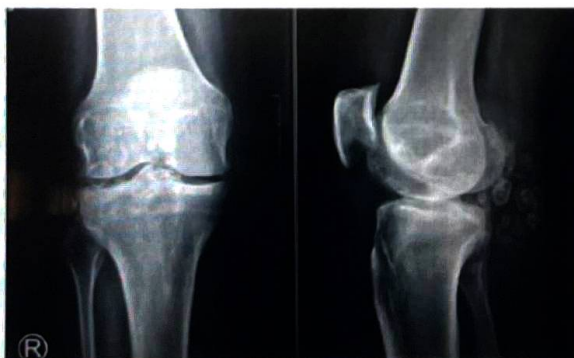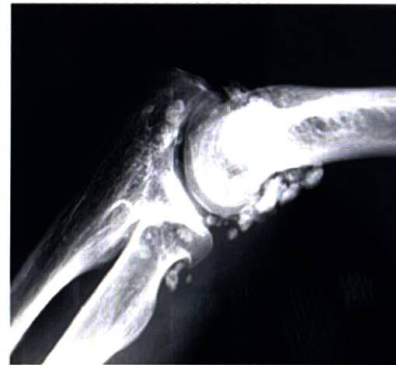
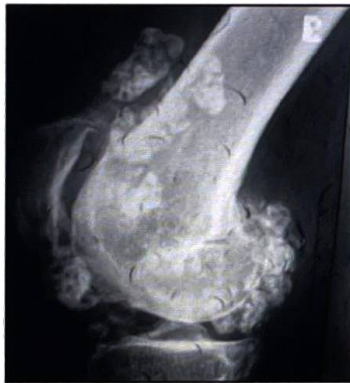IOC : MRI.

Treatment : Conservative,
arthroscopic removal of
loose body, microfractures to
stimulate healing, OATS
(Osteochondral autologous
transplantation system).



most common causes of loose body in knee :

Overall	Osteoarthritis (osteophytes).
Young	Osteochondritis dissecans.
Elderly	Osteoarthritis (osteophytes).
multiple loose bodies in knee	Synovial chondromatosis : metaplasia of synovium leading to multiple cartilaginous bodies in the joint (snowstorm appearance on X-ray).

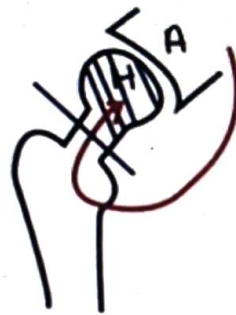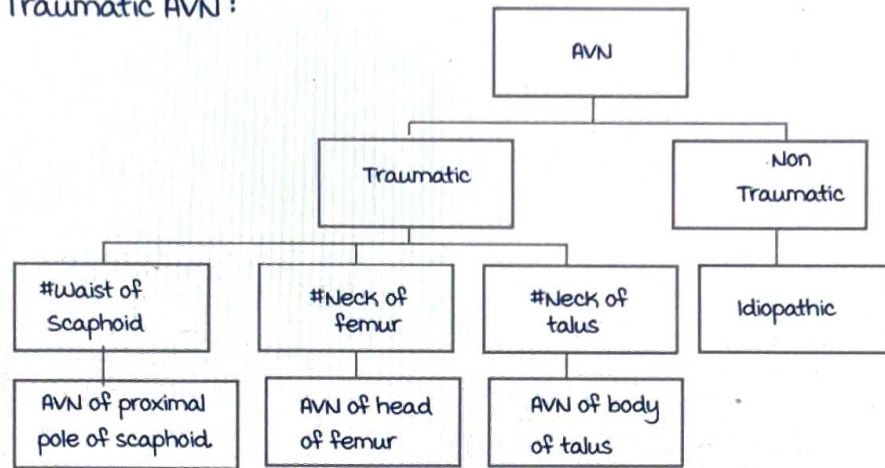


Examples of synovial chondromatosis

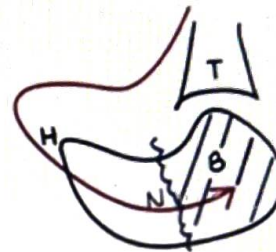
Avascular necrosis

00:17:31

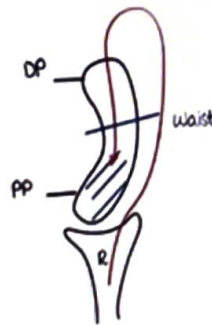
Traumatic AVN :



Head of femur necrosis following # neck of femur.



AVN of talus following # neck of talus.



AVN of proximal pole of scaphoid following #waist of scaphoid

Atraumatic AVN :

Bones with tendency for AVN :

- Head of femur (Chandler's Disease) (most common).
- Proximal pole of scaphoid.
- Body of talus.

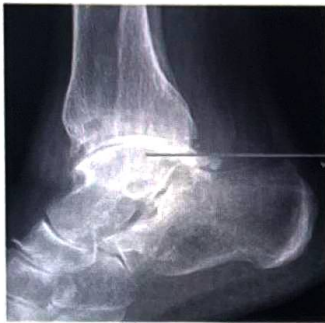Proximal pole of lunate.

- Distal femoral condyle.
- Head of humerus.
- Capitulum.

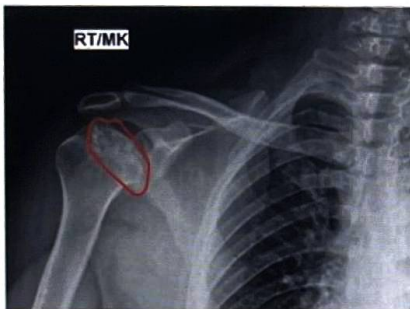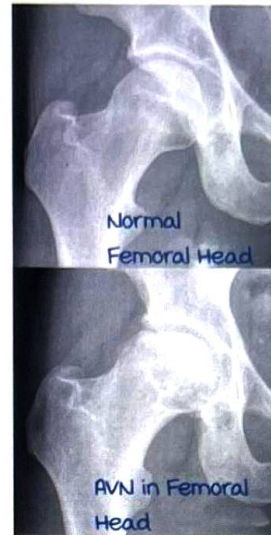Active space
60c6b3eeaa8ded0e4e7e5ea7

Dead or necrosed bone on Xray :

- Dense.
- Deformed.
- White/ sclerotic.



AVN of body of talus



kumarankitindia1@gmail.com



Snowcap sign : Dense and sclerotic head of humerus.

Causes of AVN :

most common cause of atraumatic AVN : **Idiopathic**

Traumatic causes

- Neck of femur #
- Hip dislocation >12Hrs.

Coagulation disorders :

- Familial thrombophilia.
- Hypofibrinolysis.
- Hypolipoproteinaemia.
- Thrombocytopenic purpura.

Non-traumatic causes :

- **Idiopathic : Chandler's Disease**
- **Infections** :
Osteomyelitis.
Septic arthritis.
- **Haemoglobinopathy** :
Sickle cell disease.
- **Storage disorders** :
Gaucher's disease.
- **Caisson disease** :
Dysbaric osteonecrosis.

Others :

- **Perthes' disease.**
- **Cortisone administration** (2nd most common cause).
- **Alcohol abuse.**
- **SLE** (increase in anti phospholipid antibodies).
- **Pregnancy** (decreased fibrinolysis; fatty liver).
- **Anaphylactic shock**
- **Ionizing radiation.**

All these conditions cause increased fat accumulation.



Increased intraosseous pressure in head of femur.



Inability to vascularize head of femur.



AVN of head of femur.

Clinical presentation :

- Young individuals, males > females.
- Insidious onset. No h/o trauma.
- 50% are bilateral.
- Steroid use leads to 80% cases having a bilateral presentation.
- Painful limp called **antalgic gait**.
- Groin/hip/knee pain.
- Complains of inability to squat, sit down or crosslegged.

60c6b3eeaa8ded0e4e7e5ea7

Range of movement of hip reduced : **Internal rotation** > Abduction.

Also seen in congenital coxa vara, Perthe's disease, SCFE.

- **Sectoral sign** : Limitation of internal rotation of a flexed hip. Hip goes into obligatory external rotation.

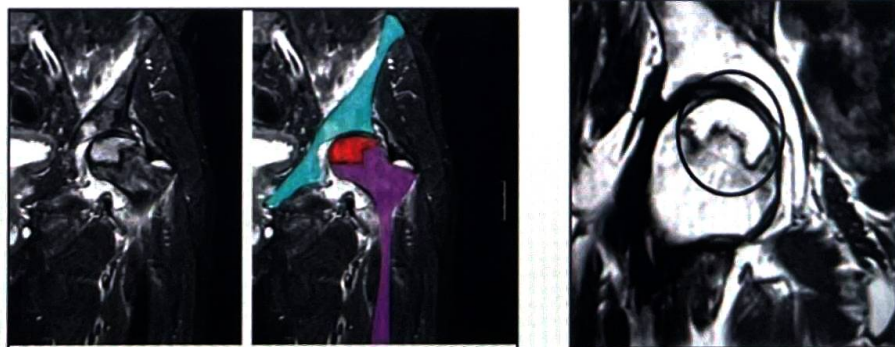
Investigations :

IOC → **MRI**.

Bone scan : **Donut sign**

The avascular part does not take up the radionuclide whereas the surrounding vascular areas takes it up. Hence the appearance of a donut.

MRI showing AVN of head of femur :



Active space

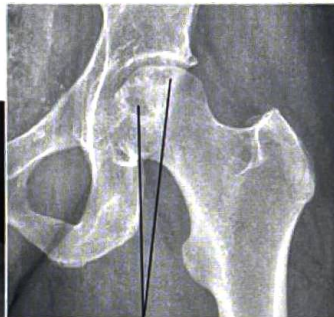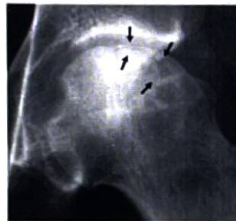
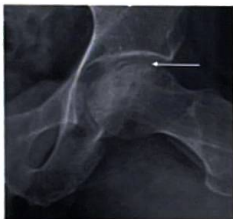X-ray findings : Takes weeks to months to show changes.

- Deformed head.
- Sclerosis.
- Increased density.
- Presence of cyst.

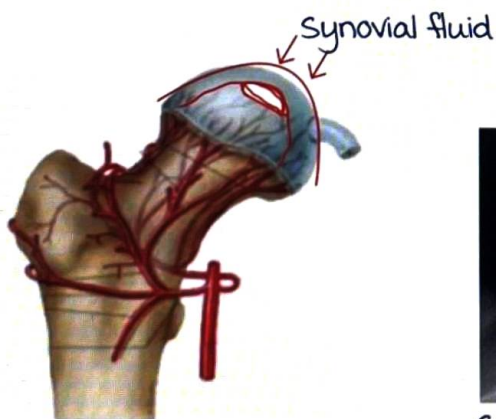
Crescent sign : Subchondral collapse of head of femur under the cartilage in form of a crescent while its sphericity is maintained.

Articular cartilage receives nutrition from synovial fluid. Bone receives nutrition from its blood supply. A watershed area exists between them which receives relatively poor nutrition. This area eventually weakens, undergoes necrosis and collapses under the articular cartilage in the shape of a crescent.

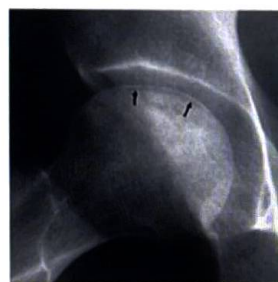
Crescent sign



Subchondral cysts



Watershed area
necrosis



Subchondral
collapse of head of
femur

Reason for restriction of movement : Due to loss of shape and sphericity of necrosed femoral head.

Management of AVN

00:36:32

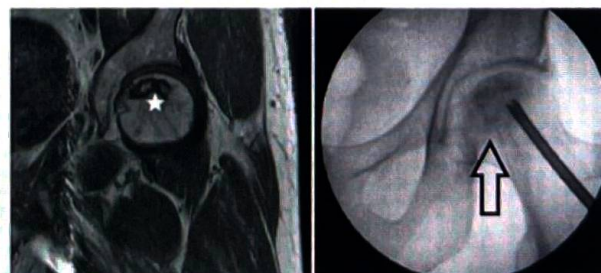
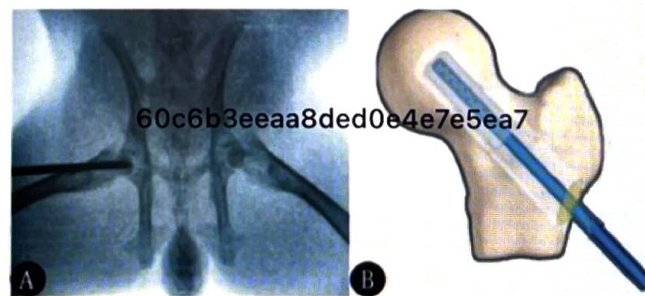
Treatment based on Ficat & Arlet classification :

Stage	Findings	management	method
I	Xray normal, MRI +ve	Conservative	Bisphosphonates
IIA	Xray : Sclerosis, Cysts, No collapse	Conservative	Bisphosphonates
IIb	Xray : Crescent Sign, No Collapse	Surgical Decompression	Core Decompression
III	Collapse + Loss of sphericity	Surgical	Osteotomy
IV	Advanced Arthritis	Reconstructive	Total Hip Replacement

Bisphosphonates are used to prevent resorption of necrosed bone.

Core decompression :

Necrosed area identified under MRI → Under fluoroscope or C-arm guidance, a hole is drilled in the necrosed area → Pressure reduces → Vascularity returns.



Active space

Sphericity maintained, crescent sign present : Perform Core decompression.

Collapse present, change/rotate the shape of head of femur that is coming in contact with acetabulum : Osteotomy.

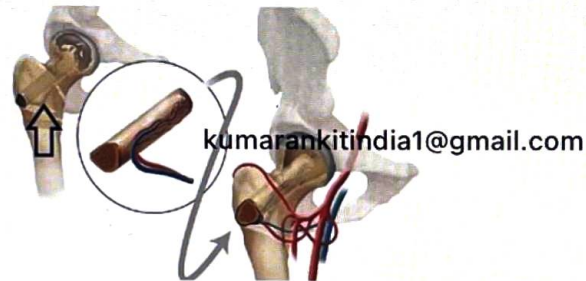
Osteotomy is salvagable procedure

Completely deformed head, sphericity lost : Perform total hip replacement.

Fibular vascular grafting (after core decompression) :

Anastomosis of fibular vessels with vessels around hip joint.

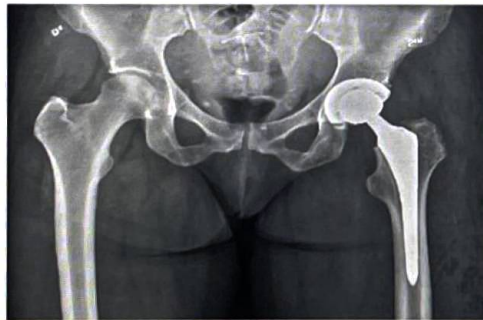Insert fibula into the hole drilled.



Total hip replacement :

Necrosed head is removed and replaced by metallic head.

Acetabulum is also removed (damaged by osteoarthritis) and replaced by metallic cup.



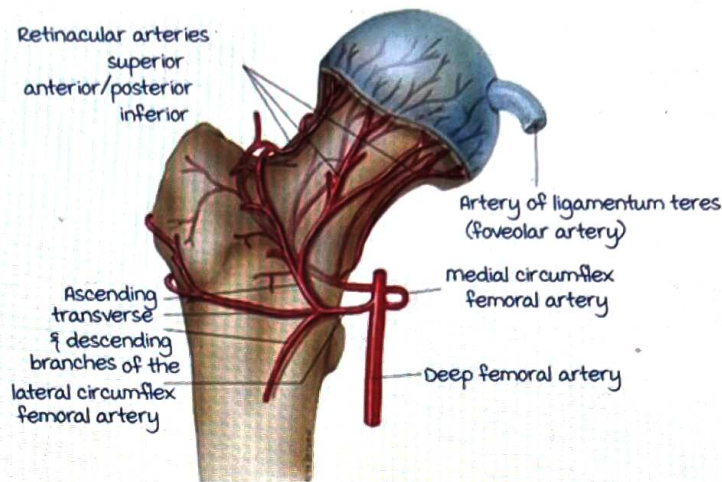
Perthe's disease

00:44:20

- Idiopathic, spontaneous osteonecrosis in children.
- Osteochondritis of femoral epiphysis.
- Coxa plana.
- AKA Legg Calve Perthe's disease.

Active space

Blood supply to head of femur :

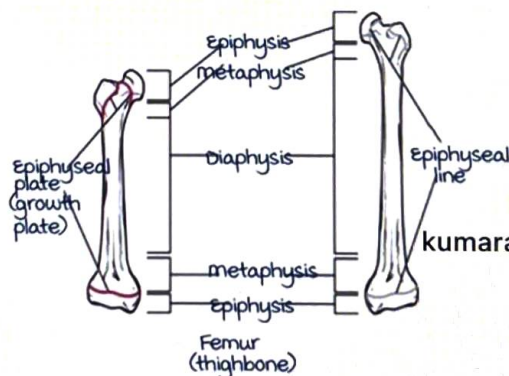


Pathology :

Head of femur receives blood supply from foveolar source and metaphyseal source.

- < 4 years → Predominantly from foveolar source.
- > 10 years → Predominantly from metaphyseal source.
- 4-10 years → **Bridge phase** where nutrition supply transitions from foveolar to metaphyseal source.

During the bridge phase, any injury, trauma or unknown cause can lead to avascular necrosis of femur.



(a) Growing long bone (b) mature long bone

kumarankitindia1@gmail.com

Features :

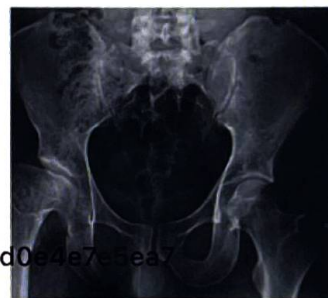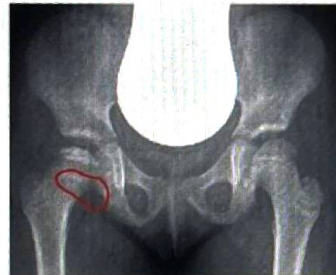- most common cause : **Idiopathic**.
- most common association : **Protein S deficiency**.
- males > Females.
- Age : 4 to 10 years
- 10-12% bilateral.
- < 6 years of age : Good prognosis
- > 6 years of age : Poor prognosis

Clinical presentation :

- Painless limp, can be painful later.
- Pain radiates to knee or groin.
- **Loss of abduction & internal rotation** : Cannot sit crossed leg or squat (other conditions → Chandler's disease AVN head of femur, congenital coxa vara, SCFE).
- Caffey Sign (obligatory external rotation on flexion).
- X-ray shows changes weeks to months later & **MRI (IOC)**. CT or USG is not required.

X ray features :

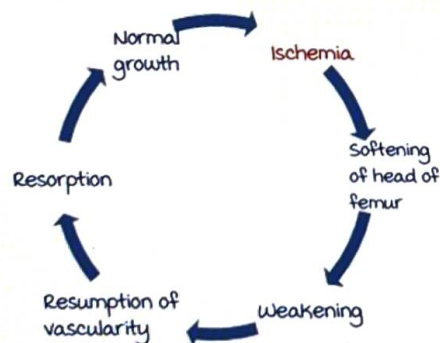
- mushroom shaped flattening of head
- **Gages sign** : metaphyseal cyst (poor prognosis)
- Lateral calcification.
- **Sagging rope sign** : Sclerotic line on neck of femur.



60c6b3eaa8ded0b467c5ea

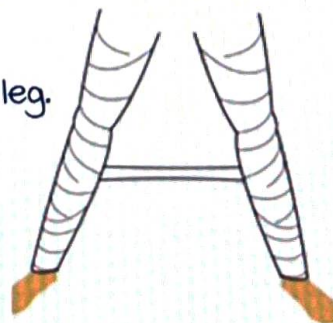
management :

Aim of treatment : **Sustain the head till the vascularity resumes.**



Prevent head of femur destruction by :

- Skin traction.
- Non-weight bearing on affected leg.
- **Petrie cast/Broom stick cast** : Keeps limb in abduction and internal rotation that keeps the vulnerable part of head away from the load.
- Osteotomy : Varus de-rotation osteotomy of femur.
- Total hip replacement only after skeletal maturity.



Active space

Q. In elbow, osteochondritis usually involves?

- A. Olecranon.
- B. Trochlea.
- C. Radial head.
- D. Capitulum.

Q. Osteonecrosis is not seen in?

- A. Ollier's disease
- B. Kienboch's disease (osteochondritis of lunate).
- C. Kohler's disease (osteochondritis of navicular bone).
- D. Perthe's disease (osteochondritis of femoral epiphysis/
head of femur).

Ollier's disease : multiple enchondromas.

Q. A 40yr old body builder taking steroids and creatinine presented with bilateral hip pain and unable to squat. On MRI there is marrow edema, subchondral cyst, flattening of weight bearing areas of femoral head & X-ray shows Crescent Sign. What is the likely diagnosis?

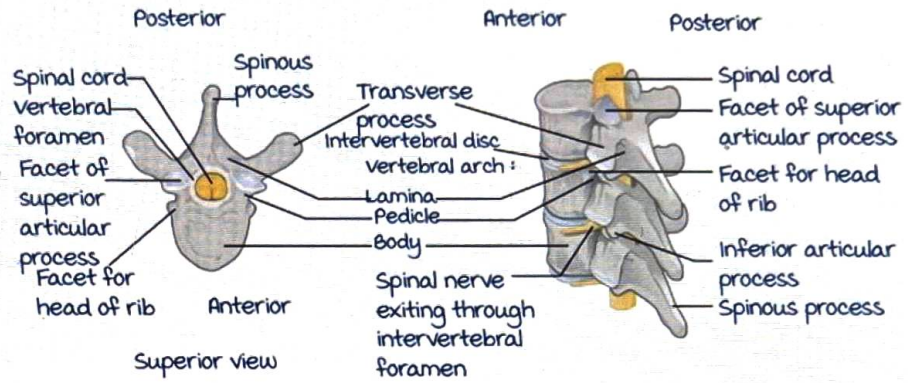
- A. AVN femur.
- B. Fracture femur.
- C. Osteochondroma.
- D. TB Hip.

60c6b3eaa8ded0e4e7e5ea7

Active space

SPINE : PART 1

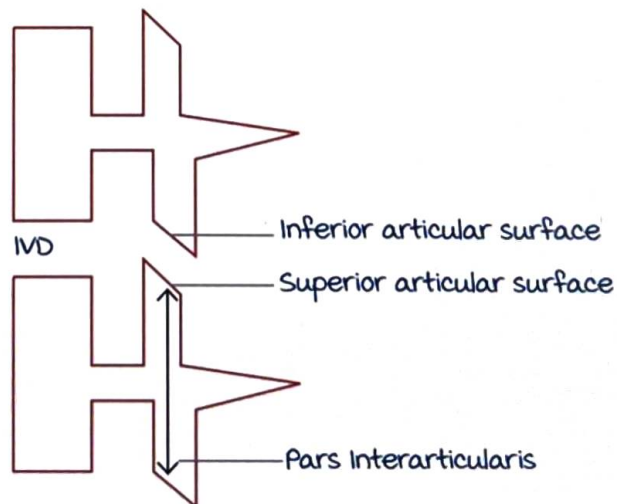
Anatomy of Vertebrae



Left posterolateral view of articulated vertebrae

60c6b3eaa8ded0e4e7e5ea7

vertebral column is the bony part of the spine.
 Spinal cord is the neurological element of the spine.
 vertebral fractures and spinal cord injuries may occur independent of one another.



Active space

The inferior articular facet of one vertebra articulates with the superior articular facet of the vertebra immediately below it.

Alignment of the vertebrae is maintained by Pars interarticularis.

Pars interarticularis : The part between the two articular facets of the same vertebra.

Spondylolysis : Break in the Pars interarticularis

Spondylolysis : Slippage of the vertebra due to an existing break in the Pars interarticularis.

Intervertebral disc (IVD) is the space between two vertebrae and it's given the name corresponding to the two vertebrae it's sandwiched between.

Example : The IVD between T_1 and T_2 is called the T_1/T_2 IVD.

IVD allow scope for movement of spine and also act as shock absorbers.

Cervical spine is the most mobile part of the spine.

Spinal Trauma

00:05:52

Stable vs. Unstable Spine

Denis 3 - columns concept of stability.

Spine is divided into 3 columns namely anterior, middle and posterior.

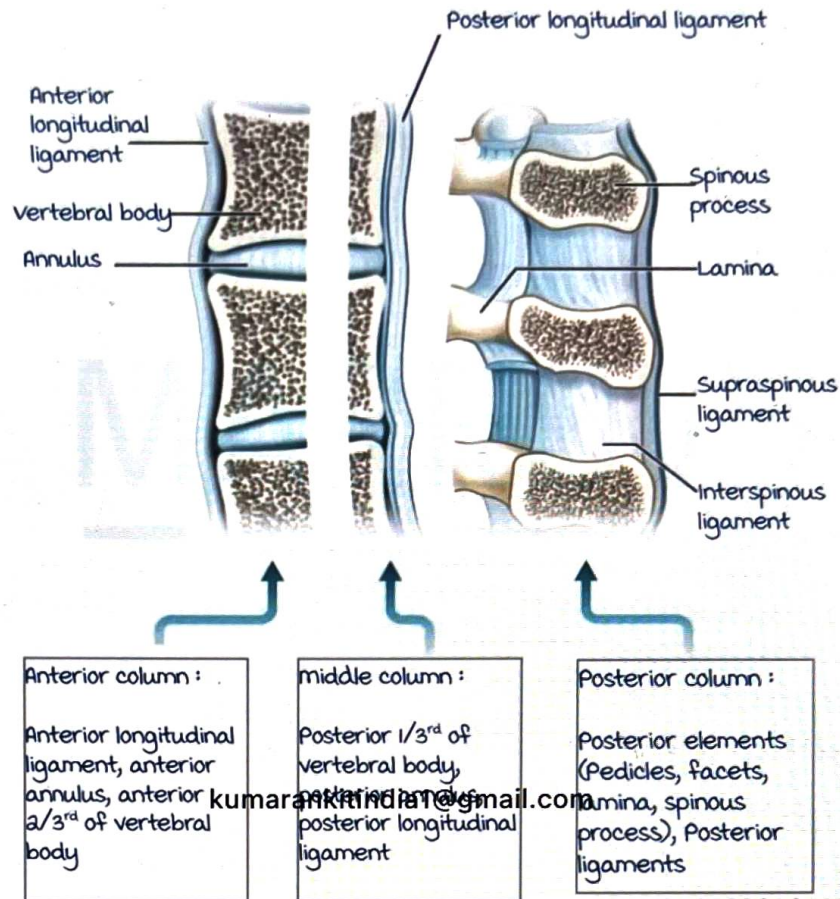
If the injury involves only to two columns, it's considered 'Stable'.

If all three columns are affected it is deemed 'Unstable'.

Stable injuries can be managed conservatively while the unstable injuries require decompression and stabilization.

Active space

Denis Classification of structural elements of the spine



movements of the Spine : Flexion, extension, lateral flexion, rotation.

mechanisms of injury of spine : Flexion, extension, lateral flexion, rotation, translation, compression, distraction or a combination of some or (unfortunately) all of the above.
 Compression force → Axial loading of spine → Burst fracture.

most common (MC) mode of Injury : Fall from height (DIA).

MC mode of injury in developed countries : Road traffic accident (RTA).

MC mechanism of injury : Flexion > Flexion with rotation.

most dangerous mechanism of injury : Translation (Two adjacent vertebrae freely move away from each other due to an underlying fracture)

MC site of :

Fracture : Lower thoracic DIA

Dislocation : Cervical spine (Dislocation without fracture)

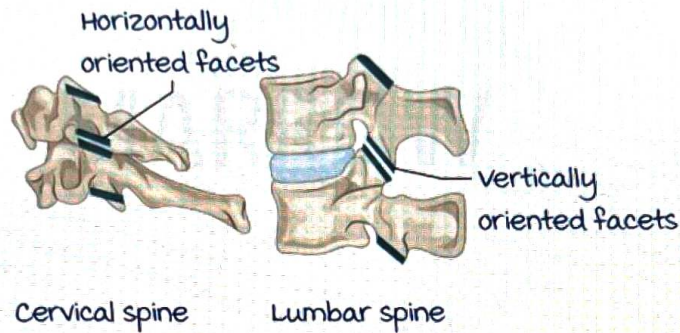
Spinal cord Injury (DCI) : Cervical spine (thickest part of cord)

Reasons for cervical spine being more prone to fractures :

Interarticular facets oriented in a more horizontal plane

giving them more scope to slip over one another.

The stability is more due to the ligaments than the bony structures and hence injuries involving dislocations without fractures are also more common here.



Jefferson's fracture

00:14:08

C1 : Atlas (ring-shaped) ; Allows turning of the head.

Mechanism : Axial Loading, compression force.

Fragments burst away ; No neurological deficit.

X-ray : Open mouth view ; Usually insufficient.

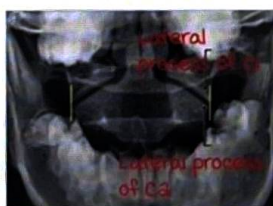
CT scan required.

Management : Conservative as it is usually stable.

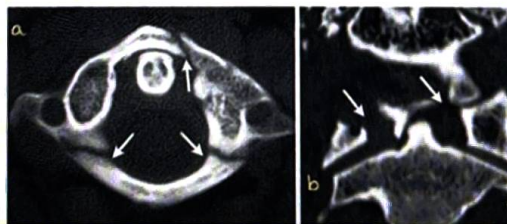
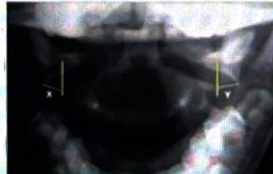
Surgical : Atlanto-occipital fusion.

Jefferson's fracture - Rule of Spence

Normal



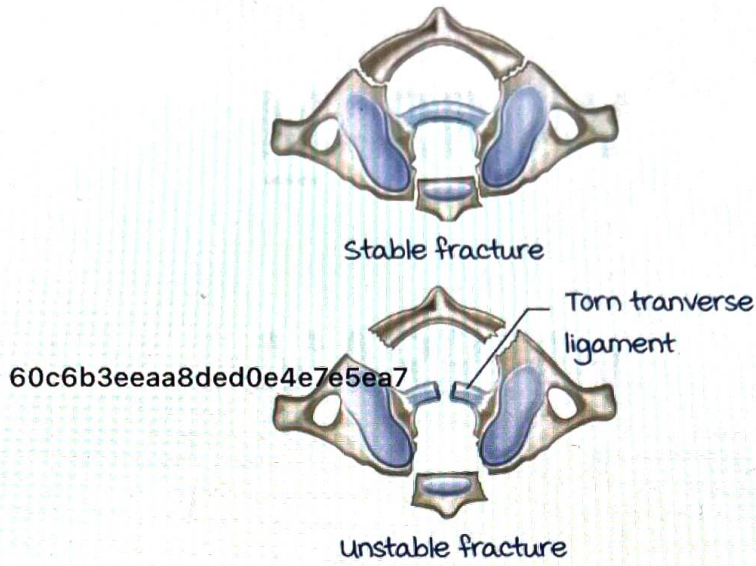
unstable Jefferson's fracture



Rule of Spence : $x+y >$

69mm suggests transverse ligament rupture (unstable fracture of atlas)


Jefferson's fracture : Superior view of the atlas



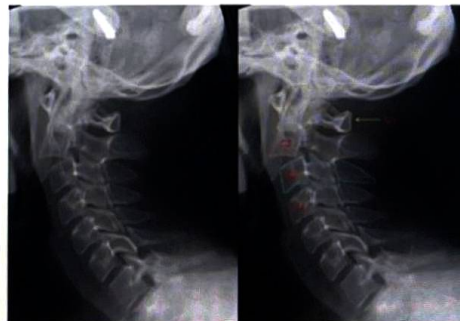
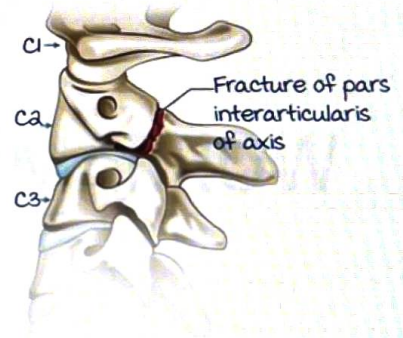
Hangman's fracture

00:16:21

Hangman's fracture



Hangman Fracture



Active space

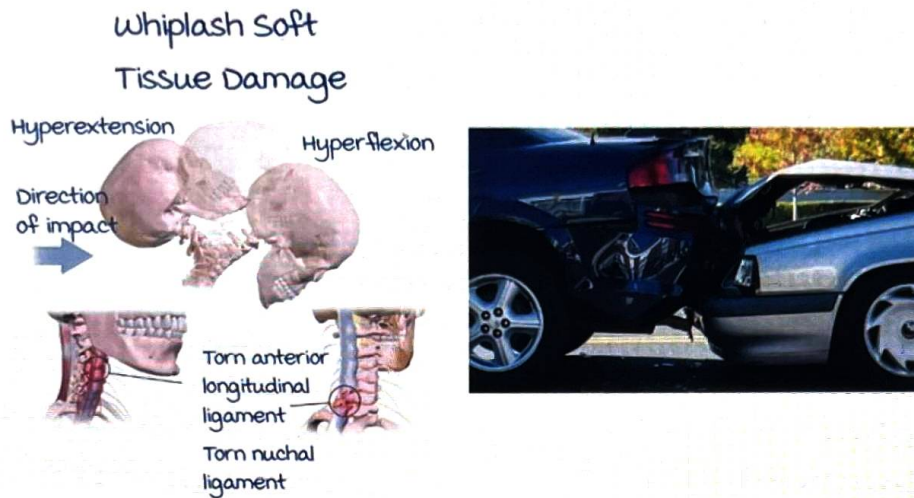
Fracture dislocation of C2 over C3 involved Spondylolysis (Pars interarticularis fracture).
No neurological Deficit.
MC mechanism of injury : RTA.

Levine & Edwards Classification.

MC fracture of C2 is **odontoid fracture**, not Hangman's.

Whiplash Injury

00:18:42



Not a fracture.

In cars without head rest.

Mechanism of injury : Hyperextension due to impact from the back.

Stretch of anterior longitudinal ligament.

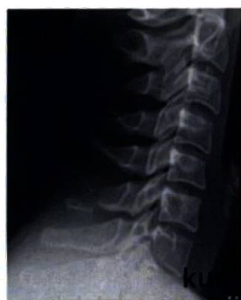No neurological deficit, only chronic neck pain.

X-Ray and CT Scan : Normal.

management : Cervical collar if required.

Clay Shoveler's Fracture

00:20:57



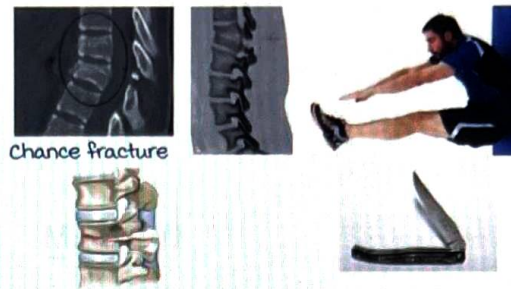arankitindia1@gmail.com

Force of the upper limb muscles while shoveling leads to avulsion of spinous process.

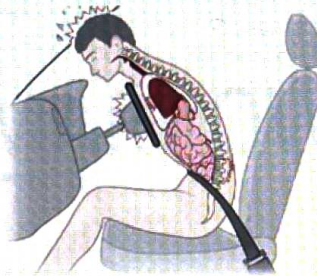
Active space

Chance Fracture

00:22:43



mechanism of Jack-knife fracture



Coined by GQ chance.

Also known as Jack-Knife fracture.

Head on collision.

Seat belts without shoulder harness.

Flexion & distraction force.

Disruption from posterior elements to forward.

Anterior compression/ Posterior compression.

Bony or soft tissue chance.

Unstable fracture and hence decompression & stabilization.

Screws inserted into the pedicle of the spine.

Spinal Cord Injury Without Radiological Abnormality (SCIWORA)

00:26:01

Occurs in children less than (7-8) years as their bones are more flexible.

Bone more elastic compared to the spinal cord.

Neural injury occurs without any bony injury.

No injury on X ray or CT scan. [60c6b3eaa8ded0e4e7e5ea7](#)

Diagnosis made on MRI.

Spinal Cord Injury

00:27:37

Spinal shock lasts (24 - 48) hours after injury.

Immediately after : All reflexes are lost; The patient cannot be tested in this phase.

After this phase passes, the spinal cord tries to revert back to its original state, but the presentation is that of the injury it sustained (Upper motor Neuron/ Lower motor Neuron).

Reflexes, sensations, motor activity.

Bulbocavernosus Reflex

00:29:29

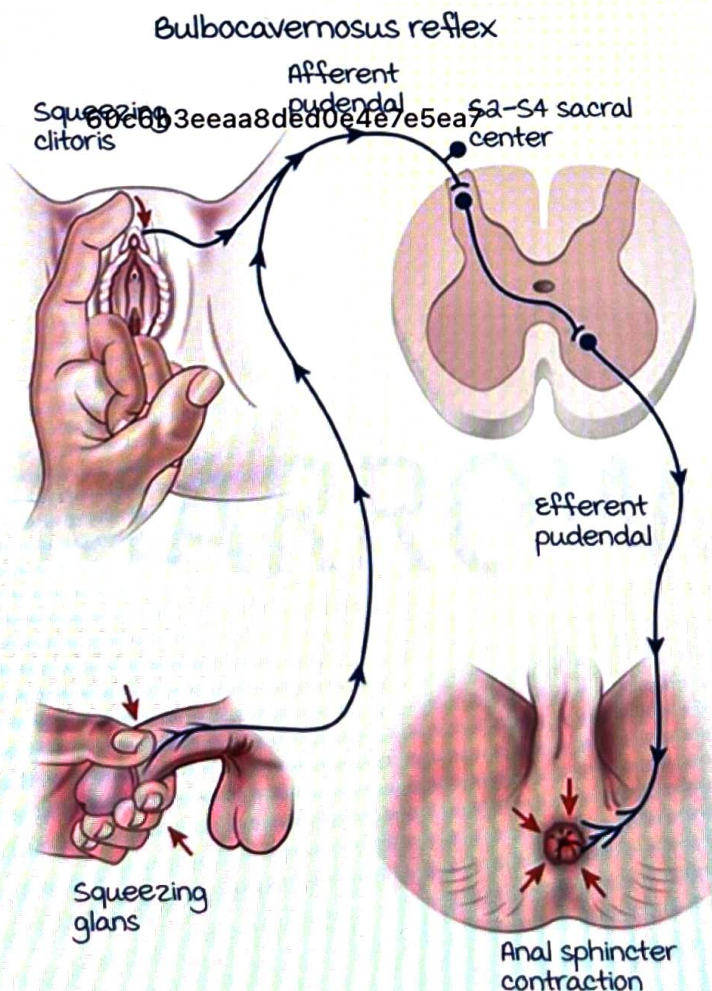
Primitive reflex

marks the end of the spinal shock.

Root value : S2, S3, S4

method : Compress Glans/ Clitoris.

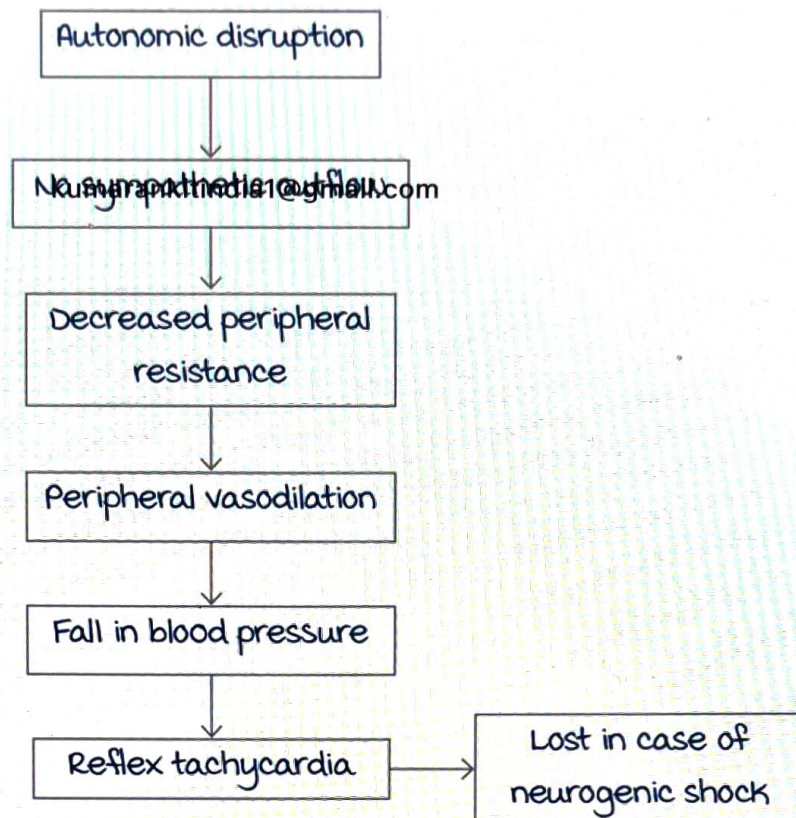
Tug on the Foley's catheter if present.



Active space

Neurogenic shock

00:31:02



Hypotension with bradycardia/without tachycardia.

Management of Spinal Cord Injury

00:32:48

ATLS protocol, Logroll method etc.

To prevent neurological manifestations :

ATLS : No role of steroids in an acute spinal cord injury.

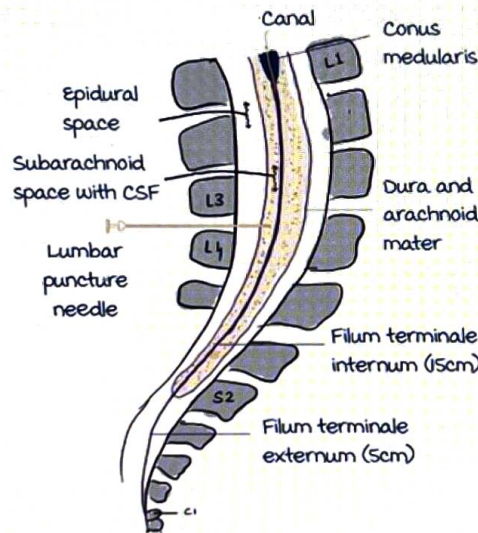
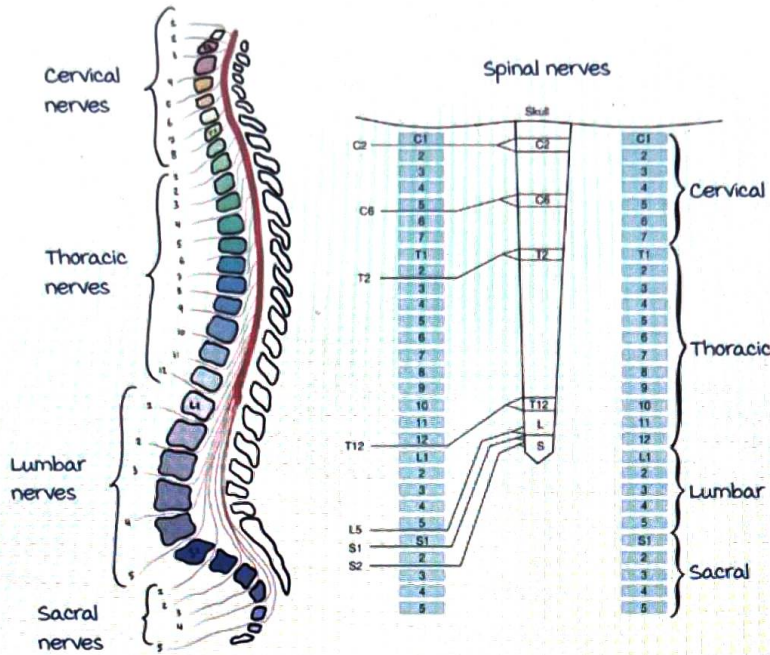
NASCIS III : Steroid use if presents within 6 hours of injury.

30 mg/kg IV methyl prednisone : Bolus.

5.4 mg/kg/hr IV continuous infusion for 24-48 hours. No benefit after 8 hours of injury.

Localization of Spinal Injury

00:35:40



Extent : medulla to lower border of L1 in adults.

Bulges : Brachial Plexus, Lumbosacral bulge.

Conus medularis : Conical shaped end of spinal cord behind lower border of L1.

Cauda Equina : Horse's tail ; Tuft of spinal nerves below the conus behind L2 and below.

Vertebral segments and nerves

Vertebrae	Segments	Nerves
Cervical	7	8
Thoracic	12	12
Lumbar	5	5
Sacral	5	5

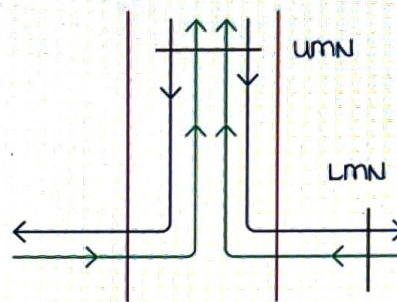
Active space

Spinal Nerves : Exit at their respective segments below the pedicle ; But the spinal cord ends at L1.
 Any injury of spinal column above L1 : Spinal cord injury.
 Any injury of spinal column below L1 : Spinal nerve injury

Spinal Cord Injury vs. Spinal Nerve Injury

00:39:43

Essentially, UMN vs. LMN injury.
 Injury below the level of L1 presents with LMN features.



UMN vs LMN

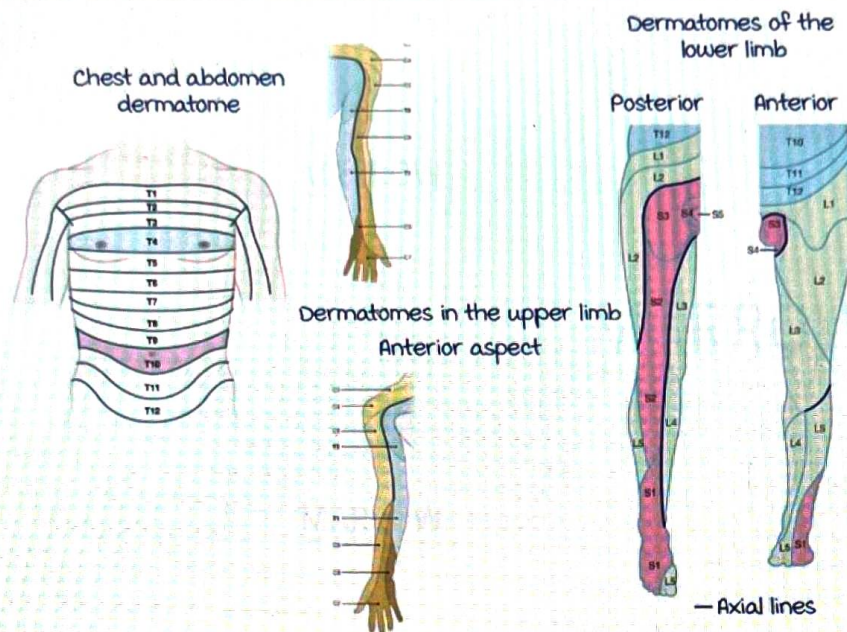
UMN	LMN
At the level of injury (Spinal cord)	At the level of injury (Spinal nerve)
<ul style="list-style-type: none"> • Sensory loss • motor weakness : Flaccid paralysis • Areflexia 	<ul style="list-style-type: none"> • Sensory loss • motor weakness : Flaccid paralysis • Areflexia
Below the level of injury	Below the level of injury
<ul style="list-style-type: none"> • Sensory loss • motor weakness : Spastic paralysis • Exaggerated reflexes 	<ul style="list-style-type: none"> • No sensory loss • No motor weakness • Normal reflexes

60c6b3eeaa8ded0e4e7e5e7

Active space

Dermatomes

00:46:49



Cutaneous sensory supply of the spinal nerves.

Quick cues :

Behind the head : C2

Behind the neck : C3

Thumb : C6 ; Index and middle fingers : C7 ; Ring and little fingers : C8

Below the nipple : T4

medial malleolus : L4 ; Dorsum of the foot : L5

Lateral malleolus : S1

Myotomes

00:49:32

A group of muscles supplied by the same spinal nerve to perform a particular movement.

Quick cues :

For upper limb : First pull everything towards yourself and then push them away/shooting a basketball.

For lower limb : First pull everything towards yourself and then push them away/kicking the door shut.

Active space

Root	myotome
C5	Elbow flexion
C6	Wrist extension
C7	Elbow extension / wrist flexion
C8	Finger flexion
T1	Finger abduction
L2	Hip flexion / iliopsoas
L3	Knee extension / Quadriceps
L4	Ankle dorsiflexors / Tibialis anterior
L5	Extensor hallucis longus / Hip abductors
S1	Gastro Soleus / Ankle plantar flexors

Reflexes

00:51:43

Reflexes :

Root	Reflex
C5	Biceps
C6	Supinator (Brachioradialis)
C7	Triceps
L3 L4	Knee (Quadriceps)
S1	Ankle (Gastro Soleus)

kumarankitindia1@gmail.com

SPINE : PART 2

Prolapsed intervertebral disc/PIVD

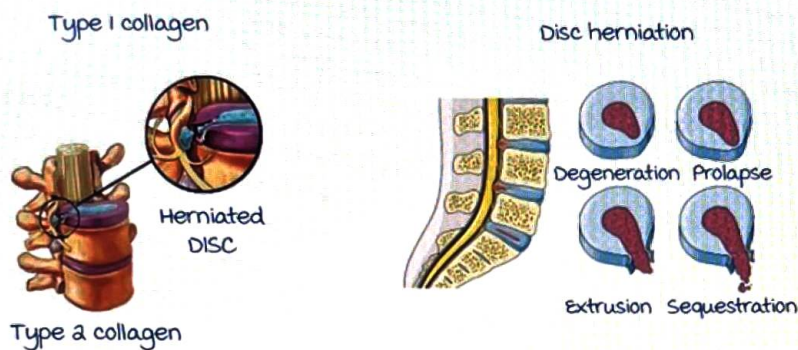
00:00:18

60c6b3eaa8ded0e4e7e5ea7

Etiology : Due to degeneration or abnormal loading of the spine.

Disc bulges out posteriorly & compress neural elements.

m/c location : L4-L5 > L5-S1 (compress the spinal nerves).

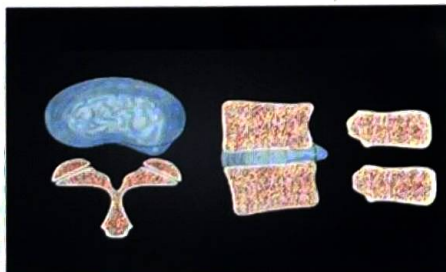


Predisposing factors : untrained young adult lifting heavy weight (e.g in gym) or sitting & bending forward for long duration (abnormal loading of spine).

Clinical features :

Classical sciatica : Pain starts radiating from back to limbs.
most common cause of sciatica is PIVD.

Clinical examination : To localize the level of the lesion by testing dermatomes, myotomes and reflexes.



Disc protrusion
<25% of disc circumference, base
wider than herniation

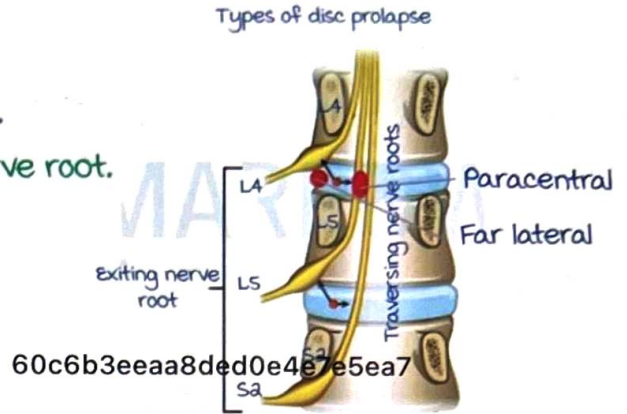
Two types of nerve roots associated with a disc.

For e.g. In case of disc L4, exiting nerve root L4 & traversing nerve root L5 are the associated nerve roots.

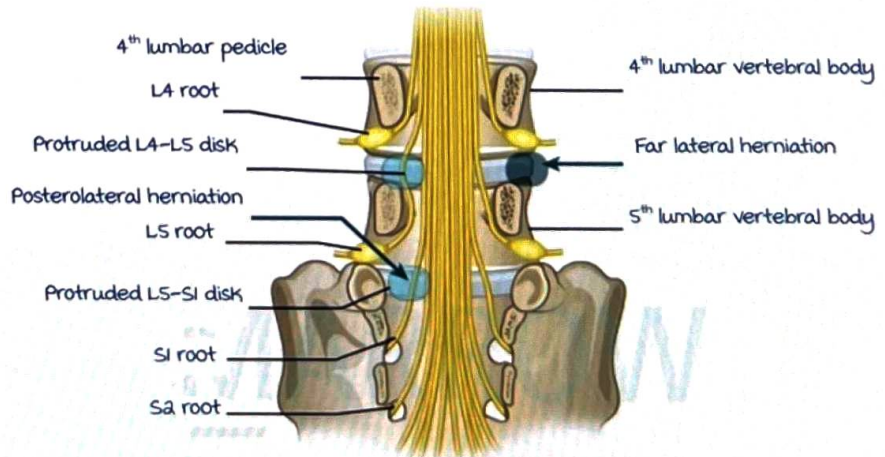
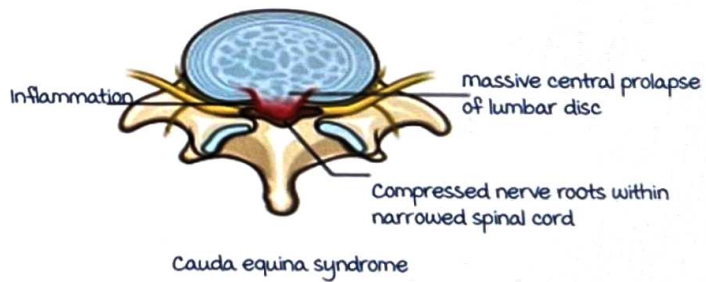
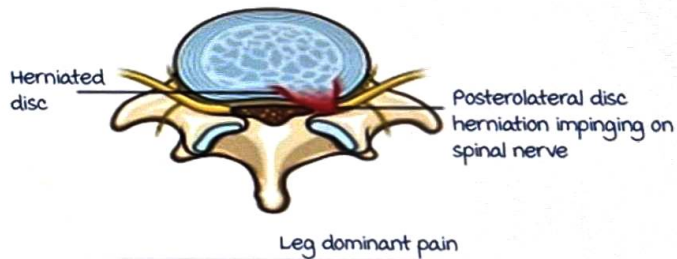
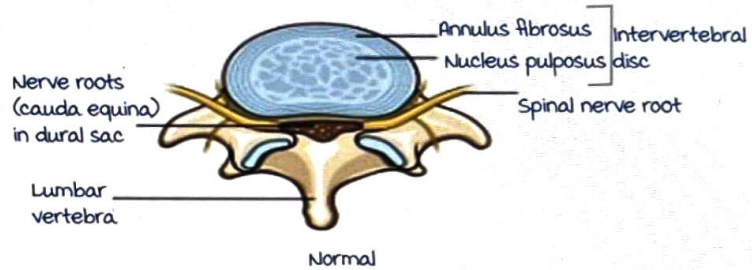
Active space

Types of disc prolapse :

- 1) Paracentral : Compress transversing nerve root.
L4-L5 compress L5 nerve root.
- 2) Far lateral : Compress exiting nerve root.
- 3) Central.



There will LMN type of palsy.
 Loss of sensation present at corresponding dermatome.
 Flaccid paralysis at corresponding myotome.
 Corresponding reflex will be lost.

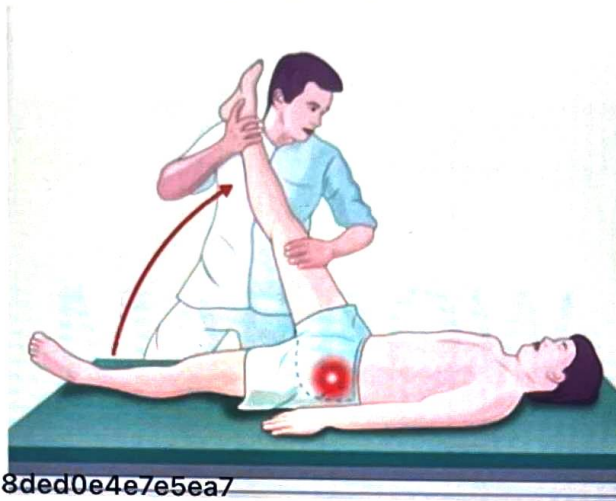


Active space

Diagnosis : Straight leg raising test.

Straight Leg Raising Test (SLRT) or Lasegue sign

Straight Leg Raising Test



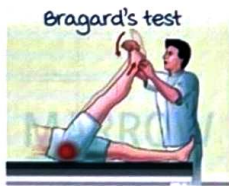60c6b3eeaa8dad0e4e7e5ea7

Flexing hip beyond a particular point causes pain.

Other tests :

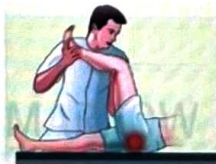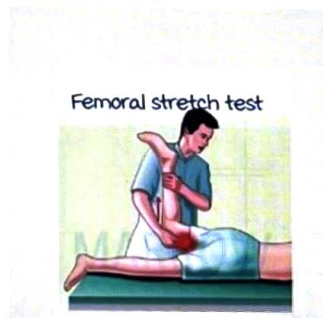
2. Bragard test (or Sciatic stretch test or Flip test)

Perform SLRT. At the point where the patient experiences discomfort, the leg is lowered a little. The stretching and pain become less. At this angle, the ankle is passively dorsiflexed. If the pain at the back of the thigh or in the calf is felt again, the test is positive. This is also called reinforcement positive or Bragard's sign positive.



3. Femoral stretch (reverse Lasegue test or mackiewicz sign)

The patient lies prone. The examiner flexes the knee to the thigh and the hip is passively extended. The test is positive if the patient experiences anterior thigh pain. This test is usually positive for L2-L3 and L3-L4 (high lumbar) protrusions.

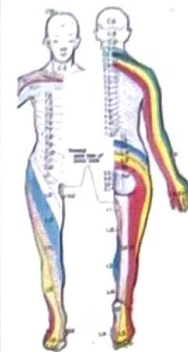


4. Bowstringing sign (or popliteal compression test)
The bowstringing sign is even more specific for disc prolapse than SLRT. Perform SLRT until the patient experiences sciatic pain. Without reducing the amount of lift, bend the knee so as to relax the sciatic nerve. Buttock pain is immediately relieved. The examiner then presses the popliteal fossa to stretch the lateral popliteal nerve behind the lateral tibial condyle. This will tighten the nerve like a bowstring and re-induce the pain.

Localization :

Active space

Root	myotome
C5	elbow flex
C6	wrist extension
C7	elbow ext/wrist flex
C8	Finger flex
T1	Finger abduction
L2	Hip flex / iliopsoas
L3	knee ext/ quadriceps
L4	Ankle dorsiflexors / tibialis anterior
L5	Extensor hallucis longus / hip abductors
S1	G soleus / ankle plantar flexors



Root	Reflex
C5	Biceps
C6	Supinator (brachioradialis)
C7	Triceps
L3 L4	Knee (quadriceps)
S1	Ankle (gastro soleus)

1) Patient presents with low backache after weightlifting and paresthesia over medial malleolus. The nerve root involved is L4 and disc likely prolapsed is L3-L4.

2) Weakness in hip flexors : L2 root involved, L1-L2 disc prolapsed.

3) Absent knee jerk : L2-L3/L3-L4 prolapse.

IOC : MRI.

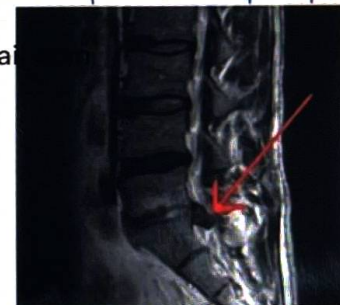Treatment :

Acute : Rest in semi Fowler position (30-40 ° of flexion).

Analgesics, physiotherapy to strengthen back

Disc decompression : Laminectomy, laminotomy, hemilaminectomy and discectomy.

L5-S1 paracentral prolapse



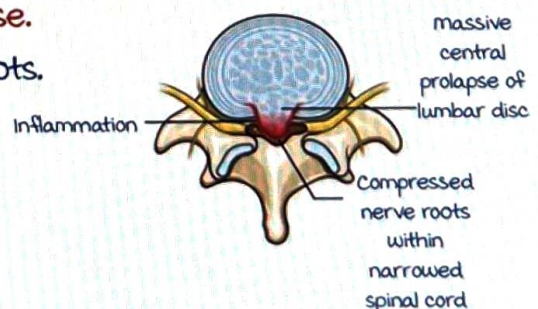
Cauda equina syndrome

00:15:02

massive central disc prolapse.

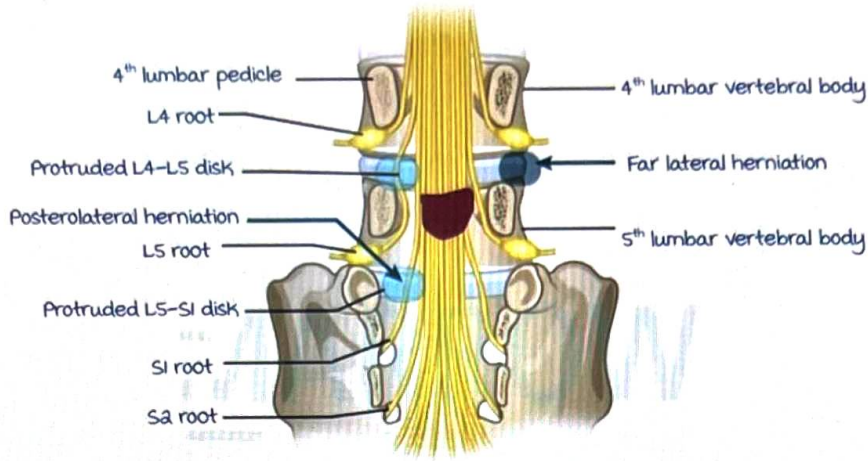
Compress multiple nerve roots.

Only absolute indication of emergency decompression.



Cauda equina syndrome

Active space



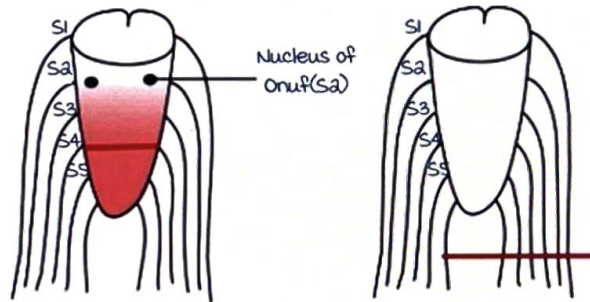
massive prolapse compressing several nerve roots.

Conus medullaris vs Cauda equina syndrome :

Conus medullaris vs Cauda equina syndrome

Conus medullaris syndrome

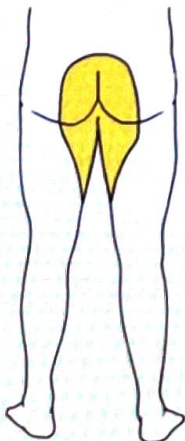
Cauda equina syndrome



Conus medullaris : It is the end conical part of the spinal cord.

If the injuries are around T12 & L1 : Conus medullaris.

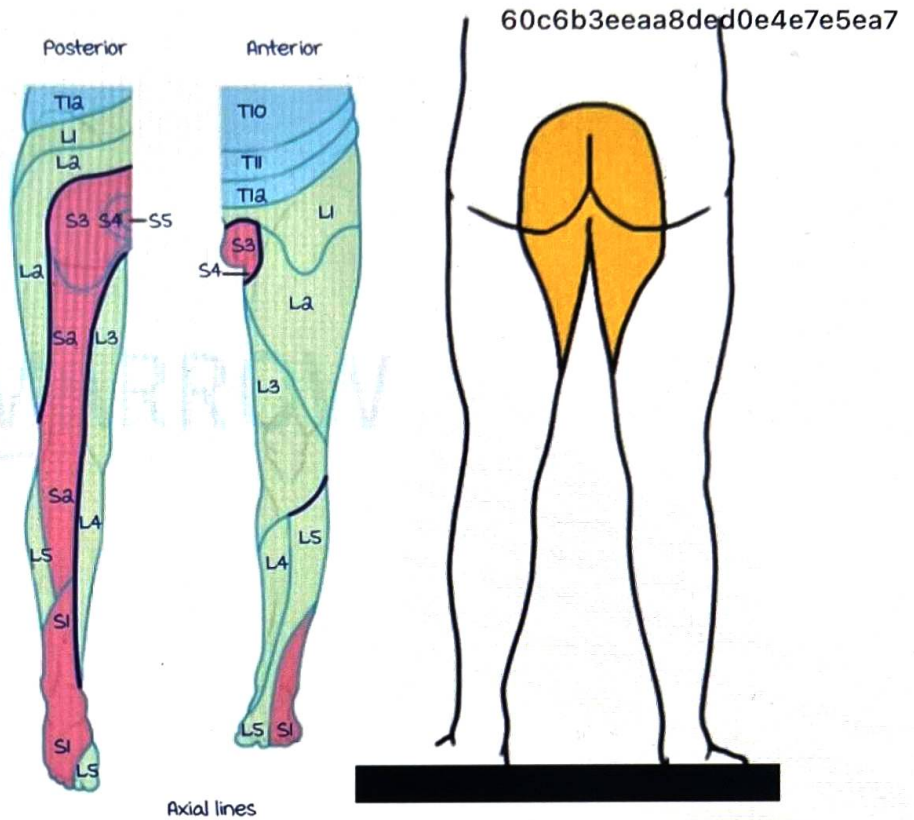
If the injuries are below L1 : Cauda equina syndrome.



kumarankitindia1@gmail.com

Active space

Both the patients present with saddle anaesthesia.



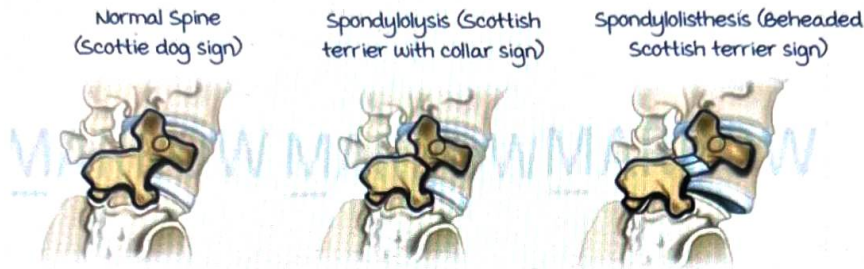
Conus medullaris syndrome	Cauda equina syndrome
Spinal cord lesion	Tuft of nerves involved
Injury at L1	Large disc prolapse below L1
motor : Symmetrical, areflexic, flaccid paralysis. (UMN with LMN features)	MOTOR : Asymmetrical, areflexic, flaccid paralysis.
Saddle anaesthesia	Saddle anaesthesia
Peri anal anaesthesia	
SS involved	Sparing of SS (peri anal sparing)
Knee reflex is normal , only ankle lost	Knee & ankle reflex lost

Active space

Spondylolisthesis

00:20:00

m/c location : L5-S1 (spondylolysis : L5).

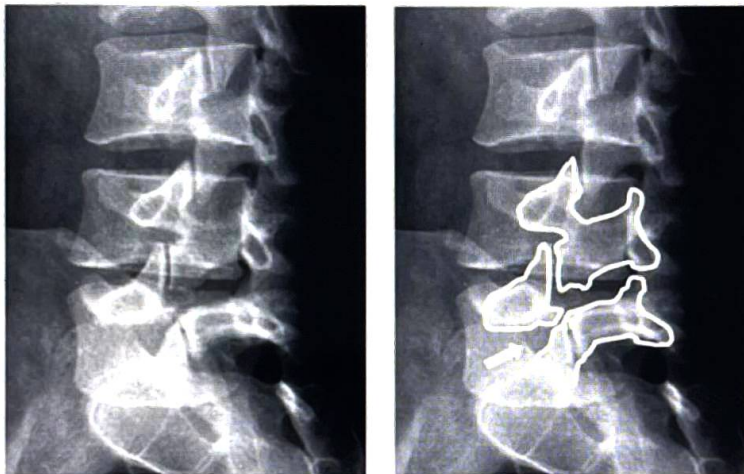


Spondylolysis : Fracture in pars intra-articularis.

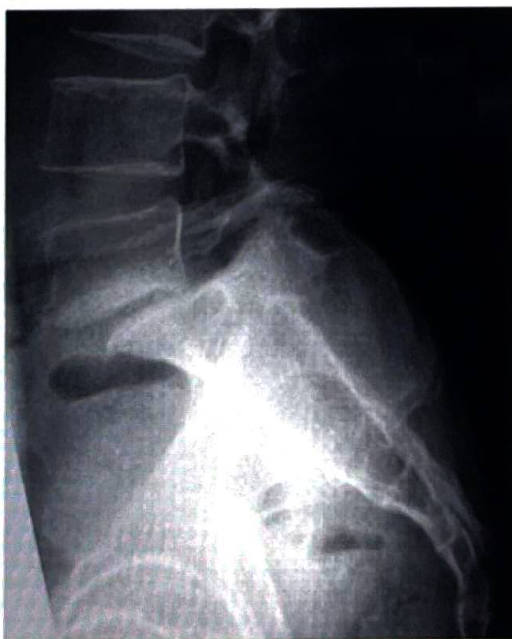Spondylolisthesis : vertebra slips over other.

kumarankitindia1@gmail.com

Best view on X-ray : Oblique view.



meyerding's classification of spondylolisthesis : Based on the amount of slip.



Active space

Grade I : 0 - 25% slip/displacement

Grade II : 25 - 50% slip

Grade III : 51 - 75% slip

Grade IV : 76 - 100% slip

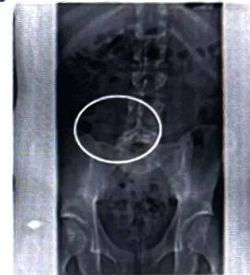
Grade V : 100 % displacement (spondyloptosis).

Clinical features : Backache radiating to lower limbs.

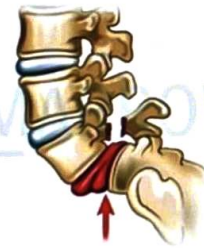
Step sign can be felt on palpation

Inverted napoleon hat sign in AP view

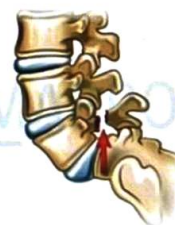60c6b3eaa8ded0e4e7e5ea7



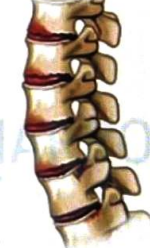Spondylolisthesis



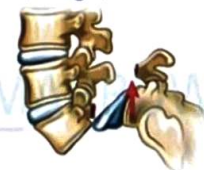Spondylolysis



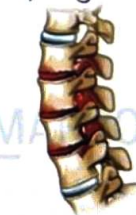Spondylitis



Spondyloptosis



Spondylosis



Spondylosis → Degeneration of spine in elderly patients.

Spondylitis → Inflammation of the spine.

Spondylolisthesis → Slipping of one vertebra over another.

Spondyloptosis → Complete slipping of one vertebra in front of another.

Spondylolysis → Pars interarticularis fracture.

Scoliosis

00:25:22

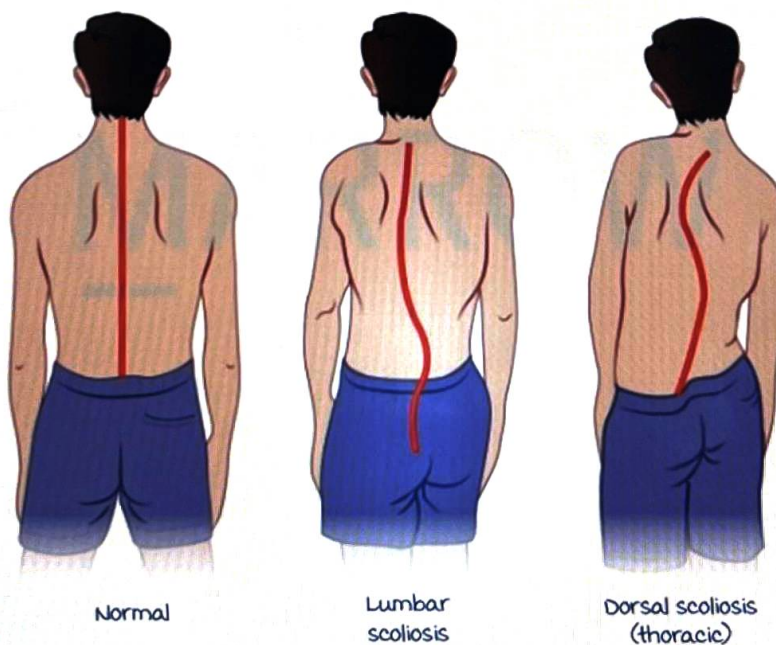
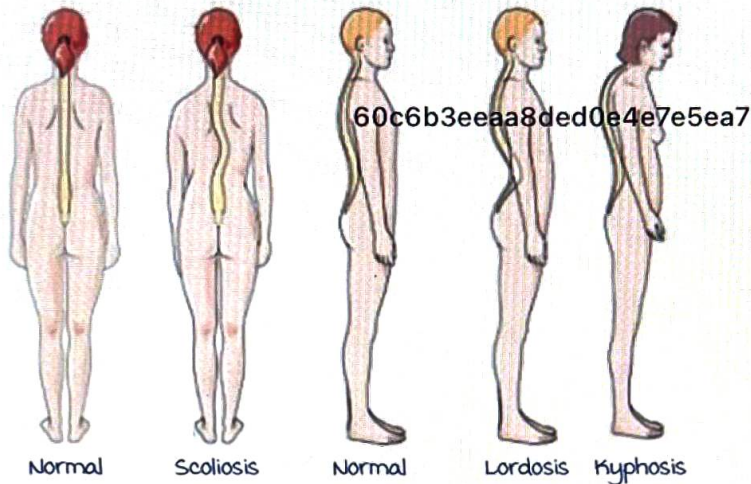
Lateral deviation of spine > 10 degrees from central axis.

Spinal asymmetry \rightarrow Lateral deviation of spine < 10 degrees.

Kyphosis \rightarrow Bending of spine forward.

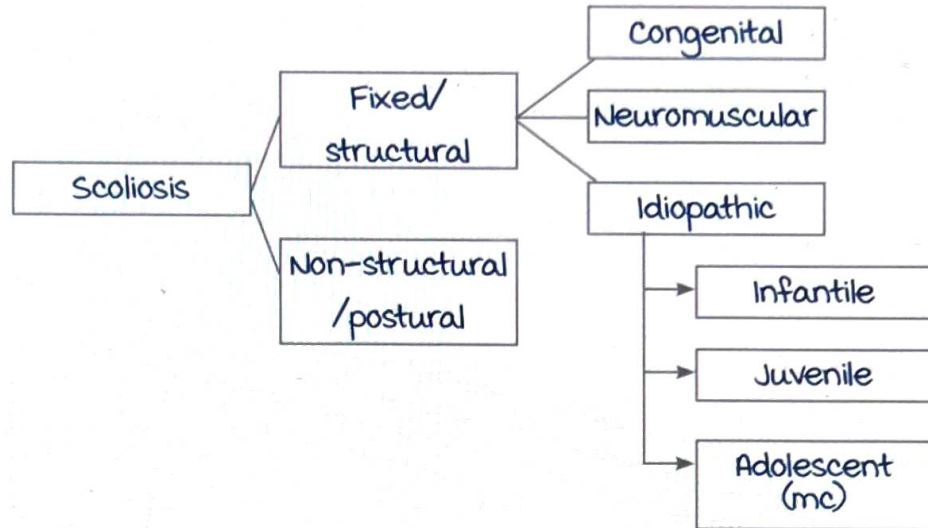
Lordosis \rightarrow Bending of spine backwards.

vertebral column disorders



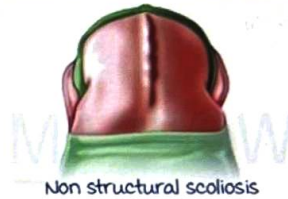Active space

Classification :



To differentiate between two types : Adam forward bending test is done.

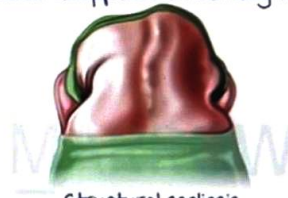Interpretation of Adam's forward bending test



Non structural scoliosis

- Scoliosis disappears on bending forward

Screening test :



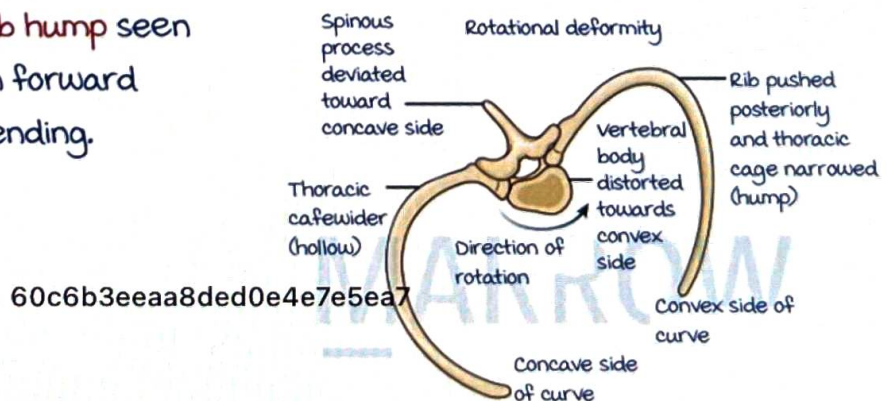
Structural scoliosis

- Scoliosis persists on bending forward

Structural scoliosis : 3-dimensional problem.

- Lateral deviation of spine.
- Exaggerated lordosis.
- Rotational component.

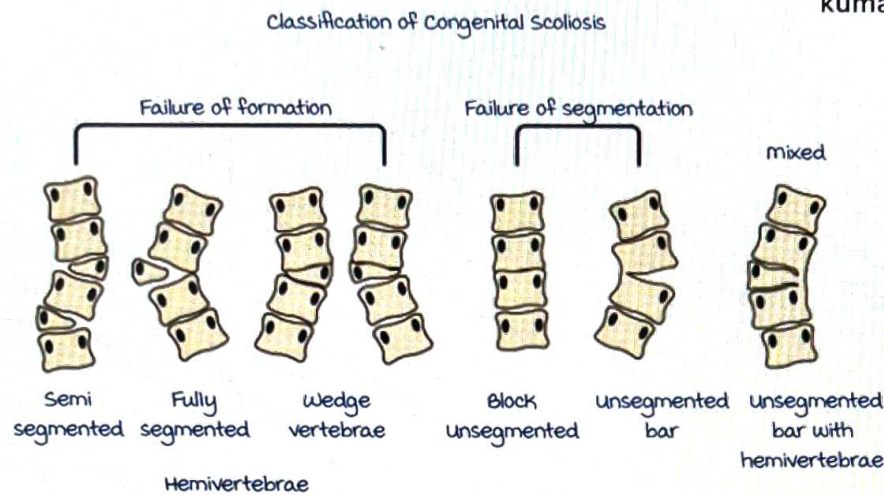
Rib hump seen on forward bending.



Active space

Neuromuscular causes : Cerebral palsy, muscular dystrophies.
 Congenital scoliosis : Congenital anomaly like wedge vertebrae, **hemi vertebrae (m/c)**, unilateral unsegmented bar vertebrae (highest progression), block vertebrae (least progression).

kumarankitindia1@gmail.com



Idiopathic scoliosis : Overall m/c type of scoliosis.

Depending on the age of presentation : Infantile, juvenile, and **adolescent (m/c)**.

Scoliosis : Spinal curves

Clinical features :

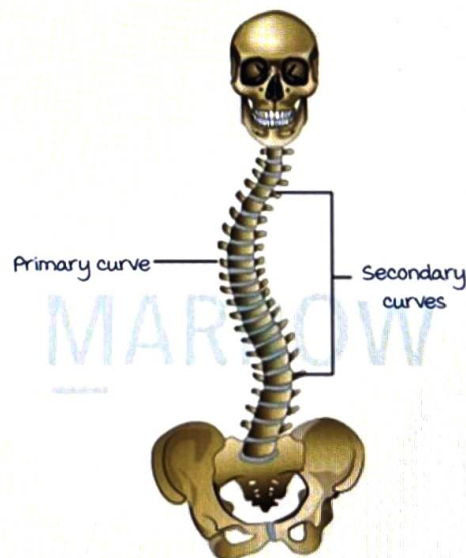
Asymmetry of shoulder.

Lateral deviated spine.

Trunk and arm gap will be asymmetrical.

Rib hump.

Neural/visceral compression symptoms may be seen.



Severity :

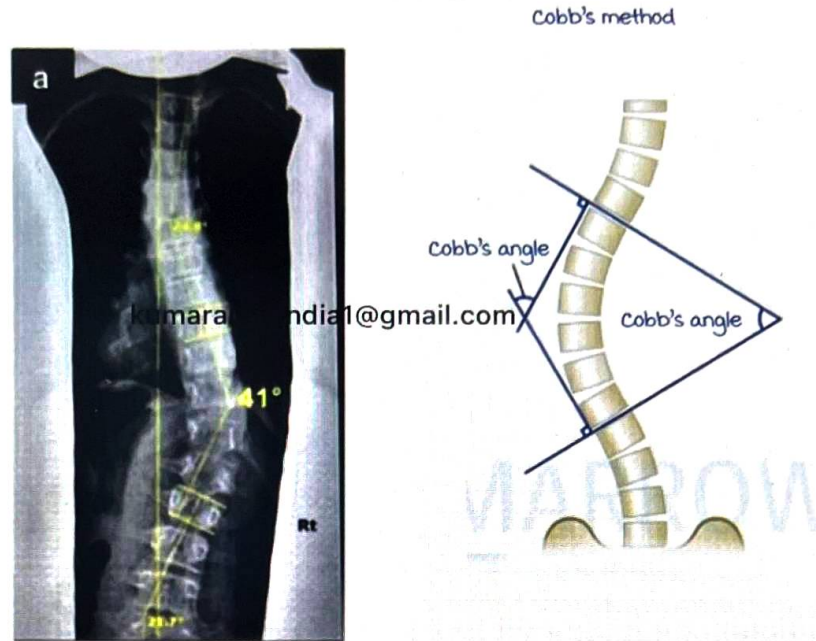
< 10 degrees → Normal.

> 10 degrees → Scoliosis.

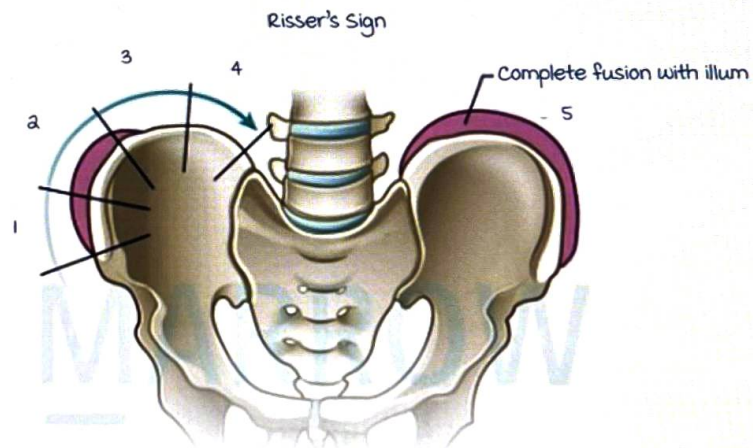
20-30 degrees → mild scoliosis.

> 30 degrees → Severe scoliosis.

Active space



Risser sign → To assess the progression potential.
Based on iliac apophysis ossification & fusion with iliac crest.
more the grade : Less potential for progression.



Risser grade	Description
Grade 1	- Ossification of lateral 25%
Grade 2	- Ossification of lateral 50%
Grade 3	- Ossification of lateral 75%
Grade 4	- Ossification of lateral 100%
Grade 5	- Fusion with the ilium

Treatment :

Conservative → Braces.

Less severity (low Cobbs).

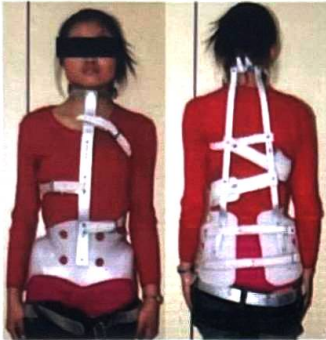Less potential for progression (high Risser).

Surgical correction : High severity.

more potential for progression.

Harrington rods (pedicle screw fixation).

Milwaukee



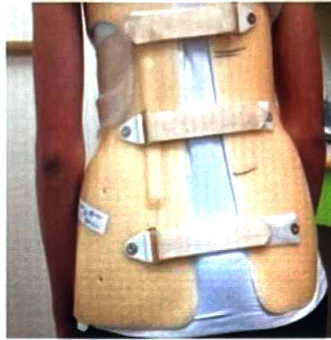High profile brace.
Pelvic mount, anterior &
posterior rods, cervical collar

Charleston eding brace



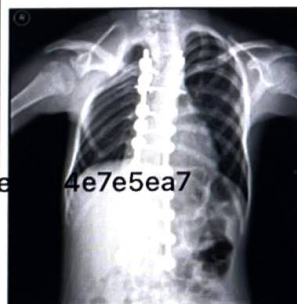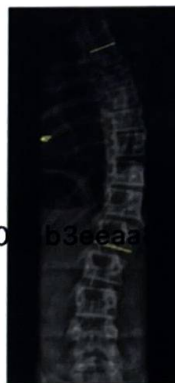Only at night

Boston



Low profile brace.
made of silicon.

Harrington rods (pedicle screw fixation) :



Dislocation without fracture is seen in :

A. Sacral spine.

B. Lumbar spine.

C. Cervical spine.

D. thoracic.

Depends more on ligamentous stability than bony stability.

Articular facets are more horizontal than vertical.

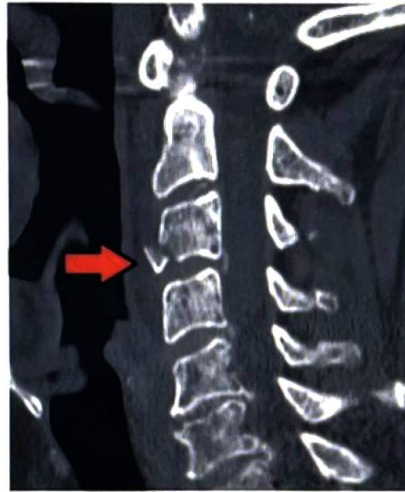Q. Hangman's fracture is :

- A. Subluxation of C5 over C6.
- B. Fracture dislocation of C2.
- C. Fracture dislocation ankle joint.
- D. Fracture of odontoid.

Q. Tear drop fracture of lower cervical spine implies :

- A. Wedge compression fracture.
- B. Axial compression fractures.
- C. Flexion-rotation injury with failure of anterior body.
- D. Flexion compression failure of body.

60c6b3eaa8ded0e4e7e5ea7
Flexion + Compression



Q. Dennis stability concept is based on which of the following?

- A. 2 columns.
- B. 3 columns.
- C. 4 columns.
- D. 5 columns.

Anterior, middle & posterior columns. At least 2 columns are required for spine to be considered unstable injury.

Q. Earliest reflex to reappear after spinal shock :

- A. Knee jerk.
- B. Ankle jerk.
- C. Bulbocavernosus reflex.
- D. Abdominal reflex.

Root value : S2, S3, S4. Elicited by compressing the glans penis or clitoris, the anal sphincter will contract.

Q. Complete transection of the spinal cord at the C7 level produces all of the following effects except :

- A. Hypotension.
- B. Limited respiratory effort.
- C. Anaesthesia below the level of the lesion.
- D. Reflexes below the level of the lesion.

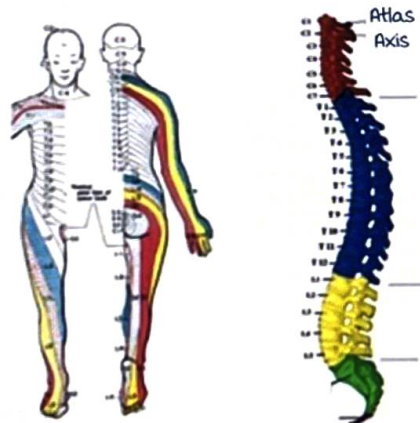
60c6b3eap8dtd0e4e7e5e17

Exaggerated reflex is seen as the inhibitory effect on the muscle tone by brain is lost.

Q. A patient met with an RTA presents with Quadriparesis with bladder involvement, sensory level is only up to the upper border of manubrium. The patient is tachypnoeic with RR : 36/min, what is the likely level of lesion?

- A. C1-C2. (If injure, no breathing)
- B. C4-C5.
- C. T1-T2. } brachial plexus
- D. T3-T4. } spared

Dermatomes



Q. Little finger of right hand corresponds to which dermatome?

- A. C6.
- B. C7.
- C. C8.
- D. T1.

Q. A Pt has sensory loss over the tip of little finger. which nerve is injured?

- A. Ulnar nerve.
- B. C8 spinal nerve.
- C. median nerve.
- D. Radial nerve.

Peripheral nerve is a conduit of multiple spinal nerves.

Q. A scooter is hit from behind, the rider is thrown off and he lands with his head hitting the kerb. He does not move, complains of severe pain in the neck and is unable to turn his head. Well-meaning onlookers rush up to him and try to make him sit up. What would be the best course of action in this situation?

- A. He should be propped up and given some water to drink.
- B. He should not be propped up but turned on his face and rushed to the hospital.
- C. He should be turned on his back and a support should be placed behind his neck and transported to the nearest hospital.
- D. He should not be moved at all but carried to the nearest hospital in the same position in which he has been since his fall.

Q. A middle aged lady presents with complaints of lower back pain. On examination there is weakness of extension of right great toe with no sensory impairment. An MRI of the lumbosacral spine would most probably reveal a prolapsed intervertebral disc at what level?

- A. L3-L4.
- B. L4-L5.
- C. L5-S1.
- D. S1-S2.

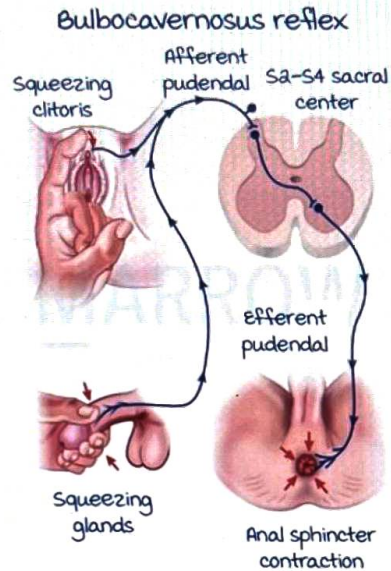
Extensor hallucis longus involved, root value L5.

Q. A body builder lifting heavy weights in the gym landed up with severe pain in back. MRI was done. MRI shows "Disc Prolapse L3-4". What neurological deficit will you expect in?

- A. Knee Reflex (L3-L4).
- B. Ankle Reflex (S1-S2).
- A. A & B Exaggerated.
- B. A Depressed, B Normal.
- C. A Depressed, B Depressed. (possible if massive disc prolapse/cauda equina syndrome)
- D. Both A & B Normal.

Q. Bulbocavernosus reflex is elicited by all except?

- A. Tug of glans penis.
 - B. Tug of clitoris.
 - C. Tug of foley catheter.
 - D. Scratching around the anal sphincter.
- (Anal wink, primitive superficial reflex)

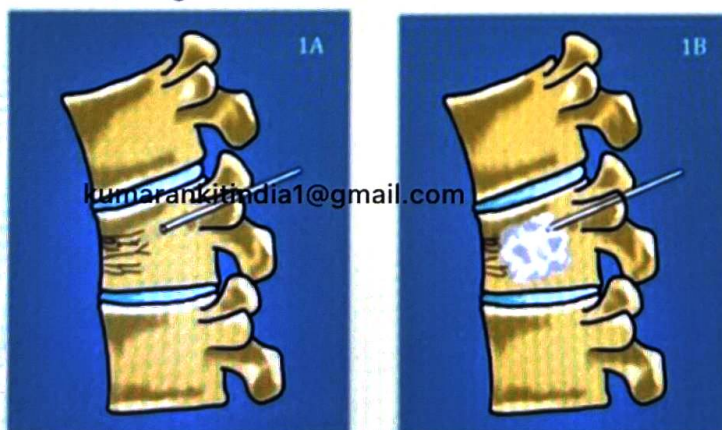


Q. What is vertebroplasty :

- A. Stabilization of vertebral compression fracture.
- B. Replacement of vertebral body only.
- C. Replacement of vertebral body with intervertebral disc.
- D. Fusion of the adjacent vertebrae.

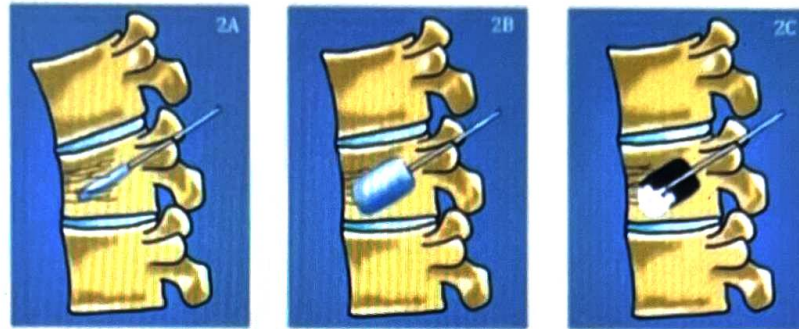
Ballon kyphoplasty : Restoring height by inflating the vertebra with ballon and injecting with bone cement (poly methyl metha acrylate)

vertebroplasty



Active space

Kyphoplasty : Balloon



Q. Percutaneous vertebroplasty is indicated in all except :

- A. Tuberculosis.
- B. metastasis.
- C. Osteoporosis.
- D. Haemangioma.

Due to infection, never introduce a foreign object, as symptoms of infection get exaggerated.

60c6b3eeaa8ded0e4e7e5ea7 Q. Which vertebrae is fractured in whiplash injury of spine ?

- A. C5-6.
- B. C3-4.
- C. C1-2.
- D. C6-7.

None of the above.

Whiplash injury is a soft tissue injury of anterior longitudinal ligament, not a fracture.

No neurological deficits seen.

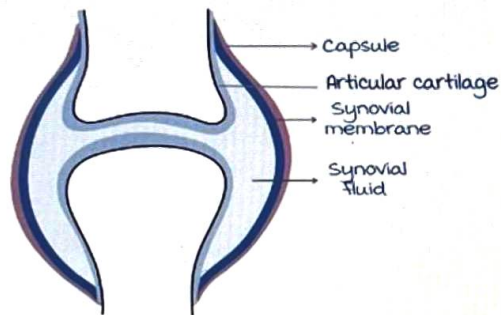
Rear end collision, type of hyperextension injury.

JOINT DISORDERS : PART 1

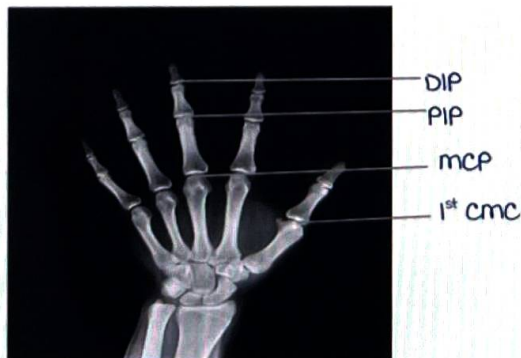
Anatomy of a joint

00:01:58

- Articular cartilage :
Present at the ends of the bone (proximal and distal).
Acts as a shock absorber.
Allows an easy/gliding movement of joints.
- Capsule.
- Synovium → Filled with synovial fluid.



Osteoarthritis	Rheumatoid arthritis
Involved : Distal inter-phalangeal joint (DIP). Proximal inter-phalangeal joint (PIP). 1 st Carpo-metacarpal joint (CMC).	Involved : meta-carpophalangeal joint (MCP). Wrist. Proximal inter-phalangeal joint (PIP).
Spared : Wrist. meta-carpophalangeal joint (MCP).	Spared : Distal inter-phalangeal joint (DIP).



Active space

Osteoarthritis

00:07:47

most common joint disease.

Degenerative disease of the cartilage.

As the cartilage is destroyed the bone ends rub against each other :

- Cause pain (both active & passive movements).
- Sclerosis of ends.
- Necrosis/cysts.

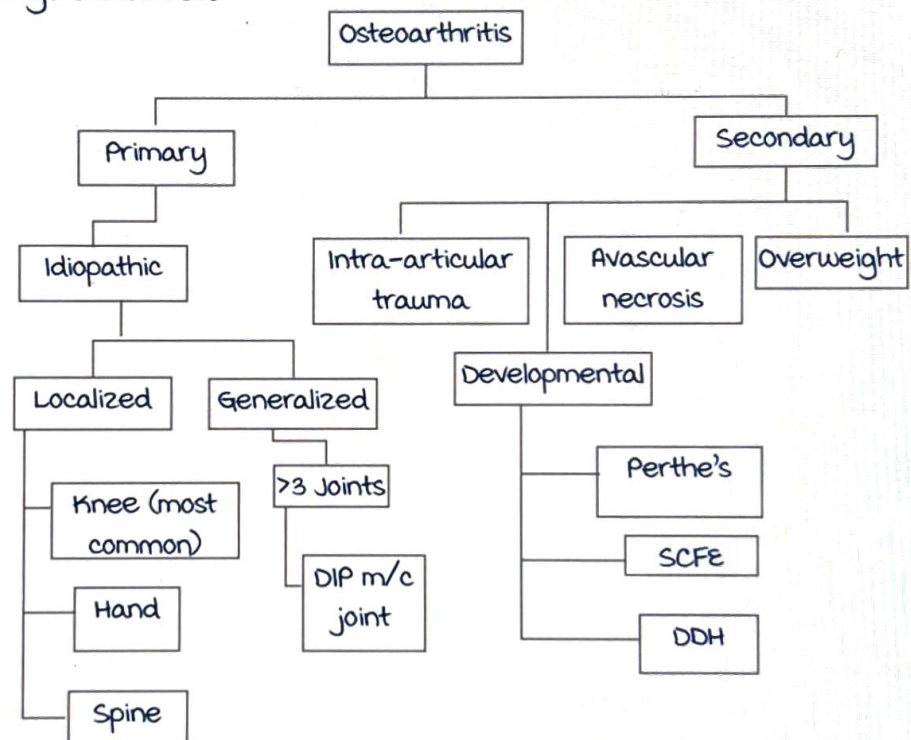
60c6b3eaa8ded0e4e7e5ea7

- Regeneration & osteophytes.

Swelling & deformity.

Decreased range of movement.

Inflammatory changes are typically absent, less pronounced, or go unnoticed.



Clinical features

00:14:09

Intra articular cause : Pain in active & passive movement the joint :

Whereas extra articular cause of pain is on active movement of joint (due to muscle pulling).

Crepitations.

Decreased range of movements.

Wasting of muscles due to decreased usage.

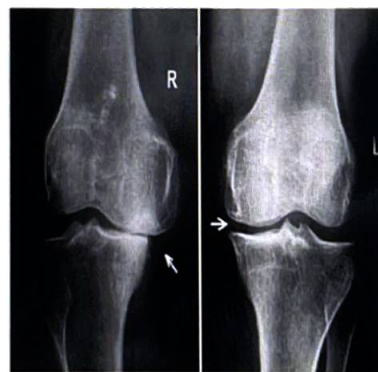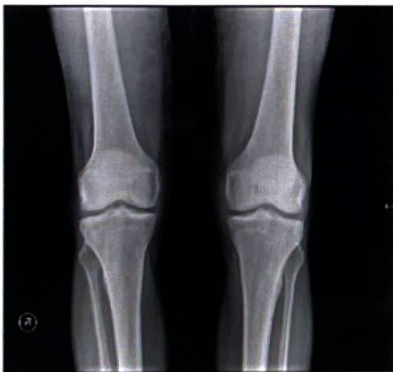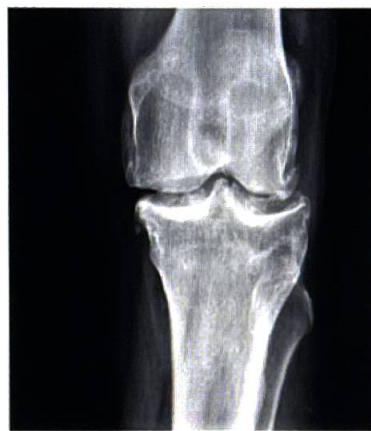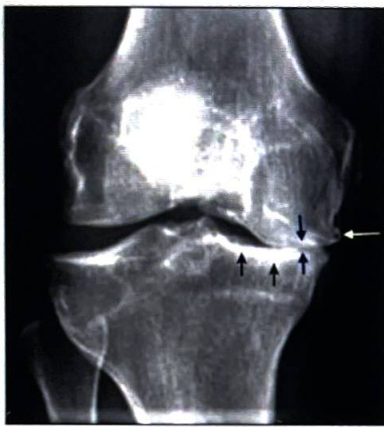- Quadriceps.
 - Vastus medialis.
- } In knee

Deformity/ Swelling.

X-ray findings :

1. Decreased joint space :

- Earliest X-ray finding.
- Due to destruction of cartilage.
- Bone on bone appearance.
- Joint space reduced (medial > lateral), because knees carry more weight over medial compared to lateral.



2. Subchondral sclerosis (increased load on bone).

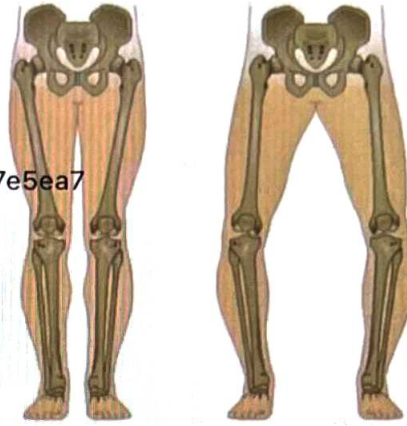
3. Subchondral necrotic cysts.

4. Osteophytes :

- Regeneration of bone.
- Break off from loose bodies.

most common cause of loose body in knee joint : **Osteophyte of osteoarthritis.**

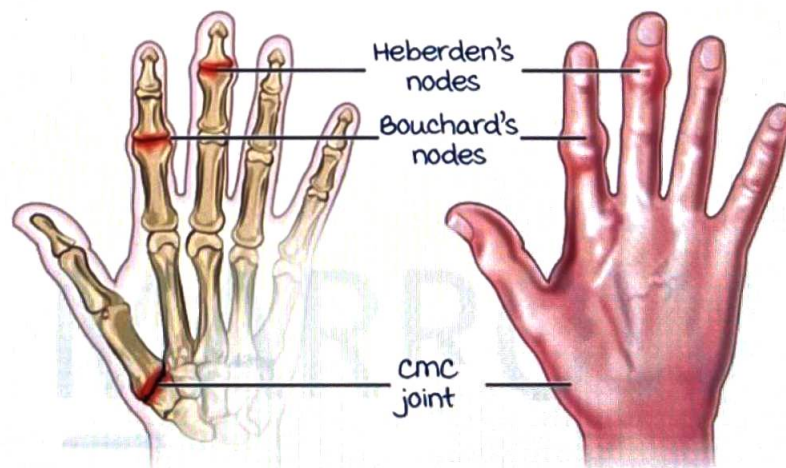
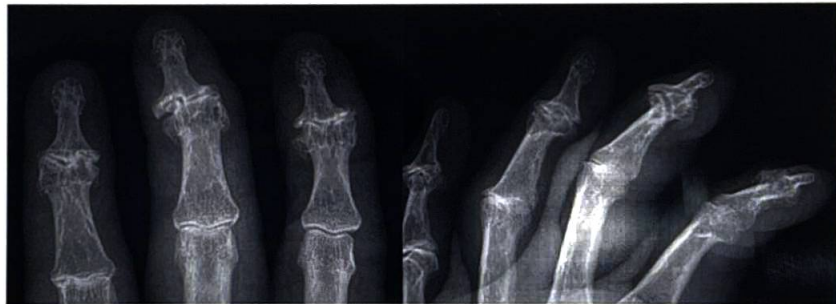60c6b3eaaa8ded0e4e7e5ea7



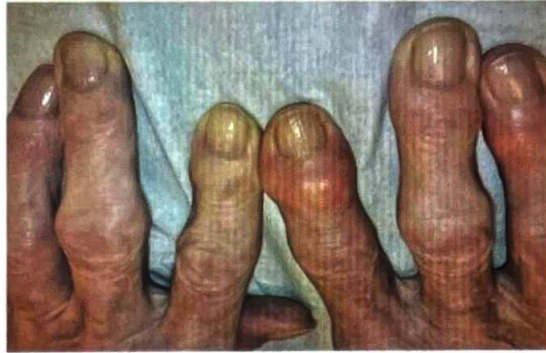5. Genu varus deformity :

- Joint space of medial side reduced which leads to shifting of tibia towards midline resulting in deformity.
- Varus deformity will perpetuate more damage to medial condyle and lead to osteoarthritis and becomes a vicious cycle.

6. Osteoarthritis of hands :



Bouchard's and Heberden's nodes



Swelling at DIP → Heberden's nodes.

Swelling at PIP → Bouchard's nodes.

Treatment

00:23:17

Conservative treatment :

Prevent the progress :

- Weight loss.

Physiotherapy : To prevent muscle atrophy.

- Heat.
- **Strengthening** : Vastus medialis oblique strengthening exercises.

Walking with support (crutch held in opposite side).

Braces to support the joint.

NSAIDS for pain :

- Acetaminophen.
- COX inhibitors.

Cartilage protectors (early stage) :

- **Glucosamine**.
- Chondroitin sulphate.

Lubrication :

- Visco supplements : **Injection Hyaluronic** (No evidence to support its action).

Surgical options :

Arthroscopy : **Joint wash out** → To remove loose bodies.

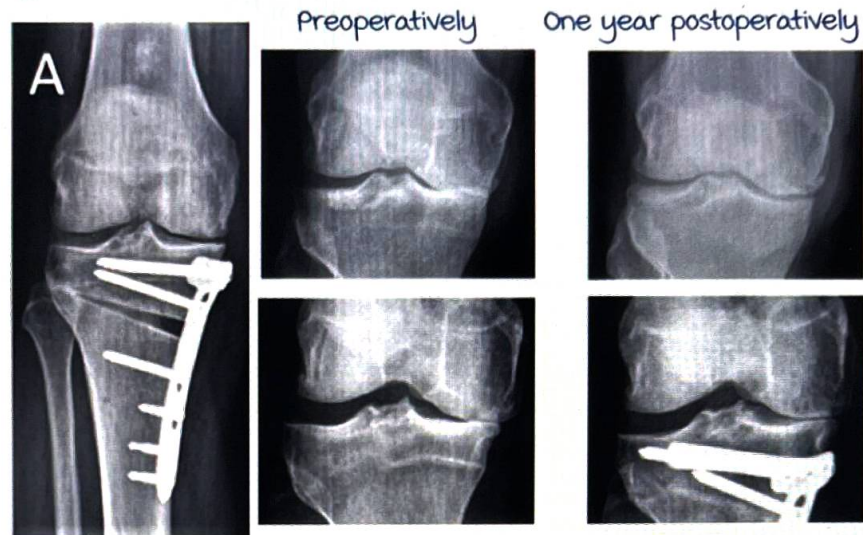
High tibial osteotomy : To correct **varus deformity**.

Arthroplasty :

- UKR : Uni-Condylar Knee Replacement.
- TKR : Total Knee Replacement.
- THR : Total Hip Replacement.

Active space

High Tibial Osteotomy: Varus is corrected to remove the excess weight falling on the medial joint line. medial side of tibia is cut & joint is straightened. This helps decrease the pain and slows the process of degeneration.



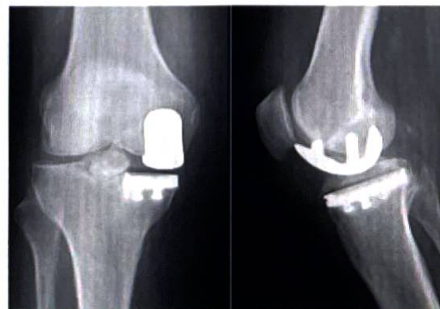
kumarankitindia1@gmail.com

Indications:

- Young population.
- Early stage of osteoarthritis.
- Only medial side affected.

Contraindications of High Tibial Osteotomy:

- Bi compartmental disease/lateral condyle involved / Rheumatoid arthritis. (inflammatory pathology)
- >20 degrees varus correction required.
- Decreased range of movement of knee :
Knee flexion < 90 degrees.
Flexion contracture > 15 degrees.



Uni Condylar Knee Replacement (UKR)

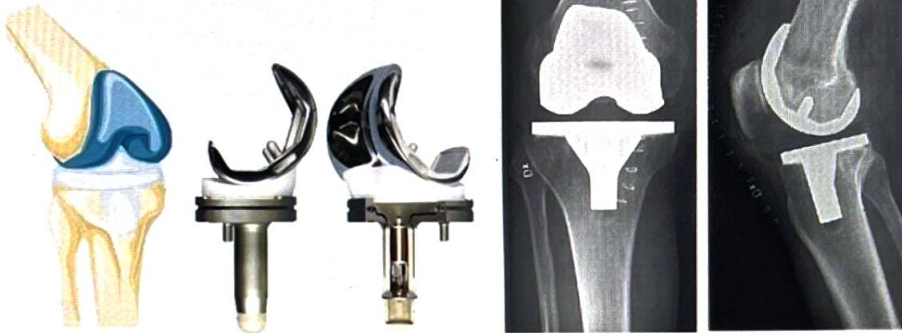
Contraindications :

- Bicompartamental syndrome.
- Rheumatoid arthritis (inflammatory arthritis involving both condyles).

Total Knee Replacement (TKR) :

Has various components :

- Femoral component.
- Tibial component.
- Insert (in the middle).



Patellar clunk syndrome :

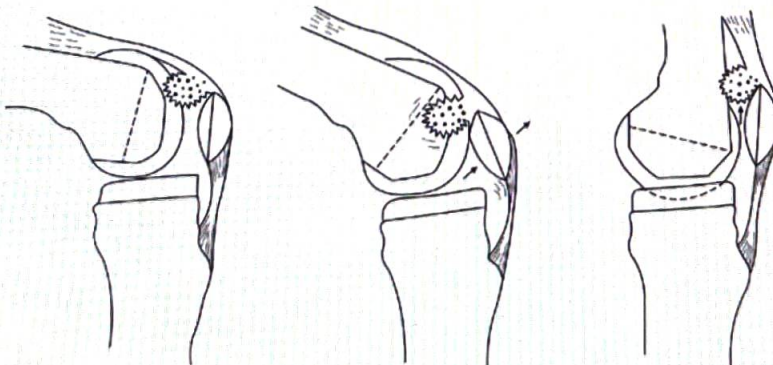
Complication in patients who undergo Total knee replacement.

There is sometimes friction between the patella and the femoral component.

Due to this, a fibrotic nodule forms at the superior pole of patella.

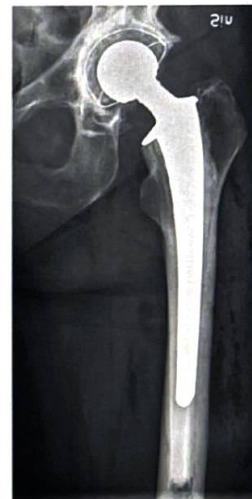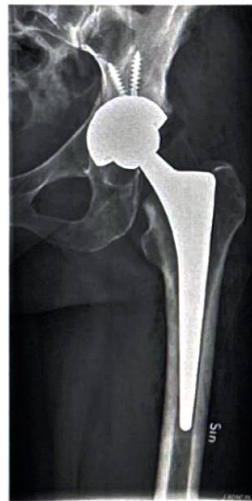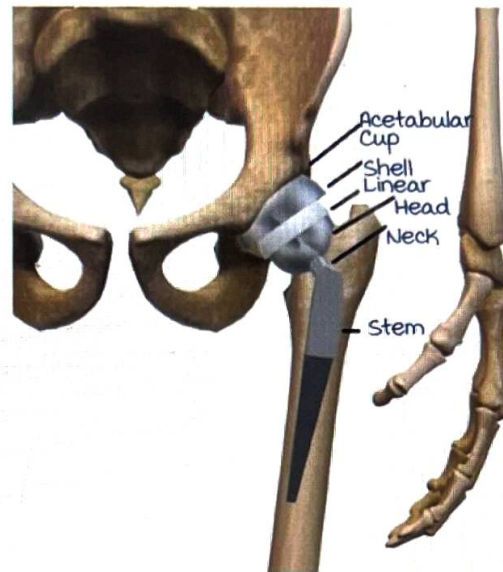
When the patient tries to extend the knee from a flexed position, this nodule gets stuck in the femoral component leading to catching of the knee.

Patient feels resistance and suddenly extends, causing the nodule to pop out, thereby enabling extension.



Total Hip Replacement :

Has 2 components : Femoral & acetabular.



Rheumatoid arthritis

00:35:29

- Disease of **synovium**.
- most common type of **inflammatory arthritis**.
- Chronic autoimmune multisystem disease with predominant musculoskeletal manifestations (autoimmune response directed against synovial structures & other organs like lungs, heart, liver etc.).
- Erosive type of arthritis : Destroys the joint (SLE is non-erosive).
- Females > males.
- **Symmetrical peripheral joint involvement**.

- Joints involved :

Hand : MCP > wrist, PIP.

Knee & hip. (DIP spared)

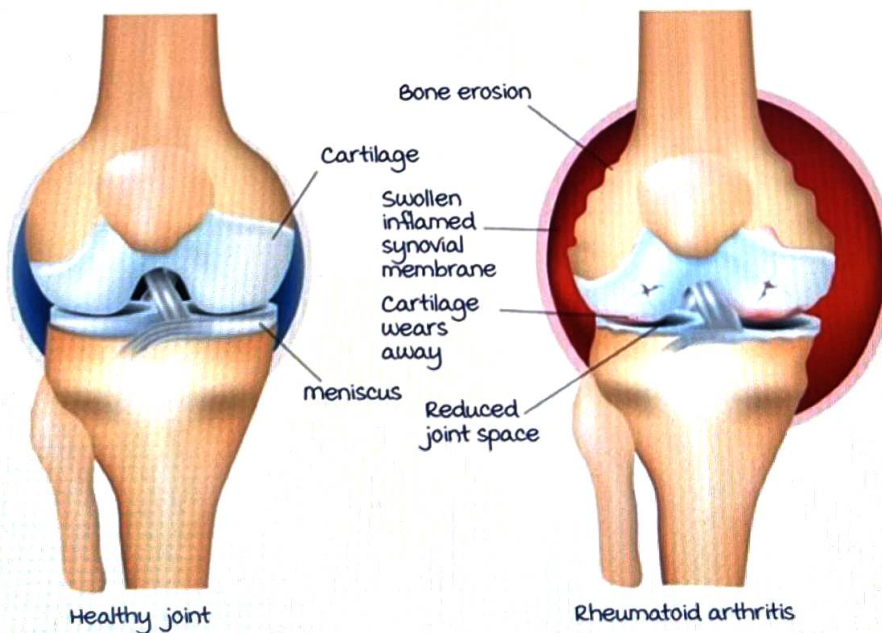
Axial is rare : may involve cervical spine (Subluxation of C1-C2 vertebrae : cord compression).

Pathology :

- Autoimmune disease (antigen/antibody reaction) leading to inflammation & destruction of synovium.
- microvascular proliferation due to inflammation :
Synovial **pannus** formation from **periphery to center**.
- Autoantibodies induce formation of immune complexes which cause obstruction of vessels → Reduces blood flow in periphery leading to ischemia → Cartilage destruction.
- Excessive cartilage destruction → Joint subluxation.

As disease progress further, fibrosis forms leading to fusion of joints called **ankylosis**.

Fusion occurs due to the formation of fibrous tissues known as **fibrous ankylosis**.



Associations

00:43:57

many multisystem medical associations leading to **decreased life expectancy** :

- Carditis.
- Pleuritis.
- Caplan syndrome.
- Felty Syndrome.

mcc of death is **CAD/CVS problems**.

kumarankitindia1@gmail.com

Diagnosis :

most sensitive marker → **Rheumatoid Factor** :

- Igm antibody against FC portion of the IgG antibodies.

most specific marker → **Anti CCP** (anti-cyclic citrullinated peptide).

Elevated CRP or ESR.

Poor prognostic factors :

- High RF, ESR, CRP.
- Subcutaneous nodules.
- Other extraarticular manifestations.
- Erosions on X-ray.
- Chronicity : History of > 1 year.

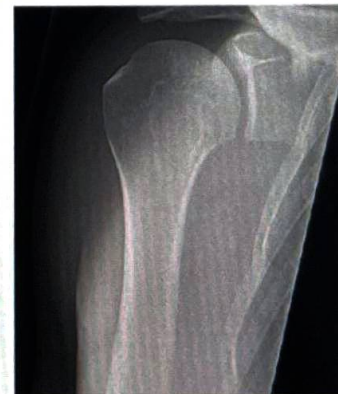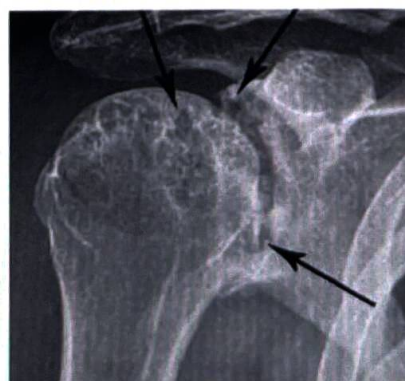
X-ray findings :

Narrowing of joint space.

Osteoporosis : Initially **juxta-articular**, and later generalized.

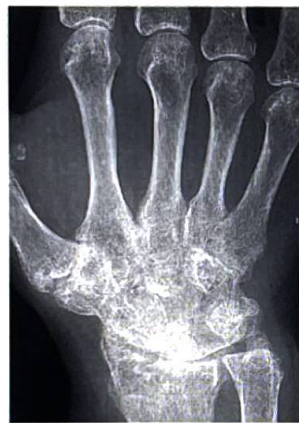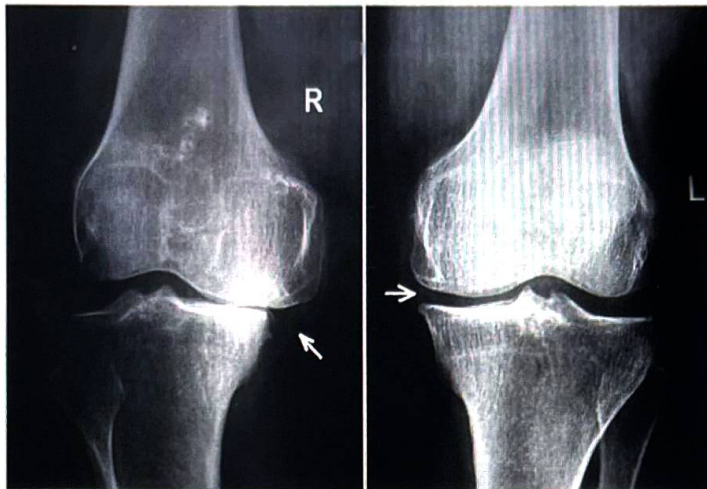
No sclerosis / No osteophytes (seen in OA).

marginal erosions.



Osteoarthritis Vs Rheumatoid arthritis

Osteoarthritis : Subchondral sclerosis seen

Rheumatoid arthritis
: No sclerosisDeformities

00:49:14

1. Hand : 60c6b3eaaa8ded0e4e7e5ea7

- Swan neck deformity.
- Boutonniere deformity.
- Z deformity.

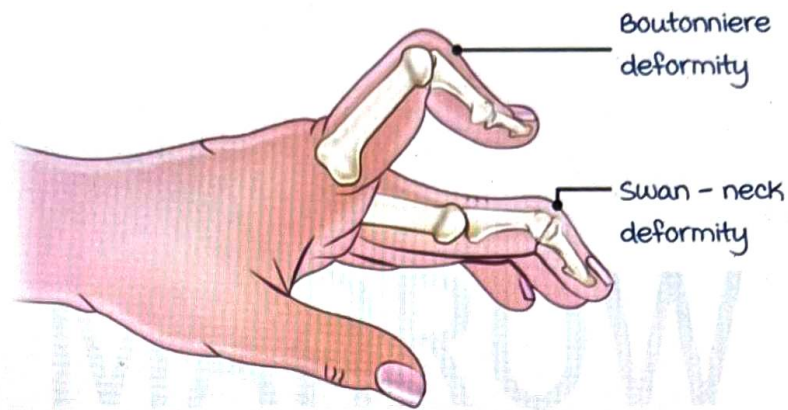
2. Knee :

- Bilateral genu valgus.
- Wind swept deformity.
- Triple deformity.

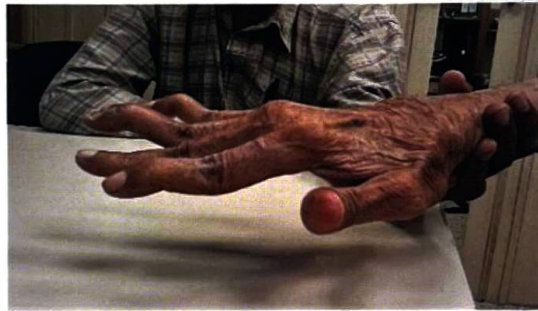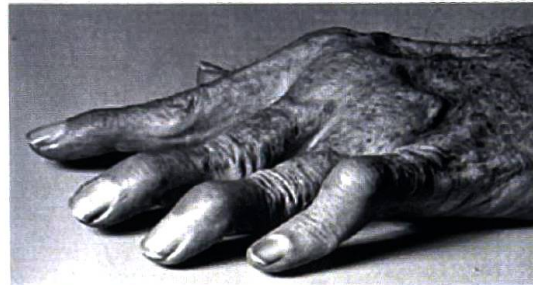3. Foot :

- Hammer toe.
- Hallux valgus.
- Wind swept deformity.

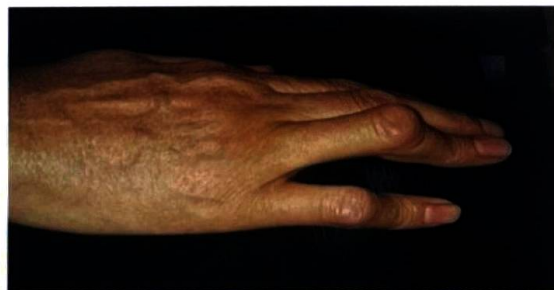Active space



Swan neck deformity : Extension at PIP and flexion of DIP.



Boutonniere deformity : Flexion at PIP and extension at DIP.



DIP is not involved in rheumatoid arthritis and occurs as a result of compensatory manifestation of the disease.

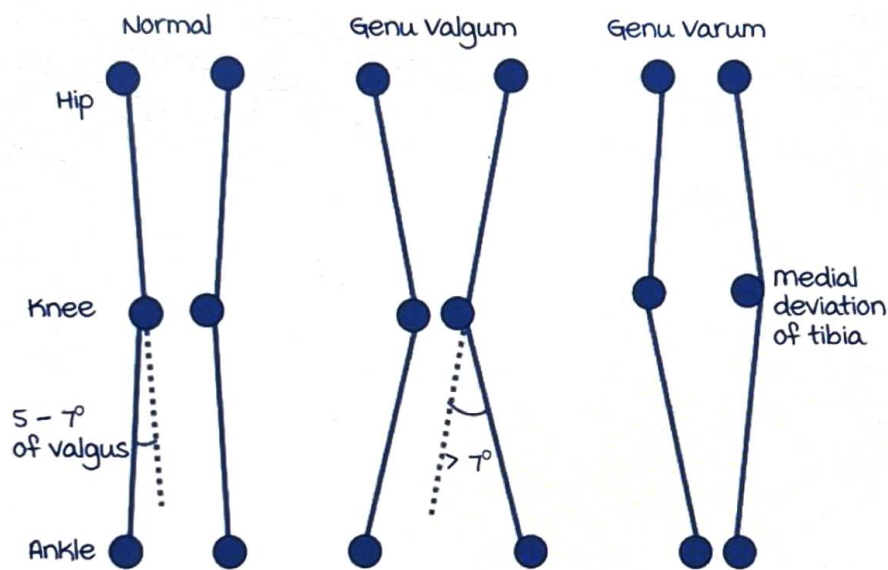
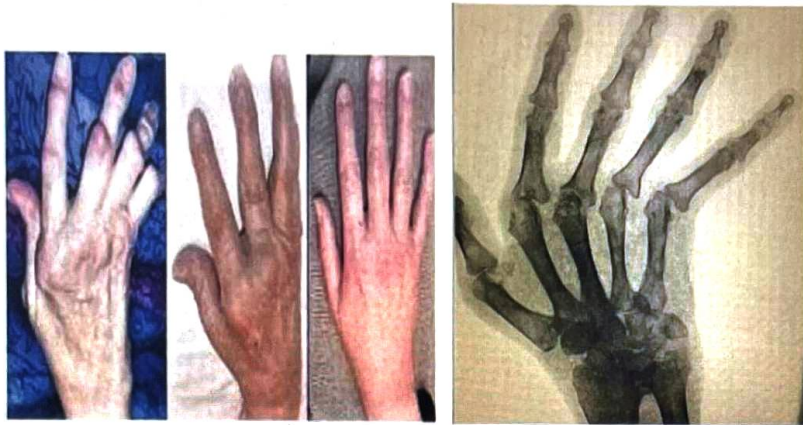Boutonniere : Failure of PIP extensor and DIP goes into compensatory extension.

60c6b3eeaa8ded0e4e7e5ea7

Swan neck deformity : Failure of PIP flexor and DIP goes into compensatory flexion.

Z deformity :

Radial deviation of the wrist and ulnar deviation of the fingers.



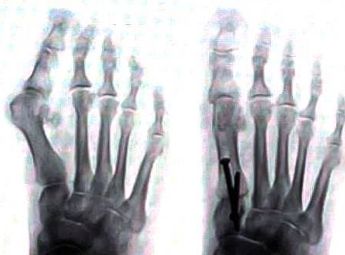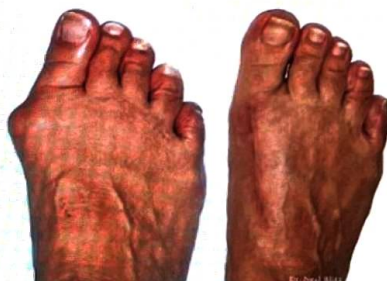Genu varus : Osteoarthritis.

Genu valgus : Rheumatoid arthritis.

kumarankitindia1@gmail.com

Hallux valgus

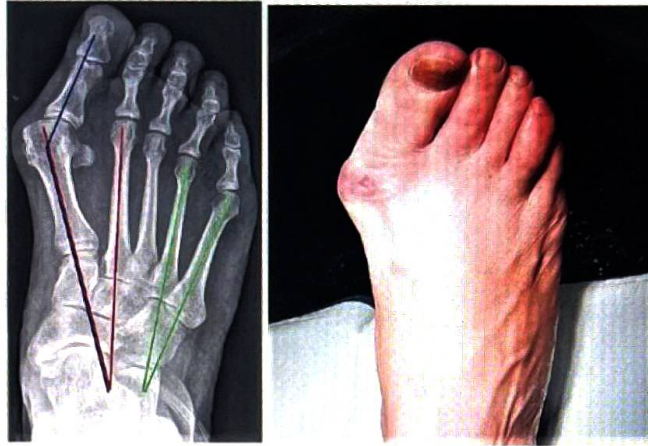
Wind swept deformity of knee



Active space

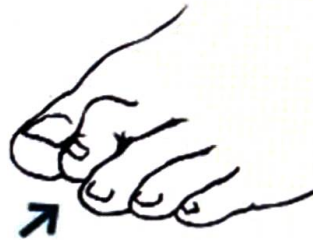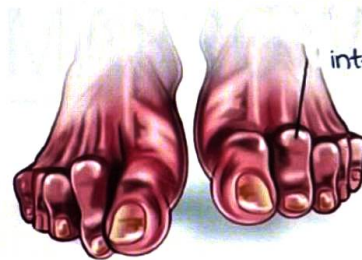Windswept deformity :

- Knee : One knee in valgus and other in varus.
Rickets > Rheumatoid Arthritis.
- Foot : One toe in valgus, other in varus (hallux valgus).
Rheumatoid arthritis.

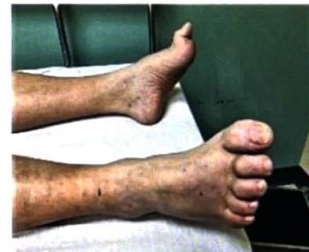

Hammer toes :

Flexion at the proximal interphalangeal joint

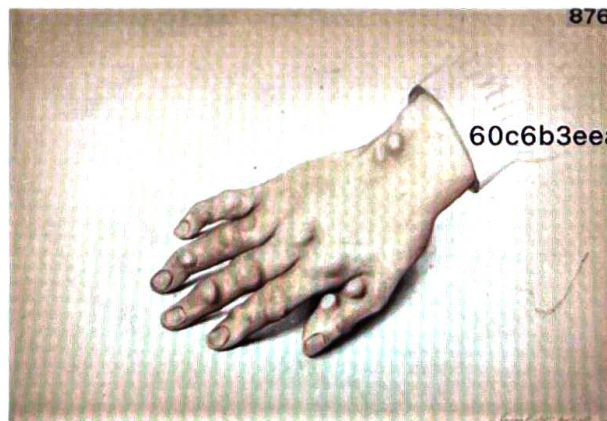


Dedo en martillo



Extra articular manifestations :

- Subcutaneous nodules.
- Eye involvement : Scleritis.



876

60c6b3eaa8ded0e4e7e5ea7

Active space

management :

- Physiotherapy.
- Drug of choice → **methotrexate**.
C/I pregnancy (stop 3 months before planning pregnancy).
- Unresponsive to therapy → **DMARD**.
- Immunosuppressant → **Leflunomide**.
- **Infliximab / Adalimumab** → TNF alpha inhibitor.
- **Anakinra** → IL-1 receptor antagonist.
- **Rituximab** → Anti CD20 antibody.
- Surgical → **Synovectomy**, joint replacement, deformity corrections.

Spondyloarthropathies

00:57:20

- Inflammatory arthritis affecting the spine and joints.
- Axial > appendicular skeleton.
- Rheumatoid factor **negative** (Sero negative spondyloarthropathies).
- Young males more than females.
- HLA B27 positive.
- **uveitis** (Scleritis in RA).
- Conditions
 1. most common → **Ankylosing spondylitis**.
 2. Enteropathic arthritis → Inflammatory bowel diseases : Crohn / ulcerative colitis.
 3. Psoriatic arthritis.
 4. Reactive arthritis : Shigella, chlamydia.

Ankylosing spondylitis :

Also called **Marie-Strumpell disease / Bechterew's disease**.

male > female.

HLA B27 positive.

Axial > Peripheral.

m/c involved : **Sacro iliac joint, lumbar spine, Hip involvement.**

Pathology : **Enthesopathy**.

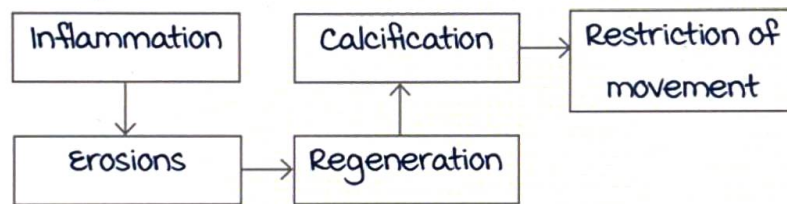
Active space

Clinical features :

- Pain at **gluteal region or back** (Sacroiliitis).
- **morning stiffness** (back pain) which improves with activity (washout of inflammatory substances by blood)
- Decreased lumbar spine movement.
- Anterior uveitis. kumarankitindia1@gmail.com
- Cardiac & pulmonary manifestation.
- Decreased chest expansion (ribs wont move as attached to stiff spine).

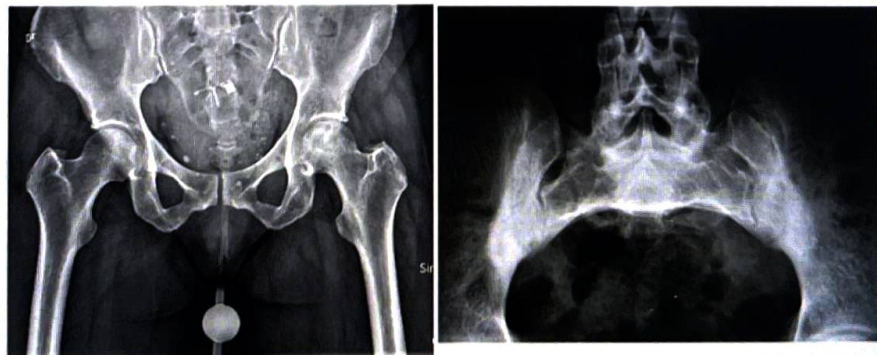
Pathogenesis

- Enthesitis : Inflammation of **enthesis** (insertion of ligaments & tendons on bone).
- Inflammation.
- Erosions.
- Calcification or bone formation.
- Restriction of movement.
- Spine & sacro-iliac Joint.

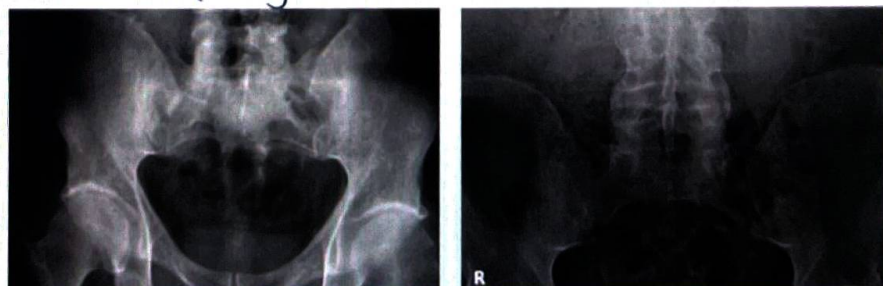


Sacroiliitis :

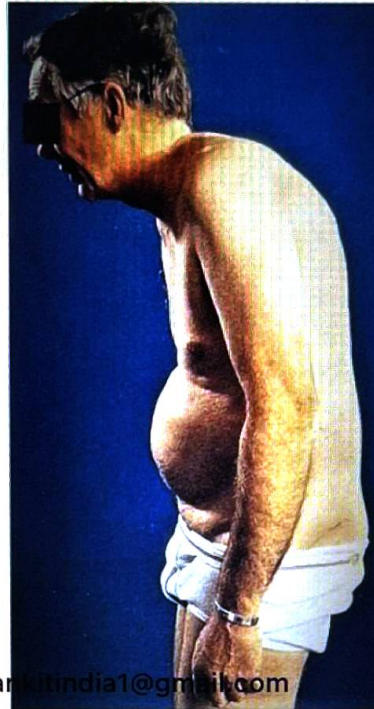
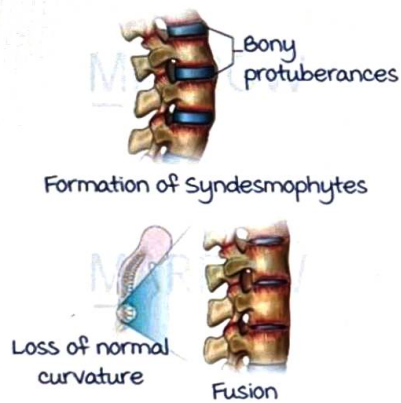
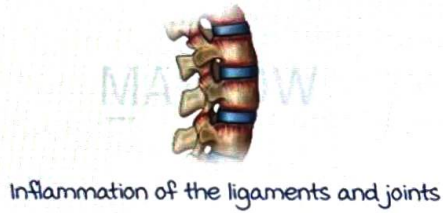
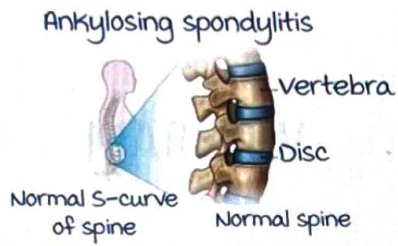
- **Juxta articular** erosion, blurring of margins & sclerosis.



- Fusion.
- Sclerosis & ankylosis.

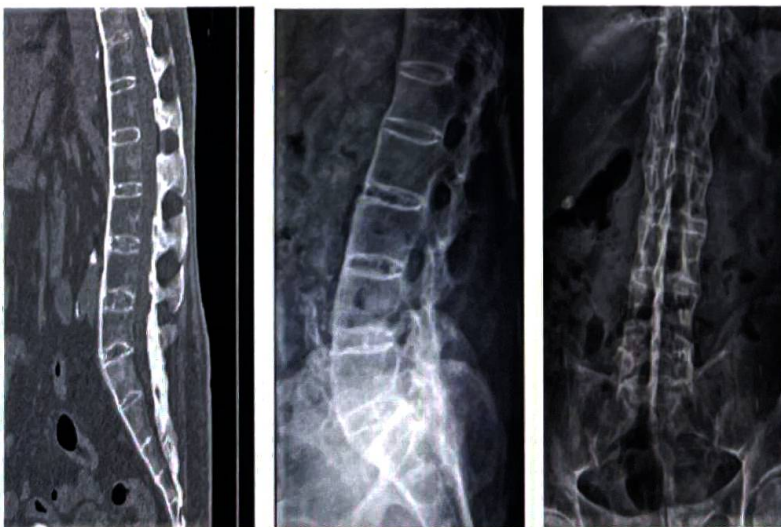

- vertical / bridging syndesmophytes.
- Squaring of vertebrae.
- Bamboo Spine.



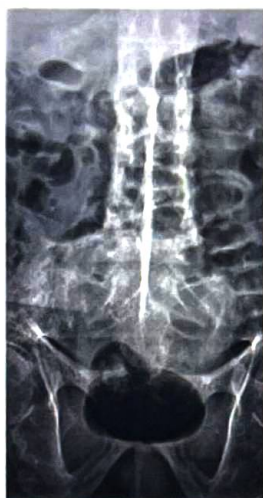Radiological findings in ankylosing spondylitis :

- Bamboo spine.

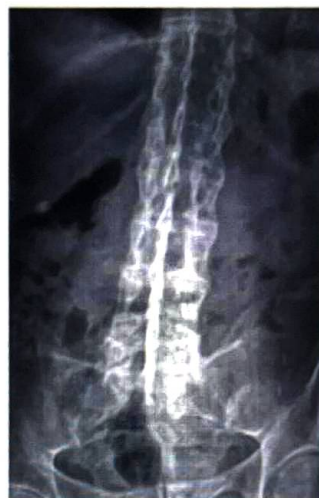

Active space

- **Dagger sign :**
Calcification of interspinous ligament.



Dagger sign



Trolley track sign

- **Trolley track sign :**
Calcification of interspinous ligament and bridging syndesmosis.
- **Shiny corner/ Romanus Lesion :**
Corners of vertebrae appears shinier due to reactive sclerosis.

Diagnostic criteria

01:08:05

kumarankitindia1@gmail.com

- **Essential criteria** → **Sacroiliitis :**
Earliest changes picked on MRI (On iliac side > sacral side).
- **Supportive criteria**
Decrease lumbar spine movement.
Decreased chest expansion.
Inflammatory back pain.

Clinical tests :

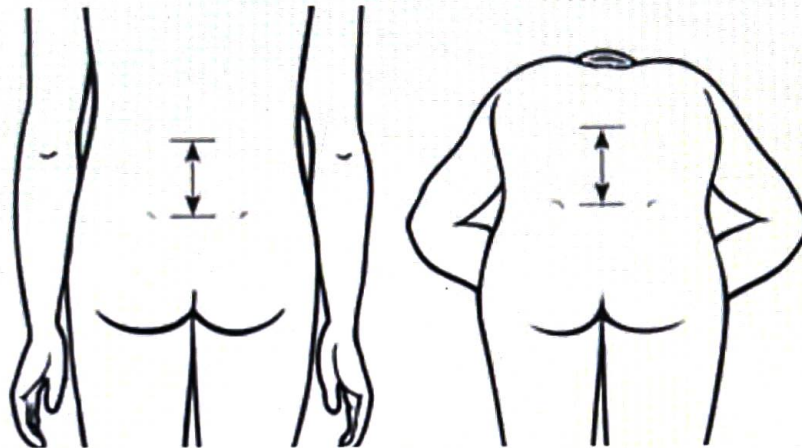
- **Decreased chest movement.**
- **For sacroiliitis :**
Gaenslen's test.
FABER test / Figure of 4 test.
Pump handle Test.
- **For testing lumbar spine mobility :**
Schober / modified Schober test :

Normally there will be lengthening of lumbar spine as patient bends forward.

In Ankylosing spondylitis, due to fusion there will be **no lengthening**.

In normal person **> 5 cm increase** in length on forward flexion.

Ankylosis of lumbar spine **< 5 cm increase** in length on forward flexion.



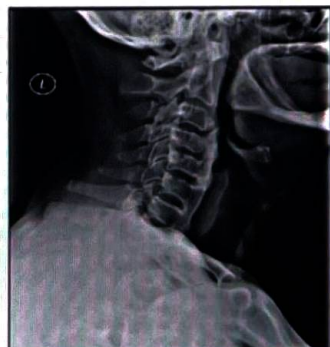Treatment :

- Physiotherapy.
- Exercises for stiffness :
Swimming.
- medical management :
NSAIDs.
Steroids.

Differential for DISH and AS.

Diffuse idiopathic skeletal hyperostosis (DISH) :

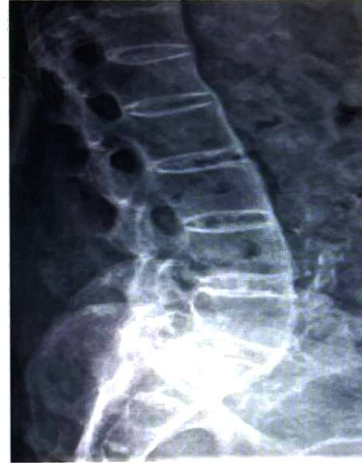- Also known as **Forestier** disease.
- Bony proliferation at spine affecting **elderly** individuals.
- Flowing ossification of the **anterior longitudinal ligament**.



Active space

In Ankylosing spondylitis :

- **Syndesmophytes** Thinner, form over the annulus, both anterior & posterior and are vertically oriented (bamboo spine).
- **Sacroiliac joint involvement.**
- **Occurs in younger population.**



Bamboo spine

60c6b3eaa8ded0e4e7e5ea7

Active space

JOINT DISORDERS : PART 2

Psoriatic Arthritis

00:00:15

Arthritis other than RA in patients with psoriasis.

AKA Erosive arthritis.

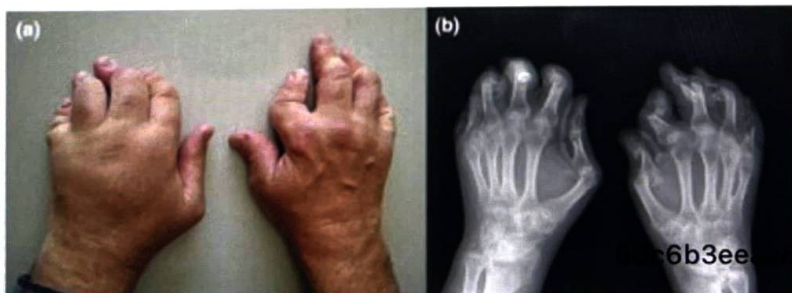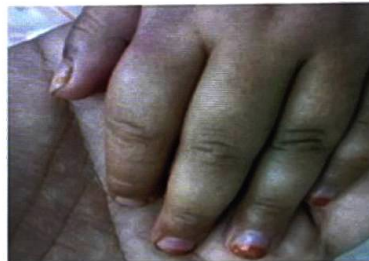CASPAR criteria :

- Psoriasis.
- RF negative.
- X ray changes.
- Dactylitis.
- Nail changes.

Females = males

Asymmetrical oligoarticular type (most commonly involved is DIP)

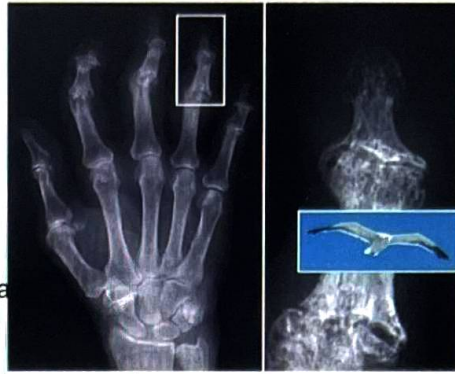- Dactylitis : Sausage digits due to swelling of fingers.
- Shortening of digits : Telescoping of fingers (will be able to pull the soft tissue).
- Arthritis mutilans : Erosive arthritis of ends of bone of hand & feet. Total destruction of bones.



6b3ee ded0e4e7e5ea7

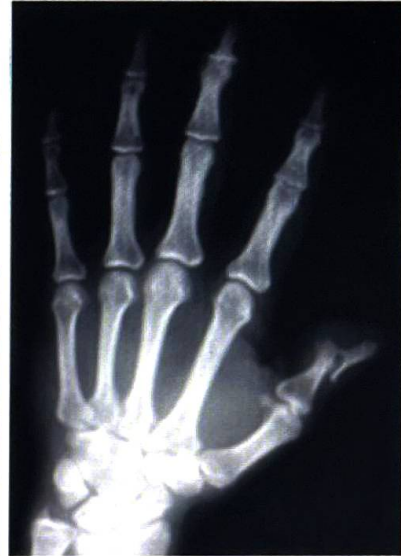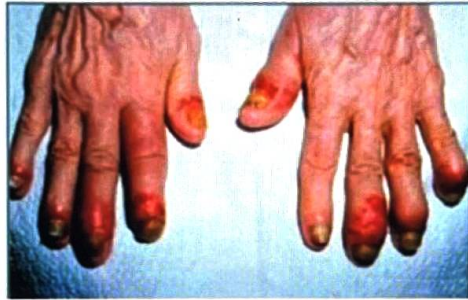Active space

60c6b3eaa8ded0e4e7e5ea

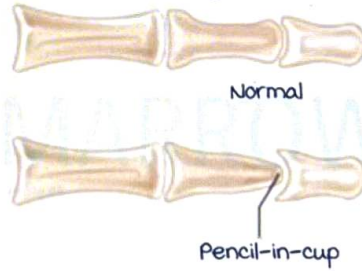


Gull - wing appearance (phalanges) : Destruction of articular cartilage in shape of sea gull

'Pencil in cup' Deformity
Psoriatic arthritis involving the distal interphalangeal joint.

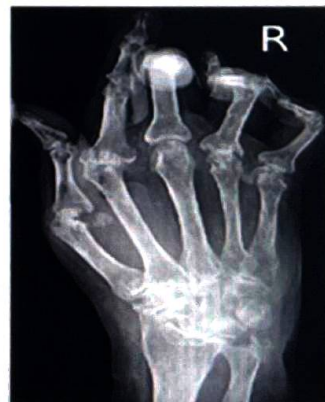
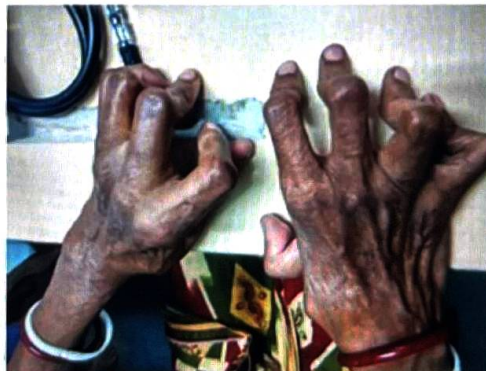
Pencil-cup deformity in psoriatic arthritis



Arthritis mutilans :

Can occur in any types of arthritis including rheumatoid arthritis.



Treatment :

Active space

Treatment of psoriasis.
methotrexate.

Hemophilic arthropathy

00:03:53

Seen in hemophiliacs.

Caused due to frequent bleeding in the joints leading to inflammation of the synovium, which causes destruction of the articular cartilage.

X-linked recessive.

Factor 8 > 9 deficiency.

Clinical Features :

- Recurrent episodes of bleeding in the joint.
- Subperiosteal bleeding.
- muscular bleeding :
Iliopsoas > Quadriceps.
Pseudo tumors (iliopsoas pseudo tumor can cause femoral nerve compression).



Synovium gets inflamed :

Destruction of articular cartilage

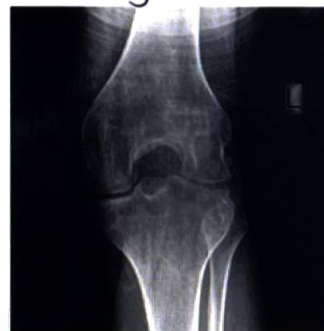most commonly involved : Knee > Elbow.

Position of ease : Flexion (minimum pain).

Aspiration is a relative contraindication which may lead to infection.

X-ray findings :

- Juxta articular osteopenia.
- Narrowing of joint space.
- Widening of intercondylar notch.
- Squaring of patella.



No sclerosis (if inflammation present : No sclerosis)

kumarankitindia1@gmail.com

Treatment :

Treat hemophilia :

- Factor replacement.
- Compression bandage.
- Ice pack application.

Crystal deposition arthropathy

00:08:10

Gout :

- Purine metabolism abnormality.
- Increased serum uric acid production.
- Normal value is 3.5 to 6.5 mg/dL.
- It's the sudden change in the serum uric acid concentration that manifests as gout because of the crystal deposition in the peripheral cold joints. This deposition leads to local inflammatory reaction leading to collateral damage and this causes pain.

Clinical features :

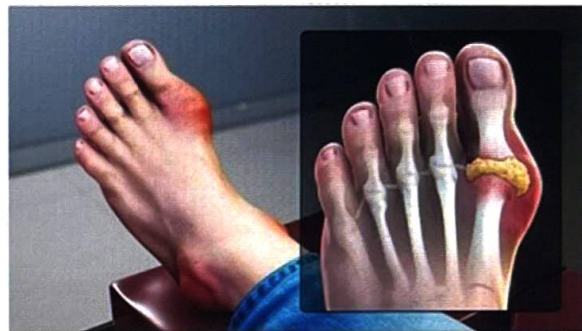History :

male > Female.

middle aged.

Keywords :

Alcohol.



- Drugs : Diuretics, aspirin.
- Business/leisure trip (Raised alcohol and meat intake)

Acute gouty pain :

- Tophi : Swollen, red 1st metatarsophalangeal joint.
- most involved joint is 1st metatarsophalangeal joint.

X-ray findings :

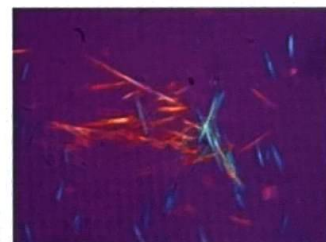
- Over hanging/martel & sign.
- Joint destruction.
- Punched out lesion.

Investigation of Choice :

Aspirate the contents of the joint/synovial fluid.

Characteristics of crystal :

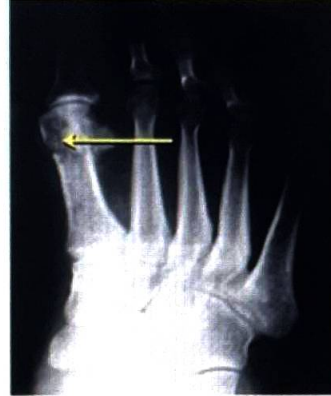- mono sodium urate.
- Needle shaped.
- On polarising light microscopy, negatively birefringent.



Treatment :

Acute gouty attack :

- NSAID : Indomethacin, colchicine is old and causes GI disturbance.
- Once acute pain is controlled use the drugs to control the serum uric acid concentration.



↳ martel sign

Chronic gout :

- Xanthine oxidase inhibitors :
Allopurinol.
Febuxostat.
Rasburicase.
- Uricosuric drugs :
Probenicid.

These drugs are never used in acute phase as they can suddenly drop uric acid levels & aggravate the condition.

Pseudogout

00:14:31

Elderly patients.

Females > males.

Associated with hypothyroidism.

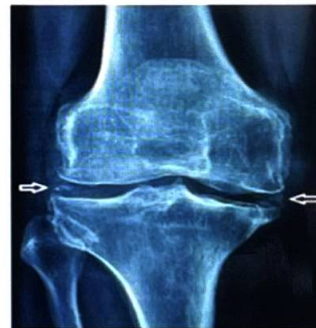Large Joints : Knee.

Investigation of choice : Aspiration.

Calcium pyrophosphate dehydrate

crystals :

- Polygonal in shape.
- Positively birefringent.

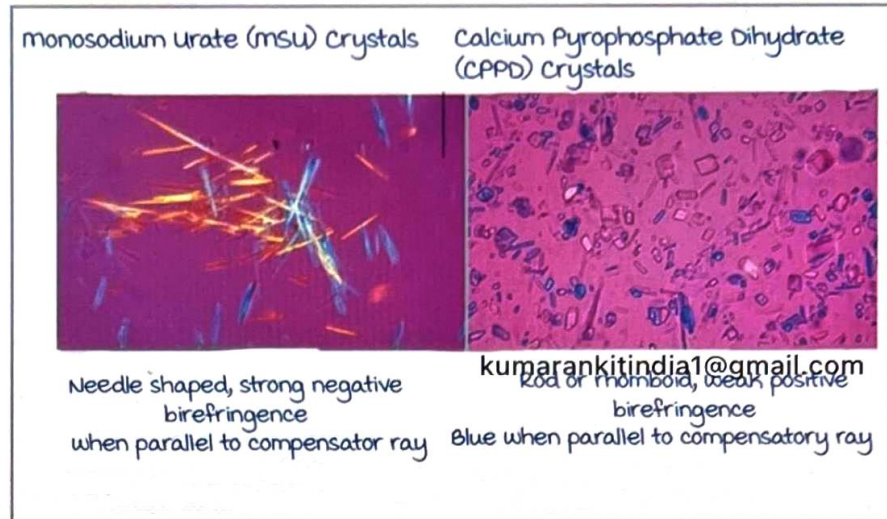


Chondrocalcinosis : Deposition of calcium in the cartilage.

Can also be seen in :

- Ochronosis/alkaptonuria.
- Hemochromatosis.
- Hyperparathyroidism.

Active space



Neuropathic joint

00:16:20

Destruction of bones due to repetitive trauma & abnormal position of joints owing to decreased sensation & proprioception (peripheral neuropathy).
AKA Charcot's joint.

Causes :

- **Diabetes mellitus** (most common) : midtarsal joints
> Tarso-metatarsal.
- Leprosy : Interphalangeal joints at hand.
- Syphilis : Knee.

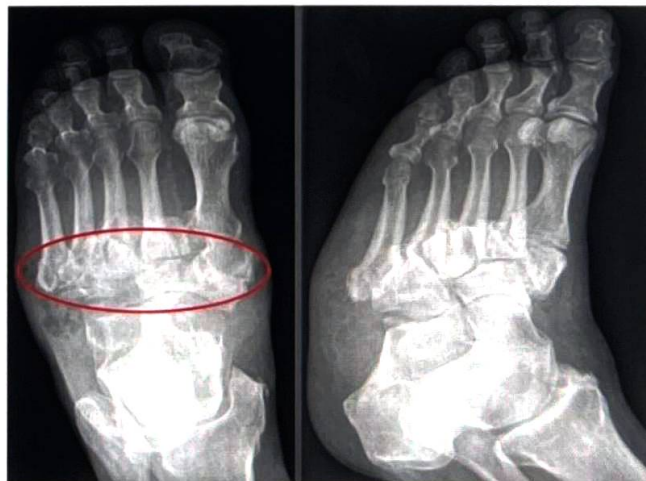Clinically : Bag of bones (mobile bony fragments) but no pain.

X-ray : Destruction of bones & joint.

Signs outweigh the symptoms.

Treatment : Arthrodesis (Surgical fusion of joints to stabilise the joint).

- Arthroplasty is contraindicated.



MCQs

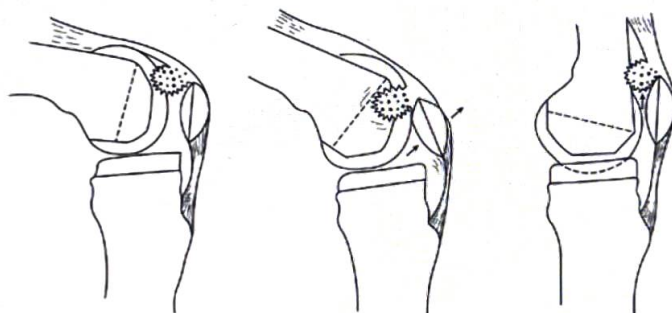
00:19:43

Q. During performing a total hip replacement, the surgeon found destruction of the articular cartilage and multiple wedge shaped subchondral depressions. What are these called?

- A. Osteolysis.
- B. Osteomyelitis.
- C. Osteonecrosis.
- D. Osteogenesis.

Q. Patellar clunk syndrome is a known complication of which surgery?

- A. Corrective osteotomy for genu valgum.
- B. Total knee replacement.
- C. medial patellofemoral ligament reconstruction.
- D. Bicondylar plating of proximal tibia fracture.



60c6b3eaa8ded0e4e7e5ea7

Fibrotic nodule which forms in the superior pole of patella because of friction from the femoral component, and when the patient extends the knee from a flexed position it leads to catching.

Q. A patient after THR develops breathlessness . which is a definitive management ?

- A. Thrombolysis.
- B. Bronchodilator
- C. Steroids.
- D. Oxygen.

Complications of Total Hip Replacement :

- Infections.
- Dislocation.
- Aseptic Loosening.

Active space

- Pulmonary thromboembolism : Dyspnoea after the surgery.
- Sciatic Nerve Injury.

Q. in THR metal on metal articulation should be avoided in ?

- Osteonecrosis.
- Young female.
- Inflammatory arthritis.
- Revision surgery.

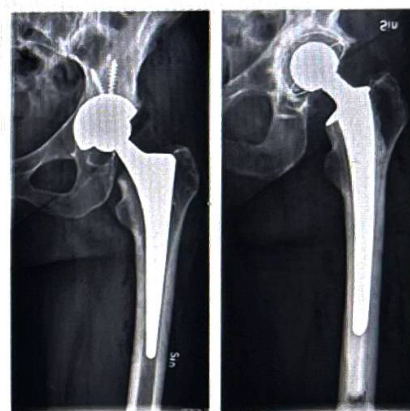Leached metal ions in circulation are teratogenic.

Types of materials in THR :

A. **metal on metal** Prosthesis :

Contra Indications :

- Hypersensitivity.
 - Pregnancy :
Teratogenic &
carcinogenic.
 - Renal Impairment.
- metal on polyethylene.
 - Ceramic on Ceramic.



Q. Which of the following is not true about osteoarthritis?

- Inflammation of synovial joint.
- Most common joint disease.
- Effects shoulder joint.
- Narrowing of joint space occurs.

Q. Pain and arthritis of distal interphalangeal joint is seen in?

- Osteoarthritis.**
- Rheumatoid arthritis.
- Ankylosing spondylitis. (axial > peripheral)
- de Quervain's disease. (Tenosynovitis of abductor pollicis longus & extensor pollicis brevis)

Q. Arthritis involving DIP, PIP, 1st carpometacarpal with sparing of MCP and wrist joints is typical of?

- Osteoarthritis.**
- Rheumatoid arthritis.
- Ankylosing spondylitis.
- Psoriatic arthritis.

Q. Which of the following is a true statement?

- A. Systemic symptoms are seen in osteoarthritis.
- B. Rheumatoid arthritis is uncommon in hands and feet.
- C. Osteoarthritis is an autoimmune disease. (degenerative disease)
- D. Osteophytes are seen in osteoarthritis.

Q. Most specific antibody seen in RA?

- A. Anti CCP.
- B. Rheumatoid factor. (most sensitive)
- C. ANA.
- D. Anti dsDNA.

Q. In which of the following deformities is the distal interphalangeal joint extended?

- A. Boutonniere deformity.
- B. Swan neck deformity. (Flexion of DIP)
- C. Z deformity.
- D. Claw hand.

Q. Hammer toe deformity is seen in?

- A. Rheumatoid arthritis.
- B. Fracture distal phalanx of great toe.
- C. Bunion.
- D. Osteochondritis.

kumarankitindia1@gmail.com

Q. Wind swept deformity of knee is seen in?

- A. Osteoarthritis.
- B. Rheumatoid arthritis.
- C. Ankylosing spondylitis.
- D. Psoriatic arthritis.

Q. Which of the following is not a feature of rheumatoid arthritis?

- A. Swan neck deformity.
- B. Ulnar deviation of fingers at metacarpophalangeal joint.
- C. Symmetric reduction of joint space.
- D. Heberden's nodes.

Heberden's nodes seen in osteoarthritis.

Q. A middle-aged female of rheumatoid arthritis on

treatment develops upper motor neuron sign in her limbs. The investigation required to evaluate her further is?

- A. Spine lateral view flexion and extension views.
- B. Open mouth view.
- C. Swimmer's view.
- D. Broden's view.

To see stability of cervical spine.

In RA peripheral > axial.

Q. Wind swept deformity is seen in?

- A. Ankylosing spondylitis.
- B. Scurvy.
- C. Rheumatoid arthritis.
- D. Rickets.

Wind swept deformity most commonly seen in children in knees due to rickets.

Q. Wind swept deformity in foot is seen in?

- A. Rickets.
- B. Rheumatoid Arthritis.
- C. Hyperparathyroidism.
- D. Scurvy.

Q. All are true about Marie Strumpel Disease except?

(Another name of ankylosing spondylitis)

- A. most commonly involves the sacroiliac joint.
 - B. Enthesitis is common.
 - C. more common in males.
 - D. Roentgenogram is the most sensitive investigation.
- MRI is the most sensitive investigation.

Q. A 25-year-old man complains of low back ache, decreased lumbar movements & morning stiffness. Which clinical examination will further help?

kumarankitmed@gmail.com

- A. Heel elevation.
- B. Chest expansion.
- C. Hyperextension of joints.
- D. Plantar arch.

Q. Charcot's joint is another name for joint affected by?

- A. Neuropathy.

- B. Osteoarthritis.
- C. Rheumatoid arthritis.
- D. Ankylosing spondylitis.

Q. Most common cause of neuropathic joint?

- A. Leprosy.
- B. Tabes dorsalis.
- C. Diabetes.
- D. Nerve injury.

Q. In a patient of gouty arthritis best investigation is?

- A. Serum uric acid estimation. (sudden rise or fall in uric acid level is not absolute serum value)
- B. Uric acid in urine estimation.
- C. Urate crystals in synovial fluid analysis.
- D. Serum calcium level estimation.

Q. Which joint is most commonly affected in pseudogout?

- A. Knee.
- B. Hip.
- C. MTP joint great toe.
- D. MCP joint thumb.

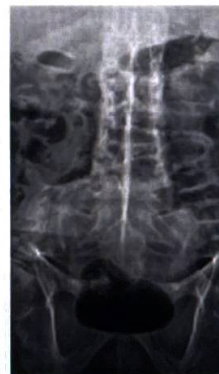Q. A lady presents with right knee swelling, aspiration was done in which CPPD crystals were obtained. Next best investigation is?

- A. ANA.
- B. RF.
- C. CPK.
- D. TSH.

Pseudogout is commonly associated with hypothyroidism.

Q. A 28-year-old man presented with complaints of backache, morning stiffness and redness of the eyes. X-ray image of the spine is given below. Which of the following is the most likely diagnosis?

- A. Rheumatoid arthritis.
 - B. Ankylosing Spondylitis.
 - C. Osteopetrosis.
 - D. Diffuse idiopathic skeletal hyperostosis.
- Dagger sign seen in the XRAY.



Active space